



AMERICAN ACADEMY  
OF OPHTHALMOLOGY®

Protecting Sight. Empowering Lives.

5

## Neuro-Ophthalmology

2023–2024  
**BCSC®**

**Basic and Clinical  
Science Course™**

### Editorial Committee

M. Tariq Bhatti, MD, *Chair*

John J. Chen, MD, PhD

Helen V. Danesh-Meyer,  
MBChB, MD, PhD

Leonard A. Levin, MD, PhD

Heather E. Moss, MD, PhD

Paul H. Phillips, MD

Gregory P. Van Stavern, MD

Zoë R. Williams, MD





AMERICAN ACADEMY  
OF OPHTHALMOLOGY®  
Protecting Sight. Empowering Lives.

# 5

## Neuro-Ophthalmology

*Last major revision 2021-2022*

2023-2024  
**BCSC**  
Basic and Clinical  
Science Course™



Published after collaborative  
review with the European Board  
of Ophthalmology subcommittee

The American Academy of Ophthalmology is accredited by the Accreditation Council for Continuing Medical Education (ACCME) to provide continuing medical education for physicians.

The American Academy of Ophthalmology designates this enduring material for a maximum of 15 *AMA PRA Category 1 Credits*<sup>™</sup>. Physicians should claim only the credit commensurate with the extent of their participation in the activity.

CME expiration date: June 1, 2024. *AMA PRA Category 1 Credits*<sup>™</sup> may be claimed only once between June 1, 2021, and the expiration date.

BCSC<sup>®</sup> volumes are designed to increase the physician's ophthalmic knowledge through study and review. Users of this activity are encouraged to read the text and then answer the study questions provided at the back of the book.

To claim *AMA PRA Category 1 Credits*<sup>™</sup> upon completion of this activity, learners must demonstrate appropriate knowledge and participation in the activity by taking the posttest for Section 5 and achieving a score of 80% or higher. For further details, please see the instructions for requesting CME credit at the back of the book.

The Academy provides this material for educational purposes only. It is not intended to represent the only or best method or procedure in every case, nor to replace a physician's own judgment or give specific advice for case management. Including all indications, contraindications, side effects, and alternative agents for each drug or treatment is beyond the scope of this material. All information and recommendations should be verified, prior to use, with current information included in the manufacturers' package inserts or other independent sources, and considered in light of the patient's condition and history. Reference to certain drugs, instruments, and other products in this course is made for illustrative purposes only and is not intended to constitute an endorsement of such. Some material may include information on applications that are not considered community standard, that reflect indications not included in approved FDA labeling, or that are approved for use only in restricted research settings. **The FDA has stated that it is the responsibility of the physician to determine the FDA status of each drug or device he or she wishes to use, and to use them with appropriate, informed patient consent in compliance with applicable law.** The Academy specifically disclaims any and all liability for injury or other damages of any kind, from negligence or otherwise, for any and all claims that may arise from the use of any recommendations or other information contained herein.

All trademarks, trade names, logos, brand names, and service marks of the American Academy of Ophthalmology (AAO), whether registered or unregistered, are the property of AAO and are protected by US and international trademark laws. These trademarks include, but are not limited to, AAO; AAOE; AMERICAN ACADEMY OF OPHTHALMOLOGY; BASIC AND CLINICAL SCIENCE COURSE; BCSC; EYENET; EYEWIKI; FOCAL POINTS; FOCUS DESIGN (logo on cover); IRIS; IRIS REGISTRY; ISRS; OKAP; ONE NETWORK; OPHTHALMOLOGY; OPHTHALMOLOGY GLAUCOMA; OPHTHALMOLOGY RETINA; OPHTHALMOLOGY SCIENCE; OPHTHALMOLOGY WORLD NEWS; PREFERRED PRACTICE PATTERN; PROTECTING SIGHT. EMPOWERING LIVES.; THE OPHTHALMIC NEWS AND EDUCATION NETWORK.

Cover image: From BCSC Section 9, *Uveitis and Ocular Inflammation*. Image courtesy of Sam S. Dahr, MD, MS.



Copyright © 2023 American Academy of Ophthalmology. All rights reserved. No part of this publication may be reproduced without written permission.

Printed in South Korea.

# Basic and Clinical Science Course



Christopher J. Rapuano, MD, Philadelphia, Pennsylvania  
*Senior Secretary for Clinical Education*



J. Timothy Stout, MD, PhD, MBA, Houston, Texas  
*Secretary for Lifelong Learning and Assessment*



Colin A. McCannel, MD, Los Angeles, California  
*BCSC Course Chair*

## Section 5

---

### Faculty for the Major Revision



M. Tariq Bhatti, MD  
*Chair*  
Rochester, Minnesota



Heather E. Moss, MD, PhD  
Palo Alto, California



John J. Chen, MD, PhD  
Rochester, Minnesota



Paul H. Phillips, MD  
Little Rock, Arkansas



Helen V. Danesh-Meyer  
MBChB, MD, PhD  
Auckland, New Zealand



Gregory P. Van Stavern, MD  
St Louis, Missouri



Leonard A. Levin, MD, PhD  
Montreal, Canada



Zoë R. Williams, MD  
Rochester, New York

The Academy acknowledges the *North American Neuro-Ophthalmology Society (NANOS)* for recommending faculty members to the BCSC Section 5 committee.

The Academy also acknowledges the following committees for review of the major revision:

*Committee on Aging:* Andrew G. Lee, MD, Houston, Texas

*Vision Rehabilitation Committee:* Linda M. Lawrence, MD, DO, Salina, Kansas

*BCSC Resident/Fellow Reviewers:* Sharon L. Jick, MD, *Chair*, St Louis, Missouri; Gordon S. Crabtree, MD; Lindsay De Andrade, MD; Lilangi S. Ediriwickrema, MD; Michael P. Ellis, MD

*Practicing Ophthalmologists Advisory Committee for Education:* Rosa A. Tang, MD, MPH, MBA, *Primary Reviewer*, Houston, Texas; Bradley D. Fouraker, MD, *Chair*, Tampa, Florida; Cynthia S. Chiu, MD, Oakland, California; George S. Ellis Jr, MD, New Orleans, Louisiana; Stephen R. Klapper, MD, Carmel, Indiana; Gaurav K. Shah, MD, Town and Country, Missouri; Troy M. Tanji, Waipahu, Hawaii; Michelle S. Ying, MD, Ladson, South Carolina

In addition, the Academy acknowledges the following committee for assistance in developing Study Questions and Answers for this BCSC Section:

*Resident Self-Assessment Committee:* Evan L. Waxman, MD, PhD, *Chair*, Pittsburgh, Pennsylvania; Robert A. Beaulieu, MD, Royal Oak, Michigan; Benjamin W. Botsford, MD, New York, New York; Olga M. Ceron, MD, Grafton, Massachusetts; Eva DeVience, MD, Windsor Mill, Maryland; Kevin Halenda, MD, Cleveland, Ohio; Amanda D. Henderson, MD, Baltimore, Maryland; Andrew M. Hendrick, MD, Atlanta, Georgia; Joshua Hendrix, MD, Dalton, Georgia; Matthew B. Kaufman, MD, Portland, Oregon; Zachary A. Koretz, MD, MPH, Pittsburgh, Pennsylvania; Kevin E. Lai, MD, Indianapolis, Indiana; Kenneth C. Lao, MD, Temple, Texas; Yasha S. Modi, MD, New York, New York; Mark E. Robinson, MD, MPH, Columbia, South Carolina; Jamie B. Rosenberg, MD, New York, New York; Tahira Scholle, MD, Houston, Texas; Syed Mahmood Shah, MD, Pittsburgh, Pennsylvania; Ann Shue, MD, Sunnyvale, California; Jeong-Hyeon Sohn, MD, Shavano Park, Texas; Misha F. Syed, MD, League City, Texas; Parisa Taravati, MD, Seattle, Washington; Tanu O. Thomas, MD, El Paso, Texas; Sarah Van Tassel, MD, New York, New York; Matthew S. Wieder, MD, Scarsdale, New York; Jules A. Winokur, MD, Great Neck, New York



*European Board of Ophthalmology:* Lotte Welinder, MD, *Liaison*, Aalborg, Denmark; Susan P. Mollan, MBChB, Birmingham, United Kingdom

## Financial Disclosures

Academy staff members who contributed to the development of this product state that within the 24 months prior to their contributions to this CME activity and for the duration of development, they have had no financial interest in or other relationship with any entity that produces, markets, resells, or distributes health care goods or services consumed by or used in patients.

The authors and reviewers state that within the 24 months prior to their contributions to this CME activity and for the duration of development, they have had the following financial relationships:\*

Dr Bhatti: Novartis (L), Receptos (C)

Dr Danesh-Meyer: Alcon (C, L), Allergan (C), Glaukos (C)

Dr Fouraker: Addition Technology (C, L), AJL Ophthalmic SA (C, L), Alcon (C, L), OASIS Medical (C, L)

Dr Klapper: AdOM Advanced Optical Technologies (O)

Dr Lee: Horizon Therapeutics (C)

Dr Levin: Aerie Pharmaceuticals (C), Allergan (C), Eyevensys (C), Galimedix Therapeutics (C), Inotek Pharmaceuticals (C), Quark Pharmaceuticals (C), Regenera Pharma (C), Santen (C), Teva Pharmaceutical Industries (C)

Dr Modi: Alimera Sciences (C), Allergan (C), Genentech (C), Théa (C), ZEISS (C)

Dr Mollan: Allergan (L), Chugai (C, L), Heidelberg Engineering (L), Roche Diagnostics (C, L), Santen (L), Santhera Pharmaceuticals (L)

Dr Moss: Optina Diagnostics (C), Regenera Pharma (S), Verily (C)

Dr Robinson: Horizon Therapeutics (O)

Dr Shah: Allergan (C, S), Bausch + Lomb (L), D.O.R.C. Dutch Ophthalmic Research Center (International) B.V./Dutch Ophthalmic USA (S), Regeneron Pharmaceuticals (C, L)

Dr Tang: EMD Serono (L), Horizon Therapeutics (C, S), Immunovant (S), Novartis (S), Quark Pharmaceuticals (C, S), Regenera Pharma (S), Sanofi (L), ZEISS (L)

Dr Van Tassel: Aerie Pharmaceuticals (C), Allergan (C), Equinox (C), New World Medical (C)

All relevant financial relationships have been mitigated.

The other authors and reviewers state that within the 24 months prior to their contributions to this CME activity and for the duration of development, they have had no financial interest in or other relationship with any entity that produces, markets, resells, or distributes health care goods or services consumed by or used in patients.

\*C=consultant fee, paid advisory boards, or fees for attending a meeting; E=employed by or received a W2 from a commercial company; L=lecture fees or honoraria, travel fees or reimbursements when speaking at the invitation of a commercial company; O=equity ownership/stock options in publicly or privately traded firms, excluding mutual funds; P=patents and/or royalties for intellectual property; S=grant support or other financial support to the investigator from all sources, including research support from government agencies, foundations, device manufacturers, and/or pharmaceutical companies



## **Recent Past Faculty**

Valerie Biousse, MD

Swaraj Bose, MD

Julie Falardeau, MD

In addition, the Academy gratefully acknowledges the contributions of numerous past faculty and advisory committee members who have played an important role in the development of previous editions of the Basic and Clinical Science Course.

## **American Academy of Ophthalmology Staff**

Dale E. Fajardo, EdD, MBA, *Vice President, Education*

Beth Wilson, *Director, Continuing Professional Development*

Denise Evenson, *Director, Brand & Creative*

Susan Malloy, *Acquisitions and Development Manager*

Stephanie Tanaka, *Publications Manager*

Rayna Ungersma, *Manager, Curriculum Development*

Jasmine Chen, *Manager, E-Learning*

Sarah Page, *Online Education and Licensing Manager*

Lana Ip, *Senior Designer*

Amanda Fernandez, *Publications Editor*

Beth Collins, *Medical Editor*

Eric Gerdes, *Interactive Designer*

Kenny Guay, *Publications Specialist*

Debra Marchi, *Permissions Assistant*

American Academy of Ophthalmology  
655 Beach Street  
Box 7424  
San Francisco, CA 94120-7424

# Contents

Introduction to the BCSC . . . . .	xv
Introduction to Section 5 . . . . .	xvii
<b>Objectives . . . . .</b>	<b>1</b>
<b>1 Neuro-Ophthalmic Anatomy . . . . .</b>	<b>3</b>
Highlights . . . . .	3
Introduction . . . . .	3
Bony Anatomy . . . . .	4
Skull Base . . . . .	4
The Orbit . . . . .	5
Vascular Anatomy . . . . .	10
Arterial System . . . . .	10
Anterior Circulation . . . . .	12
Posterior Circulation . . . . .	18
Venous System . . . . .	20
Afferent Visual Pathways . . . . .	24
Retina . . . . .	24
Optic Nerve . . . . .	25
Optic Chiasm . . . . .	27
Optic Tract . . . . .	27
Cortex . . . . .	29
Efferent Visual System . . . . .	32
Cortical Input . . . . .	33
Subcortical Structures . . . . .	34
Brainstem . . . . .	35
Ocular Motor Cranial Nerves . . . . .	37
Extraocular Muscles . . . . .	45
Sensory and Facial Motor Anatomy . . . . .	45
Fifth Cranial Nerve . . . . .	45
Seventh Cranial Nerve . . . . .	49
Eyelids . . . . .	51
Ocular Autonomic Pathways . . . . .	52
Sympathetic Pathways . . . . .	52
Parasympathetic Pathways . . . . .	55
<b>2 Imaging in Neuro-Ophthalmology . . . . .</b>	<b>57</b>
Highlights . . . . .	57
Introduction . . . . .	57
Computed Tomography . . . . .	59

Magnetic Resonance Imaging . . . . .	59
Crucial Considerations in Neuroimaging. . . . .	66
When to Order . . . . .	69
What to Order . . . . .	69
How to Order. . . . .	70
How to Interpret . . . . .	71
Vascular and Other Imaging Modalities . . . . .	72
Catheter Angiography . . . . .	72
Magnetic Resonance Angiography and Magnetic Resonance Venography . . . . .	73
Computed Tomography Angiography and Computed Tomography Venography . . . . .	73
Metabolic and Functional Imaging Modalities. . . . .	75
Ultrasonography . . . . .	75
Optical Coherence Tomography . . . . .	76
Glossary of Select Neuroimaging Terminology . . . . .	84
<b>3 The Patient With Decreased Vision: Evaluation. . . . .</b>	<b>87</b>
Highlights . . . . .	87
History . . . . .	87
Unilateral Versus Bilateral Involvement . . . . .	87
Time Course of Vision Loss. . . . .	88
Associated Signs and Symptoms. . . . .	88
Cognitive Status. . . . .	88
Examination . . . . .	89
Visual Acuity Testing . . . . .	89
Color Vision Testing. . . . .	90
Pupillary Testing . . . . .	91
Fundus Examination . . . . .	94
Visual Field Evaluation. . . . .	96
Examination: Adjunct Testing . . . . .	102
Contrast Sensitivity Testing. . . . .	102
Photostress Recovery Testing . . . . .	104
Potential Acuity Meter Testing . . . . .	104
Fluorescein and Indocyanine Green Angiography . . . . .	104
Fundus Autofluorescence. . . . .	105
Optical Coherence Tomography. . . . .	107
Ultrasonography . . . . .	115
Electrophysiologic Testing . . . . .	117
<b>4 The Patient With Decreased Vision Due to Retinal,     Optic Nerve, and Chiasmal Diseases . . . . .</b>	<b>125</b>
Highlights . . . . .	125
Introduction . . . . .	125
Ocular Media Abnormalities . . . . .	126
Retinopathy . . . . .	126
AIBSE Syndrome, AZOOR, and MEWDS . . . . .	127
Cone Dystrophy . . . . .	128
Autoimmune Retinopathies and Paraneoplastic Retinopathies. . . . .	129

Optic Neuropathy . . . . .	131
Visual Field Patterns in Optic Neuropathy . . . . .	131
Causes of Optic Neuropathy . . . . .	132
Chiasmal Lesions . . . . .	180
Visual Field Loss Patterns . . . . .	181
Etiology of Chiasmal Disorders . . . . .	181
<b>5 The Patient With Visual Dysfunction</b>	
<b>Due to Retrochiasmal Disease . . . . .</b>	<b>187</b>
Highlights . . . . .	187
Introduction . . . . .	187
Retrochiasmal Lesions. . . . .	187
Optic Tract. . . . .	188
Lateral Geniculate Nucleus . . . . .	189
Optic Radiations of the Temporal Lobe. . . . .	190
Optic Radiations of the Parietal Lobe . . . . .	191
Optic Radiations of the Occipital Lobe . . . . .	191
Cortical Visual Impairment . . . . .	194
Vision Rehabilitation . . . . .	195
<b>6 The Patient With Transient Visual Loss . . . . .</b>	<b>197</b>
Highlights . . . . .	197
Clinical Characteristics . . . . .	197
Examination . . . . .	199
Monocular Transient Visual Loss . . . . .	200
Ocular Causes . . . . .	200
Orbital Causes . . . . .	200
Vascular Causes. . . . .	202
Binocular Transient Visual Loss. . . . .	211
Migraine. . . . .	211
Occipital Mass Lesions. . . . .	211
Occipital Ischemia. . . . .	211
Occipital Seizures . . . . .	212
<b>7 The Patient With Illusions, Hallucinations,</b>	
<b>and Disorders of Higher Cortical Function . . . . .</b>	<b>213</b>
Highlights . . . . .	213
Introduction . . . . .	213
Visual Distortion and Illusions . . . . .	215
Ocular Origin . . . . .	215
Optic Nerve Origin . . . . .	216
Cortical Origin . . . . .	216
Hallucinations . . . . .	216
Ocular Origin . . . . .	216
Optic Nerve Origin . . . . .	217
Cortical Origin . . . . .	217
Treatment of Illusions and Hallucinations . . . . .	220

Disorders of Higher Cortical Function. . . . .	220
Disorders of Recognition. . . . .	221
Disorders of Visual–Spatial Relationships. . . . .	223
Disorders of Awareness of Vision or Visual Deficit. . . . .	224

## **8 The Patient With Abnormal Ocular Motility**

<b>or Diplopia. . . . .</b>	<b>227</b>
Highlights . . . . .	227
Introduction . . . . .	227
History . . . . .	228
Physical Examination . . . . .	229
Monocular Diplopia . . . . .	231
Differentiating Paretic From Restrictive Causes of Diplopia. . . . .	231
Comitant and Incomitant Deviations . . . . .	232
Localization of Potential Lesions . . . . .	232
Supranuclear Causes of Abnormal Ocular Motility . . . . .	233
Nuclear Causes of Diplopia . . . . .	234
Internuclear Causes of Diplopia. . . . .	235
Internuclear Ophthalmoplegia . . . . .	235
One-and-a-Half Syndrome . . . . .	236
Ocular Motor Cranial Nerve Palsies . . . . .	237
Intra-axial Ocular Motor Cranial Nerve Palsies . . . . .	238
Third Cranial Nerve Palsy . . . . .	239
Fourth Cranial Nerve Palsy. . . . .	244
Sixth Cranial Nerve Palsy . . . . .	246
Recurrent Painful Ophthalmoplegic Neuropathy . . . . .	248
Paresis of More Than One Cranial Nerve . . . . .	248
Cavernous Sinus and Orbital Apex Involvement . . . . .	248
Myopathic, Restrictive, Orbital, Neuromuscular, and Other Causes of Diplopia . . . . .	252
Thyroid Eye Disease . . . . .	252
Orbital Myositis. . . . .	252
Posttraumatic Restriction . . . . .	252
Postsurgical Restriction . . . . .	253
Chronic Progressive External Ophthalmoplegia . . . . .	254
Neoplastic Involvement . . . . .	254
Brown Syndrome . . . . .	254
Heavy Eye Syndrome . . . . .	254
Sagging Eye Syndrome. . . . .	254
Ocular Neuromyotonia . . . . .	255
Neuromuscular Junction Causes of Diplopia . . . . .	255
Refractive Procedure–Induced Diplopia . . . . .	255
Foveal Displacement Syndrome . . . . .	255



<b>9</b>	<b>The Patient With Supranuclear Disorders of Ocular Motility . . . . .</b>	<b>257</b>
	Highlights . . . . .	257
	Fundamental Principles of Ocular Motor Control . . . . .	257
	Supranuclear Ocular Motor Systems: Function, Anatomy, Clinical Testing, and Disorders of Eye Movements . . . . .	259
	Ocular Fixation System . . . . .	259
	Vestibular-Ocular System (Vestibular-Ocular Reflex). . . . .	260
	Optokinetic System (Optokinetic Nystagmus). . . . .	267
	Saccadic System. . . . .	268
	Smooth-Pursuit System . . . . .	276
	Vergence System . . . . .	279
	Gaze Preference, Gaze Palsy, and Tonic Deviations. . . . .	282
<b>10</b>	<b>The Patient With Nystagmus or Spontaneous Eye Movement Disorders . . . . .</b>	<b>287</b>
	Highlights . . . . .	287
	Introduction and Terminology . . . . .	287
	Assessment of Eye Movement Abnormalities . . . . .	288
	Early-Onset (Childhood) Nystagmus . . . . .	289
	Infantile Nystagmus Syndrome (Congenital Nystagmus) . . . . .	289
	Fusional Maldevelopment Nystagmus Syndrome (Latent Nystagmus) . . . . .	291
	Heimann-Bielschowsky Phenomenon . . . . .	293
	Spasmus Nutans Syndrome . . . . .	294
	Gaze-Evoked Nystagmus. . . . .	295
	Rebound Nystagmus. . . . .	296
	Vestibular Nystagmus . . . . .	296
	Peripheral Vestibular Nystagmus . . . . .	296
	Central Vestibular Nystagmus. . . . .	299
	HINTS Test . . . . .	302
	Acquired Pendular Nystagmus . . . . .	303
	Oculopalatal Myoclonus or Tremor . . . . .	303
	See-Saw Nystagmus . . . . .	304
	Dissociated Nystagmus With Internuclear Ophthalmoplegia . . . . .	304
	Saccadic Intrusions . . . . .	305
	Saccadic Intrusions With Normal Intersaccadic Intervals . . . . .	305
	Saccadic Intrusions Without Normal Intersaccadic Intervals . . . . .	306
	Voluntary Flutter (Voluntary “Nystagmus”). . . . .	307
	Additional Eye Movement Disorders . . . . .	307
	Convergence-Retraction Nystagmus . . . . .	307
	Superior Oblique Myokymia . . . . .	308
	Oculomasticatory Myorhythmia . . . . .	309
<b>11</b>	<b>The Patient With Pupillary Abnormalities. . . . .</b>	<b>311</b>
	Highlights . . . . .	311
	Introduction . . . . .	311

History . . . . .	311
Pupillary Examination . . . . .	312
Factors Affecting Pupil Size . . . . .	313
Pupil Irregularity . . . . .	313
Anisocoria . . . . .	314
Normal Pupillary Response to Light . . . . .	314
Anisocoria Equal in Dim and Bright Light . . . . .	314
Anisocoria Greater in Dim Light . . . . .	316
Anisocoria Greater in Bright Light. . . . .	322
Disorders of Pupillary Reactivity: Light–Near Dissociation . . . . .	325
Afferent Visual Pathway . . . . .	325
Midbrain. . . . .	325
Aberrant Regeneration of Cranial Nerve III. . . . .	326
Other Pupillary Disorders . . . . .	326
Benign Episodic Unilateral Mydriasis . . . . .	326
<b>12 The Patient With Eyelid or Facial Abnormalities . . . . .</b>	<b>327</b>
Highlights . . . . .	327
Introduction . . . . .	327
Examination Techniques. . . . .	328
Ptosis . . . . .	331
Congenital Ptosis . . . . .	331
Acquired Ptosis . . . . .	332
Pseudoptosis . . . . .	333
Apraxia of Eyelid Opening . . . . .	334
Eyelid Retraction . . . . .	334
Abnormalities of Facial Movement . . . . .	335
Seventh Cranial Nerve Disorders . . . . .	337
Disorders of Underactivity of the Seventh Cranial Nerve . . . . .	337
Disorders of Overactivity of the Seventh Cranial Nerve. . . . .	342
<b>13 The Patient With Head, Ocular, or Facial Pain . . . . .</b>	<b>347</b>
Highlights . . . . .	347
Head Pain . . . . .	347
Headache Associated With Systemic Conditions. . . . .	348
Migraine and Tension-type Headache . . . . .	350
Trigeminal Autonomic Cephalgias and Hemicrania Continua . . . . .	357
Idiopathic Stabbing Headache. . . . .	358
Inherited Encephalopathies Resembling Migraine . . . . .	358
Ocular and Orbital Pain . . . . .	359
Trochlear Headache and Trochleitis . . . . .	360
Photophobia . . . . .	361
Facial Pain . . . . .	361
Herpes Zoster Ophthalmicus . . . . .	361
Internal Carotid Artery Dissection . . . . .	362
Giant Cell Arteritis . . . . .	362
Neoplastic Processes. . . . .	362

Trigeminal Neuralgia . . . . .	362
Occipital Neuralgia . . . . .	363

## **14 The Patient With Functional Neurological Symptom (Conversion) and Related Disorders . . . . . 365**

Highlights . . . . .	365
Introduction . . . . .	366
Clinical Profile . . . . .	368
Examination Techniques. . . . .	369
Afferent Visual Pathway . . . . .	369
Ocular Motility and Alignment . . . . .	377
Pupils and Accommodation . . . . .	378
Eyelid Position and Function . . . . .	379
Management of the Patient With Functional Neurological Symptom and Related Disorders . . . . .	379
Functional Neurological Symptom (Conversion) Disorder . . . . .	379
Somatic Symptom Disorder. . . . .	380

## **15 The Patient With a Systemic Disease . . . . . 381**

Highlights . . . . .	381
Introduction . . . . .	381
Immunologic Disorders . . . . .	381
Giant Cell Arteritis . . . . .	382
Multiple Sclerosis . . . . .	384
Neuromyelitis Optica Spectrum Disorder and Myelin Oligodendrocyte Glycoprotein Immunoglobulin G–Associated Disorder. . . . .	389
Myasthenia Gravis . . . . .	394
Thyroid Eye Disease . . . . .	397
Sarcoidosis . . . . .	397
Inherited Disorders With Neuro-Ophthalmic Signs . . . . .	398
Myopathies. . . . .	398
Neurocutaneous Syndromes . . . . .	400
Selected Neuro-Ophthalmic Disorders Associated With Pregnancy . . . . .	403
Posterior Reversible Encephalopathy Syndrome . . . . .	405
Lymphocytic Hypophysitis . . . . .	405
Cerebrovascular Disorders . . . . .	406
Transient Visual Loss . . . . .	406
Vertebrobasilar System Disease . . . . .	406
Cerebral Aneurysms. . . . .	409
Arterial Dissection . . . . .	412
Arteriovenous Malformations. . . . .	413
Cerebral Venous Thrombosis . . . . .	415
Reversible Cerebral Vasoconstriction Syndrome . . . . .	417
Neuro-Ophthalmic Manifestations of Infectious Diseases . . . . .	419
Human Immunodeficiency Virus Infection . . . . .	419
Herpesvirus . . . . .	421

<i>Mycobacterium</i> . . . . .	421
Syphilis . . . . .	422
Progressive Multifocal Leukoencephalopathy . . . . .	422
Toxoplasmosis . . . . .	422
Lyme Disease . . . . .	423
Fungal Infections . . . . .	424
Prion Diseases . . . . .	428
Radiation Therapy . . . . .	428
 Additional Materials and Resources . . . . .	 431
Requesting Continuing Medical Education Credit . . . . .	433
Study Questions . . . . .	435
Answers . . . . .	445
Index . . . . .	455

# Introduction to the BCSC

The Basic and Clinical Science Course (BCSC) is designed to meet the needs of residents and practitioners for a comprehensive yet concise curriculum of the field of ophthalmology. The BCSC has developed from its original brief outline format, which relied heavily on outside readings, to a more convenient and educationally useful self-contained text. The Academy updates and revises the course annually, with the goals of integrating the basic science and clinical practice of ophthalmology and of keeping ophthalmologists current with new developments in the various subspecialties.

The BCSC incorporates the effort and expertise of more than 100 ophthalmologists, organized into 13 Section faculties, working with Academy editorial staff. In addition, the course continues to benefit from many lasting contributions made by the faculties of previous editions. Members of the Academy Practicing Ophthalmologists Advisory Committee for Education, Committee on Aging, and Vision Rehabilitation Committee review every volume before major revisions, as does a group of select residents and fellows. Members of the European Board of Ophthalmology, organized into Section faculties, also review volumes before major revisions, focusing primarily on differences between American and European ophthalmology practice.

## Organization of the Course

The Basic and Clinical Science Course comprises 13 volumes, incorporating fundamental ophthalmic knowledge, subspecialty areas, and special topics:

- 1 Update on General Medicine
- 2 Fundamentals and Principles of Ophthalmology
- 3 Clinical Optics and Vision Rehabilitation
- 4 Ophthalmic Pathology and Intraocular Tumors
- 5 Neuro-Ophthalmology
- 6 Pediatric Ophthalmology and Strabismus
- 7 Oculofacial Plastic and Orbital Surgery
- 8 External Disease and Cornea
- 9 Uveitis and Ocular Inflammation
- 10 Glaucoma
- 11 Lens and Cataract
- 12 Retina and Vitreous
- 13 Refractive Surgery

## References

Readers who wish to explore specific topics in greater detail may consult the references cited within each chapter and listed in the Additional Materials and Resources section at the back of the book. These references are intended to be selective rather than exhaustive,



chosen by the BCSC faculty as being important, current, and readily available to residents and practitioners.

## Multimedia

This edition of Section 5, *Neuro-Ophthalmology*, includes videos related to topics covered in the book and interactive content, or “activities,” developed by members of the BCSC faculty. The videos and activities are available to readers of the print and electronic versions of Section 5 ([www.aao.org/bcscvideo\\_section05](http://www.aao.org/bcscvideo_section05) and [www.aao.org/bcscactivity\\_section05](http://www.aao.org/bcscactivity_section05)). Mobile device users can scan the QR codes below (a QR-code reader may need to be installed on the device) to access the videos and activities.



Videos



Activities

## Self-Assessment and CME Credit

Each volume of the BCSC is designed as an independent study activity for ophthalmology residents and practitioners. The learning objectives for this volume are given on page 1. The text, illustrations, and references provide the information necessary to achieve the objectives; the study questions allow readers to test their understanding of the material and their mastery of the objectives. Physicians who wish to claim CME credit for this educational activity may do so by following the instructions given at the end of the book.\*

## Conclusion

The Basic and Clinical Science Course has expanded greatly over the years, with the addition of much new text, numerous illustrations, and video content. Recent editions have sought to place greater emphasis on clinical applicability while maintaining a solid foundation in basic science. As with any educational program, it reflects the experience of its authors. As its faculties change and medicine progresses, new viewpoints emerge on controversial subjects and techniques. Not all alternate approaches can be included in this series; as with any educational endeavor, the learner should seek additional sources, including Academy Preferred Practice Pattern Guidelines.

The BCSC faculty and staff continually strive to improve the educational usefulness of the course; you, the reader, can contribute to this ongoing process. If you have any suggestions or questions about the series, please do not hesitate to contact the faculty or the editors.

The authors, editors, and reviewers hope that your study of the BCSC will be of lasting value and that each Section will serve as a practical resource for quality patient care.

\*There is no formal American Board of Ophthalmology (ABO) approval process for self-assessment activities. Any CME activity that qualifies for ABO Continuing Certification credit may also be counted as “self-assessment” as long as it provides a mechanism for individual learners to review their own performance, knowledge base, or skill set in a defined area of practice. For instance, grand rounds, medical conferences, or journal activities for CME credit that involve a form of individualized self-assessment may count as a self-assessment activity.

# Introduction to Section 5

Since its inception, Section 5, *Neuro-Ophthalmology*, has continually evolved. In 2001, the text was reorganized to take a symptom-driven approach, focusing on how to approach patients with neuro-ophthalmic concerns. Accordingly, the emphasis is on the examination of the patient—both basic and extended—and the appropriate use of adjunctive studies to determine the status of the patient’s visual system as a whole. With this edition, we hope the reader will find the content to be improved in terms of both the approach to the diagnosis and to the management of a patient with neuro-ophthalmic disease.

As part of every major revision, outdated material is eliminated, and text, tables, illustrative material, and references are updated. For this major revision, several new features were added. Each chapter begins with a list of highlights to pique the reader’s interest. “Clinical pearl” boxes appear throughout the book, presenting information that can be quickly applied to clinical practice. Sidebars emphasize important concepts or ideas. Also, a significant number of videos and animated figures were added to enhance the educational value of the book.

The titles of several chapters were revised to reflect changes to the content. The title of Chapter 2 changed from “Neuroimaging in Neuro-Ophthalmology” to the broader “Imaging in Neuro-Ophthalmology,” as an entire section of the chapter is now dedicated to optical coherence tomography (OCT), specifically, how to interpret OCT results. This imaging technique has become an important part of the evaluation of patients with neuro-ophthalmic disorders.

A particularly significant modification for this edition is the division of Chapter 4, previously titled “The Patient With Decreased Vision: Classification and Management,” into 2 chapters, titled “The Patient With Decreased Vision Due to Retinal, Optic Nerve, and Chiasmal Diseases” and “The Patient With Visual Dysfunction Due to Retrochiasmal Disease.” This was done for 2 main reasons; the first was to simplify the organization. Pre-chiasmal lesions cause monocular visual loss, whereas chiasmal and post-chiasmal lesions typically cause binocular visual loss (with the rare exception of the temporal crescent syndrome). Further, dividing vision loss on the basis of the location of the cause is a practical clinical approach. The second reason was to make the content more manageable for the reader, as Chapter 4 in previous editions presented a tremendous amount of information.

Chapter 14, formerly titled “The Patient With Nonorganic Ophthalmic Disorders,” has been substantially updated to align with evolving diagnostic categorization and treatment approaches used by psychiatrists and neurologists for patients with visual symptoms and signs that are incompatible with recognized neurologic or ophthalmic disease *and* with distress or impairment related to these, as well as for patients with excessive thoughts, feelings, or behaviors related to either explained or unexplained visual symptoms. The updates—reflected by the new title, “The Patient With Functional Neurological Symptom (Conversion) and Related Disorders”—include an overview of the most recent diagnostic

categorization of these disorders with a focus on the role of the ophthalmologist in identifying them and supporting care of the patient.

Links to the NOVEL (Neuro-Ophthalmology Virtual Education Library) website of NANOS (North American Neuro-Ophthalmology Society) are included in several chapters throughout the book. This is a web-accessible collection of open-access, copyrighted resources such as images, videos, lectures, and other digital media. After accessing the collections, the user can navigate through to the relevant resources. See the NOVEL website, <https://novel.utah.edu>, for more information.

This book is not meant to be an all-encompassing or comprehensive treatise; thus, we have included a list of some of the more useful secondary sources of information, as well as references with primary source material. As with all previous major revisions, we have endeavored to make this book more readable as well as clinically relevant and hope that it will help instill confidence in ophthalmologists to approach patients with common clinical neuro-ophthalmic problems.

Finally, we acknowledge all the former Section 5 Committee members for their work, upon which this major revision has been built. Further, we believe it is safe to say that not only is this book a wonderful tool for teaching the next generation of great ophthalmologists, but by contributing to it, we have become better clinicians. The Chair also thanks the current Committee members for their expertise and dedication.

# Objectives

---

Upon completion of BCSC Section 5, *Neuro-Ophthalmology*, the reader should be able to

- explain a symptom-driven approach to the assessment of patients with common neuro-ophthalmic clinical manifestations and state an appropriate differential diagnosis
  - select the most appropriate diagnostic tests and imaging studies, based on clinical signs and symptoms
  - develop a management algorithm for neuro-ophthalmic disorders
  - identify neuro-ophthalmic emergencies
  - describe a plan for the immediate management of patients with neuro-ophthalmic emergencies
  - identify the anatomical structures that are relevant to neuro-ophthalmic disorders (including the skull base, orbit, brain, vascular system, and cranial nerves) in order to localize lesions
  - describe eye movement disorders and their anatomical relationship to the ocular motor system
  - describe the management of diplopia
  - state the various clinical manifestations and underlying causes of illusions, hallucinations, and cortical visual impairment
  - describe pupil, eyelid position, and ocular motor pathology in relation to specific disease processes
  - explain functional neurological symptom (conversion) disorder, factitious disorder, and malingering, and list the various clinical tests that are used to evaluate functional vision loss
  - describe the neuro-ophthalmic effects of the most common neurologic and systemic disorders affecting the visual and ocular motor systems
-





## CHAPTER 1

# Neuro-Ophthalmic Anatomy



This chapter includes a related activity. Go to [www.aao.org/bcscactivity\\_section05](http://www.aao.org/bcscactivity_section05) or scan the QR code in the text to access this content.

### Highlights

---

- The optic canal is located within the lesser wing of the sphenoid bone and transmits the optic nerve, ophthalmic artery, and some oculosympathetic fibers.
- The ophthalmic artery gives off the central retinal artery, which enters the optic nerve 10–12 mm posterior to the globe.
- The optic chiasm is anterior to the hypothalamus and the anterior third ventricle and is usually approximately 10 mm above the sella.
- Cranial nerve (CN) IV is the only CN that exits on the dorsal surface of the brainstem and has the longest unprotected intracranial course (likely responsible for its frequent involvement in closed-head trauma).
- A central or upper motor neuron CN VII palsy causes contralateral lower facial weakness, whereas a peripheral or lower motor neuron CN VII palsy causes ipsilateral upper and lower facial weakness.

### Introduction

---

Although an adequate understanding of physiology—and increasingly molecular genetics—is important in managing diseases and potential treatments, anatomy remains the foundation of medical practice in general and of surgical subspecialties in particular. Nowhere is this more apparent than in ophthalmology, given the complex structure and components of the human eye. This chapter outlines the intracranial pathways subserving the afferent and efferent visual pathways, the sensory and motor anatomy of the face, and the autonomic nervous system of the eye and visual system. The anatomy of the globe and adnexal structures is covered in more detail in BCSC Section 2, *Fundamentals and Principles of Ophthalmology*; Section 7, *Oculofacial Plastic and Orbital Surgery*; and Section 8, *External Disease and Cornea*.

## Bony Anatomy

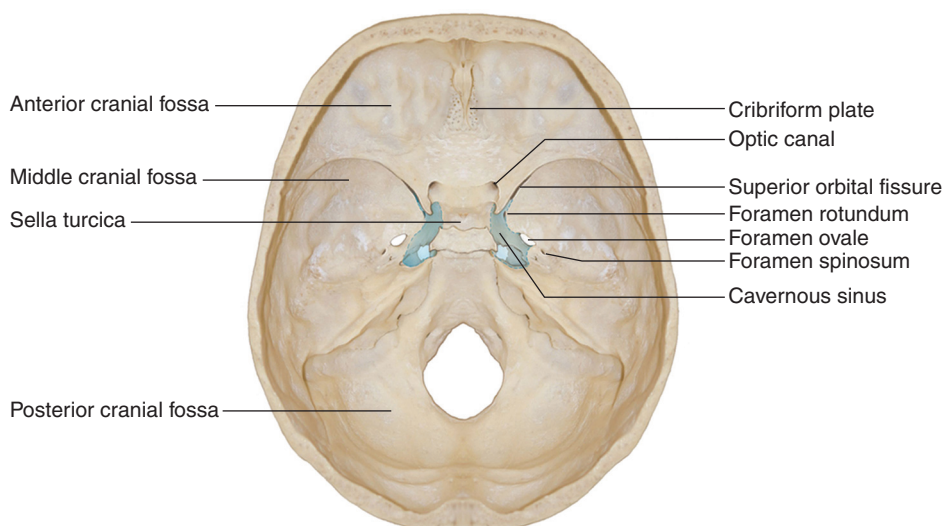
### Skull Base

The skull base has an intimate relationship with the visual system. It is connected to the lower facial skeleton by 3 sets of pillars formed by the *maxillary* and *zygomatic bones* anteriorly and the *pterygoid process* of the sphenoid bone posteriorly. Superiorly, the vault of the skull is made up of the following:

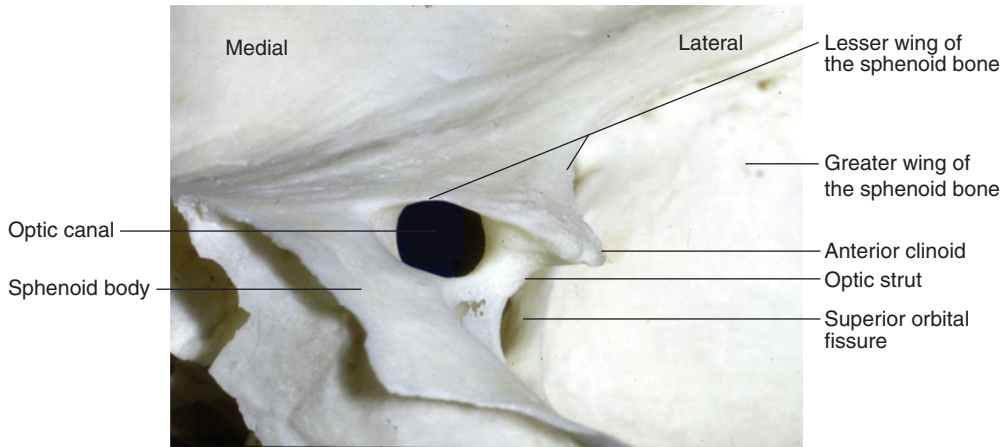
- the parietal bones, which meet at the *sagittal suture*
- the frontal bone, which adjoins the parietal bones at the *coronal suture*
- the occipital bone, which meets the parietal bones at the *lambdoid suture*

See BCSC Section 6, *Pediatric Ophthalmology and Strabismus*, for more on these skull sutures.

In the skull base, located posterior and medial to the 2 orbits, is the *sella turcica*, a depression within the body of the *sphenoid bone* (Fig 1-1). The lesser wing of the sphenoid bone is pierced by the *optic canal*, which allows the optic nerves to exit from the orbits. Within the canal, the optic nerve is accompanied by the ophthalmic artery (OphA) inferiorly and is separated from the superior orbital fissure by the optic strut (the posterior root of the lesser wing of the sphenoid), which terminates superiorly as the anterior clinoid (Fig 1-2). As a result, anterior clinoid meningiomas may cause compressive optic neuropathy. Medially, the optic nerve is separated from the sphenoid sinus by bone that may be thin or dehiscant.



**Figure 1-1** Bony anatomy of the skull base. The cavernous sinuses are located on each side of the sella turcica. Important openings within the skull base include the cribriform plate (transmits branches of the olfactory nerve, also known as cranial nerve [CN] I), optic canal (transmits the optic nerve, CN II), foramen ovale (transmits the mandibular division [CN V<sub>3</sub>] of the trigeminal nerve, CN V), foramen rotundum (transmits the maxillary division [CN V<sub>2</sub>] of CN V), superior orbital fissure (transmits CNs III, IV, VI, and V [ophthalmic division, CN V<sub>1</sub>]), and foramen spinosum (transmits the middle meningeal artery, a branch of the external carotid artery). (Courtesy of Albert L. Rhoton Jr, MD.)



**Figure 1-2** Intracranial view of the left optic canal. Within the lesser wing of the sphenoid bone is the optic foramen, which leads to the optic canal. The optic strut separates the optic canal from the superior orbital fissure. (Courtesy of Albert L. Rhoton Jr, MD.)

The gap between the lesser and greater wings of the sphenoid bone represents the *superior orbital fissure*, which transmits the following neurovascular structures:

- oculomotor nerve (CN III)
- trochlear nerve (CN IV)
- ophthalmic division of the sensory trigeminal nerve (CN V<sub>1</sub>)
- abducens nerve (CN VI)
- oculosympathetic fibers
- superior ophthalmic vein

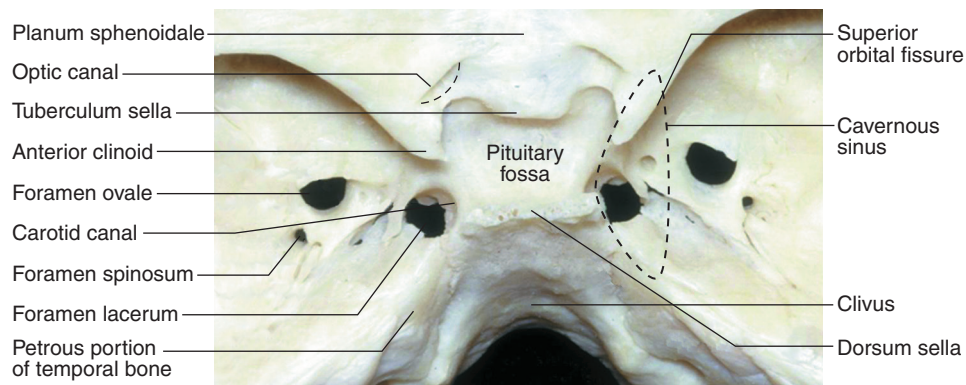
The parasellar region is connected laterally to the *petrous* and *temporal bones* and inferiorly to the *clivus*, extending to the *foramen magnum* and the exit of the spinal cord. The posterior skull base is enclosed by the *occipital bones* (Fig 1-3).

## The Orbit

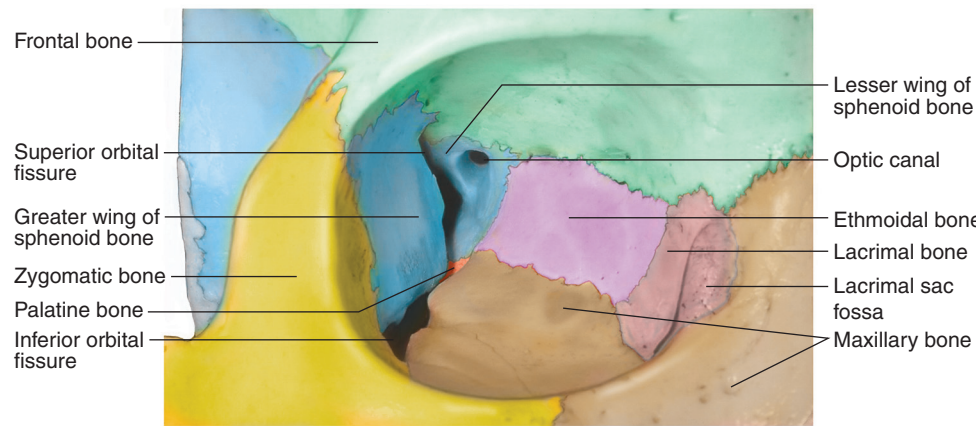
The anterior aspect of the skull includes the orbits, which connect posteriorly to the parasellar region. Approximately 45 mm wide and 35 mm in maximal height, the orbit has a total volume of about 30 cm<sup>3</sup>. Its medial walls are about 40 mm from the rim to the optic canal. Although these walls are roughly parallel, the lateral walls form an almost 90° angle.

The orbit is composed of 7 craniofacial bones (Fig 1-4, Table 1-1):

- maxillary
- zygomatic
- frontal
- lacrimal
- sphenoid
- palatine
- ethmoid



**Figure 1-3** Parasellar bony anatomy demonstrates the relationship of the pituitary fossa to the cavernous sinus, including the foramina of the skull base. The foramen lacerum is filled with cartilage and contains the artery of the pterygoid canal, the nerve of the pterygoid canal, and the venous drainage structures. The carotid artery enters the skull base through the carotid canal. (Courtesy of Albert L. Rhoton Jr, MD.)



**Figure 1-4** Anatomy of the orbit. Bony anatomy of the right orbital apex. The optic canal transmits the optic nerve, ophthalmic artery, and some oculosympathetic fibers. The superior orbital fissure, between the greater and lesser wings of the sphenoid bone, transmits CNs III, IV, and VI; the ophthalmic division of CN V (CN V<sub>1</sub>); the oculosympathetics; and the superior ophthalmic vein. (Illustration by Dave Peace.)

**Table 1-1 Bones of the Orbit**

Orbital Roof	Lateral Wall	Orbital Floor	Medial Wall
Frontal	Zygomatic	Zygomatic	Maxillary
Lesser wing of sphenoid	Greater wing of sphenoid	Maxillary	Lacrimal
		Palatine	Ethmoid
			Lesser wing of sphenoid

The superior orbital rim is made up of the *frontal bone*, which connects to the *zygomatic bone* laterally at the *frontozygomatic suture*. The inferior orbital rim is made up of the zygomatic bone inferolaterally and the maxillary bone inferonasally, which meet at the *zygomaticomaxillary suture*. Medially, the orbital rim consists of the *maxillary* and *lacrimal bones*, which join the frontal bone superiorly. Three additional bones contribute to the orbit: the *ethmoid bone* medially, the *palatine bone* inferiorly in the posterior orbit, and the *sphenoid bone* laterally and superiorly in the orbital apex (Activity 1-1).



#### ACTIVITY 1-1 Bony anatomy of the orbit.

Developed by Zoë R. Williams, MD. Illustrations by Dave Peace.



At the orbital apex, the annulus of Zinn gives rise to the 4 rectus muscles. CNs II and III, the nasociliary nerve of CN V, and CN VI pass through the annulus of Zinn. In contrast, CN IV and the frontal and lacrimal nerves of CN V, as well as the superior ophthalmic vein, pass through the superior orbital fissure outside the annulus of Zinn (Fig 1-5).

#### CLINICAL PEARL

Because the superior oblique muscle is innervated by CN IV, which bypasses the annulus of Zinn, it is often not paralyzed—or is the last extraocular muscle to be paralyzed—by a retrobulbar block.

The orbit is surrounded by several important structures, including 4 *paranasal sinuses* (Fig 1-6):

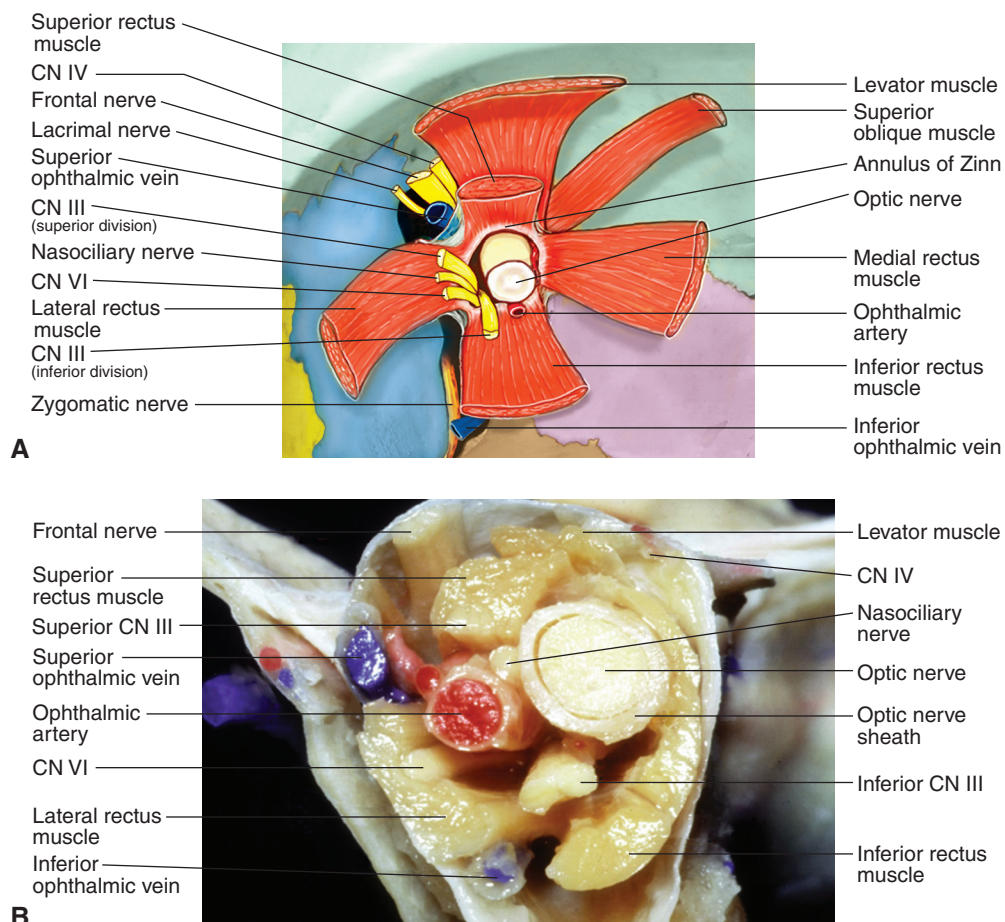
- the *maxillary sinus*, which is adjacent to the orbital floor
- the *ethmoid sinus*, which is adjacent to the orbital medial wall
- the *sphenoid sinus*, also adjacent to the orbital medial wall
- the *frontal sinus*, with variable relationship to the anterior orbital roof

The *sphenoid sinus* forms the medial wall of the optic canal (Fig 1-7). In approximately 4% of patients, the bone may be incomplete, leaving only mucosa separating the sinus from the optic nerve. Surgery within the sphenoid sinus can potentially damage the optic nerve. In patients with pituitary or suprasellar lesions, use of the sphenoid sinus for an endoscopic surgical approach facilitates decompression of the optic chiasm. However, decompression can also be approached via craniotomy depending on the extent and site of pathology.

Other major structures around the orbit are the *anterior cranial fossa* superiorly (containing the frontal lobe) and the *temporal fossa* laterally (containing the temporalis muscle). The roof of the *ethmoidal complex*, delineated by the *frontoethmoidal suture* (top of the *ethmoid bone*, or *lamina papyracea*), marks the inferior boundary of the anterior



## 8 • Neuro-Ophthalmology

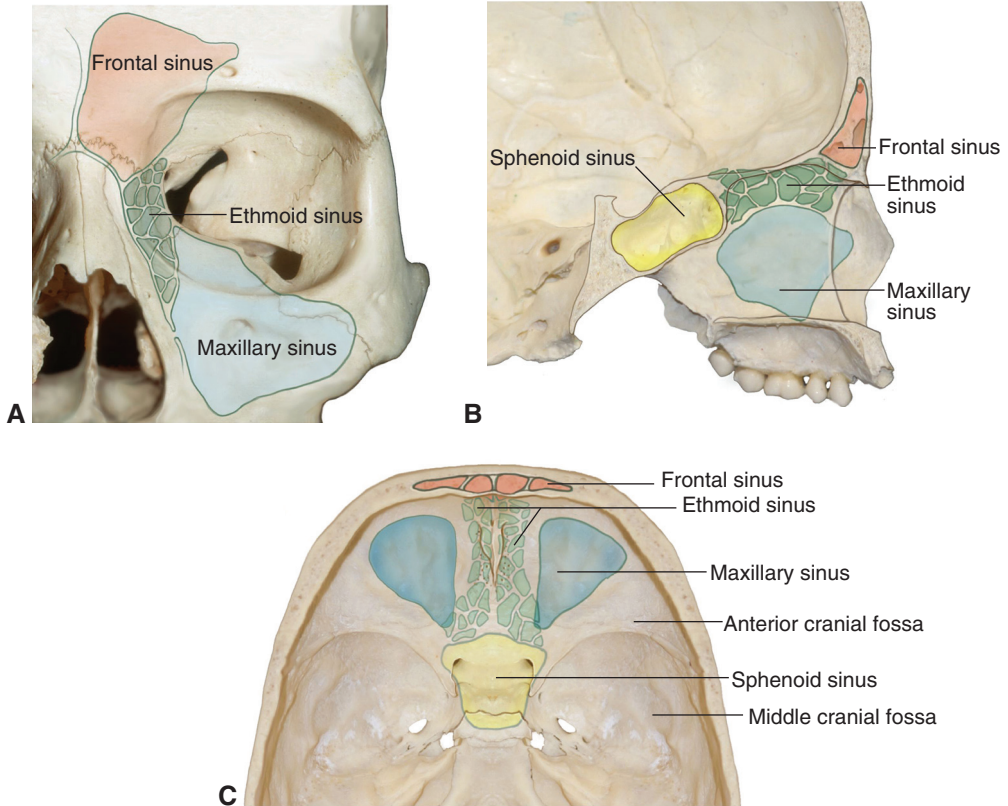


**Figure 1-5** Anatomy of the orbital apex. **A**, The 4 rectus muscles arise from the annulus of Zinn. CNs II, III (superior and inferior branches), and VI and the nasociliary nerve all course through the annulus of Zinn. CN IV, the frontal and lacrimal nerves, and the ophthalmic veins are located outside the annulus. **B**, Anatomical dissection just anterior to the superior orbital fissure. (Part A illustration by Dave Peace; part B courtesy of Albert L. Rhoton Jr, MD.)

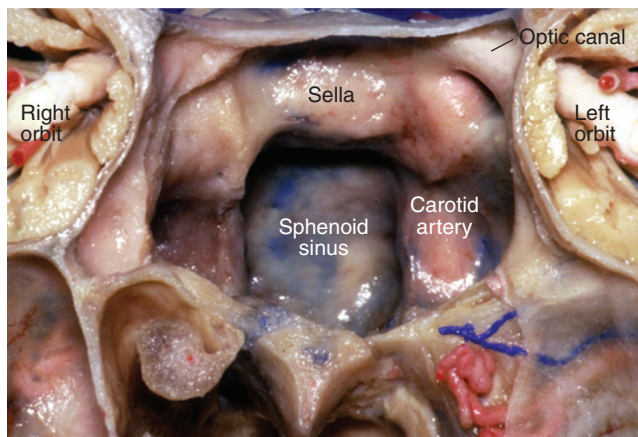
cranial fossa. Surgical intervention above the frontoethmoidal suture, as occurs during an endoscopic sinus procedure, can result in inadvertent entry into the anterior cranial fossa or a cerebrospinal fluid (CSF) leak.

Under the apex of the orbit, the *pterygomaxillary area* contains the sphenopalatine ganglion and the internal maxillary artery. The pterygomaxillary area communicates

- anteriorly through the *infraorbital canal* to the cheek and lower eyelid
- posteriorly through the *foramen rotundum* and *vidian canal* to the *middle cranial fossa*
- superiorly through the *inferior orbital fissure* to the orbit



**Figure 1-6** Anatomical relationship of the 4 paranasal sinuses to the orbit. **A**, Coronal view. **B**, Sagittal view. **C**, Axial view. (Illustrations by Dave Peace.)



**Figure 1-7** Coronal section, anterior view into the sphenoid sinus demonstrating the relationship of the internal carotid artery and optic nerve within the lateral wall of the sinus. (Courtesy of Albert L. Rhoton Jr, MD.)

### Canals and fissures

The orbit communicates with the surrounding areas through several bony canals and fissures. Posteriorly, the orbit is contiguous with the *cavernous sinus* through the superior orbital fissure (see Fig 1-3). The medial wall of the orbit continues as the lateral wall of the sphenoid bone, marking the medial extent of the cavernous sinus. When sharp objects enter the medial orbit, they are directed through the superior orbital fissure, where they can lacerate the carotid artery. Within the cavernous sinus, iatrogenic or traumatic damage to the internal carotid artery (ICA) may produce a direct, high-flow carotid-cavernous fistula (see Chapter 8).

The orbit is connected superiorly and posteriorly to the anterior cranial fossa by way of the *optic canal* (see Fig 1-2), which transmits the optic nerve, OphA, and some of the oculo-sympathetic fibers (terminal branches of the carotid plexus). Inferiorly at the apex, the orbit is connected to the *pterygopalatine fossa*—and thus the temporal and inferotemporal regions—through the inferior orbital fissure. This fissure, formed by the greater wing of the sphenoid bone and the maxillary, zygomatic, and palatine bones, carries the following structures:

- maxillary branch of CN V (CN V<sub>2</sub>)
- infraorbital vessels
- inferior ophthalmic vein
- branches from the pterygopalatine ganglion
- parasympathetic fibers that innervate the lacrimal gland
- collateral meningeal arteries that connect the external and internal carotid circulation

Anteriorly, the orbit connects to the *inferior meatus* of the nose (beneath the inferior turbinate) through the *nasolacrimal duct*, which carries tears into the nasal cavity. Other canals surrounding the orbit include the *anterior* and *posterior ethmoidal foramina*, which carry blood vessels that connect the internal carotid circulation (ie, the OphA) to the external carotid circulation (ie, the terminal branches of the ethmoidal arteries). Additional *supraorbital* and *zygomaticotemporal foramina* carry blood vessels between the orbit and corresponding vessels of the forehead and temple.

Rhoton AL, Natori Y. *The Orbit and Sellar Region: Microsurgical Anatomy and Operative Approaches*. Thieme; 1996.

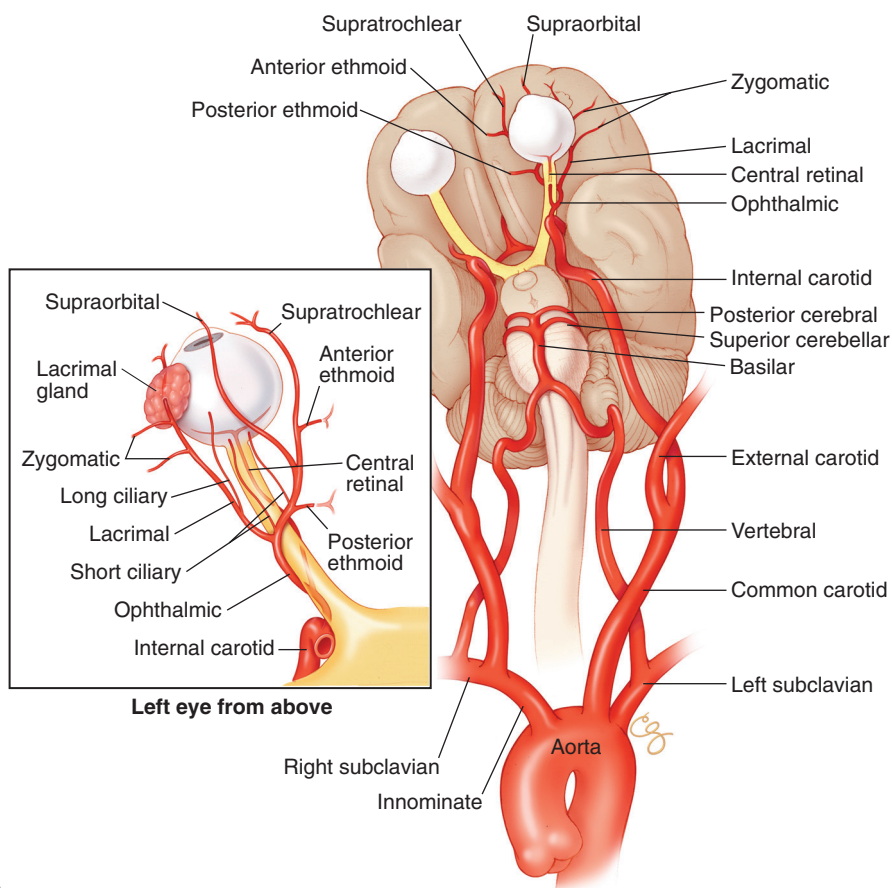
## Vascular Anatomy

---

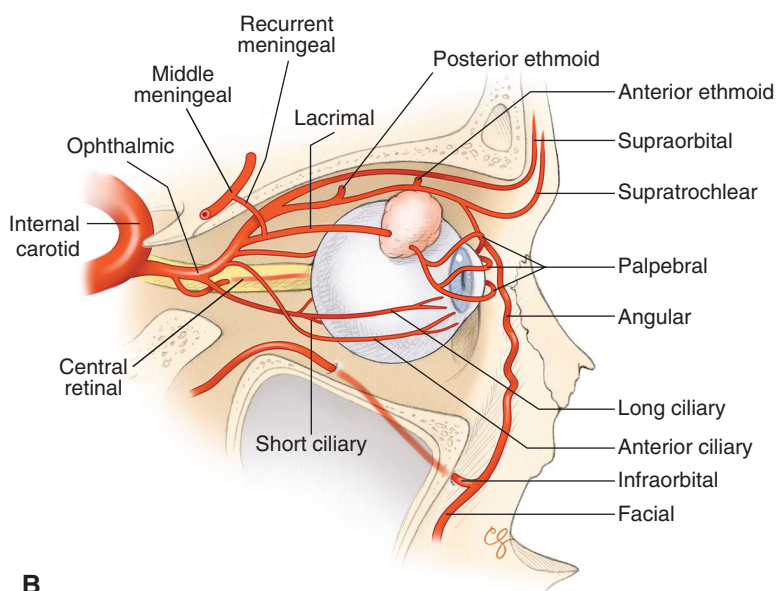
### Arterial System

Ischemia is a common pathophysiologic cause of visual dysfunction, including double vision and loss of vision. Knowledge of the vascular anatomy of the eye is crucial in understanding the potential for and managing damage secondary to ischemia. The *common carotid arteries*, arising from the *innominate artery* on the right and directly from the aorta on the left, supply most of the blood to the skull and its contents. The remainder of the blood supply to the skull comes from the 2 *vertebral arteries* (VAs), which enter through the foramen magnum after traversing foramina in the cervical vertebral segments. Once the VAs penetrate the dura, they join near the pontomedullary junction to form the *basilar artery* (BA), which ascends along the anterior surface of the pons and terminates in the 2 *posterior cerebral arteries* (PCAs) at the level of the midbrain (Fig 1-8).





**A**

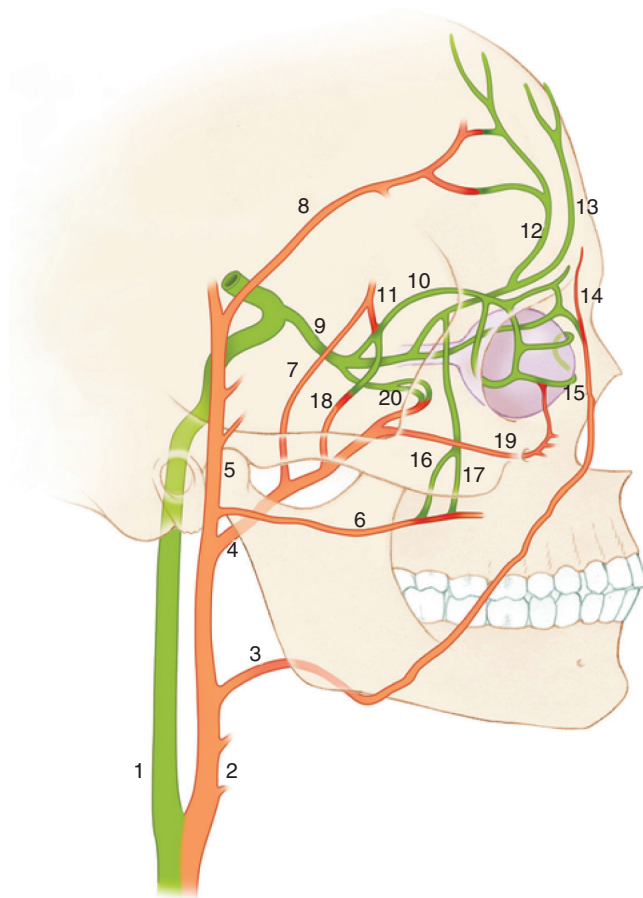


**B**

**Figure 1-8** Arterial map of the orbit and ocular adnexa. **A**, Arterial supply of the orbit and ocular adnexa originating from the aortic arch. **B**, Sagittal view of the arterial supply to the orbit and globe. (Illustrations by Christine Gralapp.)

## Anterior Circulation

The common carotid artery divides into external and internal branches at the angle of the jaw (Fig 1-9). The *external carotid artery (ECA)* supplies blood to the face through its major branches of the *facial artery*. The scalp is supplied via branches of the *superficial temporal artery* anteriorly and the *occipital artery* posteriorly. The paranasal sinuses receive their blood supply from branches of the *maxillary artery* (sphenopalatine and infraorbital), which terminates in the pterygopalatine fossa. The coverings of the brain are supplied by branches of the *middle meningeal artery*—a major branch of the maxillary artery—which enters the middle cranial fossa through the foramen spinosum, lateral to the foramen ovale. Branches of the middle meningeal artery supply the parasellar area, including the lateral wall of the



**Figure 1-9** Internal carotid artery (*green*) and external carotid artery (*orange*) collateral anatomy. 1, internal carotid; 2, external carotid; 3, facial; 4, maxillary; 5, superficial temporal; 6, transverse facial; 7, middle meningeal; 8, frontal branch of superficial temporal; 9, ophthalmic; 10, lacrimal; 11, recurrent meningeal; 12, supraorbital; 13, supratrochlear; 14, angular; 15, palpebral; 16, zygomaticotemporal; 17, zygomaticofacial; 18, deep temporal; 19, infraorbital; 20, muscular. (Modified with permission from Kline LB. Neuro-Ophthalmology Review Manual. 6th ed. Slack; 2008:213. Illustration by Christine Gralapp.)

cavernous sinus, and terminate in the arteries of the foramen rotundum and ovale. Variable meningeal branches may enter the superior orbital fissure. Terminal branches of the facial artery supply the marginal arcades of the eyelids. For further discussion of the blood supply of the eyelids, see BCSC Section 7, *Oculofacial Plastic and Orbital Surgery*.

It is extremely important to understand the extent of the collateral connections between the branches of the ECA and the ICA (see Fig 1-9). Interventional neuroradiologists and neurosurgeons may inadvertently embolize distal ICA branches, including the *central retinal artery (CRA)*, while placing particles into the ECA. Embolization is most likely to occur during the treatment of arteriovenous malformations, but it can also occur when skull-base tumors are embolized before surgical resection.

The most important collateral connections between the external and internal circulations traverse the orbit, including the following arteries:

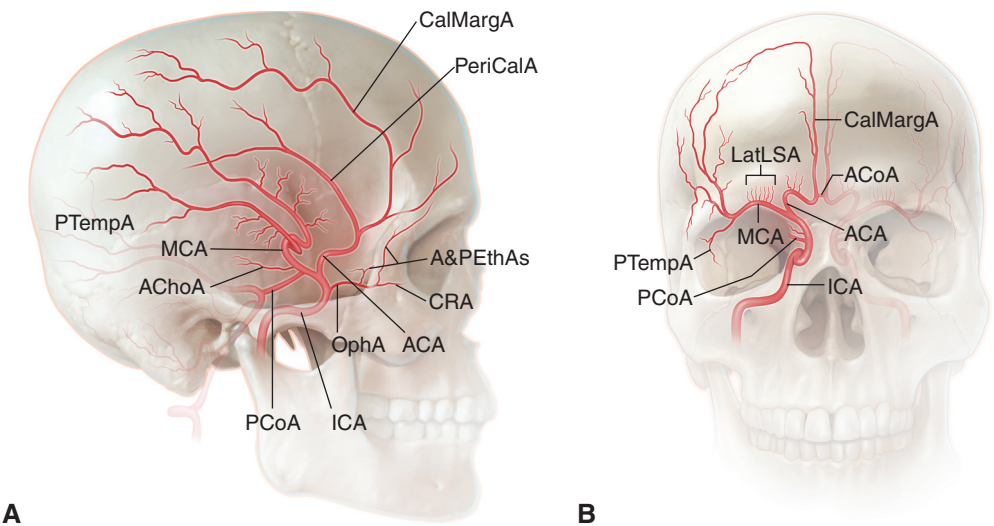
- *anterior and posterior ethmoidal arteries* medially
- *facial artery* where it joins the distal branches of the *supratrochlear* and *infratrochlear arteries* around the *angular artery* medially
- *infraorbital* and *supraorbital arteries* (including distal connections to the lacrimal artery) anteriorly
- *zygomaticotemporal branch* laterally
- various dural branches that traverse the superior and inferior orbital fissures

In rare instances, the *OphA* may also arise as a branch of the meningeal system of the ECA.

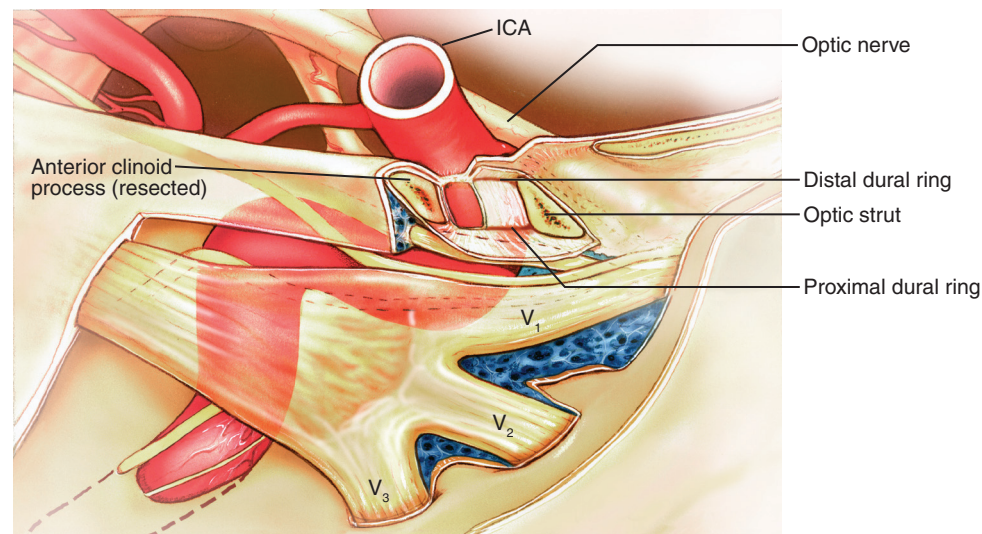
The ICA carries the major blood supply to the intracranial contents (Fig 1-10). The ICA enters the skull through the carotid canal. Within the petrous bone, the artery is near the middle and inner ear, as well as the intrapetrous portion of CN VII. As the ICA reaches the parasellar area, it turns superiorly just above the foramen lacerum. It then enters the cavernous sinus, where it first gives off the *meningohypophyseal trunk* and then turns anteriorly to run horizontally parallel to the body of the sphenoid to give off the *inferolateral trunk*, which forms anastomoses with branches of the middle meningeal artery. Branches of the meningohypophyseal trunk supply the dura of the posterior cavernous sinus as well as CNs III, IV, V, and VI entering the cavernous sinus. These branches also variably supply the lateral aspect of the sella turcica, including the pituitary capsule and a large portion of the pituitary gland itself.

At the anterior aspect of the cavernous sinus, the ICA loops to reverse its direction under the anterior clinoid and the optic nerve. This loop passes through 2 dural rings, both close to the anterior clinoid (the terminal portion of the lesser wing of the sphenoid). As the ICA passes through the second ring, it becomes intradural (Fig 1-11). Shortly thereafter, the ICA gives off the *OphA*, which enters the orbit along with the optic nerve through the optic canal. Determining whether an ICA aneurysm is intradural or extradural is critical, as the former carries an inherent risk of life-threatening subarachnoid hemorrhage with rupture, whereas the latter is associated with low morbidity with rupture.

Within the orbit, the *OphA* (see Fig 1-9) may anastomose with recurrent meningeal branches that enter through the superior orbital fissure. The *OphA* gives off the *CRA*, which then enters the substance of the optic nerve approximately 10–12 mm posterior to the globe. Within the eye, the *CRA* divides into superior and inferior arcades. These



**Figure 1-10** Branches of the internal carotid artery (ICA). **A**, Lateral view. **B**, Anteroposterior view. Proximal ICA branches: ophthalmic artery (OphA) and its branches (anterior and posterior ethmoidal arteries [A&PEthAs] and central retinal artery [CRA]); posterior communicating artery (PCoA); anterior choroidal artery (AChoA); anterior communicating artery (ACoA); anterior cerebral artery (ACA) and its branches (callosomarginal artery [CalMargA] and pericallosal artery [PeriCalA]); and middle cerebral artery (MCA) and its branches (lateral lenticulostriate artery [LatLSA] and posterior temporal artery [PTempA]). (Illustrations by Rob Flewell, CMI.)



**Figure 1-11** Lateral view of the bend of the internal carotid artery (ICA) within the right cavernous sinus. The anterior clinoid process has been resected to show the proximal and distal dural rings. V<sub>1</sub>=ophthalmic division of CN V; V<sub>2</sub>=maxillary division of CN V; V<sub>3</sub>=mandibular division of CN V. (Illustration by Dave Peace.)

retinal arteries and arterioles have tight junctions that form a blood–retina barrier, much like the blood–brain barrier. The intraretinal arterioles run within the substance of the nerve fiber layer to supply the inner two-thirds of the retina.

### CLINICAL PEARL

In most people, the OphA runs under the intracranial portion of the optic nerve. Therefore, an OphA aneurysm causes an inferior visual field defect because the superior portion of the optic nerve is pushed up against the falxiform ligament.

The *lacrimal artery*, which also derives from the OphA, runs parallel to the lacrimal branch of CN V<sub>1</sub> in the superior lateral orbital roof to reach the lacrimal gland. It also gives off the *anterior ciliary artery* of the lateral rectus muscle, which reaches the anterior segment at the muscle's insertion. The *frontal artery* runs within the superior orbit, paralleling the frontal branch of CN V<sub>1</sub> and separates into and terminates as the supraorbital and supratrochlear arteries that, along with the lacrimal artery, supply the eyelid.

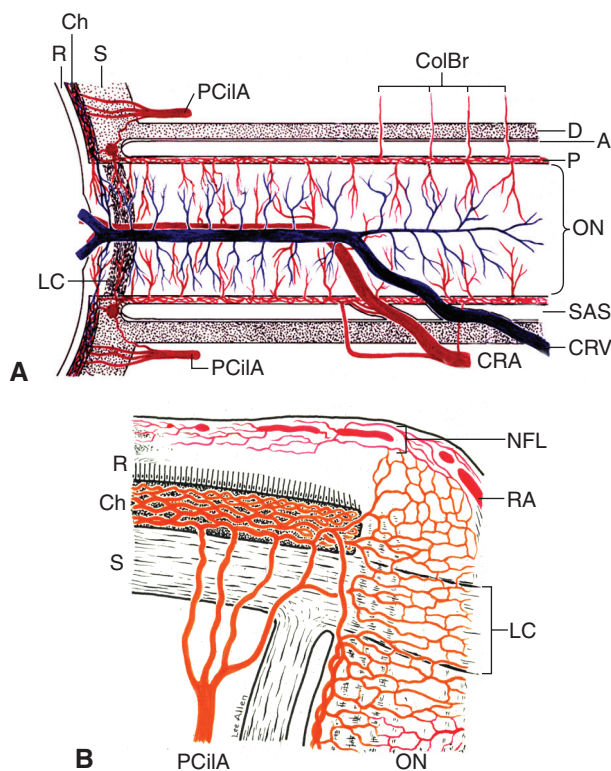
The next branches leaving the OphA are the *superior* and *inferior muscular arteries*, which supply the anterior ciliary arteries of the superior rectus and superior oblique muscles (superior muscular branch) and the medial and inferior rectus muscles (inferior muscular artery). The anterior ciliary arteries are responsible for most of the blood flow to the ciliary body. The *medial* and *lateral long posterior ciliary arteries* sometimes anastomose with penetrating branches of the anterior ciliary arteries (within the rectus muscles) to form the *greater arterial circle* near the anterior part of the ciliary body. Branches from this circle extend radially within the iris to form a second anastomotic circle (the *lesser arterial circle*) near the collarette of the iris.

The terminal OphA supplies additional branches that form collaterals with the *anterior* and *posterior ethmoidal arteries* and also form the *short* and *long posterior ciliary arteries* (Fig 1-12). The short posterior ciliary arteries then divide into 10–20 small branches that supply the optic nerve head (ONH) and posterior choroid. Together, these arteries also supply the retinal pigment epithelium and approximately the outer one-third of the retina, including the photoreceptor cells. In approximately 20%–30% of individuals, branches of the posterior ciliary arteries (*cilioretinal arteries*) directly supply a portion of the inner retina; this blood supply may protect the macula in the case of a CRA occlusion. Approximately 4 short posterior ciliary arteries form a variably complete anastomotic ring (known as the *circle of Zinn-Haller*) around the ONH, which is also supplied by the peripapillary choroid and the terminal branches of the pial network.

Collateral branches from terminal branches of the infraorbital artery and the superficial temporal artery help supply the lower and upper eyelids and may also provide collateral supply to the anterior segment. These collaterals may be interrupted if the conjunctiva and Tenon capsule are removed from the limbus during ocular surgery.

Distal to the origin of the OphA, the intradural supraclinoid ICA gives off the *anterior choroidal artery* (AChoA) and anastomoses with the proximal PCA through the *posterior communicating artery* (PCoA). The AChoA supplies blood proximally to the optic tract and

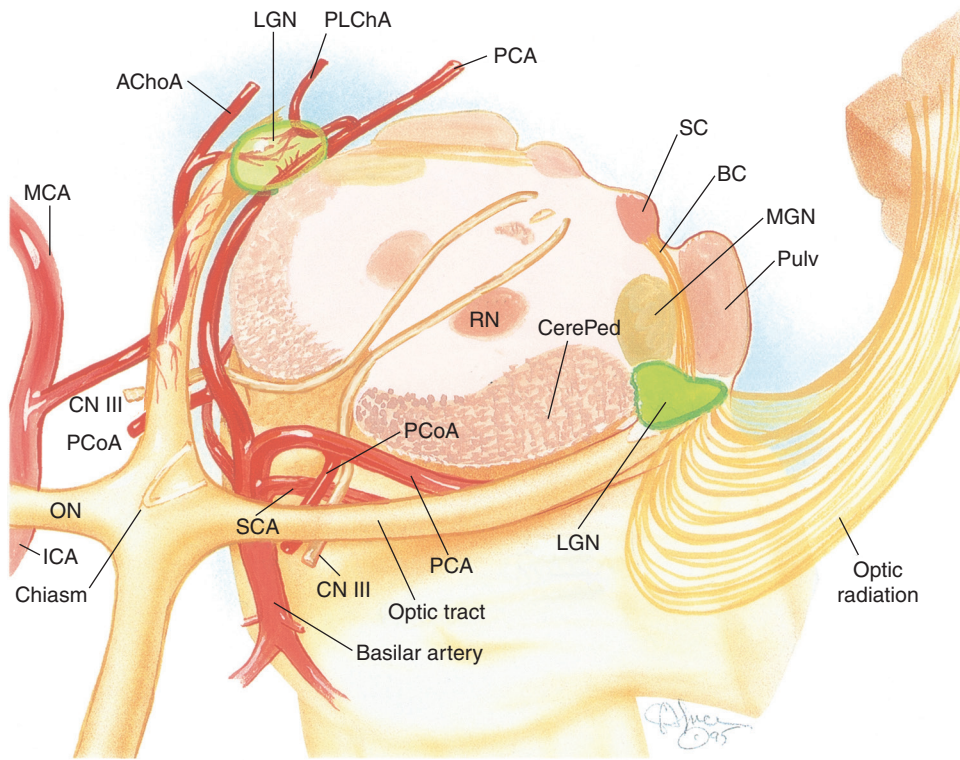




**Figure 1-12** Schematic representation of the vascular supply to the optic nerve and optic nerve head (ONH). **A**, Lateral view of the ONH. **B**, Axial view of the ONH. Short posterior ciliary arteries supply the centripetal capillary beds of the anterior ONH. The central retinal artery (CRA) contribution is restricted to capillaries of the nerve fiber layer and the anterior intraorbital optic nerve. Capillary beds at all levels drain into the central retinal vein (CRV). A=arachnoid; Ch=choroid; ColBr=collateral branch; D=dura; LC=lamina cribrosa; NFL=surface nerve fiber layer of the ONH; ON=optic nerve; P=pia; PCiIA=posterior ciliary artery; R=retina; RA=retinal arteriole; S=sclera; SAS=subarachnoid space. (Reprinted from Hayreh SS. The blood supply of the optic nerve head and the evaluation of it—myth and reality. *Prog Retin Eye Res.* 2001;20(5):563–593, with permission from Elsevier.)

distally to the *lateral geniculate nucleus (LGN)* (Fig 1-13). Occlusion of the AChOA can produce optic tract syndrome, a disorder consisting of contralateral homonymous hemianopia, contralateral band atrophy of the ONH, and a contralateral relative afferent pupillary defect (RAPD; see Chapter 4). The ICA then gives off the *anterior cerebral artery (ACA)* and terminates as branches of the *middle cerebral artery (MCA)*. The proximal ACA (the A1 segment) crosses over the optic nerve and joins the opposite ACA via the *anterior communicating artery (ACoA)*. This combination of the ACoA and PCoA creates the *circle of Willis*, which permits collateral flow between the carotid and vertebrobasilar systems when there is vascular compromise (Fig 1-14). Small perforating branches arising from the proximal ACA as well as the ACoA also supply the intracranial optic nerves and chiasm (Fig 1-15).

When distal ACA occlusion occurs, the afferent visual pathways are spared; however, the premotor areas of the frontal lobes responsible for initiating saccades are supplied by branches of the ACA. Thus, patients with acute occlusion of the distal ACA may have a



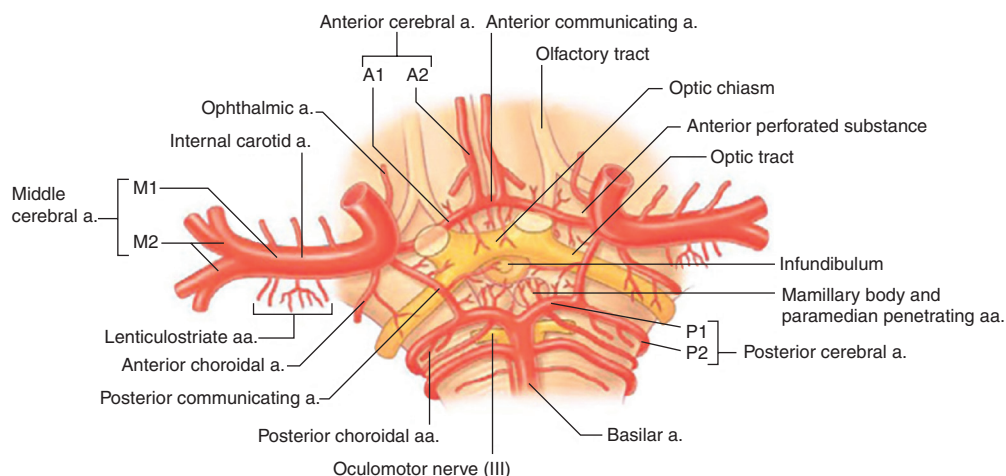
**Figure 1-13** Relationship of the lateral geniculate nucleus (LGN) to nearby structures and its blood supply. AChOA=anterior choroidal artery; BC=brachium conjunctivum; CerePed=cerebral peduncle; CN=cranial nerve; ICA=internal carotid artery; MCA=middle cerebral artery; MGN=medial geniculate nucleus; ON=optic nerve; PCA=posterior cerebral artery; PCoA=posterior communicating artery; PLChA=posterior lateral choroidal artery; Pulv=pulvinar; RN=red nucleus; SC=superior colliculus; SCA=superior cerebellar artery. (Illustration by Craig A. Luce.)

transient gaze preference and difficulty initiating contralateral saccades, although this effect is more commonly seen in patients with MCA territory lesions.

The MCA divides into several branches that supply the temporal lobe, parietal lobe, and superficial portions of the frontal and occipital lobes. Branches important to the visual pathways include those supplying the optic radiations as they traverse the deep white matter of the parietal and temporal lobes. Terminal branches of the MCA also variably supply the occipital tip representing the macula. This supply is chiefly responsible for the perimetric finding of macular sparing in PCA or calcarine artery occlusion (see Chapter 5). In addition to supplying the afferent pathways, the MCA supplies the middle temporal region, which is involved in visually guided pursuit movements.

### CLINICAL PEARL

An MCA infarct causes ipsilateral pursuit dysfunction or asymmetry in optokinetic nystagmus (OKN) when a clinician rotates the OKN drum toward the side of the infarction.



**Figure 1-14** The circle of Willis represents an anastomosis of the anterior, middle, and posterior cerebral arteries. Branches from these vessels supply the distal segment of the intracranial optic nerves, optic chiasm, and optic tract. a. = artery; aa = arteries. (Modified with permission from Liu GT, Volpe NJ, Galetta SL. *Neuro-Ophthalmology: Diagnosis and Management*. 2nd ed. Elsevier; 2010:295.)

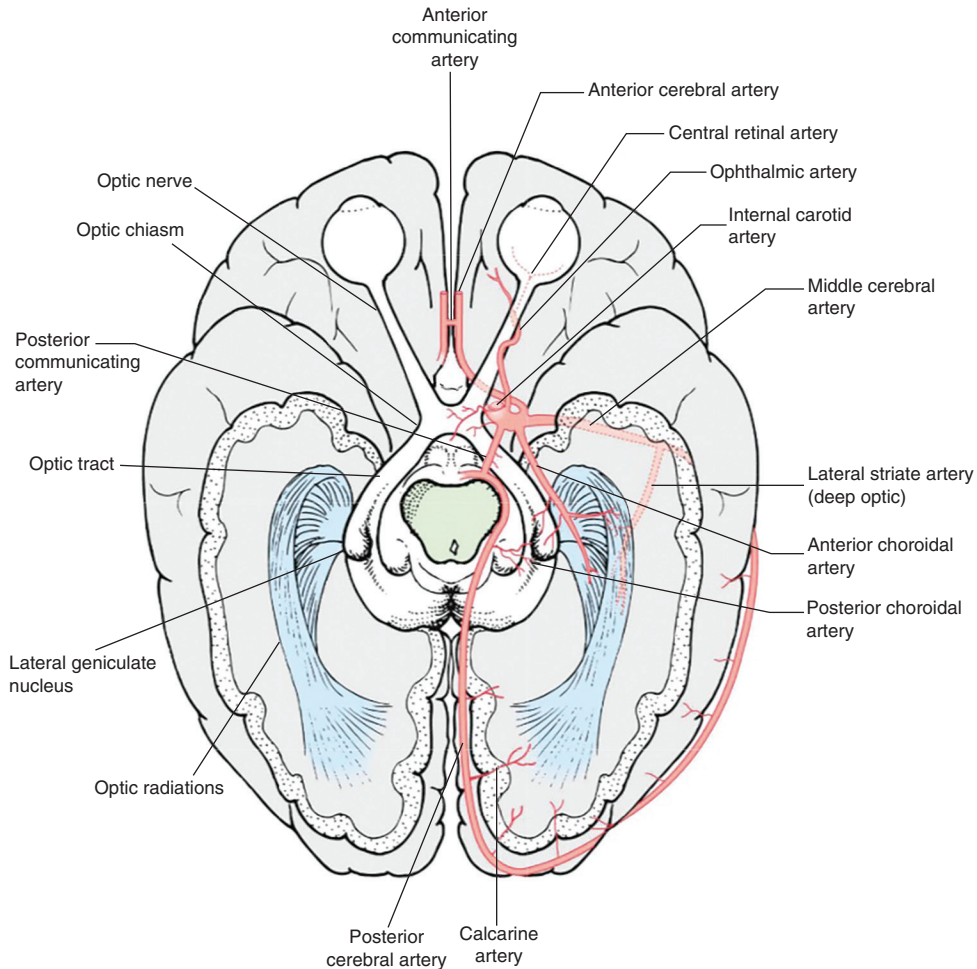
## Posterior Circulation

The posterior neurovascular circulation begins with the aortic arch. Beyond the origin of the common carotid artery, the innominate artery becomes the right subclavian artery. The left subclavian artery comes directly off the aorta. The right and left VAs subsequently arise from the subclavian arteries (see Fig 1-8A). The VA travels through a series of foramina in the lateral aspects of the cervical vertebral processes. After penetrating the dura at the foramen magnum, the VA gives rise to the *posterior inferior cerebellar artery (PICA)* before joining the other VA to form the BA (Fig 1-16). The PICA represents the more caudal of the 2 major circumferential arteries that wrap around the brainstem. Proximally, the PICA and BA give off branches that perforate the medial portion of the brainstem at the medullary level, followed by paramedian branches that supply the lateral aspects of the brainstem. Distally, the PICA supplies the inferior cerebellum, which is intimately involved in eye movements. VA or PICA occlusion is associated with lateral medullary syndrome (also called Wallenberg syndrome), which may present with ocular findings of Horner syndrome and ocular tilt reaction (see Chapter 9).

The second major circumferential arteries are branches of the *anterior inferior cerebellar artery (AICA)*. The AICA arises from the more rostral BA and supplies the pontomedullary junction and distal cerebellum. A large proximal branch of the AICA, the *internal auditory artery*, supplies the CN VIII complex in the subarachnoid space and extends into the internal auditory canal. Along the course of the BA, small perforators arise directly to supply portions of the pons and midbrain. Median perforators of the BA supply the following structures:

- the MLF
- the paramedian pontine reticular formation (PPRF)
- the medially located nuclei of CNs III, IV, and VI



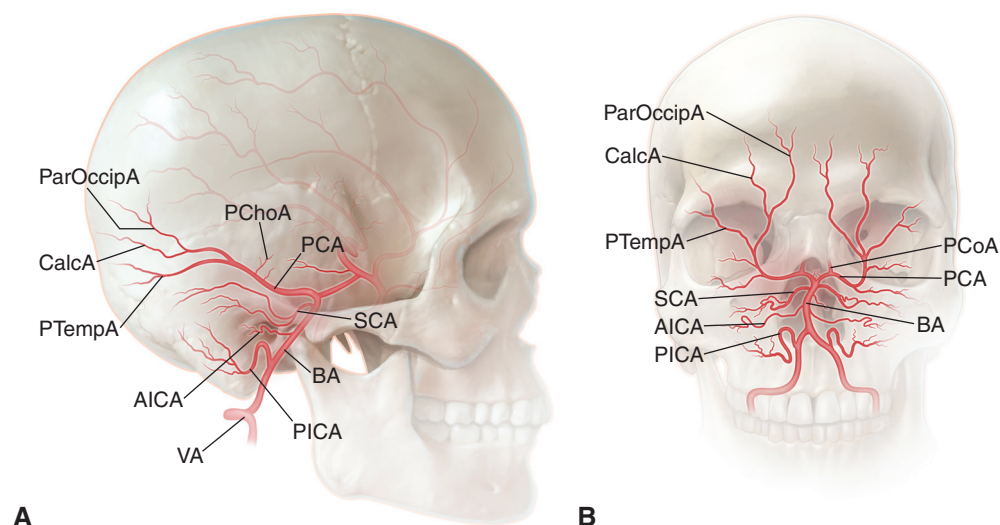


**Figure 1-15** Vascular supply of the optic nerve and visual pathway. (Modified with permission from Forrester JV, Dick AD, McMenemy PG, Roberts F, Pearlman E. *The Eye: Basic Sciences in Practice*. 4th ed. Elsevier; 2016:98.)

Interruption of these branches (which occurs commonly with vertebrobasilar atherosclerotic disease or emboli) produces variable ophthalmoplegia, internuclear ophthalmoplegia, and skew deviation. Pontine branches of the BA also supply the proximal portions of the CNs (particularly CN V) as they exit the brainstem.

The distal 2 sets of circumferential arteries consist of the *superior cerebellar artery* (SCA) followed by the PCA, representing the terminal branches of the BA at the level of the midbrain. Perforators from the proximal SCA partially supply the nucleus of CN III and its fascicles. In addition, small branches often supply the CN V root. CN III exits between the SCA and the PCA, where it may be compressed by an aneurysm.

Perforators from the proximal PCA (the P1 segment) supply the rostral portion of the midbrain (involved in vertical gaze) and part of the LGN. A large branch, the *artery of Percheron*, often supplies both sides of the midbrain from one of the PCAs. Because



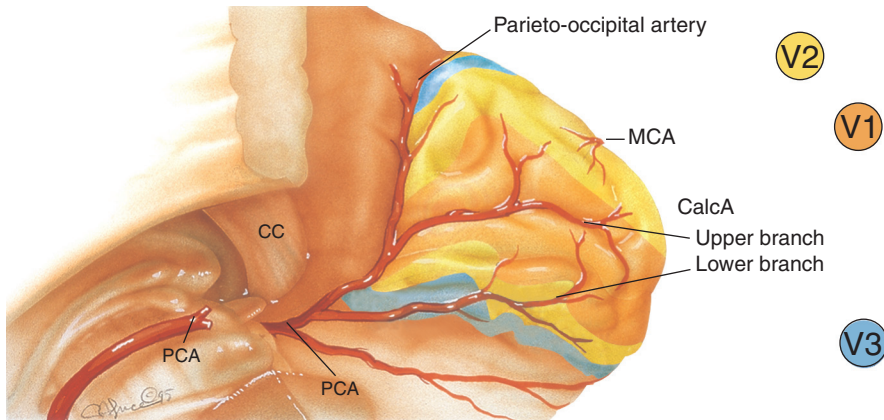
**Figure 1-16** Vertebrobasilar arterial system and major arteries with common variations of the cortical branches of the posterior cerebral artery (PCA). **A**, Lateral view. **B**, Anteroposterior view. Vertebral artery (VA) and basilar artery (BA) branches: anterior inferior cerebellar artery (AICA); posterior inferior cerebellar artery (PICA); superior cerebellar artery (SCA). PCA and its branches: calcarine artery (CalcA); parieto-occipital artery (ParOccipA); posterior choroidal artery (PChoA); posterior temporal artery (PTempA); posterior communicating artery (PCoA). (Illustration by Rob Flewell, CMI.)

*thalamostriate arteries* originate from the P1 segment, infarcts related to the ICA–MCA spare the thalamus. The P1 segment ends with the PCoA, which joins the vertebrobasilar circulation to the carotid circulation anteriorly. The connecting PCoA parallels the course of CN III and then joins the ICA, which explains the occurrence of CN III palsy with PCoA aneurysms. As the distal PCA courses around the brainstem, it gives off a *parieto-occipital branch* before terminating in the *calcarine branch*, which supplies the primary visual cortex (Fig 1-17).

## Venous System

Ocular venous outflow begins in the *arcade retinal veins*, which exit into the *central retinal vein* (CRV), and in the *choroidal veins*, which exit the sclera through the *vortex veins*. Anteriorly, the episcleral venous plexus collects both blood from the anterior uveal circulation and aqueous percolating through the Schlemm canal. These 3 primary venous drainage pathways (Fig 1-18) empty mainly into the *superior ophthalmic vein* (SOV), which runs posteriorly within the superior medial orbit to the orbital apex, where it crosses laterally to enter the cavernous sinus posterior to the superior orbital fissure. Cavernous sinus thrombosis or carotid-cavernous fistulas may cause venous congestion in the orbit and arterialization of the episcleral and conjunctival vessels (see Chapter 8, Fig 8-13).

Microscopic collaterals exist at variable levels between these venous beds. In rare instances, shunts connecting retinal veins to choroidal veins are present within the retina. More commonly, optociliary shunt vessels (retinochoroidal collateral vessels) may appear



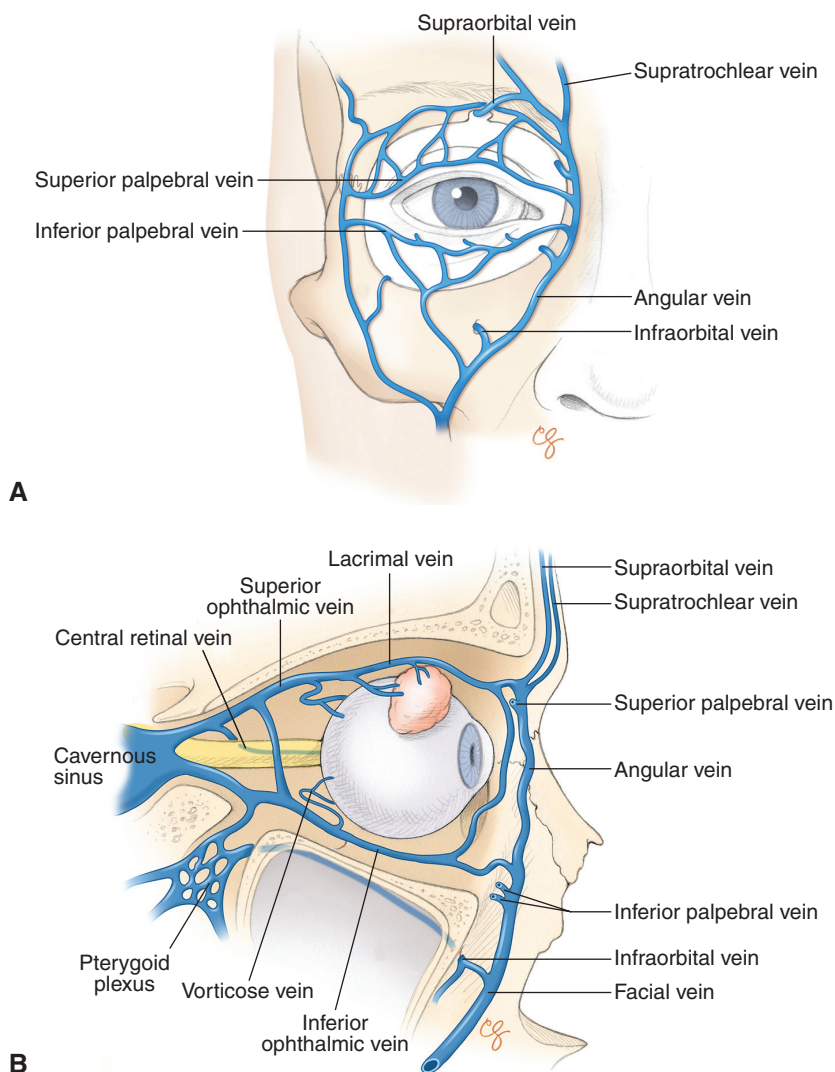
**Figure 1-17** The occipital cortex and its blood supply. The primary visual cortex, or striate cortex (V1); the parastriate cortex (V2); and V3 are keyed by color. CalcA=calcarine artery; CC=corpus callosum; MCA=middle cerebral artery; PCA=posterior cerebral artery. (Illustration by Craig A. Luce.)

on the ONH surface, usually with diseases that impair venous outflow, such as CRV occlusion, optic nerve sheath meningioma, or optic nerve gliomas. At a more macroscopic level, the SOV is inconstantly connected anteriorly to the *angular* and *facial veins* and inferiorly to the *inferior ophthalmic vein* and *pterygoid plexus*. Venous collaterals are especially important in patients with elevated venous pressure due to a carotid-cavernous fistula and may provide endovascular access for embolization.

Intracranially, the superficial cortical venous system drains mainly superiorly and medially to the *superior sagittal sinus* running in the sagittal midline (Fig 1-19). In addition to facilitating cortical drainage, the superior sagittal sinus absorbs CSF through the arachnoid villi and the pacchionian granulations. The superior sagittal sinus continues posteriorly to terminate at the *torcular Herophili* (confluence of the venous sinuses) at the level of the tentorium that separates the cerebellum from the occipital lobes. Obstruction to venous outflow from venous sinus stenosis or thrombosis decreases CSF absorption and elevates intracranial pressure and may present as papilledema and/or CN VI palsy. From the point where the tentorium connects to the skull, the *transverse sinuses* run anteriorly to the petrous pyramid. Here, they turn to run caudally as the *sigmoid sinus* down to the *jugular bulb*, where the *internal jugular vein* exits the skull.

Inferior superficial cortical venous drainage is carried directly down to the transverse and sigmoid sinuses through the *vein of Labbé* and the *basilar vein of Rosenthal*. Supratentorial diencephalon and mesencephalon drainage begins with the deep-draining veins (often in relation to the ventricular system). These deep veins merge to form the *vein of Galen*, which drains posteriorly into the straight sinus. Along with the superior sagittal sinus, the vein of Galen then runs within the tentorium to drain into the torcular Herophili.

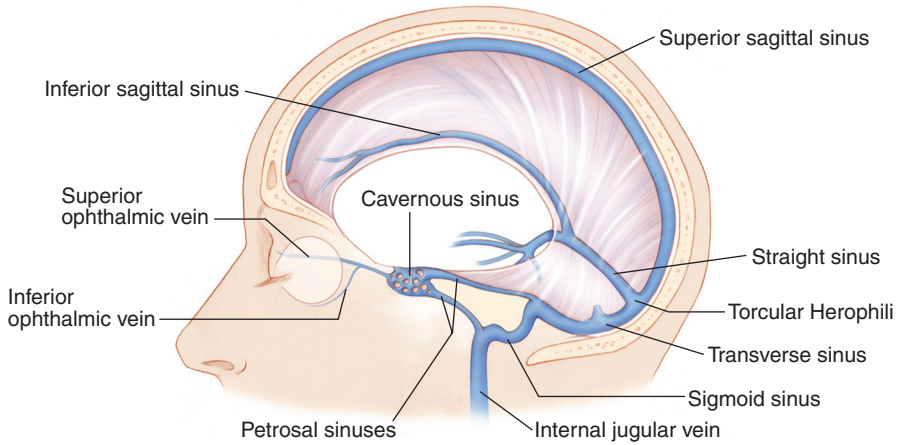
Some anterior cerebral venous drainage may access the 2 cavernous sinuses, which are joined by variable connections through the sella and posteriorly through a plexus of



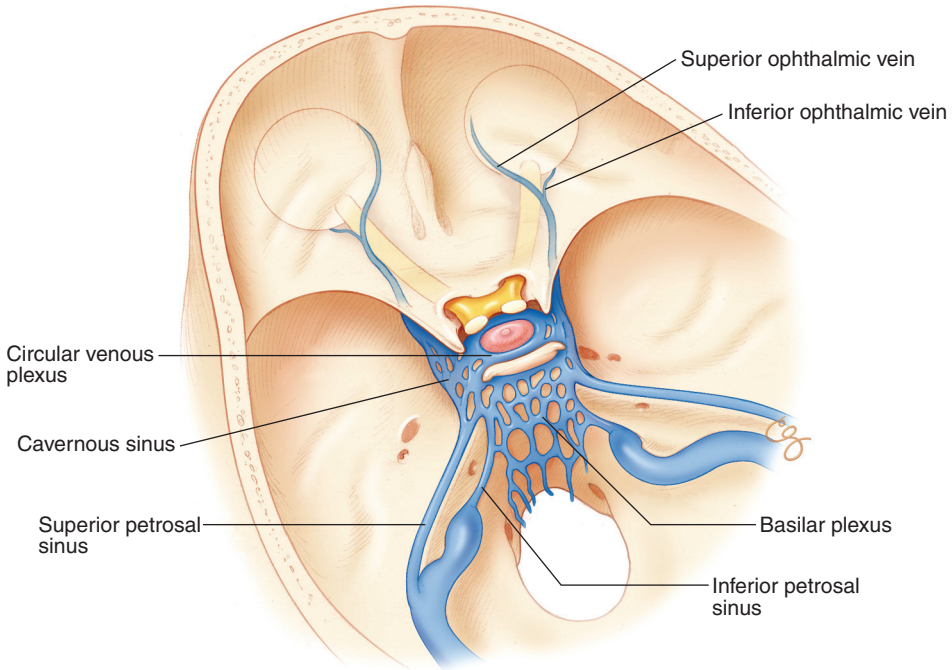
**Figure 1-18** Venous drainage of the orbit. **A**, Anterior view of the superficial venous system of the eyelids. **B**, Sagittal view of the venous circulation of the orbit and globe. (Illustrations by Christine Gralapp.)

veins over the clivus. The cavernous sinus drains primarily caudally into the jugular bulb via the *inferior petrosal sinus*, which traverses the Dorello canal with CN VI under the petroclinoid ligament. Alternatively, drainage may occur laterally along the petrous apex through the *superior petrosal sinus* to the junction of the transverse and sigmoid sinuses (Fig 1-20). Small veins may drain through the foramen rotundum and foramen ovale as well as through the pterygoid plexus to anastomose with the *facial venous system* (*external jugular vein*).





**Figure 1-19** Anatomy of the cerebral venous sinus system. (Illustration by Christine Galapp.)



**Figure 1-20** Anatomy of the cavernous sinus drainage system. (Illustration by Christine Galapp.)

Veins of the eyelids anastomose medially between the *angular vein* and branches of the SOV in the superior medial orbit in the region of the trochlea. Facial veins drain inferiorly and laterally to form the external jugular vein, which eventually joins the internal jugular in the neck.

Lasjaunias P, Berenstein A, ter Brugge KG. *Clinical Vascular Anatomy and Variations*. 2nd ed. Springer; 2001. *Surgical Neuroangiography*; vol 1.

## Afferent Visual Pathways

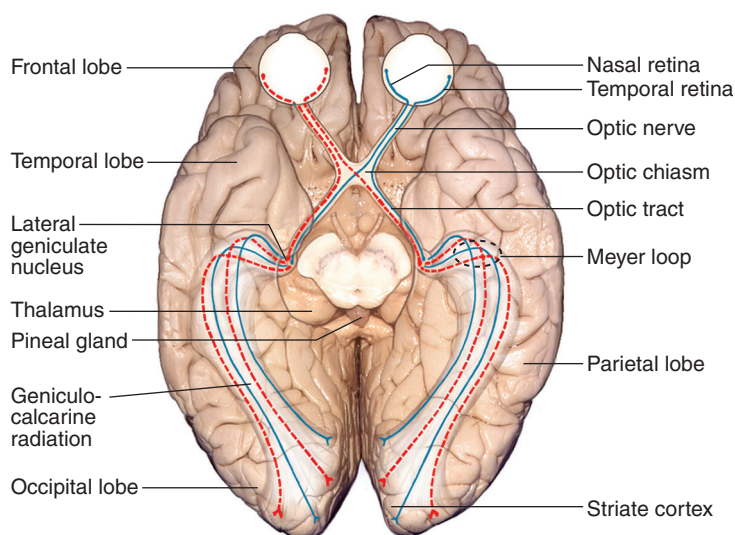
A disturbance in visual function may be the result of pathology affecting any part of the afferent visual system, including the retina, optic nerve, and visual pathways (Fig 1-21).

### Retina

The afferent visual pathway begins within the retina. Details of retinal anatomy can be found in BCSC Section 2, *Fundamentals and Principles of Ophthalmology*, and Section 12, *Retina and Vitreous*. The following discussion focuses on key points relevant to neuro-ophthalmology.

The absence of retinal receptors over the ONH creates a *physiologic scotoma* (*blind spot*), located approximately 15° from the fovea and measuring approximately 5° by 7°. The fovea, which is approximately 1.5 mm in diameter (1 disc diameter), is located about 4 mm (approximately 2.5 disc diameters) from and 0.8 mm lower than the ONH.

By contrast, the retinal pigment epithelium is in direct contact with the retinal photoreceptor cells. Between the outer and inner retinal layers, the retinal signal generated in rods and cones is processed primarily through the bipolar cells that synapse on retinal ganglion cells (RGCs). A subset of melanopsin-containing RGCs, known as intrinsically photosensitive retinal ganglion cells (ipRGCs), serve primarily nonvisual light-dependent



**Figure 1-21** Basal view of the brain showing the anterior and posterior visual pathways. (Illustration by Dave Peace.)

functions such as the pupillary light reflex. *Horizontal*, *amacrine*, and *interplexiform cells* (which communicate horizontally between neighboring cells) permit signal processing within the retinal layers. The glial support cells—*Müller cells* and *astrocytes*—play an important metabolic role.

The ratio of photoreceptor cells to RGCs varies depending on the region of the retina. The ratio is highest in the periphery (at more than 1000:1) and lowest at the fovea (where an RGC may receive a signal from a single cone). The foveal bipolar cells and RGCs are displaced radially from the fovea, with the bipolar cells receiving input via long cone axons that make up the *Henle layer*. The radial nature of the Henle layer is responsible for the accumulation of fluid in the macula in a star-shaped pattern.

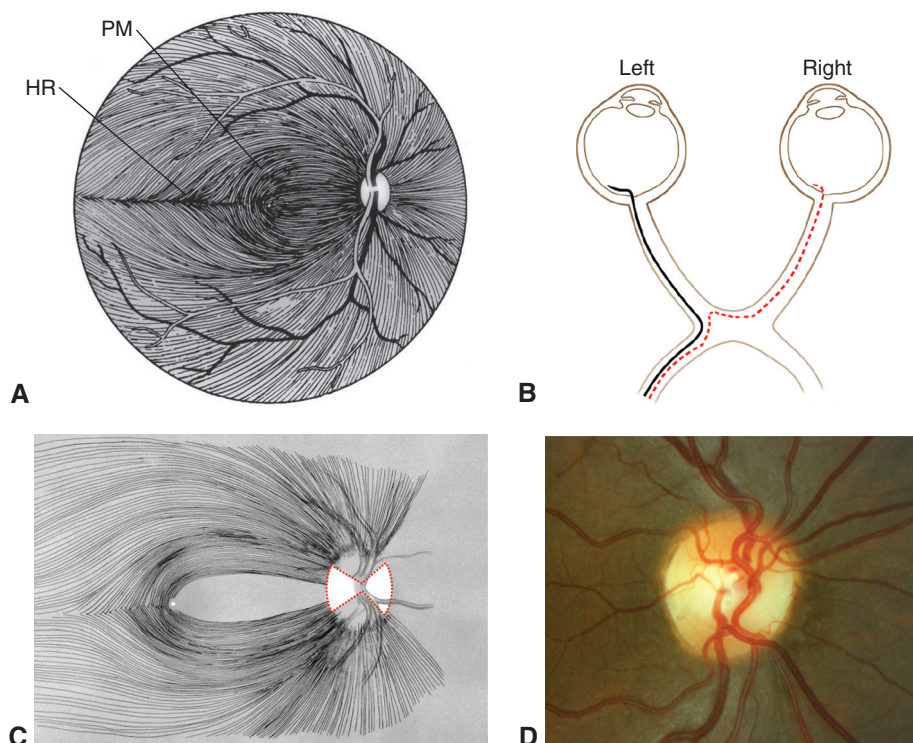
## Optic Nerve

The optic nerve begins anatomically at the ONH but physiologically and functionally within the RGC layer that covers the entire retina. Although ganglion cell fibers coming from the nasal retina can travel uninterrupted directly to the ONH, those coming from the temporal retina must anatomically separate to enter the ONH at either the superior or the inferior pole in order to avoid the macula (Fig 1-22). This unique anatomy means that some of the nasal fibers (nasal within the macula) enter the ONH on its temporal side (within the *papillomacular bundle*). Defects in the nerve fiber layer include focal loss, which may appear as either grooves or slits or as reflections that parallel the retinal arterioles where the internal limiting membrane drapes over the vessels. Diffuse loss of the nerve fiber layer is often more difficult to detect and brings the retinal vessels into sharp relief.

The first portion of the optic nerve, representing the confluence of approximately 1.0–1.2 million RGC axons, traverses the sclera through the lamina cribrosa, which contains approximately 200–300 channels. The combination of small channels and a unique blood supply (largely from branches of the posterior ciliary arteries) likely plays a role in several optic neuropathies. Anterograde and retrograde axonal transport of molecules, subcellular organelles, and metabolic products occurs along the length of the optic nerve. The anterograde axonal transport system is further subdivided into slow, intermediate, and fast speeds. This energy-dependent system, which requires high concentrations of oxygen, is sensitive to ischemic, inflammatory, and compressive processes.

Just posterior to the sclera, the optic nerve acquires a dural sheath that is contiguous with the periorbita of the optic canal and an arachnoid membrane that supports and protects the axons and is contiguous with the arachnoid of the subdural intracranial space through the optic canal. This arrangement permits circulation of CSF around the optic nerve up to the ONH. Just posterior to the lamina cribrosa, the optic nerve also acquires a myelin coating, which increases its diameter from 1.5 mm (ie, in the ONH) to approximately 3 mm (6 mm including the optic nerve sheath). The myelin is part of the membrane of oligodendrocytes that join the nerve posterior to the sclera.

The intraorbital optic nerve extends approximately 25–30 mm to the optic canal, a length that allows unimpeded globe rotation as well as axial shifts within the orbit. The CRA and CRV travel within the anterior 10–12 mm of the optic nerve. The CRA supplies



**Figure 1-22** Anatomy of retinal ganglion cell axons. **A**, Pattern of the nerve fiber layer of axons from ganglion cells to the ONH. Superior, inferior, and nasal fibers take a fairly straight course. Temporal axons originate above and below the horizontal raphe (HR) and take an arching course to the ONH. Axons arising from ganglion cells in the nasal macula project directly to the ONH as the papillomacular bundle (PM). **B**, Lesions involving the decussating nasal retinal fibers (represented by the *dashed red line*) can result in bow-tie atrophy. **C**, Schematic depiction of damage to nasal and papillomacular fibers of the retina and patterns of nasal and temporal optic nerve atrophy (represented by *red outlined triangles*) corresponding to damaged crossing nasal fibers. Therefore, in a patient with a pregeniculate homonymous hemianopia or a bitemporal hemianopia, band (or bow-tie) atrophy occurs with loss of nasal macular and peripheral fibers in the contralateral eye. **D**, Clinical photograph of a right optic nerve demonstrating bow-tie atrophy. (Part A reprinted from Kline LB, Foroozan R, eds. *Optic Nerve Disorders*. 2nd ed. *Ophthalmology Monographs* 10. Oxford University Press, in cooperation with the American Academy of Ophthalmology; 2007:5. Part B illustration by Christine Gralapp; part C courtesy of Neil Miller, MD; part D courtesy of Lanning Kline, MD.)

only a minor portion of the optic nerve circulation; most of the blood supply comes from pial branches of the surrounding meninges, which are in turn supplied by small branches of the OphA (see Fig 1-12). An approximate topographic representation is maintained in the optic nerve. Peripheral retinal representation is found more peripherally, and the papillomacular bundle travels temporally and increasingly centrally within the nerve.

As the optic nerve enters the optic canal, its dural sheath fuses with the periorbita. It is also surrounded by the *annulus of Zinn*, which serves as the origin of the 4 rectus muscles and the superior oblique muscle. The optic canal, which runs superiorly and medially, is normally approximately 8–10 mm long and 5–7 mm wide; however, it may be elongated and



narrowed by bone thickening processes (eg, fibrous dysplasia, intraosseous meningioma, vitamin A deficiency). Within the canal, the optic nerve is relatively anchored and can easily be injured by shearing forces transmitted from blunt facial trauma (see Chapter 4).

At its intracranial passage, the optic nerve passes under a fold of dura (the falciform ligament) that may impinge on the nerve, especially if it is elevated by lesions arising from the bone of the sphenoid (tuberculum) or the sella. Once it becomes intracranial, the optic nerve no longer has a sheath. The anterior loop of the carotid artery usually lies just below and temporal to the nerve, and the proximal ACA passes over it. The gyrus rectus, the most inferior portion of the frontal lobe, lies above and parallel to the optic nerve. The intracranial portion of the optic nerve—which is 3–16 mm long, usually approximately 10 mm—continues to the optic chiasm.

Lee AG, Morgan ML, Palau A, et al. Anatomy of the optic nerve and visual pathway. In: Tubbs RS, Rizk E, Shoja M, Loukas M, Barbaro N, Spinner R. *Nerves and Nerve Injuries*. Vol 1. Academic Press; 2015:277–303.

Salazar JJ, Ramirez AI, De Hoz R, et al. Anatomy of the human optic nerve: structure and function. In: *Optic Nerve*. IntechOpen; 2018. 10.5772/intechopen.79827

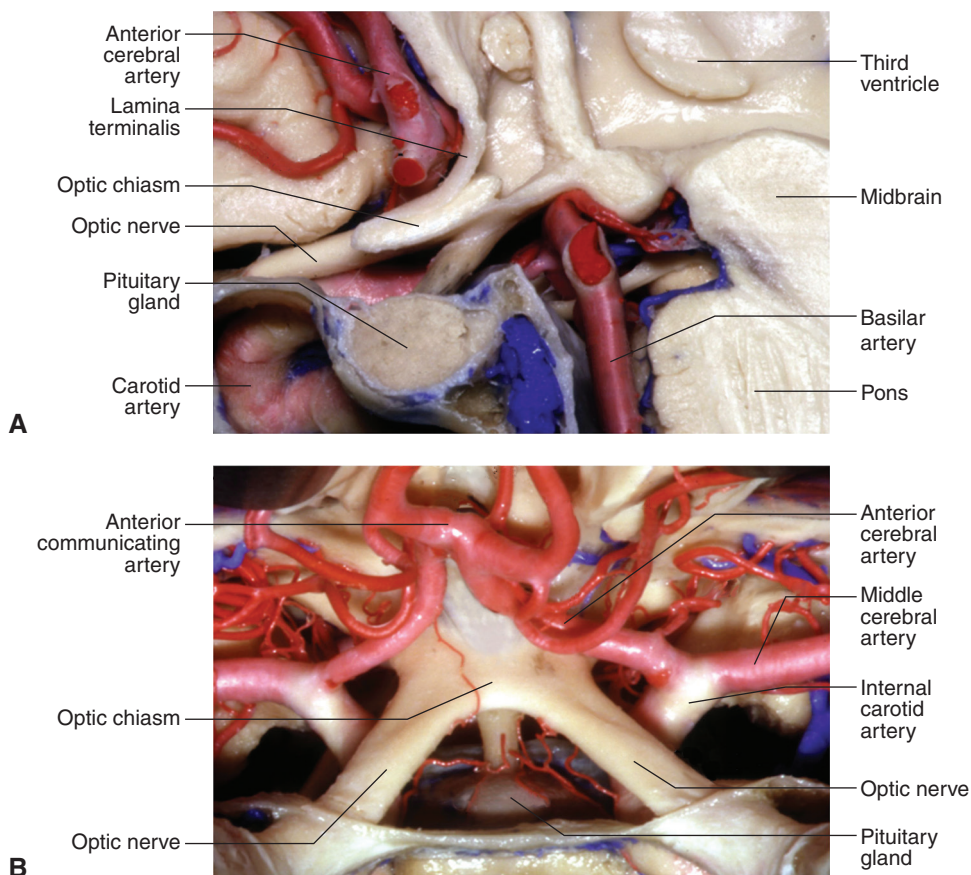
## Optic Chiasm

The optic chiasm is approximately 12 mm wide, 8 mm long in the anteroposterior direction, and 4 mm thick (Fig 1-23). It is inclined at almost 45° and is supplied by small arterial branches from the proximal ACA and ACoA. The chiasm is located just anterior to the hypothalamus and the anterior third ventricle (forming part of its anterior wall and causing an invagination) and approximately 10 mm above the sella. Its location with respect to the sella varies but is usually directly superior (Fig 1-24). In individuals with a pituitary macroadenoma, a prefixed chiasm may cause compression of the optic tract, whereas a postfixed chiasm may cause compression of the optic nerve(s).

Within the chiasm, the fibers coming from the nasal retina (approximately 53% of total fibers) cross to the opposite side to join the corresponding contralateral fibers. The inferior fibers (those subserving the superior visual field) are the first to cross. The anterior loop of fibers into the contralateral optic nerve (Wilbrand knee) may be an artifact in monkeys, but not necessarily in humans. The finding of a superior temporal visual field defect contralateral to a central scotoma localizes the pathology to the junction of the optic nerve and chiasm. The macular fibers tend to cross posteriorly within the chiasm; this arrangement underlies the bitemporal scotomatous visual field defects observed with posterior chiasmal compression.

## Optic Tract

The fibers exiting the optic chiasm proceed circumferentially around the diencephalon lateral to the hypothalamus and in contact with the ambient cistern (see Fig 1-13). The lack of proximity between corresponding fibers from the right and left eyes explains the incongruous nature of optic tract visual field defects. Just before the LGN, the fibers involved in the pupillary pathways exit to the pretectal nuclei; other fibers exit to the superficial layers of the superior colliculi (SC) via the brachium of the SC. These fibers, which

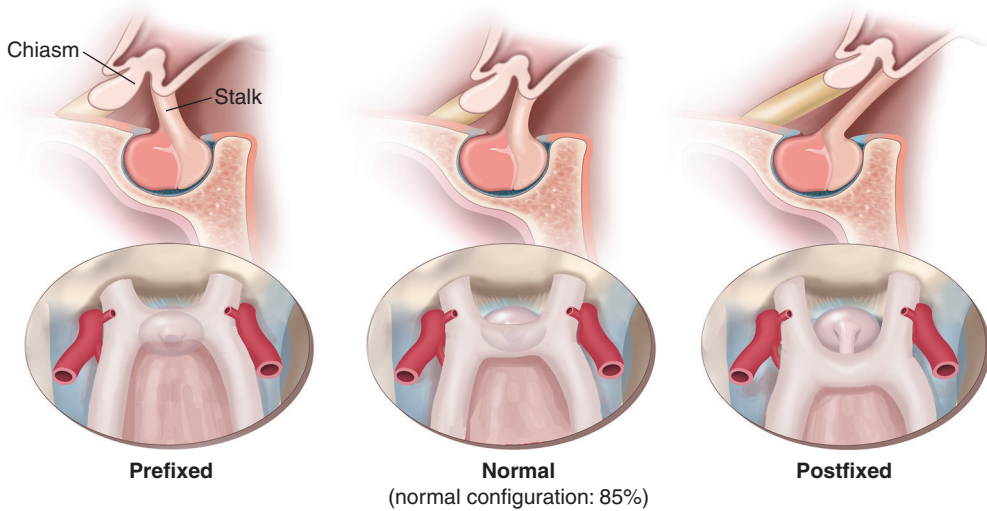


**Figure 1-23** Anatomical dissection of the optic chiasm and surrounding structures. **A**, Sagittal view. **B**, Superior view. (Courtesy of Albert L. Rhoton Jr, MD.)

originate from ipRGCs, are likely the sole source of pupillomotor input from the retina to the midbrain. The ipRGCs also project to the suprachiasmatic nucleus of the hypothalamus, which is likely responsible for light-induced diurnal rhythms. Most of the axons that originate in the RGCs terminate within the LGN.

The LGN is located in the posterior thalamus below and lateral to the pulvinar and above the lateral recess of the ambient cistern. This peaked, mushroom-shaped structure is divided into 6 levels (see Figure 3-9 in BCSC Section 2, *Fundamentals and Principles of Ophthalmology*): Axons originating in the contralateral eye terminate in layers 1, 4, and 6 of the LGN. Axons from the ipsilateral eye terminate in layers 2, 3, and 5.

- Two inferior layers (layers 1 and 2) receive input from fibers of M-cells, ganglion cells with larger receptive fields sensitive to motion detection.
- Four superior levels (layers 3, 4, 5, and 6) are the termini of axons of P-cells, ganglion cells with smaller receptive fields responsible for mediating maximal spatial resolution and color perception.



**Figure 1-24** Position of the optic chiasm in relation to the sella. (Illustration by Rob Flewell, CMI.)

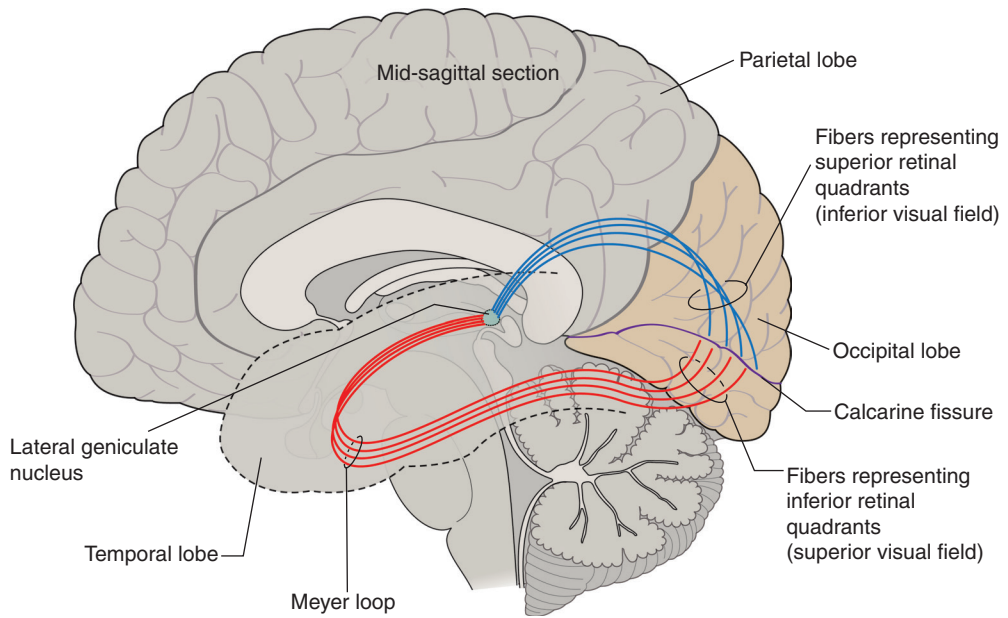
As the fibers approach the LGN, the retinal representation rotates almost  $90^\circ$ , with the superior fibers moving medially and the inferior fibers laterally. The macular fibers tend to move superolaterally. Cortical and subcortical pathways may modulate activity in the LGN. In addition, the cortex, SC, and pretectal nuclei project back to the LGN.

## Cortex

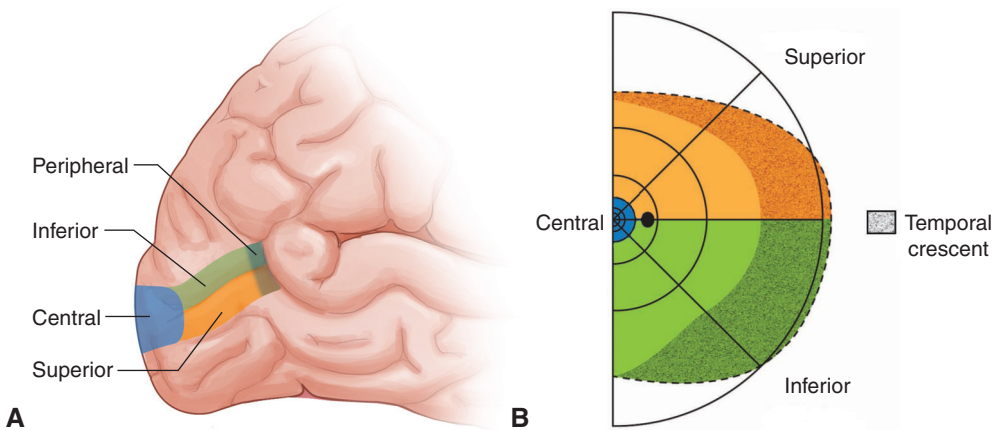
Following a synapse in the LGN, axons travel posteriorly as optic radiations that terminate in the primary visual (calcarine) cortex in the occipital lobe (Fig 1-25). The most inferior fibers first travel anteriorly, then laterally and posteriorly to loop around the temporal horn of the lateral ventricles (called the *Meyer loop*). The superior fibers travel posteriorly through the deep white matter of the parietal lobe. The macular (central) fibers course laterally, with the peripheral fibers concentrated more at the superior and inferior aspects of the radiations.

Injury to fibers within a radiation produces a homonymous hemianopia, a contralateral visual field defect that respects the vertical midline. If the corresponding fibers from the 2 eyes are close to each other, the visual field defect in each eye is identical, or congruous. Congruous visual field defects occur as a result of lesions in the calcarine cortex. More anterior involvement often produces incongruous visual field defects, suggesting that the corresponding fibers lie farther apart more anteriorly in the visual pathways.

The *primary visual cortex* (known variously as *V1*, *striate cortex*, or *Brodmann area 17*) is arrayed along the horizontal calcarine fissure, which divides the medial surface of the occipital lobe. Fibers of the optic radiations terminate in the fourth of 6 layers in the primary visual cortex. Fibers from the *temporal crescent*, or the most lateral visual field (originating only in the contralateral eye), terminate most anteriorly (Fig 1-26). The macular fibers terminate more posteriorly.



**Figure 1-25** Schematic of the optic radiations, sagittal view. The inferior fibers (subserving the superior visual field) course anteriorly before looping posteriorly in the temporal lobe. The superior fibers (subserving the inferior visual field) course dorsally in the parietal lobe to terminate in the occipital lobe above the calcarine fissure. (Redrawn with permission from the University of Texas at Dallas. Illustration by Mark Miller.)

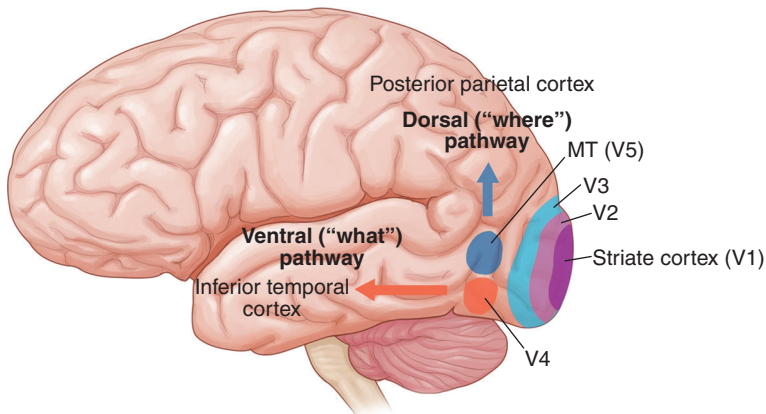


**Figure 1-26** Primary visual cortex and corresponding visual field representation. **A**, Left occipital cortex showing the location of the striate cortex within the calcarine fissure. *Blue* represents the macula (central visual field); *green* represents the inferior visual field; and *orange* represents the superior visual field. The most peripheral fibers are represented by the *stippled colors*. **B**, Right hemifield corresponds to the regions of the striate cortex in **A**. The *stippled area* corresponds to the monocular temporal crescent, which is mapped in the most anterior approximately 8% of the striate cortex. Black dot=physiologic blind spot. (Illustrations by Christine Galapp.)

The cortex is heavily weighted to central retinal activity, with 50%–60% of the cortex responding to activity within the central 10° and approximately 80% devoted to macular activity (within 30°).

The superior portion of the cortex continues to receive information from the inferior visual field in a retinotopic distribution. This retinotopic mapping throughout the afferent visual pathways allows lesions to be localized on the basis of visual field defects. The anteromedial portion of the striate cortex represents the far monocular temporal visual field (temporal crescent) of the contralateral eye. Therefore, a far monocular temporal visual field defect localizes the lesion to the contralateral anterior occipital cortex (see Fig 1-26).

The *parastriate cortex* (also called V2, or *Brodmann area 18*) is contiguous with the primary visual cortex and receives its input from V1. Area V3 projects primarily to the posterior parietal lobe and receives direct input from V1. Area V3 has no sharp histologic delineation from V2 and sends efferent information to the basal ganglia (pulvinar) and the midbrain. Cells in this area are thought to respond to more than 1 stimulus dimension, suggesting that visual integration occurs in this region. Area V4, located within the lingual and fusiform gyri, is particularly sensitive to color. Damage to this area is probably responsible for most cases of cerebral achromatopsia. Area V5 is located posterior to and within the superior temporal sulcus and gyrus subangularis. It corresponds to the middle temporal visual region and receives ipsilateral input from V1 and direct input from the M-cell layers of the LGN (Fig 1-27). The receptive fields of V5 are larger than those of V1, and the underlying white matter is heavily myelinated. The SC receives afferent input directly from the anterior visual pathways and indirectly from the calcarine cortex. The superficial layers contain a retinotopic map that overlies the deeper layers, which are primarily concerned with saccadic generation.



**Figure 1-27** Parallel visual processing pathways in the human brain. The occipitotemporal (ventral, or "what") pathway begins in the striate cortex (V1) and projects to the angular gyrus for language processing, to the inferior temporal cortex for object identification, and to the limbic structures. The occipitoparietal (dorsal, or "where") pathway begins in the striate cortex and projects to the posterior parietal cortex and the superior temporal cortex and is responsible for visual-spatial analysis. MT = middle temporal visual area.



**CLINICAL PEARL**

The neurons in area V5 encode the speed and direction of moving stimuli. This sensory area is likely the origin of pursuit movements and thus connects the afferent and efferent pathways.

Horton JC, Hoyt WF. The representation of the visual field in human striate cortex.

A revision of the classic Holmes map. *Arch Ophthalmol*. 1991;109(6):816–824.

## Efferent Visual System

---

Over the last few decades, our understanding of the anatomy, physiology, and pathology of the ocular motor system has increased dramatically on the basis of primate model experiments, human electrophysiology testing, functional magnetic resonance imaging studies, and the clinical-pathologic-radiologic correlations of disorders in patients with eye movement abnormalities.

A properly functioning ocular motor system ultimately ensures clear, stable, and binocular vision. Two basic human eye movements facilitate this task:

- gaze shift
- gaze stabilization

These movements can be further divided into 6 functional systems:

- ocular fixation system
- vestibular ocular system (vestibular ocular reflex)
- optokinetic system
- saccadic system
- smooth-pursuit system
- vergence system

Although these systems are under the control of—and are modulated by—different regions of the brain (ie, the cortex) and brainstem, they have considerable anatomical and functional overlaps (see Chapter 9).

This section provides an overview of the anatomy of the ocular motor system, with a detailed discussion of clinical applications presented in Chapter 9. To facilitate learning, this discussion follows a top-to-bottom approach based on the following topics:

- cortical control of eye movements, including frontal eye fields, supplementary eye fields, and posterior parietal cortex
- subcortical centers, including the basal ganglia (BG), thalamus, and SC
- brainstem or premotor structures coordinating conjugate eye movements, including the vestibular-ocular system and the cerebellum
- ocular motor CNs (CNs III, IV, and VI)
- extraocular muscles (EOMs)

Interested readers can find a comprehensive description of the ocular motor system in the following reference.

Leigh RJ, Zee DS. *The Neurology of Eye Movements*. 5th ed. Contemporary Neurology Series. Oxford University Press; 2015.

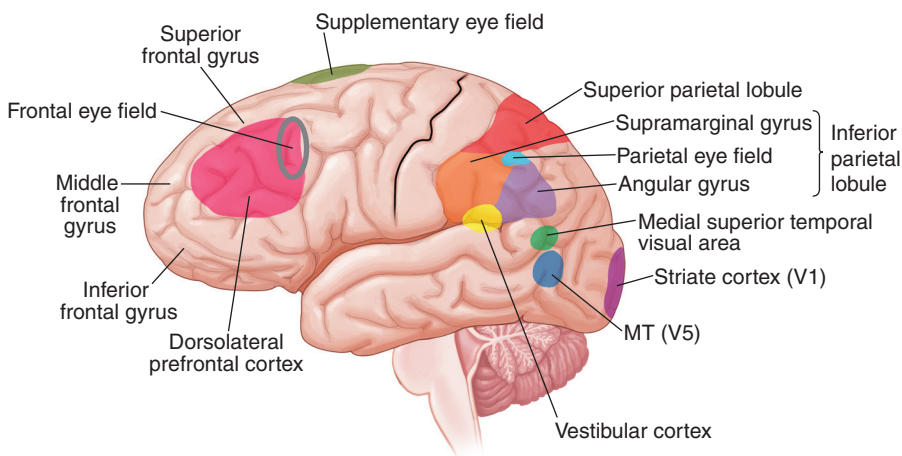
## Cortical Input

The efferent visual system spans a large segment of the central nervous system, as many areas of the brain generate eye movements (Fig 1-28). Saccadic and smooth-pursuit eye movements were once thought to derive from distinct supranuclear pathways; however, it now appears that these systems overlap considerably. In addition, there are 2 major visual pathways: one for the movement of images (magnocellular: M cells) and the other for the discrimination of images (parvocellular: P cells).

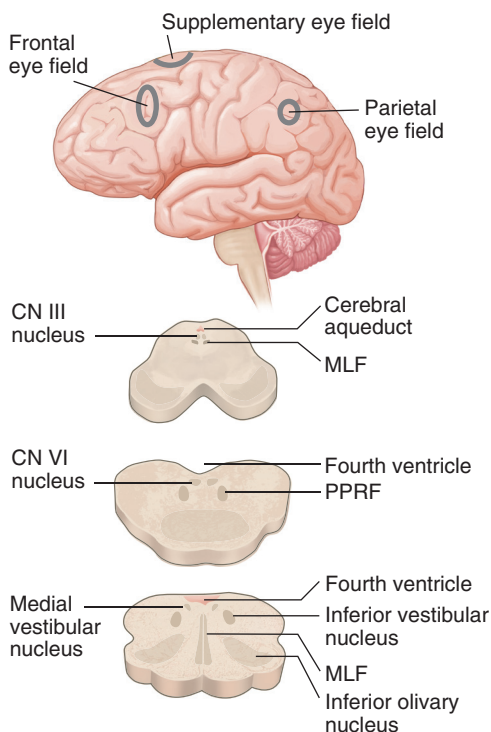
## Saccadic system

The saccadic system comprises the following structures in an organized framework (Fig 1-29):

- cortical structures for volitional/memory-guided saccades: frontal eye fields, supplementary eye fields; visually reflexive saccades, which are generated by various areas of the parietal cortex but mainly from the superior parietal lobe (Brodmann area 7) and parietal eye fields with connections to the SC and frontal and supplementary eye fields
- subcortical structures: the BG, thalamus, and SC
- brainstem neural network or premotor neurons: several types of pontine neurons
- brainstem saccade generators: PPRF and rostral interstitial nucleus of the medial longitudinal fasciculus (riMLF)
- motoneurons of the ocular motor CNs



**Figure 1-28** Overview of the cortical centers that control human eye movements. MT=middle temporal visual area. (Redrawn by Rob Flewell, CMI.)



**Figure 1-29** The saccadic system comprises visually reflexive movements (derived from the parietal eye field) and memory-guided and volitional movements (derived from the frontal eye field). Supplemental eye fields receive input from frontal eye fields and program saccades projecting to the superior colliculus, basal ganglia, and thalamus. Projections are also sent to the paramedian pontine reticular formation (PPRF); rostral interstitial medial longitudinal fasciculus, which is more rostral in the mid-brain; and motoneurons of the ocular motor cranial nerves (CNs). MLF=medial longitudinal fasciculus. (Illustration by Cyndie C. H. Wooley.)

### Smooth-pursuit system

The smooth-pursuit system consists of the following structures (Fig 1-30):

- cortical structures: areas V1, V2, V3, V5 (*middle temporal* visual area), *medial superior temporal* area, posterior parietal cortex, and frontal eye field
- subcortical structure: posterior portion of the internal capsule
- brainstem neural network or premotor neurons: *dorsolateral pontine nuclei* and lateral pontine nuclei
- projections to the cerebellum (flocculus and dorsal vermis) and vestibular nuclei

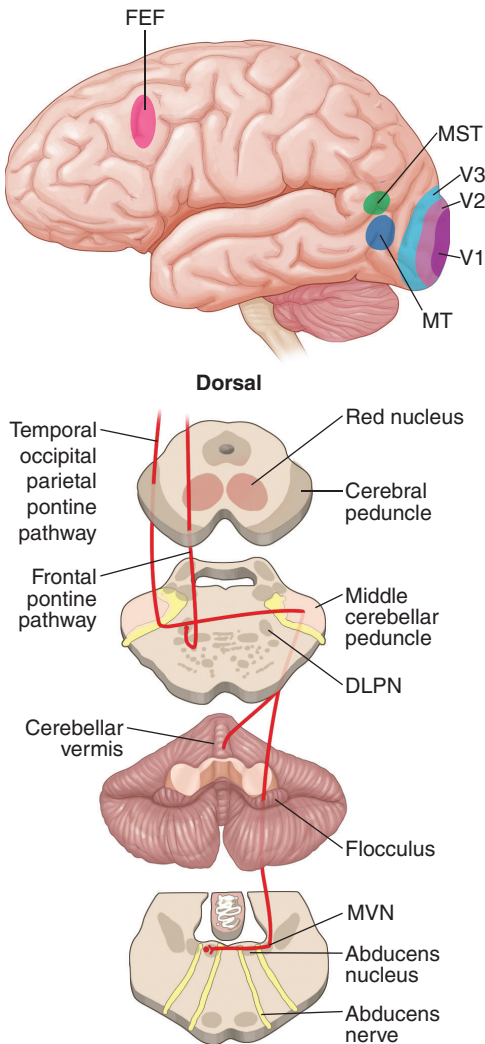
For information on clinical disorders of the pursuit function, see Chapter 9 in this volume.

### Subcortical Structures

Several subcortical structures are involved in relaying information between the cortex and the brainstem for coordination of eye movements:

- SC: divided into 2 parts:
  - *superficial (dorsal)*: receives sensory input from the visual cortex and retina
  - *deep (ventral)*—*stratum griseum profundum* and *stratum album profundum*: generate the motor signal to premotor structures
- BG (*caudate nucleus*, *putamen*, and *substantia nigra pars reticulata*): controls voluntary saccades and inhibits unnecessary reflexive saccades
- thalamus (*internal medullary lamina* and *pulvinar*): programs saccades



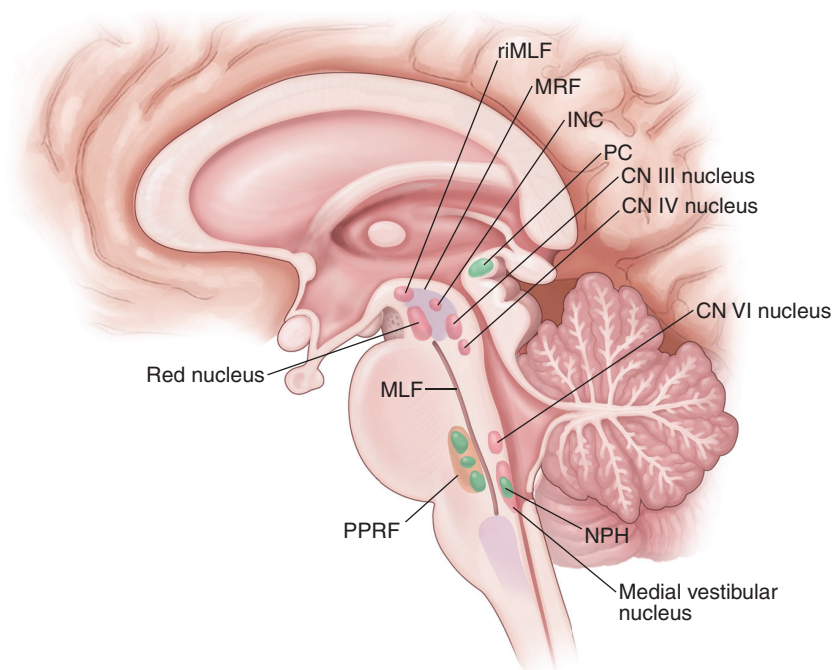


**Figure 1-30** Pursuit system. A moving object creates signals in the striate cortex (V1) and from there to the extrastriate cortex (V2 and V3). These signals are subsequently relayed to the middle temporal (MT) and medial superior temporal (MST) visual areas, which are part of the dorsal visual processing stream, the posterior parietal cortex, and the frontal eye field (FEF). The descending cortical pathways of the temporal, parietal, and frontal lobes innervate the ipsilateral dorsolateral pontine nucleus (DLPN). The neurons in the DLPN decussate and project to the vermis and flocculus in the contralateral cerebellar lobe, which innervates the medial vestibular nucleus (MVN). VN neurons then decussate and project to the contralateral CN VI nucleus. The nucleus of CN VI initiates conjugate horizontal eye movements by innervating the ipsilateral lateral rectus muscle and, via internuclear neurons that travel in the medial longitudinal fasciculus, the contralateral medial rectus muscle. (Illustration by Rob Flewell, CML.)

## Brainstem

The following list of major anatomical structures and their functions lays the foundation for the discussion of pathways for coordinating conjugate eye movements in Chapter 9 (Fig 1-31):

- riMLF: excitatory burst neurons that generate vertical and torsional saccades
- interstitial nucleus of Cajal (INC): inhibitory burst neurons for vertical saccades and the neural integrator for vertical and torsional gaze
- posterior commissure: projecting axons from the INC to the contralateral nuclei of CNs III, IV, and VI and the INC
- medial longitudinal fasciculus (MLF): major pathways for relaying signals within the brainstem and for connecting the nuclei of CN VI to the contralateral nuclei of CN III



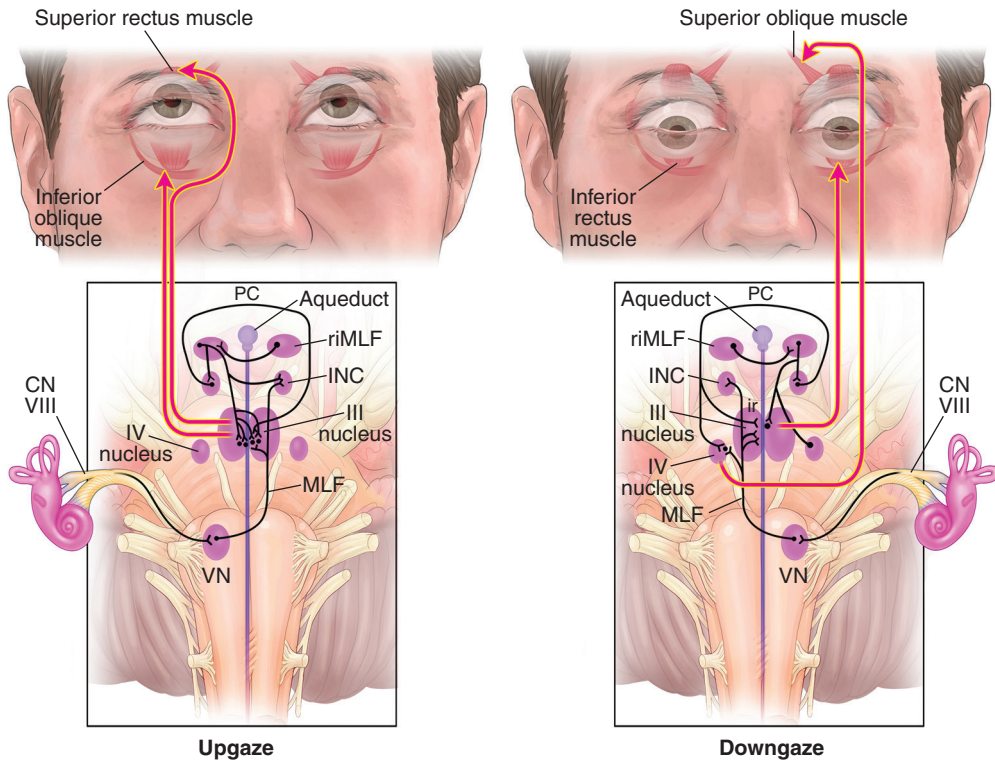
**Figure 1-31** Schematic representation of a sagittal section of the brainstem showing the location of the important structures involved in eye movements. The shaded area indicates the paramedian pontine reticular formation (PPRF). The dorsolateral pontine nucleus (DLPN) is not visible because this illustration is a midsagittal section, and the DLPN is laterally located; it is best visualized on an axial view through the rostral pons. CN=cranial nerve; INC=interstitial nucleus of Cajal; MLF=medial longitudinal fasciculus; MRF=mesencephalic reticular formation; NPH=nucleus prepositus hypoglossi; PC=posterior commissure; riMLF=rostral interstitial nucleus of the MLF. (Illustration by Rob Flewell, CMI.)

- dorsolateral pontine nuclei: neurons for smooth pursuit
- nucleus prepositus hypoglossi-medial vestibular nucleus: neural integrator for horizontal gaze
- PPRF: excitatory burst neurons that generate horizontal saccades and inhibitory burst neurons that suppress horizontal saccades
- CNs III, IV, and VI: neurons that project directly to EOMs
- vestibular nuclei (CN VIII): neurons that project vestibular information to saccade generators and ocular motor CNs (Figs 1-32, 1-33)

### ***Vestibular ocular system (vestibular ocular reflex)***

The vestibular nuclei provide major supranuclear input into ocular motility and tonic input into eye positioning.

- The *vestibular nerve* and *cochlear nerve* form the CN VIII complex and exit the petrous bone through the internal auditory meatus.
- CN VIII traverses the subarachnoid space within the cerebellopontine angle to *medial, lateral, and superior vestibular nuclei* in the medulla.



**Figure 1-32** Anatomical schemes for the synthesis of vertical eye movements. From the vertical semicircular canals, primary afferents from CN VIII synapse on the vestibular nuclei (VN) and ascend into the medial longitudinal fasciculus (MLF) and brachium conjunctivum (not shown) to the CN III and CN IV nuclei and the interstitial nucleus of Cajal (INC). Excitatory burst neurons in the rostral interstitial nucleus of the MLF (riMLF) project to the motoneurons of CNs III and IV and send axon collaterals to the INC. III nucleus=oculomotor nerve (CN III) nucleus; IV nucleus=trochlear nerve (CN IV) nucleus; PC=posterior commissure. (Illustration by Rob Flewell, CMI.)

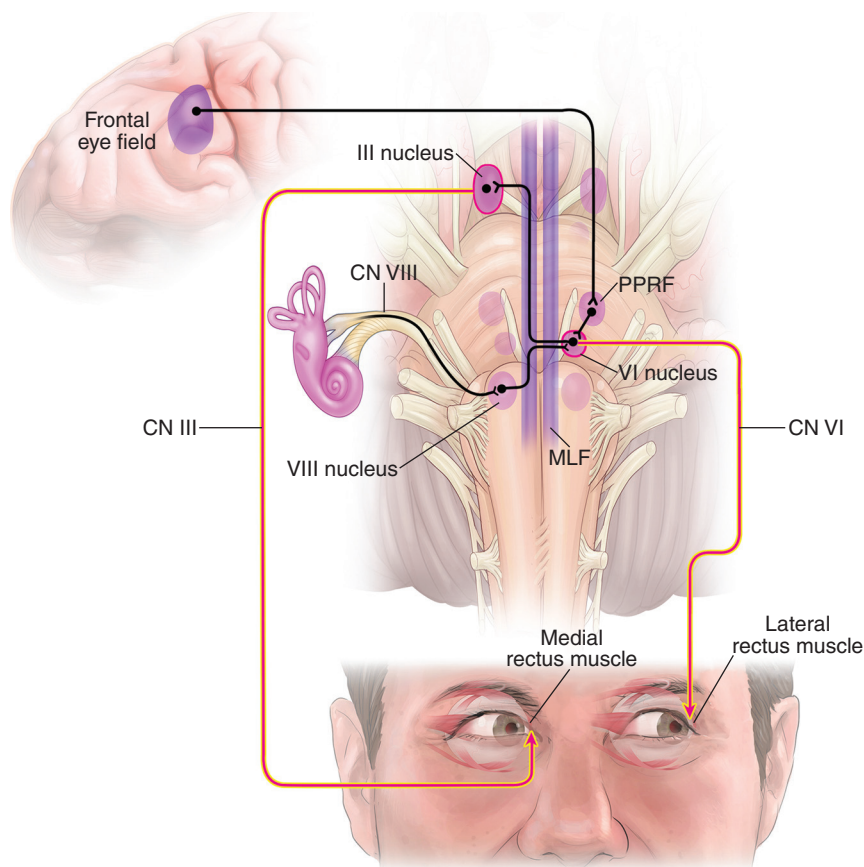
- The medial and inferior vestibular nuclei project to the *nodulus* (a central nucleus of the cerebellum) and the *ventral uvula*.

For information on clinical disorders of vestibular-ocular function, see Chapter 9.

### Ocular Motor Cranial Nerves

Without neural activity, the visual axes are usually mildly to moderately divergent. The major tonic input to ocular motility is supplied by 3 pairs of ocular motor CNs—III, IV, and VI—that innervate the 6 EOMs controlling ocular movement (Fig 1-34). In addition, CN III innervates the levator palpebrae superioris and the pupillary sphincter muscles.

Except for the inferior oblique muscle, the innervation of the EOMs occurs at approximately one-third of the distance from the apex. The inferior oblique muscle receives innervation at approximately its midpoint from a neurovascular bundle running parallel to the lateral aspect of the inferior rectus muscle. Except for the superior oblique muscle,



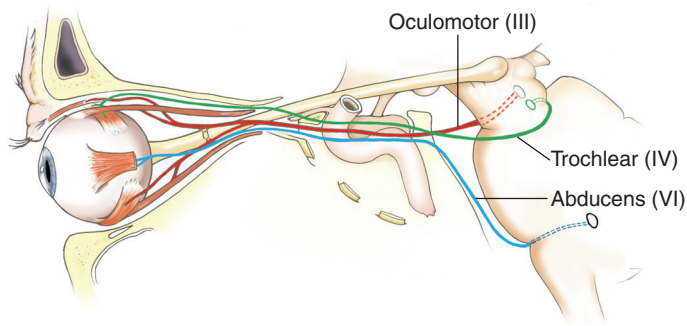
**Figure 1-33** Anatomical scheme for the synthesis of horizontal eye movements. From the horizontal semicircular canal, primary afferents of the vestibular nerve (CN VIII) project mainly to neurons of the vestibular nerve nucleus (VIII nucleus), which then send an excitatory connection to the contralateral CN VI nucleus. CN VI innervates the ipsilateral lateral rectus muscle and the contralateral CN III nucleus via the medial longitudinal fasciculus (MLF). Horizontal saccades are generated in the frontal eye field, which activates the contralateral paramedian pontine reticular formation (PPRF). Burst neurons in the PPRF stimulate the ipsilateral CN VI nucleus, with the subsequent pathway identical to that subserving horizontal vestibular-generated eye movements. Some neurons in the PPRF project to the nucleus prepositus hypoglossi-medial vestibular nucleus (neural integrator) and then to the CN VI nucleus. (Illustration by Rob Flewell, CML.)

all EOMs receive their innervation on the inside surface. The branches of CN IV terminate on the upper (outer) surface of the muscle.

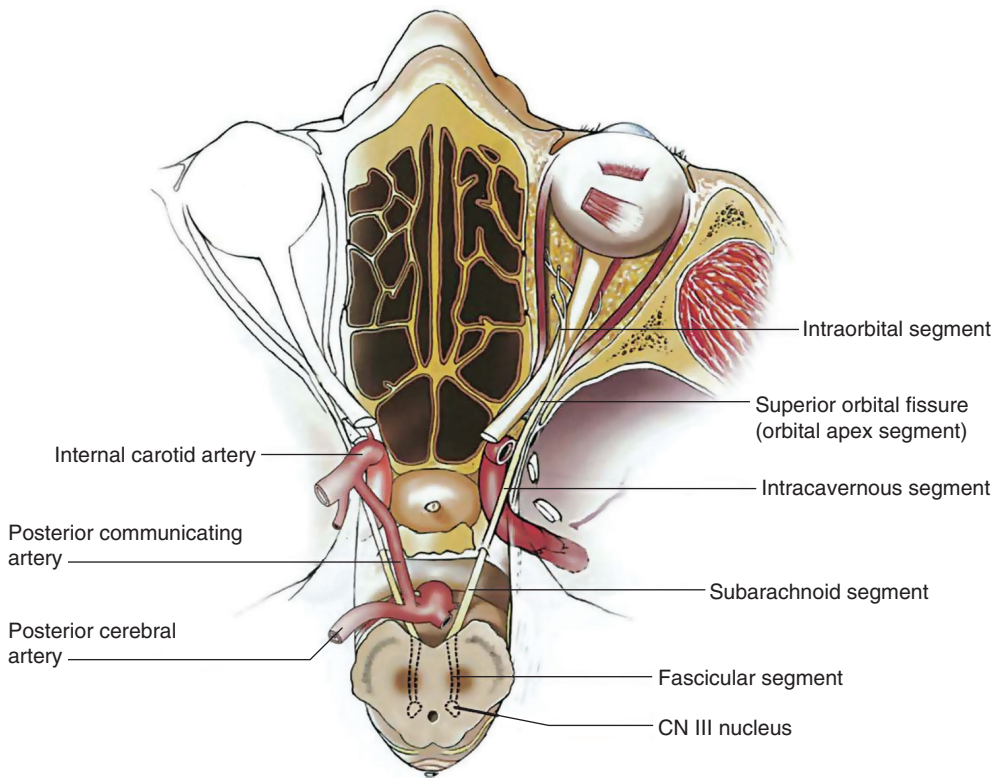
See Chapter 8 for information on the clinical presentation of disorders due to infra-nuclear, fascicular, and peripheral ocular motor CN lesions.

### **Third cranial nerve**

The CN III (oculomotor) nucleus is located dorsally within the midbrain ventral to the aqueduct connecting the third and fourth ventricles (Fig 1-35). The nuclear complex itself



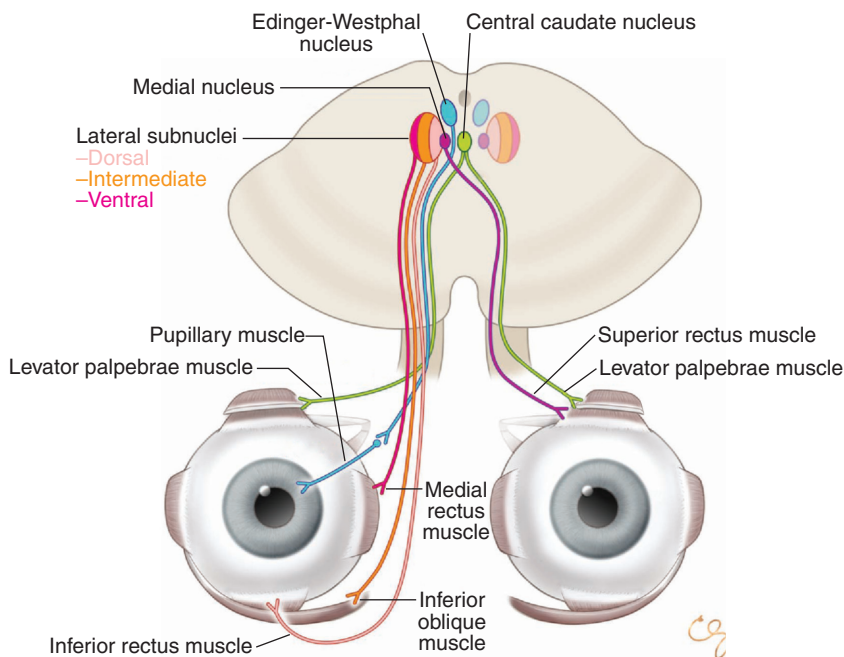
**Figure 1-34** Lateral view of the course of CNs III, IV, and VI. (Illustration by Dave Peace.)



**Figure 1-35** Illustration of the axial course of CN III from its origin in the midbrain. (Reprinted from Foroozan R, Bhatti MT, Rhoton AL. Transsphenoidal diplopia. *Surv Ophthalmol.* 2004;49(3):352; with permission from Elsevier.)

represents a collection of subnuclei that have specific identifiable functions (Fig 1-36). The fibers destined to innervate the medial rectus, inferior rectus, inferior oblique, pupil sphincter, and ciliary body muscles exit ventrally ipsilateral to the individual nuclei from





**Figure 1-36** Oculomotor nucleus complex. Note that with the exception of the superior rectus muscle, all extraocular muscles served by CN III are innervated by their respective ipsilateral nuclei. Parasympathetic fibers travel to the pupillary sphincter muscle synapse in the ciliary ganglion in the orbit (see Fig 1-47). (Illustration by Christine Gralapp.)

which they originate. In contrast, the fibers from the medial subnucleus, which lies along the midline, cross before exiting the brainstem to innervate the contralateral superior rectus muscle. The central caudate nucleus provides innervation to the levator palpebrae superioris bilaterally. A nuclear CN III lesion can cause an ipsilateral CN III palsy with possible additional limitation of supraduction of the contralateral eye and/or bilateral ptosis depending on which subnuclei are affected.

Within the midbrain, CN III is topographically organized into a superior division (supplying the superior rectus and levator palpebrae superioris muscles) and an inferior division (supplying the medial and inferior rectus, inferior oblique, pupillary sphincter, and ciliary body muscles). However, the true anatomical division into 2 branches occurs at the level of the anterior cavernous sinus/superior orbital fissure (discussed in a following paragraph).

The fascicles of CN III traverse the ventral midbrain tegmentum, passing near and possibly through the red nucleus, the substantia nigra, and the corticospinal tracts within the cerebral peduncle. The fascicles exit on the ventral surface of the peduncles (see Fig 1-35). Although CN III is considered a single structure within the subarachnoid space, as is the case in the midbrain, the nerve and its various fibers are topographically

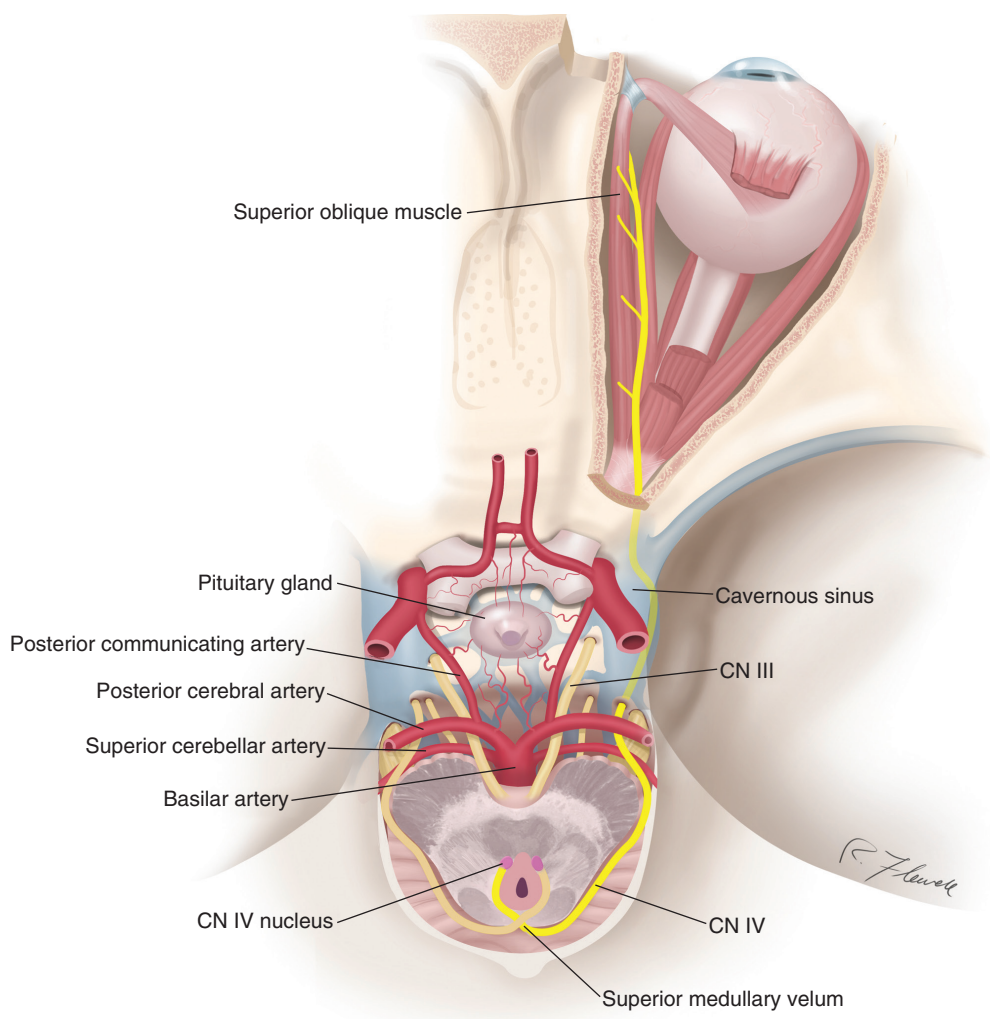
organized. Within the subarachnoid space, the nerve passes between the SCA below and the PCA above. It runs slightly oblique to the tentorial edge, parallel and lateral to the PCoA. The pupillary fibers are usually found on the dorsomedial surface of the nerve, where they are anatomically vulnerable to compression. The *uncus*, which is the most medial aspect of the temporal lobe, is located just above the tentorium and the subarachnoid portion of CN III. Unilateral supratentorial mass lesions may force the uncus through the tentorial notch (uncal herniation) to compress the ipsilateral CN III.

At the back edge of the dura of the clivus and cavernous sinus, the nerve enters its own dural canal just above CN IV (see Fig 1-35). Running forward in the superior lateral wall of the cavernous sinus, the nerve separates into 2 divisions: superior and inferior. These divisions enter the orbit through the superior orbital fissure within the annulus of Zinn. The superior division runs forward intraconally to innervate first the superior rectus muscle and then the levator palpebrae superioris muscle. The inferior division sends parasympathetic fibers to the ciliary ganglion in the orbital apex approximately 10 mm anterior to the annulus of Zinn and lateral to the optic nerve. Within the ciliary ganglion, the fibers destined for the pupillary sphincter and the ciliary body synapse. The fibers subsequently accompany the branch destined for the inferior oblique muscle. The number of fibers associated with accommodation innervating the ciliary body is approximately 9 or 10 times the number of fibers reaching the pupillary sphincter muscle. This disparity may be one reason for the development of light–near dissociation in Adie pupil (see Chapter 11). The remaining branches of CN III within the orbit innervate the medial rectus and inferior rectus muscles.

#### **Fourth cranial nerve**

The CN IV (trochlear) nucleus lies within the gray matter in the dorsal aspect of the caudal midbrain just below the aqueduct, directly contiguous with the more rostral CN III nucleus (Fig 1-37). The intra-axial portion (fascicle) of CN IV is very short, running dorsally around the periaqueductal gray to cross within the anterior medullary velum just caudal to the inferior colliculi and below the pineal gland. CN IV is the only CN that exits on the dorsal surface of the brainstem, and it has the longest unprotected intracranial course (which is likely responsible for its frequent involvement in closed-head trauma). Within the subarachnoid space, CN IV swings around the midbrain, paralleling the tentorium just under the tentorial edge. As a result, CN IV is easily damaged during neurosurgical procedures that involve the tentorium.

The fourth CN enters the posterior lateral aspect of the cavernous sinus below the anterior tentorial insertion and underneath CN III. Covered by a variable sheath, CN IV runs forward within the lateral wall of the cavernous sinus. Anteriorly, the nerve crosses over CN III to enter the superior orbital fissure. Along with the frontal and lacrimal nerves of CN V and the SOV, CN IV passes through the superior orbital fissure but outside the annulus of Zinn. CN IV subsequently crosses over the optic nerve to enter the superior oblique muscle within the superior medial orbit.



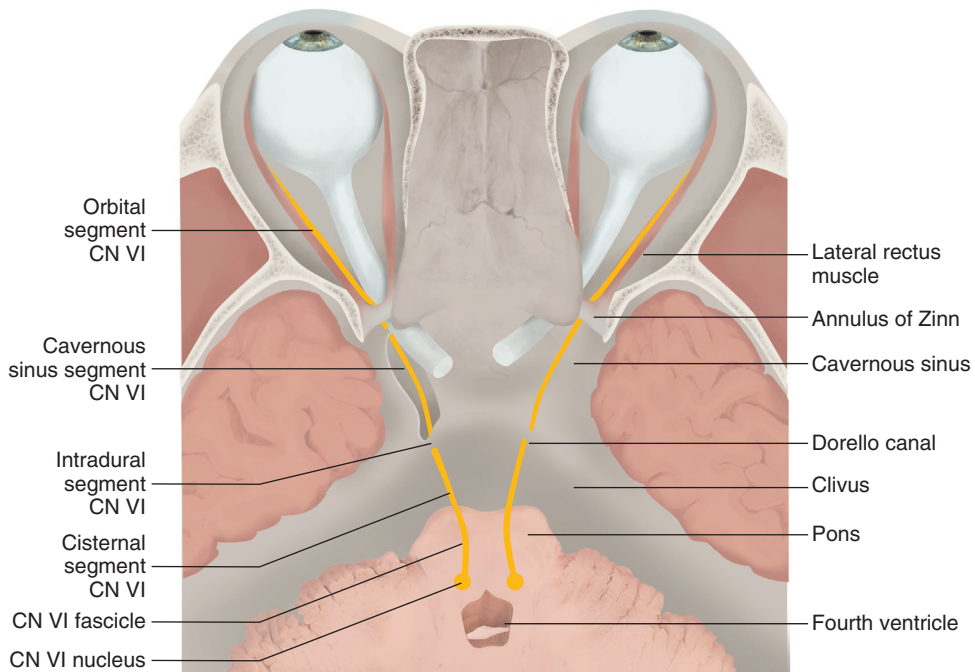
**Figure 1-37** Illustration of the axial course of CN IV from its origin in the midbrain to the superior oblique muscle. (Reprinted from Al-Zubidi N, Chevez-Barrios P, Foroozan R, Bhatti MT. My eyes are turned outside. *Surv Ophthalmol.* 2014;59(3):356, with permission from Elsevier.)

### **Sixth cranial nerve**

Cranial nerve VI (abducens nerve) originates in the dorsal caudal pons just beneath the fourth ventricle. Its nucleus is surrounded by the looping fibers (genu) of CN VII and adjacent to the PPRF and the MLF (Fig 1-38). The CN VI nucleus contains primary motoneurons and interneurons that cross to the contralateral MLF to reach the CN III nucleus. Pathology affecting the CN VI nucleus produces an ipsilateral gaze palsy.

The motor axons exiting the CN VI nucleus travel ventrally and slightly laterally, medial to the superior olivary nucleus, emerging on the ventral surface of the caudal pons. As the fascicles pass through the brainstem, they lie adjacent to the spinal tract of CN V



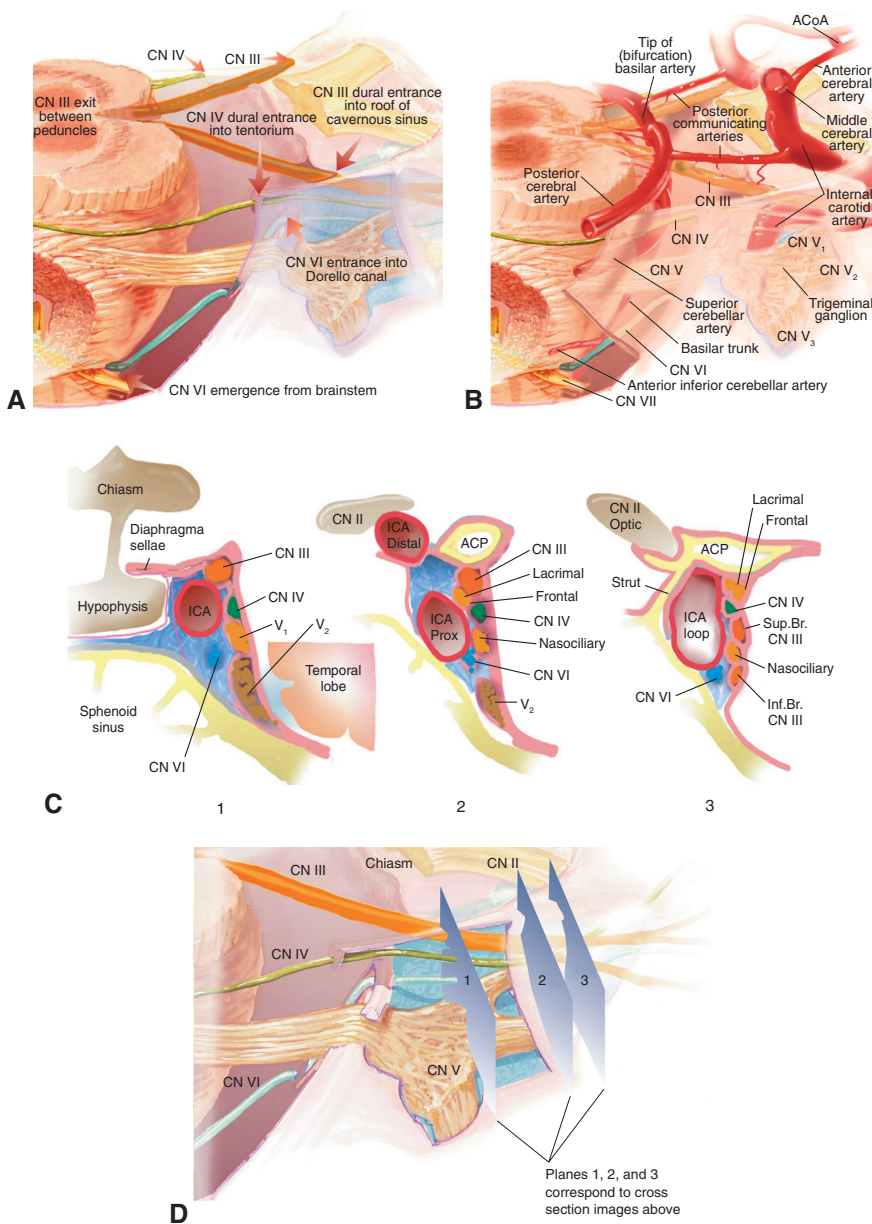


**Figure 1-38** Illustration of the axial course of CN VI from its origin in the pons to the lateral rectus muscle. (Illustration by Cyndie C. H. Wooley.)

and traverse the corticobulbar tracts. Exiting the brainstem, the nerve runs rostrally within the subarachnoid space on the surface of the clivus from the area of the cerebellopontine angle to the superior portion of the posterior fossa. The nerve pierces the dura approximately 1 cm below the petrous apex and travels beneath the petroclinoid ligament (the Gruber ligament, which connects the petrous pyramid to the posterior clinoid) to enter the canal of Dorello. Within the canal, CN VI travels with the inferior petrosal sinus. Once it becomes extradural, the nerve is within the cavernous sinus, where it runs parallel to the horizontal segment of the carotid artery and CN V<sub>1</sub> (Fig 1-39). CN VI is the only CN within the substance of the cavernous sinus; ipsilateral CN VI palsy and Horner syndrome localize here as the nerve is joined for a short segment by branches of the oculosympathetics lying within the wall of the intrapetrous carotid artery. Reaching the anterior portion of the cavernous sinus, CN VI traverses the superior orbital fissure through the annulus of Zinn (see Fig 1-5) to enter the medial surface of the lateral rectus muscle.

### CLINICAL PEARL

Lesions of the clivus can cause unilateral or bilateral CN VI palsies.



**Figure 1-39** Anatomical relationships of the ocular motor nerves. **A**, Subarachnoid course of the ocular motor nerves. Note their relationship to the surrounding dural structures, particularly the tentorium (partially removed to visualize CNs) and the dura of the clivus. CN III enters the dural canal at the posterior aspect of the cavernous sinus, CN IV enters at the tentorial edge, and CN VI enters along the clivus. **B**, Major blood vessels and their relationships to the ocular motor nerves. Note the passage of CN III between the superior cerebellar artery below and the posterior cerebellar artery above. CN VI runs by the anterior inferior cerebellar artery, which is a major branch off the basilar artery. **C**, Intracavernous course of the ocular motor nerves. CNs III and IV run in the lateral wall of the cavernous sinus along with CN V divisions V<sub>1</sub> and V<sub>2</sub>. CN VI runs close to the carotid artery within the cavernous sinus itself. **D**, As the nerves course toward the anterior aspect of the cavernous sinus and the superior orbital fissure, the ophthalmic branch of CN V (CN V<sub>1</sub>) divides into 3 branches: the lacrimal, frontal, and nasociliary nerves. ACoA = anterior communicating artery; ACP = anterior clinoid process; ICA = internal carotid artery; Inf. Br. = inferior branch; Prox = proximal; Sup. Br. = superior branch. (Illustrations by Craig A. Luce.)

## Extraocular Muscles

The final common pathways that influence the position of the eye within the orbit are the numerous soft-tissue elements connected to the globe. In addition to the EOMs, these tissues include the optic nerve, Tenon capsule, blood vessels, and the conjunctiva anteriorly. (For a discussion of orbital anatomy, see BCSC Section 7, *Oculofacial Plastic and Orbital Surgery*.)

Of the 6 EOMs, 4 are *rectus muscles* (lateral, medial, superior, and inferior), and 2 are oblique muscles (superior and inferior). The rectus muscles originate—along with the levator palpebrae superioris muscle—at the annulus of Zinn, a condensation of tissue around the optic nerve at the orbital apex. They run forward within sheaths that are connected by intermuscular septa to pierce the posterior Tenon capsule and insert on the anterior sclera at points variably posterior to the corneal limbus, increasing from the medial through the inferior and lateral to the superior insertion (*spiral of Tillaux*). The rectus muscles are also held in position by septal attachments to the orbital periosteum, which act as pulleys.

The 2 *oblique muscles* insert on the posterior lateral aspect of the globe. The inferior oblique muscle originates in the anteromedial periorbital area near the posterior margin of the lacrimal fossa. The effective origin of the superior oblique muscle is the trochlea, a pulley-like structure located at the notch in the superior medial orbit. The superior oblique muscle runs anteriorly in the superior medial orbit to the trochlea, where its tendon's direction of action is reversed.

The EOMs have variable mass and cross section. The superior oblique is the thinnest, and the medial rectus is the largest. Thus, with normal tonic innervation, the somewhat stronger medial rectus reduces divergent phoria. With the exception of the medial and lateral rectus muscles, the EOMs have primary, secondary, and tertiary functions that vary depending on the position of gaze (Fig 1-40). For further discussion and illustration of the EOMs and their actions, see BCSC Section 6, *Pediatric Ophthalmology and Strabismus*. Also see Chapter 8 for the clinical etiologies of EOM dysfunction.

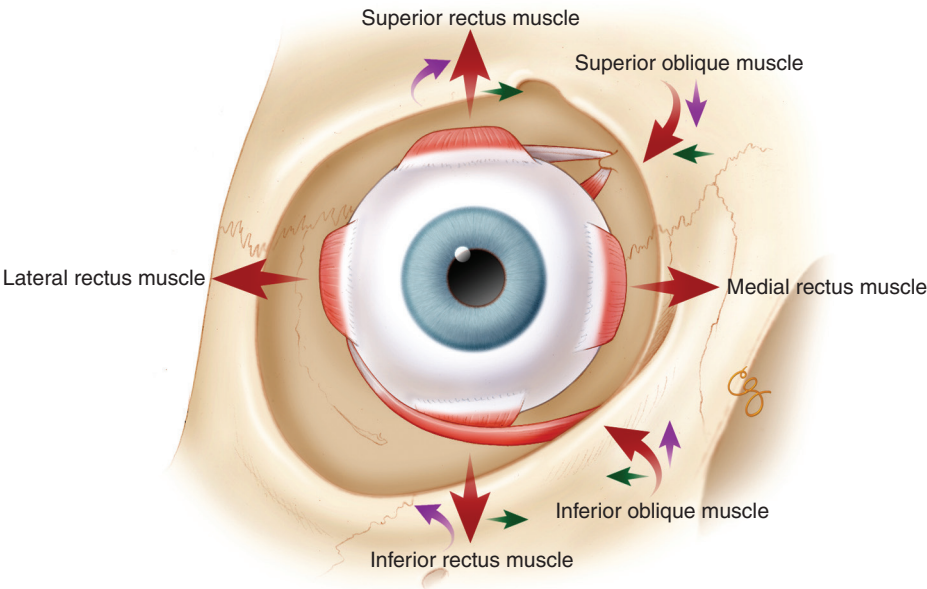
## Sensory and Facial Motor Anatomy

---

Cranial nerves V and VII contribute significantly to normal ophthalmic function and are frequently involved in neuro-ophthalmic disorders. Proper functioning of CN V preserves corneal sensation, loss of which may be accompanied by abnormal corneal epithelial growth (neurotrophic keratitis associated with loss of neural secreted growth factors). A functioning CN VII prevents exposure keratopathy. Dysfunction of both CNs V and VII greatly increases the risk of corneal damage.

### Fifth Cranial Nerve

The sensory nerve, CN V (trigeminal nerve), terminates within the *trigeminal nucleus*. The nuclear complex of CN V extends from the midbrain to the cervical spinal cord.



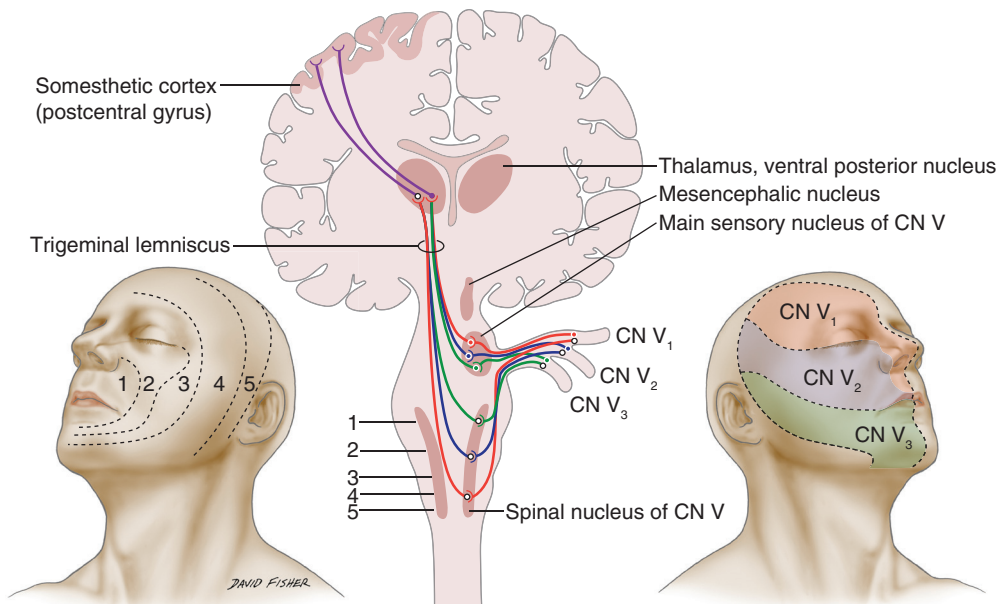
<u>Muscle</u>	<u>Primary</u>	<u>Secondary</u>	<u>Tertiary</u>
Medial rectus	Adduction		
Lateral rectus	Abduction		
Inferior rectus	Depression	Extorsion	Adduction
Superior rectus	Elevation	Intorsion	Adduction
Inferior oblique	Extorsion	Elevation	Abduction
Superior oblique	Intorsion	Depression	Abduction

**Figure 1-40** Primary, secondary, and tertiary functions of the extraocular muscles, right eye. (Illustration by Christine Gralapp.)

The following sensory nuclei are included within the CN V nuclear complex:

- *main sensory nucleus*: located within the pons lateral to the motor nucleus; it receives light-touch information from the skin of the face and mucous membranes
- *mesencephalic nucleus*: serves proprioception and deep sensation from the facial muscles, including the EOMs and the muscles of mastication (temporalis, pterygoid, and masseter)
- *spinal nucleus*: extends caudally to the level of C4 vertebra; it receives pain and temperature sensation and cutaneous sensory information

Damage to the spinal nucleus of CN V (eg, a brainstem lesion) causes bilateral sensory loss in concentric rings of the face, whereas peripheral sensory loss is unilateral and assumes the pattern of the ophthalmic, maxillary, or mandibular divisions of the trigeminal nerve (Fig 1-41).



**Figure 1-41** Diagram of the central pathways and peripheral innervation of CN V. The numbers 1–5 indicate the location of dermatomes on the face and their corresponding representation in the brainstem. (Used with permission from Kline LB. *Neuro-Ophthalmology Review Manual*. 6th ed. Slack; 2008:174. Illustration by David Fisher).

The various sensory nuclei of CN V project to the contralateral thalamus and from there to the postcentral gyrus. The oculocardiac reflex is mediated by the trigeminal nerve (afferent limb) and parasympathetic output of the vagus nerve (efferent limb).

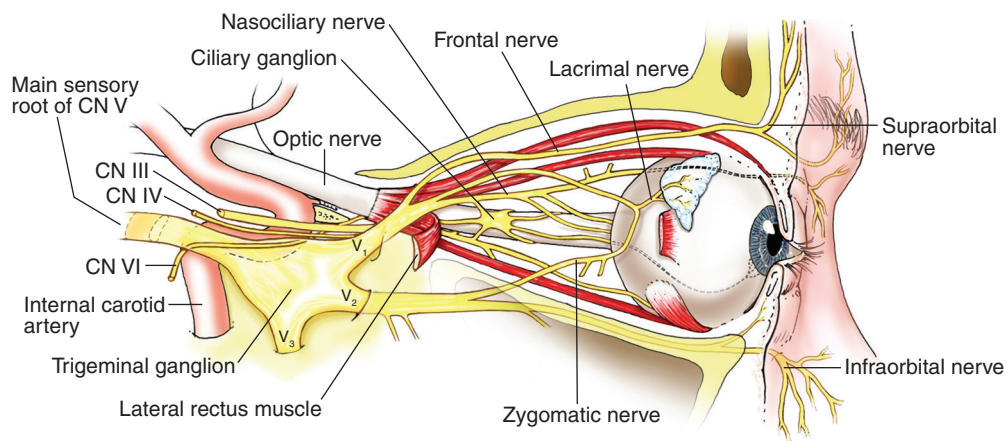
Medial to the main sensory nucleus, the *motor nucleus* of CN V lies in the pons. The motor nucleus sends signals to the muscles of mastication, the *tensor tympani* (which reflexively dampens loud noises by tensing the tympanic membrane within the middle ear), the *tensor veli palatini* (which orients the uvula), the mylohyoid, and the anterior belly of the digastric muscle.

The fascicles of CN V enter the brainstem ventrally in the pons and extra-axially traverse the subarachnoid space to penetrate the dura just over the petrous pyramid. Within the subarachnoid space, the trigeminal root often comes in contact with the SCA. This proximity may be a cause of trigeminal neuralgia (atypical facial pain, discussed in Chapter 13) and is the anatomical basis for microvascular decompression. The 3 divisions of CN V synapse in the trigeminal (gasserian) ganglion (Fig 1-42), located in an extradural space at the floor of the middle cranial fossa (Meckel cave).

### **Ophthalmic division**

The ophthalmic division (CN V<sub>1</sub>) is the most anterior branch of CN V exiting the trigeminal ganglion. It runs forward within the lateral wall of the cavernous sinus just below CN IV. As it approaches the superior orbital fissure extradurally, it divides into 3 major branches: *lacrimal*, *frontal*, and *nasociliary*. In addition, small branches innervate the dura of the anterior





**Figure 1-42** Lateral view of the orbit, showing its sensory nerves. (Illustration by Dave Peace.)

middle cranial fossa, including the cavernous sinus, the parasellar region, the tentorium, and the dura of the petrous apex. These branches also innervate the floor of the anterior cranial fossa, including the falx cerebri and the major blood vessels at the skull base.

The lacrimal and frontal nerves enter the orbital apex outside the annulus of Zinn. At its terminus, the frontal nerve divides into supraorbital and supratrochlear branches, which innervate the forehead, frontal sinus, and upper eyelid (including the conjunctiva). The lacrimal nerve also runs anteriorly in the superior lateral orbit slightly above the lateral rectus to innervate the lacrimal gland and the skin just superotemporal to the orbit. The nasociliary nerve is the only branch that enters the intraconal space through the annulus of Zinn. The nasociliary branch runs through the ciliary ganglion and anteriorly to innervate the globe through the short and long posterior ciliary nerves. Before reaching the globe, branches from the nasociliary division pass through the anterior and posterior ethmoidal foramina to innervate part of the ethmoid sinuses, the lateral wall of the nose, and the skin of the nose to the nasal tip. The co-innervation of the globe and the nasal skin explains the development of Hutchinson sign (vesicles on the tip or side of the nose) in patients with herpes zoster ophthalmicus.

### **Maxillary division**

The maxillary division (CN V<sub>2</sub>) runs forward at the inferior lateral base of the cavernous sinus to enter the foramen rotundum, located just below the superior orbital fissure. Before entering the canal, CN V<sub>2</sub> gives off the middle meningeal nerve, which supplies the dura of the lateral middle cranial fossa. On the anterior end of the foramen rotundum, CN V<sub>2</sub> enters the pterygomaxillary area. This division provides sensation to the cheek as well as the lower eyelid and upper teeth and gums.

Sensory nerve CN V<sub>2</sub> has several other branches:

- Two large *pterygopalatine nerves* supply sensation to the nasopharynx, hard and soft palate, and portions of the nasal cavity.
- The *posterior alveolar nerves* supply sensation to the upper gums and molars.



- The *zygomatic nerve* enters the orbit through the inferior orbital fissure and divides into the *zygomaticofacial* and *zygomaticotemporal* nerves, which supply sensation to the lateral face.
- The maxillary nerve continues anteriorly within a canal between the orbit above and the maxillary sinus below to exit through the infraorbital foramen as the *infraorbital nerve* just below the inferior orbital rim. It subsequently divides into the palpebral, nasal, and labial branches.

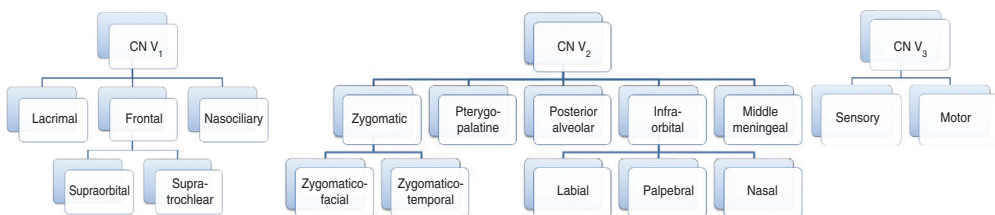
### Mandibular division

The mandibular division (CN V<sub>3</sub>) enters through the foramen ovale, lateral to the foramen lacerum and medial to the foramen spinosum (carrying the middle meningeal artery). CN V<sub>3</sub> innervates the skin of the jaw and carries the motor division of CN V to the muscles of mastication and the neck. Motor paralysis of CN V results in contralateral deviation of the jaw when it is closed (due to weakness of the ipsilateral temporalis) and ipsilateral deviation when protruded (due to weakness in the lateral pterygoid) (Fig 1-43).

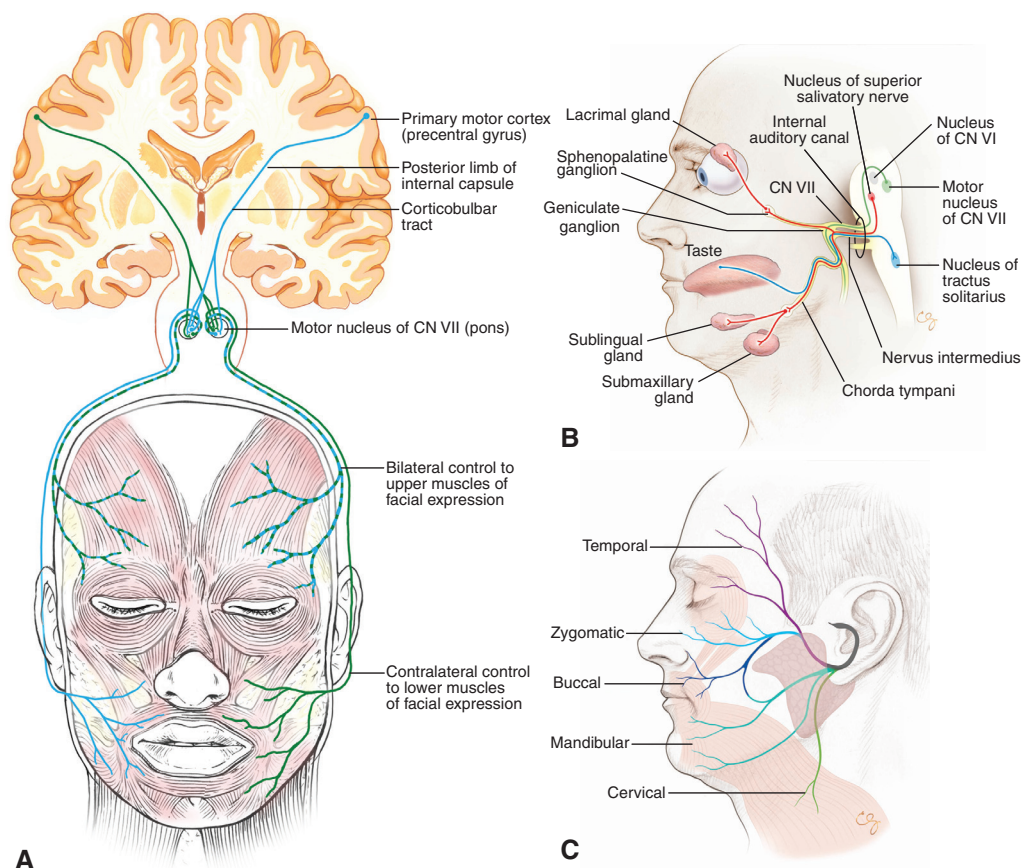
### Seventh Cranial Nerve

Cranial nerve VII, the facial nerve, is responsible for movement of the facial muscles. Voluntary facial movements, along with other motor activity, originate in the precentral gyrus. White matter tracts pass through the internal capsule and cerebral peduncles along with the other corticobulbar fibers. The motoneurons destined for the upper face receive bilateral innervation, whereas the lower facial musculature receives information only from the contralateral cortex (Fig 1-44). A central or upper motor neuron CN VII palsy causes contralateral lower facial weakness, whereas a peripheral or lower motor neuron CN VII palsy causes ipsilateral upper and lower facial weakness.

The motor fibers of the CN VII nucleus originate in the tegmentum of the caudal pons, ventrolateral to the CN VI nucleus and medial to the spinal nucleus of CN V. The dorsal subnucleus receives bilateral innervation and supplies the upper face; the lateral subnucleus (contralateral innervation) supplies the lower face. The CN VII nucleus receives additional information from BG extrapyramidal connections, which are largely responsible for involuntary blinking. Abnormal blinking, as present in BG disorders such as Parkinson disease, is probably mediated through altered inhibition of supranuclear control of the blink reflex.



**Figure 1-43** The divisions of the trigeminal nerve. (Courtesy of Zoë R. Williams, MD.)



**Figure 1-44** Supranuclear, nuclear, and infranuclear anatomy of the facial nerve (CN VII). **A**, The corticobulbar fibers travel through the internal capsule down into the medial one-third of the corticospinal tracts in the cerebral peduncles of the midbrain. The pathways for the upper one-third of facial function (brow and orbicularis muscles) run parallel to but apparently distinct from the pathways for the lower two-thirds along the pyramidal tracts. The corticobulbar fibers travel in the basis pontis; those that control the lower facial muscles decussate at the level of the pons to synapse on the contralateral CN VII nucleus. Corticobulbar fibers that control the upper facial muscles decussate to synapse on the contralateral CN VII nucleus, and some of the fibers do not cross, reaching the ipsilateral CN VII nucleus. **B**, CN VII is predominantly motor in function, with its nucleus located in the caudal pons. CN VII courses dorsomedially and encircles the nucleus of CN VI. After bending around the CN VI nucleus, CN VII exits the pons in the cerebellopontine angle close to CNs V, VI, and VIII. CN VIII, the motor root of CN VII, and the nervus intermedius, the sensory and parasympathetic root of CN VII, enter the internal auditory meatus. Sensory cells located in the geniculate ganglion continue distally as the chorda tympani nerve, which carries taste fibers. Peripheral fibers of the nervus intermedius portion of CN VII initiate salivary, lacrimal, and mucous secretions. **C**, After emerging from the parotid gland, CN VII innervates the muscles of facial expression via 5 peripheral branches. (Part A reprinted from Bhatti MT, Shiffman JS, Pass AF, Tang RA. *Neuro-ophthalmologic complications and manifestations of upper and lower motor neuron facial paresis*. *Curr Neurol Neurosci Rep*. 2010;10(6):448–458, with permission from Springer. Part A illustration by Dave Pearce; parts B and C illustrations by Christine Galapp.)

The fascicles of CN VII pass dorsomedially to surround the CN VI nucleus, creating a bump on the floor of the fourth ventricle (the genu of CN VII intra-axially and the colliculus of CN VII on the floor of the fourth ventricle). CN VII exits the ventrolateral surface of the pons along with fascicles of the *nervus intermedius*, which contains the facial nerve sensory fibers and the visceral efferent fibers (see the section Parasympathetic Pathways later in this chapter). The subarachnoid portion of the nerve runs anteriorly and laterally to enter the internal auditory meatus along with CN VIII.

Within the petrous bone, CN VII enters the fallopian canal and traverses 3 segments (the labyrinthine, the tympanic, and the mastoid) that run close to the semicircular canals.

CN VII has both sensory and motor functions that are subserved by the following branches in this region:

- The parasympathetic fibers destined for the lacrimal gland separate from CN VII in the region of the geniculate ganglion to accompany the *greater superficial petrosal nerve* (Fig 1-45).
- The *stapedial nerve* enters the pyramidal eminence to innervate the stapedius muscle.
- The *chorda tympani* conducts parasympathetic innervation to the submaxillary gland and afferent fibers from the anterior two-thirds of the tongue. These special afferent fibers are responsible for taste in the anterior tongue and synapse in the geniculate ganglion.

The main branch of CN VII exits the stylomastoid foramen just behind the styloid process at the base of the mastoid. The extracranial trunk of the nerve passes between the superficial and deep lobes of the parotid gland, where it divides into 2 trunks: the *temporofacial* superiorly and the smaller *cervicofacial* inferiorly. These usually divide into 5 major sub-branches:

- temporal
- zygomatic
- buccal
- mandibular
- cervical

The temporal and zygomatic branches laterally innervate the orbicularis oculi muscles. Infraorbital and buccal branches may also variably contribute to the inferior orbicularis (see Fig 1-44). Ophthalmologists are sometimes concerned about encountering branches of CN VII, particularly when performing a temporal artery biopsy or during orbital or lacrimal surgery.

## Eyelids

The muscles of the eyelids are divided into 2 components: *orbital* (responsible for forced closure) and *palpebral*. The palpebral muscles are further separated into pretarsal (predominantly intermediate fast-twitch fibers responsible for normal blinks) and preseptal muscles. This separation occurs at the upper eyelid crease, approximately 6–7 mm above the eyelid margin. The upper eyelid crease represents the attachments of the levator aponeurosis to the pretarsal orbicularis muscle and skin. Closure of the eyelids is marked by

increased activity of the orbicularis muscle and inhibition of the levator palpebrae superioris muscle. The balance of tonic orbicularis and active levator activity determines the amount of eyelid opening.

For discussion of eyelid abnormalities encountered in neuro-ophthalmic practice, see Chapter 12. For further discussion of eyelid anatomy, including illustrations, see BCSC Section 7, *Oculofacial Plastic and Orbital Surgery*.

Harnsberger HR, Osborn AG, MacDonald AJ, Ross JS. *Diagnostic and Surgical Imaging Anatomy: Brain, Head & Neck, Spine*. Amirsys Inc; 2009.

## Ocular Autonomic Pathways

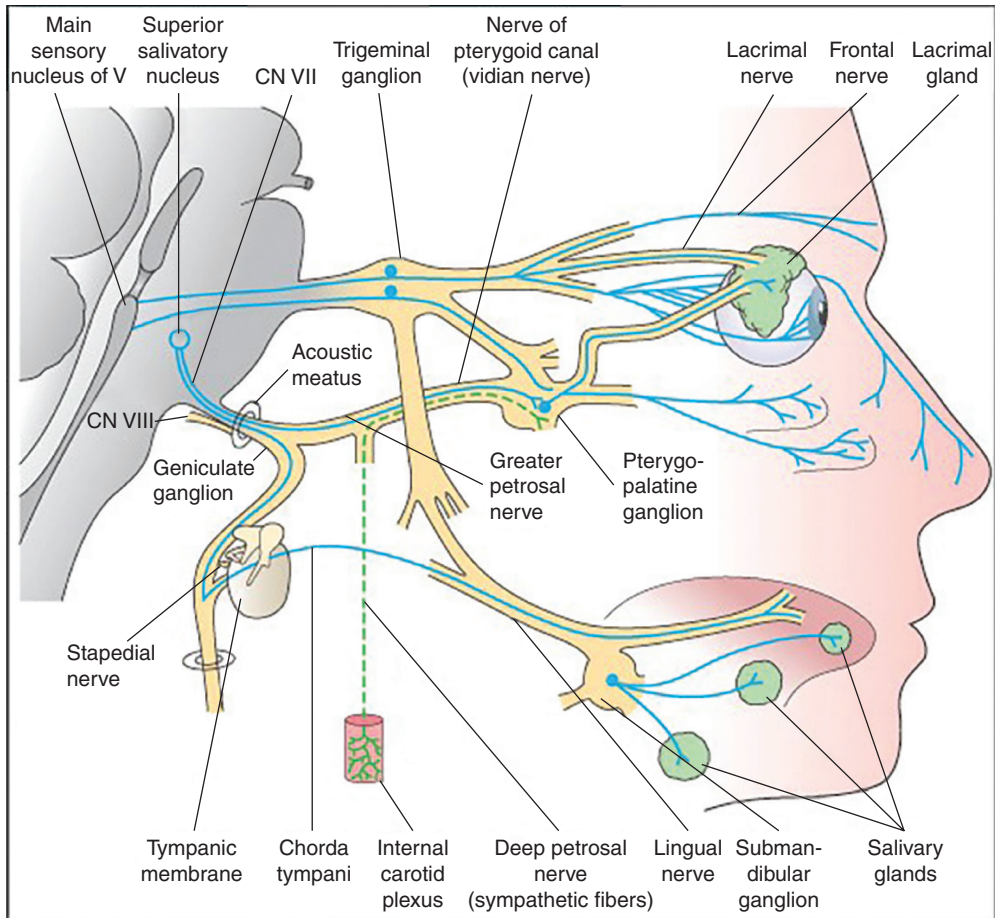
Lacrimal function is governed by branches of the parasympathetic system, whereas pupil size is controlled by a balance between innervation of the sympathetic fibers to the iris dilator muscles and innervation of the parasympathetic fibers to the iris sphincter muscles. The accessory retractor muscles, including Müller muscle in the upper eyelid, receive sympathetic innervation.

### Sympathetic Pathways

Sympathetic activity originates in the posterolateral region of the hypothalamus, which is influenced by signals in the frontal, sensorimotor, and occipital cortex and in the limbic system (cingulate gyrus). Along their course, sympathetic fibers destined for the orbit are divided into first-, second-, and third-order segments (Fig 1-46). Axons destined for the dilator muscles of the pupil and Müller muscle represent the first-order segment; along with other sympathetic fibers, they descend superficially in the anteromedial column through the brainstem to the spinal cord. Within the cervical spinal cord, the sympathetic fibers continue in the intermediolateral column. From cervical level C8 to upper thoracic level T2, the sympathetic fibers destined for the orbit synapse in the ciliospinal center of Budge-Waller.

The postsynaptic second-order fibers leave the spinal cord through the ventral rami of C8 and the T1 and T2 levels before joining the paravertebral sympathetic plexus. Ascending rostrally, the sympathetic chain passes in the anterior loop of the ansa subclavia proximate to the innominate artery on the right and the subclavian artery on the left just above the lung apex. These fibers pass through the inferior and middle cervical ganglia to terminate in the superior cervical ganglion, at the level of the angle of the jaw (C2) and the carotid artery bifurcation. The postganglionic third-order fibers continue in the wall of the bifurcated carotid. Sympathetic fibers innervating the sweat glands of the lower face follow the ECA.

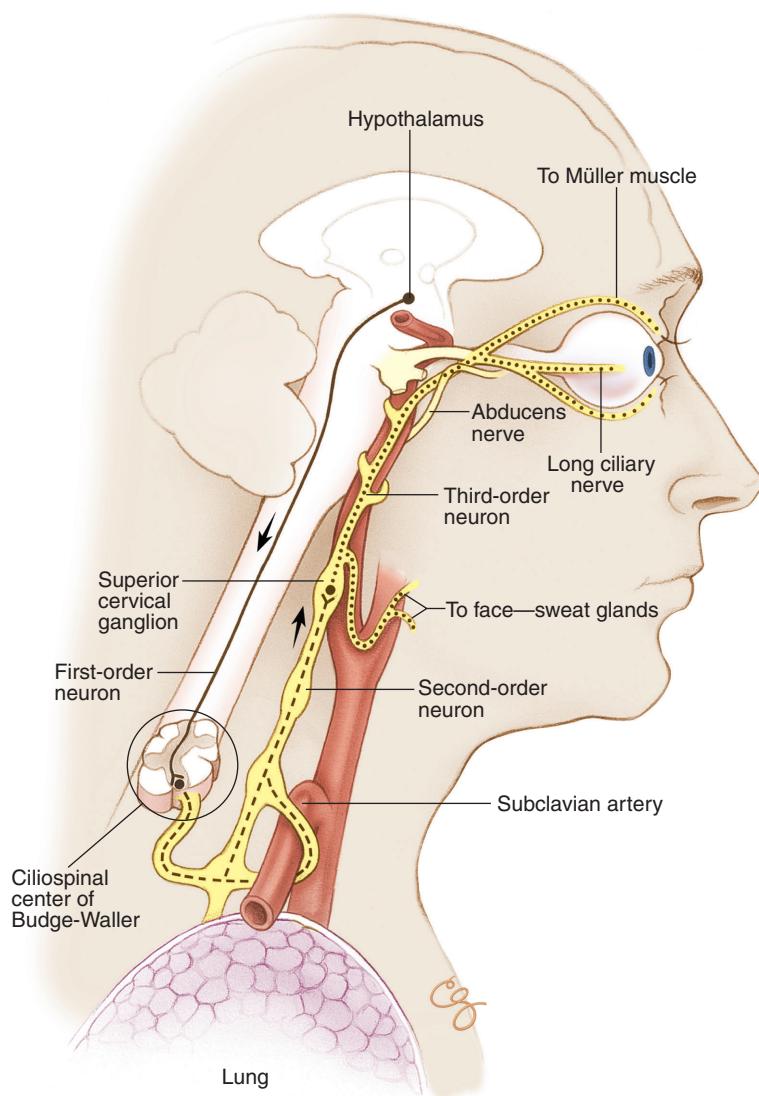
The oculosympathetic fibers destined for the pupil continue along the ICA, entering the cranium through the carotid canal. Some sympathetic fibers leave the carotid artery as it exits the petrous bone, combining with the *greater superficial petrosal nerve* to form the *vidian nerve*. These sympathetic fibers parallel the parasympathetic fibers to the lacrimal gland (see Fig 1-45). Within the cavernous sinus, sympathetic fibers destined for the dilator muscles leave the carotid in conjunction with CN VI for a few millimeters. Further anteriorly in the cavernous sinus, the sympathetic fibers join the nasociliary branch of CN V<sub>1</sub>. In the orbital apex, the fibers then pass through the ciliary ganglion (without



**Figure 1-45** Lacrimal reflex arc. The afferent pathway is provided by the first and second divisions of CN V. The efferent pathway proceeds from the lacrimal nucleus (close to the superior salivatory nucleus) via CN VII (nervus intermedius), through the geniculate ganglion, the greater superficial petrosal nerve, and the nerve of the pterygoid canal (vidian nerve), where it is joined by sympathetic fibers from the deep petrosal nerve. The fibers then pass to the pterygopalatine ganglion, where they synapse with postganglionic fibers. These fibers reach the lacrimal gland directly, via the retro-orbital plexus of nerves (particularly CN V<sub>1</sub>). The fibers carry cholinergic and vasoactive intestinal polypeptide-ergic fibers to the gland. (Modified with permission from Spalton D, Hitchings R, Hunter P. *Atlas of Clinical Ophthalmology*. 3rd ed. Elsevier/Mosby; 2005:642.)

synapsing). Along with the nasociliary branch, the sympathetic fibers reach the globe and travel with the long ciliary nerves to the dilator muscles of the pupil. The dilator muscles lie just superficial to the posterior pigment epithelium of the iris, which continues peripherally as the nonpigmented superficial layer of the ciliary body. The myoepithelial cells are approximately 12.5  $\mu\text{m}$  thick, with an apical epithelial portion and a basilar muscular portion that is oriented radially toward the pupillary opening. The muscular processes terminate peripheral to the sphincter muscle. Peripherally at the iris root, these cells are continuous with the pigmented epithelium of the ciliary body.





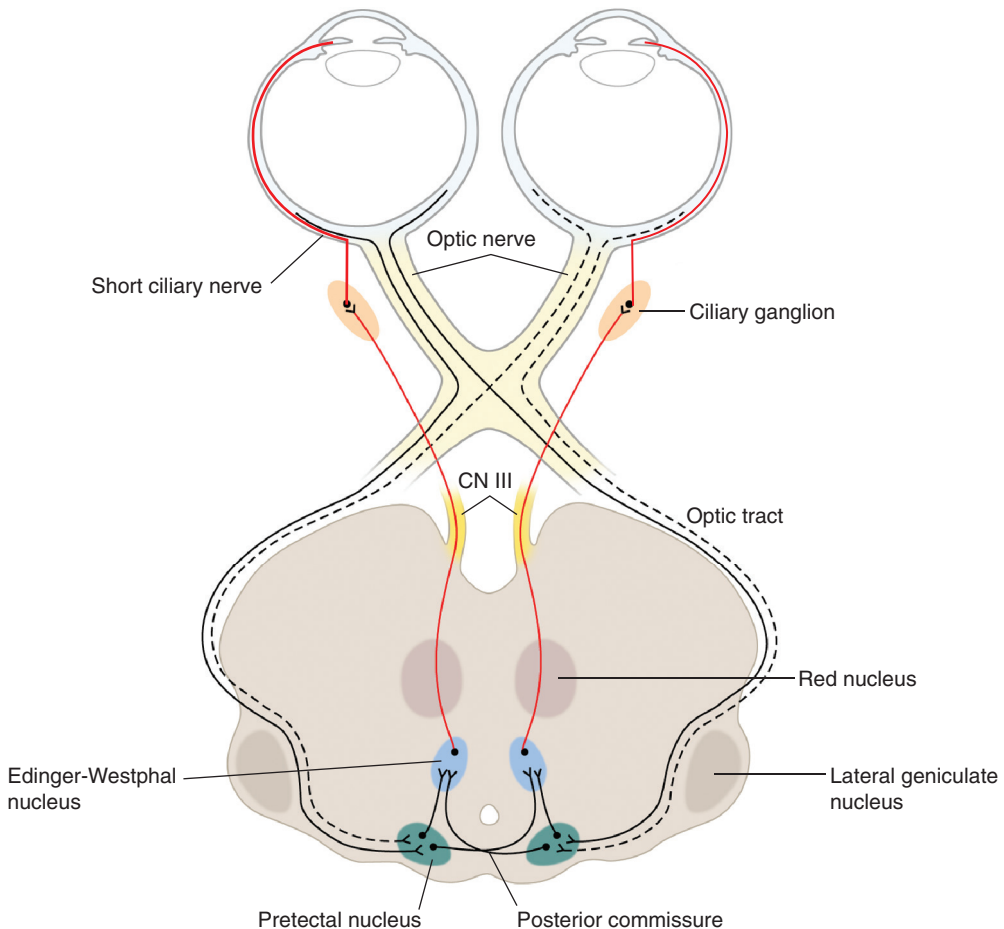
**Figure 1-46** Anatomy of the sympathetic pathway showing first-order central neuron, second-order intermediate neuron, and third-order neuron segments. Note the proximity of the pulmonary apex to the sympathetic chain. Note also the intimate relationship of the sympathetic fibers to CN VI within the cavernous sinus. (Illustration by Christine Galapp.)

The fibers destined for the Müller muscle travel along the OphA and its subsequent frontal and lacrimal branches. The Müller muscle originates near the origin of the levator aponeurosis and inserts 10–12 mm inferiorly on the superior border of the tarsus. The superior orbital sympathetic fibers also innervate the sweat glands of the forehead. Disruption of these superior orbital sympathetic fibers causes the mild ptosis and the frontal anhidrosis associated with distal Horner syndrome.



## Parasympathetic Pathways

Parasympathetic activity originates in various areas within the brainstem. The fibers that control the pupil sphincter muscles originate in the Edinger-Westphal nuclei of the CN III nuclear complex within the midbrain. The main input to the Edinger-Westphal nuclei is from the pretectal nuclei, both directly and via the posterior commissure. In turn, the pretectal nuclei receive input directly from the afferent visual pathways via the pupillary tract, which leaves the optic tract in the brachium of the SC just anterior to the LGN (Fig 1-47). Lesions of the brachium of the SC can cause a contralateral RAPD, whereas lesions of the LGN do not cause this defect. The cortex (especially the frontal lobes), the hypothalamus, and the reticular activating system provide tonic inhibitory signals to the Edinger-Westphal nuclei. During sleep, loss of this inhibitory activity causes the pupil to become smaller. In addition, the Edinger-Westphal nucleus receives input from the more ventral and rostral midbrain, probably related to bitemporal image disparity that serves as a stimulus for convergence and the near reflex.



**Figure 1-47** Pathway of the pupillary reaction to light. (Illustration by Christine Gralapp.)

The parasympathetic fibers and the CN III fascicles leave the CN III nucleus and exit the brainstem ventrally in the interpeduncular fossa. Within the subarachnoid space, the parasympathetic fibers tend to run on the medial superficial surface of CN III. When CN III bifurcates in the anterior cavernous sinus, the parasympathetic fibers travel with the inferior division. In the orbital apex, these fibers synapse in the ciliary ganglion (unlike the sympathetic and nasociliary fibers, which travel through the ganglion without synapse). The post-synaptic fibers then travel with the branch destined for the inferior oblique muscle, joining the short posterior ciliary nerves to reach the anterior segment and the iris sphincter muscles. The sphincter muscles collectively are approximately 0.8 mm in diameter and 0.15 mm thick. They travel circumferentially around the pupillary margin just anterior to the posterior pigmented epithelium and central to the termination of the dilator muscle cells. The muscles are made up of units of 5–8 muscle cells each.

Parasympathetic innervation to the lacrimal gland originates in the superior salivatory (salivary) nucleus located in the caudal pons posterolateral to the motor nucleus of CN VII (see Fig 1-45). This nucleus receives sensory input from CN V and additional afferent fibers from the hypothalamus. Efferent parasympathetic fibers for lacrimal, mucous, and salivary secretion exit the nucleus, joining other parasympathetic efferent fibers coming from the salivatory nucleus and traveling with afferent gustatory fibers from the anterior two-thirds of the tongue in the *nervus intermedius*. The gustatory fibers synapse in the *nucleus of the tractus solitarius* parallel to the fascicles of CN VII in the *nervus intermedius* (see Fig 1-44). This nerve joins CN VII to exit the brainstem on its ventral surface at the pontomedullary junction. Together with the other fascicles of CN VII, the parasympathetic fibers of the *nervus intermedius* run laterally to the internal auditory meatus. Within the petrous bone and fallopian canal, the parasympathetic fibers exit at the geniculate ganglion and then travel superficially over the petrous bone with the *greater superficial petrosal nerve*. This course parallels that of the ICA. In the area where the ICA turns to rise into the cavernous sinus, the fibers join the *vidian nerve*, which then travels through the sphenoid bone parallel to and beneath the foramen rotundum to enter the pterygomaxillary space. The fibers synapse in the sphenopalatine ganglion (see Fig 1-45). The postganglionic fibers travel superiorly through the inferior orbital fissure and then with the lacrimal nerve to innervate the lacrimal gland. This pathway is also responsible for reflex tearing.

## CHAPTER 2

# Imaging in Neuro-Ophthalmology



*This chapter includes related activities. Go to [www.aao.org/bcscactivity\\_section05](http://www.aao.org/bcscactivity_section05) or scan the QR codes in the text to access this content.*

### Highlights

---

- The appropriate neuroimaging technique depends on the clinical question being addressed.
- Computed tomography is a relatively quick imaging modality that provides good visualization of bone and hemorrhage.
- Magnetic resonance imaging provides higher resolution of brain matter, soft tissue, posterior fossa pathology, and optic nerve pathology than CT does, but it is more costly and takes more time to complete.
- A systematic approach to reviewing optical coherence tomography results can identify artifacts that could cause significant interpretive errors.

### Introduction

---

Neuroimaging and ophthalmic imaging are excellent diagnostic and prognostic tools in ophthalmology. However, they should be used in conjunction with—not as a substitute for—a detailed clinical evaluation of the patient. During the clinical assessment, it is important to address the following questions:

- What is the patient's clinical presentation?
- Where is the lesion that is causing the clinical presentation?
- What are the potential etiologies of the lesion?

Selection and timing of an appropriate neuroimaging technique can then be tailored to the differential diagnosis, nature of the suspected lesion (eg, vascular, neoplastic, inflammatory), location of the lesion, and patient characteristics (eg, age, weight, allergies, comorbidities such as renal dysfunction or claustrophobia, presence of metallic foreign bodies, or use of a pacemaker or other device), as well as the availability of the imaging modality. Direct communication with the radiologist is also important, not only in choosing the best imaging modality but also in interpreting the study results.

Errors that the clinician may make when ordering or reviewing a neuroimaging study fall into 2 broad categories: prescriptive and descriptive (see the sidebar).

This chapter includes discussions of the 2 most common neuroimaging techniques used in neuro-ophthalmology clinical practice: *computed tomography (CT)* (Fig 2-1) and *magnetic resonance imaging (MRI)* (Fig 2-2). In general, most neuro-ophthalmic diseases are best assessed with MRI of the brain and/or orbits using contrast material and fat-saturation techniques. When a vascular abnormality is suspected, *magnetic resonance angiography (MRA)* or *magnetic resonance venography (MRV)* can be added to the MRI study; similarly, *computed tomography angiography (CTA)* or *computed tomography venography (CTV)* can be added to CT.

This chapter also addresses ultrasonography, which is helpful for assessing certain vascular diseases, and optical coherence tomography (OCT), which has become pivotal in evaluating patients with vision loss. The importance of accurately interpreting an OCT scan and identifying artifacts that can influence the results is discussed as well. (The clinical applications of OCT are reviewed in Chapter 3.)

A glossary of select neuroimaging terminology appears at the end of this chapter. See also Chapter 17 in BCSC Section 2, *Fundamentals and Principles of Ophthalmology*, for further discussion of neuroimaging and ultrasonography.

Bose S. Principles of neuroimaging in neuro-ophthalmology. In: Yanoff M, Duker JS, eds. *Ophthalmology*. 5th ed. Saunders; 2018.

Costello F, Scott JN. Imaging in neuro-ophthalmology. *Continuum (Minneapolis)*. 2019;25(5):1438–1490.

Custer PL, Kent TL. Pitfalls of ophthalmic radiographic imaging. *Curr Opin Ophthalmol*. 2014;25(5):432–435.

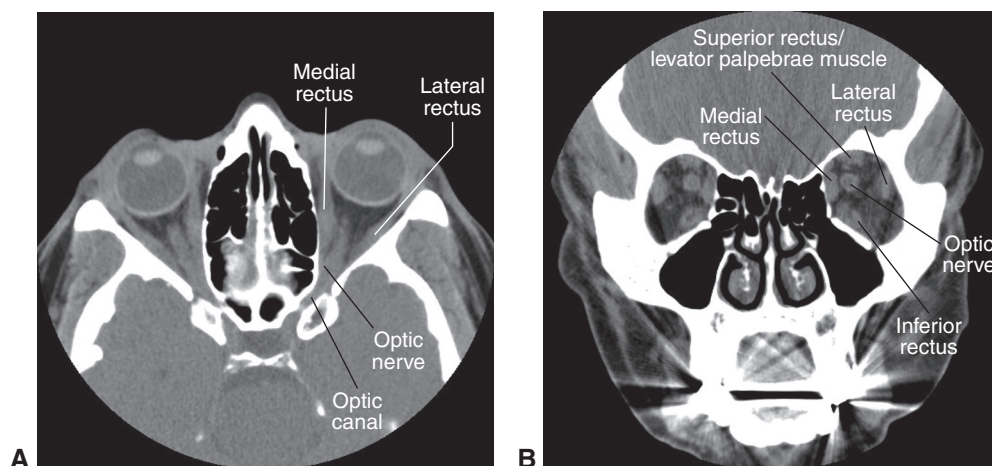
## ERRORS TO AVOID WHEN ORDERING OR REVIEWING A NEUROIMAGING STUDY

### *Prescriptive errors include*

- failure to obtain the correct study
- inappropriate use of a dedicated study
- omission of intravenous contrast material
- omission of specialized sequences

### *Interpretive errors include*

- failure to detect a lesion because of misleading clinical information
- rejection of a clinical diagnosis because an expected abnormality is absent from an image
- the incorrect assumption that a striking imaging abnormality accounts for a clinical abnormality



**Figure 2-1** Orbital computed tomography (CT) in a healthy subject. **A**, Axial. **B**, Coronal. (Courtesy of Rod Foroozan, MD.)

## Computed Tomography

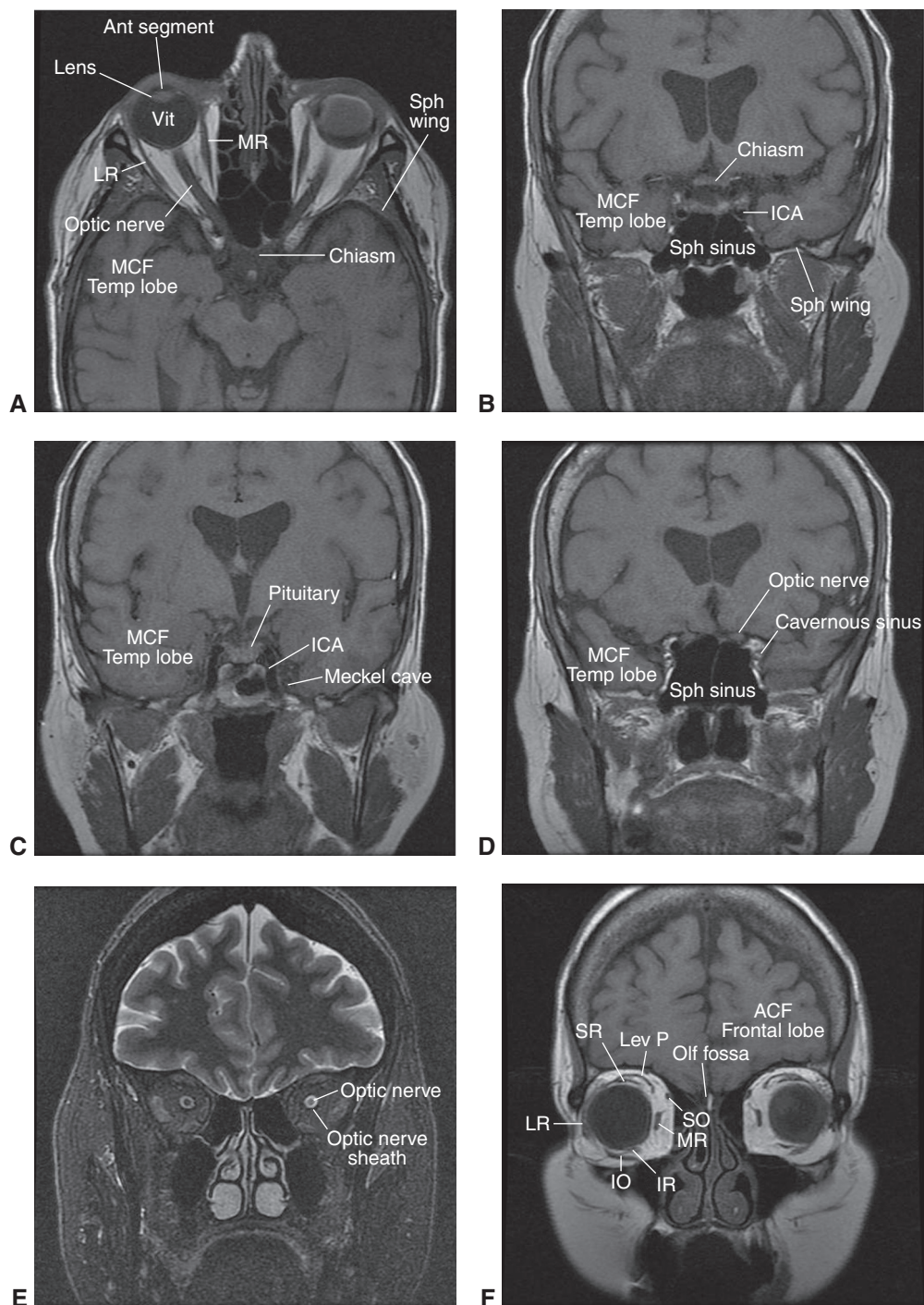
The orbit is particularly well suited to x-ray–based CT imaging because fat provides excellent contrast to the globe, lacrimal gland, optic nerve, and extraocular muscles. Bone and lesions that contain calcium can also be easily visualized because of their marked x-ray attenuation (see Fig 2-1). Soft-tissue details can be further enhanced with the injection of iodinated contrast material; this material crosses a disrupted blood–brain barrier and accumulates within a local lesion, revealing inflammatory and neoplastic processes. Iodinated contrast material can be used in patients with a calculated glomerular filtration rate (GFR) of 30 mL/min/1.73 m<sup>2</sup> or higher. If the patient’s kidney function is below this level, contrast material should be avoided if possible.

The advantages of CT include its relatively low cost, rapid image acquisition, wide availability, and excellent spatial resolution. Its speed and ability to accurately identify acute blood or bone abnormalities make CT especially useful when trauma patients who may be confused or combative are examined. However, CT scans carry the risk of ionizing radiation. The average radiation dose is 2 millisievert (mSv) or less per CT scan of the head, and therefore this is a low risk. The advantages and disadvantages of CT are summarized in Table 2-1.

## Magnetic Resonance Imaging

Magnetic resonance imaging is the imaging method of choice for most patients with neuro-ophthalmic conditions because it provides excellent details of central nervous system (CNS) tissue and pathology (Fig 2-3, Activity 2-1; see also Fig 2-2). It is better than CT at visualizing optic nerve and posterior fossa pathology, but it is more costly and the acquisition times are longer. The advantages and disadvantages of MRI are summarized in Table 2-1.





**Figure 2-2** Brain and orbital magnetic resonance imaging (MRI) showing visual and orbital anatomical structures from the chiasm to the anterior orbit. (The abnormality of the left globe is not pertinent to the objective of this figure.) T1-weighted axial (**A**), T1-weighted coronal (**B–D**), T2-weighted coronal with fat saturation (**E**), and T1-weighted coronal (**F**) images. ACF=anterior cranial fossa; Ant segment=anterior segment; ICA=internal carotid artery; IO=inferior oblique muscle; IR=inferior rectus muscle; LR=lateral rectus muscle; Lev P=levator palpebrae superioris muscle; MCF=middle cranial fossa; MR=medial rectus muscle; Olf fossa=olfactory fossa; SO=superior oblique muscle; Sph sinus=sphenoid sinus; Sph wing=sphenoid wing; SR=superior rectus muscle; Temp lobe=temporal lobe; Vit=vitreous. (Courtesy of M. Tariq Bhatti, MD.)



**Table 2-1 Comparison of Computed Tomography and Magnetic Resonance Imaging**

	<b>Advantages</b>	<b>Disadvantages</b>	<b>Contraindications (Relative)</b>
CT	Can assess bony abnormalities Can assess orbital and hyperacute intracranial hemorrhage Can detect calcification in lesions Can evaluate globe and orbital trauma (includes high-resolution bone algorithms) Has wide availability	Exposure to ionizing radiation dose (CT head radiation dose = 2 mSv) Reactions to iodine-based contrast dye Lack of direct sagittal imaging Limited resolution in the posterior fossa Poor resolution of the orbital apex	Renal insufficiency: contraindicated if calculated GFR <30 mL/min/1.73 m <sup>2</sup> Brain cancer risk: 2.8 times greater in children who receive a dose of ≥50 mGy compared to those without this cumulative dose
MRI	Can distinguish white matter from gray matter Can better depict posterior fossa pathology compared to CT Has good resolution of soft tissue Has good resolution of optic nerve and orbital apex Can establish evolution of intraparenchymal hemorrhage Does not use ionizing radiation	Contrast dye reactions and systemic nephrogenic fibrosis Greater cost compared to CT Susceptibility artifacts from metal (eg, braces) or air–tissue interfaces Longer acquisition time compared to CT	Cochlear implants Ferromagnetic implants/foreign bodies Gadolinium: should not be administered in patients who are pregnant or who have calculated GFR level <30 mL/min/1.73 m <sup>2</sup> Metallic cardiac valves Non-MRI-compatible intracranial aneurysm clips Pacemakers Renal insufficiency Technical considerations: claustrophobia/patient too large for the bore
CTA/CTV	Is less invasive than catheter angiography	Artifacts from superimposed bone and adjacent vessels, especially when aneurysms lie within or close to bone Limited resolution (in aneurysms ≤3 mm) Contrast agent required	Same as for CT
MRA/MRV	Is less invasive than catheter angiography Can be done without contrast agent	Limited resolution (in aneurysms ≤3 mm) Possible overestimation of carotid stenosis or venous sinus stenosis	Same as for MRI

CT = computed tomography; CTA = computed tomography angiography; CTV = computed tomography venography; GFR = glomerular filtration rate; mGy = milligray; MRA = magnetic resonance angiography; MRI = magnetic resonance imaging; MRV = magnetic resonance venography; mSv = millisievert.

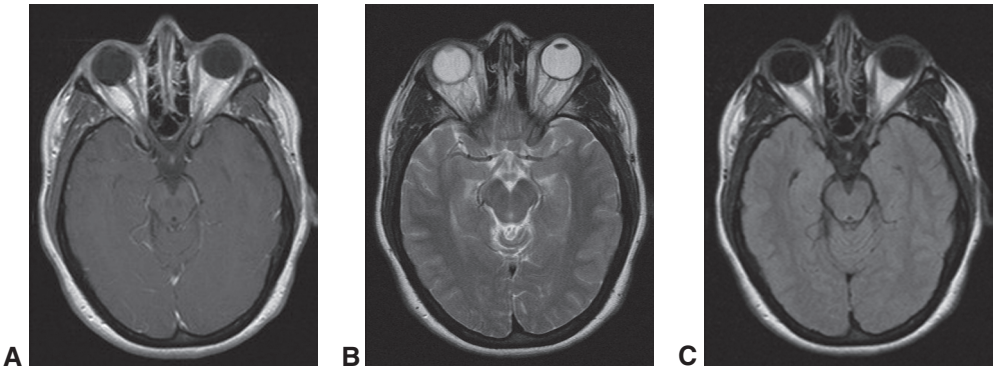


**ACTIVITY 2-1** Interactive MRI exploring orbital anatomy and visual pathways.  
*Images courtesy of John J. Chen, MD, PhD.*



MRI generates images based on the magnetic properties of the spinning protons in soft tissue. The magnetic field strength is measured in tesla (T); most commercially available machines range from 1.5 to 3 T in strength. Open MRI machines operate at lower strength and provide poorer image quality than closed machines. The superior image quality and shorter acquisition times provided by higher-strength machines are based on higher signal-to-noise and contrast-to-noise ratios.

MRI protocols include multiple scans, each generated with different sequences. Sequences are usually classified as T1- or T2-weighted (see Figs 2-2, 2-3, Activity 2-1). Each tissue type has characteristic T1 and T2 relaxation times attributable to the amount of water it contains and how the water is bound in the tissue (Table 2-2). T1-weighted imaging is optimal for demonstrating anatomy. T1-weighted images also have a higher resolution than T2-weighted images, chiefly because of the increased intensity of the signal and shorter repetition time; this results in faster acquisition times, thereby minimizing movement-related



**Figure 2-3** Normal axial MRI at the level of the orbits and midbrain, highlighting different signal characteristics depending on water content and bound state of the tissue. **A**, T1-weighted image with contrast material shows cerebrospinal fluid (CSF) and vitreous as hypointense (*dark*), orbital fat as hyperintense (*bright*), and gray matter as relatively hypointense compared with white matter. **B**, T2-weighted image shows that CSF, vitreous, and orbital fat are hyperintense and that gray matter is hyperintense compared with white matter. **C**, Fluid-attenuated inversion recovery (FLAIR) image shows that orbital fat is hyperintense; however, vitreous and CSF appear hypointense, facilitating detection of abnormalities in periventricular tissue. Note that in the FLAIR image the gray matter is lighter than in the T1-weighted image. (*Courtesy of Rod Foroozan, MD.*)

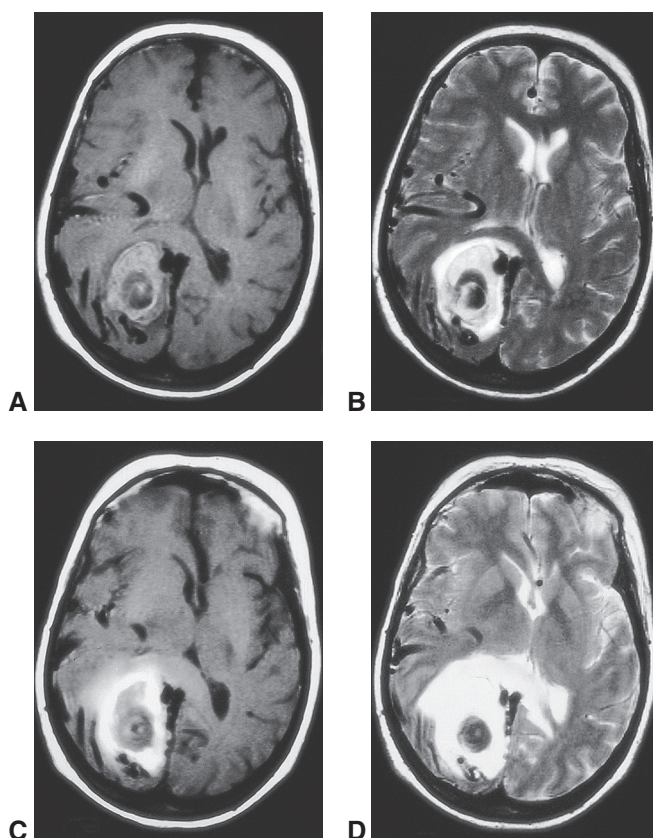
**Table 2-2 MRI Signal Intensity (Brightness) by Tissue Type**

T1	Fat > white matter > gray matter > CSF/vitreous > air
T2	CSF/vitreous > fat > gray matter > white matter
FLAIR	Fat > gray matter > white matter > CSF/vitreous > air
STIR	CSF/vitreous = gray matter > white matter > fat > air

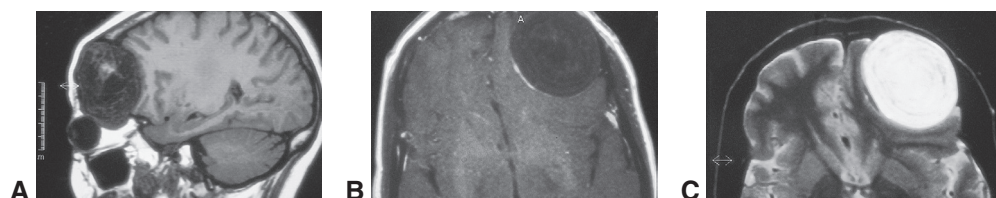
CSF = cerebrospinal fluid; FLAIR = fluid-attenuated inversion recovery; MRI = magnetic resonance imaging; STIR = short tau inversion recovery.

artifacts. T2-weighted images maximize differences in tissue water content and state and thus are more sensitive to inflammatory, ischemic, or neoplastic alterations in the tissue (Figs 2-4, 2-5, 2-6).

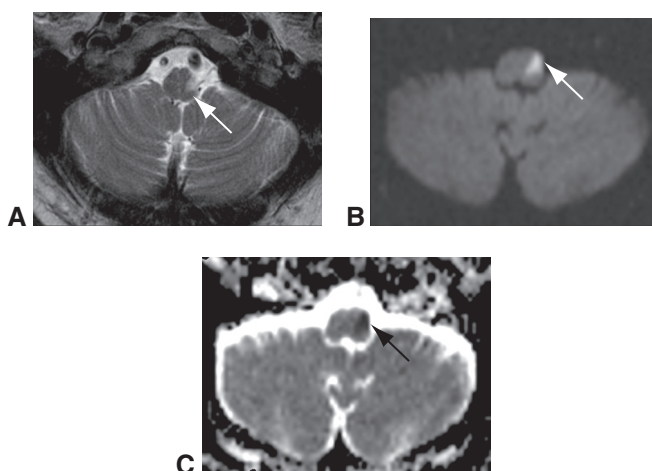
Very intense tissue signals (eg, those from fat in T1-weighted MRI scans and those from cerebrospinal fluid [CSF] or vitreous in T2-weighted images) may obscure subtle signal abnormalities in neighboring tissues (see Table 2-2). To reduce these intense signals, special radiofrequency pulse sequences are used. Similarly, fat-suppression techniques such as *short tau inversion recovery* (STIR) are used to obtain T1-weighted images without the confounding bright fat signal. This technique is particularly useful in studying the orbit (Figs 2-7, 2-8; see Fig 2-9D). *Fluid-attenuated inversion recovery* (FLAIR) images are similar to T2-weighted images but without the high-intensity (bright) CSF signal, making



**Figure 2-4** T1-weighted and T2-weighted MRI sequences can yield complementary information about the characteristics of a lesion and can be particularly helpful in dating hemorrhages. A 61-year-old patient presented with acute onset of severe headache. A hemorrhage is apparent in the parieto-occipital region on the axial T1-weighted (**A**) and T2-weighted (**B**) images. The signal at the lesion periphery relates to the presence of oxyhemoglobin, whereas the core remains dark in the 2 images because of the presence of deoxyhemoglobin. When MRI was repeated 10 days later, the signal characteristics had changed as a result of the development of methemoglobin in the outer ring, which is bright on T1-weighted (**C**) and T2-weighted (**D**) images but the core remains dark. (Courtesy of Steven A. Newman, MD.)



**Figure 2-5** Various tumors may have specific findings based on the MRI sequence used. This patient had a large frontal tumor invading the orbit with radiologic characteristics consistent with an epidermoid cyst. **A**, Sagittal T1-weighted image shows the tumor to be heterogeneous but mostly hypointense to gray matter. **B**, Axial, post-gadolinium T1-weighted image demonstrates minimal rim enhancement. **C**, On the coronal T2-weighted image, the lesion becomes extremely bright. (Courtesy of Steven A. Newman, MD.)



**Figure 2-6** MRI scans from a patient with lateral medullary syndrome (also called Wallenberg syndrome). **A**, Axial T2-weighted sequence demonstrates a bright signal in the left lateral medulla (arrow). **B**, Diffusion-weighted imaging (DWI) shows a bright signal (arrow). **C**, The apparent diffusion coefficient shows a dark signal (arrow) consistent with an acute infarction and not the phenomenon known as *T2 shine-through*. (Courtesy of M. Tariq Bhatti, MD.)

this modality ideal for detecting periventricular white matter changes in a demyelinating process such as multiple sclerosis (Fig 2-9; see also Chapter 15).

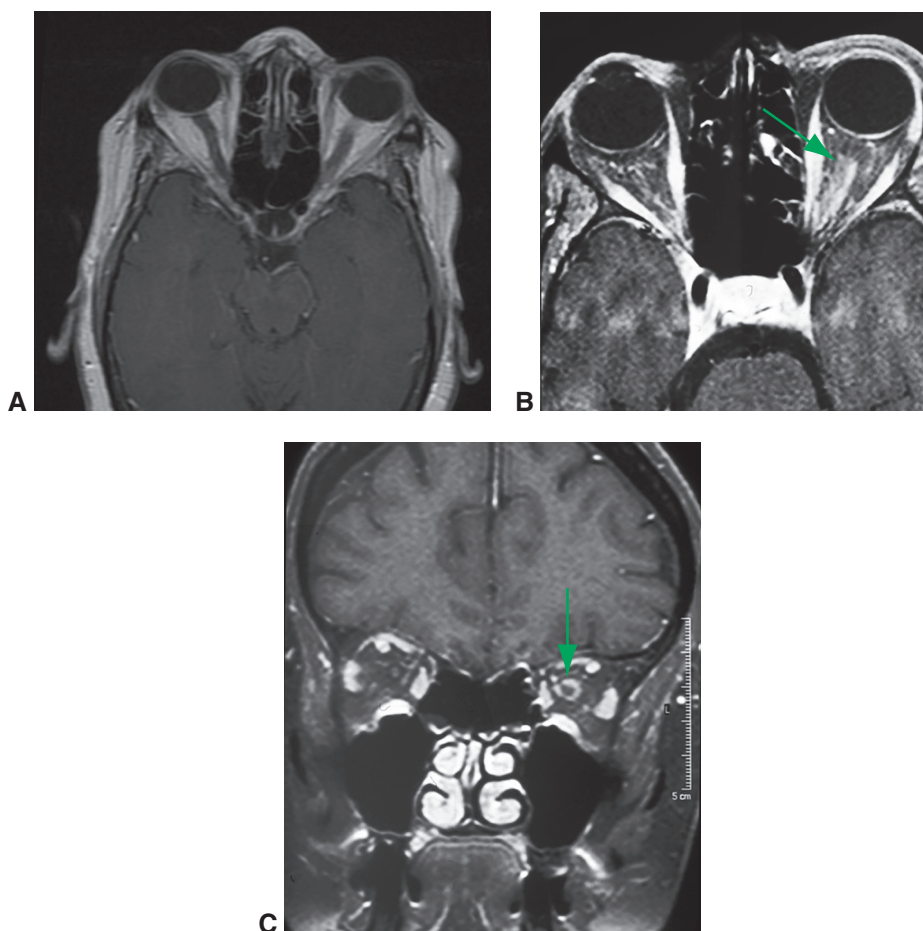
Other MRI sequences are helpful in specific clinical scenarios. *Diffusion-weighted imaging (DWI)* is sensitive to recent alterations in vascular perfusion; thus, it is ideal for identifying recent infarctions (Fig 2-10; see also Fig 2-6). An abnormal DWI signal occurs within minutes of the onset of cerebral ischemia (vs within several hours with conventional MRI sequences) and persists for approximately 3 weeks, serving as a time marker for acute and subacute ischemic events. *Apparent diffusion coefficient (ADC)* is a derived technique used for imaging patients with suspected stroke or tumor. ADC helps to determine whether DWI hyperintensity is a real diffusion restriction or a T2 “shine-through” artifact (Table 2-3). Gradient echo imaging and especially susceptibility weighted imaging (SWI) are helpful in detecting mineralization and/or hemorrhage.

Some MRI sequences, most commonly T1, can be further modified by injecting gadolinium, a paramagnetic contrast agent that traverses a disrupted blood–brain barrier and alters MRI signal characteristics. This alteration may be crucial in identifying infectious and inflammatory lesions as well as tumors with compositions that make them otherwise indistinguishable from normal cortical tissue. For example, gadolinium contrast enhancement is very helpful in identifying a meningioma and optic neuritis (see Figs 2-7, 2-8, 2-9; see also Chapter 4). In the MRI shown in Activity 2-2 (from a patient with a meningioma involving the right cavernous sinus, which caused diplopia) the meningioma is most visible in the T1 postcontrast sequence.



**ACTIVITY 2-2** Interactive MRI of a meningioma showing its appearance on different sequences.

*Images courtesy of John J. Chen, MD, PhD.*

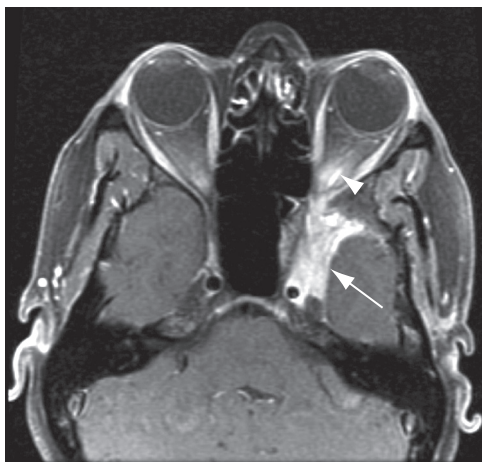


**Figure 2-7** MRI of a patient with left optic nerve sheath meningioma. **A**, Axial T1-weighted image shows normal hyperintense orbital fat. **B**, Suppression of the orbital fat allows visualization of optic nerve sheath enhancement (*arrow*) consistent with a meningioma. **C**, Coronal, post-gadolinium, fat-suppressed T1-weighted image shows enhancement of the optic nerve sheath (*arrow*). (Courtesy of Valerie Biousse, MD.)



**Figure 2-8** MRI of a 48-year-old woman who presented with slowly progressive decreased vision in the left eye. The axial, post-gadolinium T1-weighted image with fat suppression shows a meningioma involving the middle cranial fossa of the skull base (*arrow*), including the optic canal. Abnormal enhancement in the orbital apex indicates that the meningioma extends along the optic nerve sheath (*arrowhead*).

(Courtesy of Eric Eggenberger, DO.)



However, gadolinium-based contrast agents may cause nephrogenic systemic fibrosis, a rare multisystemic disease of the heart, lung, and liver characterized by soft-tissue collagen deposition that results in skin thickening and muscle contractures. Therefore, they are relatively contraindicated in patients who have preexisting renal disease or who have recently received kidney or liver transplants. Most radiologists will not administer the contrast medium if the calculated GFR level is lower than 30 mL/min/1.73 m<sup>2</sup>. Lastly, there are reports of asymptomatic gadolinium deposition in the brain after repeated MRI scans, especially in the dentate nuclei and globus pallidi. However, the short- and long-term adverse effects from this gadolinium deposition are unknown at this time.

Delouche A, Attyé A, Heck O, et al. Diffusion MRI: pitfalls, literature review and future directions of research in mild traumatic brain injury. *Eur J Radiol.* 2016;85(1):25–30.

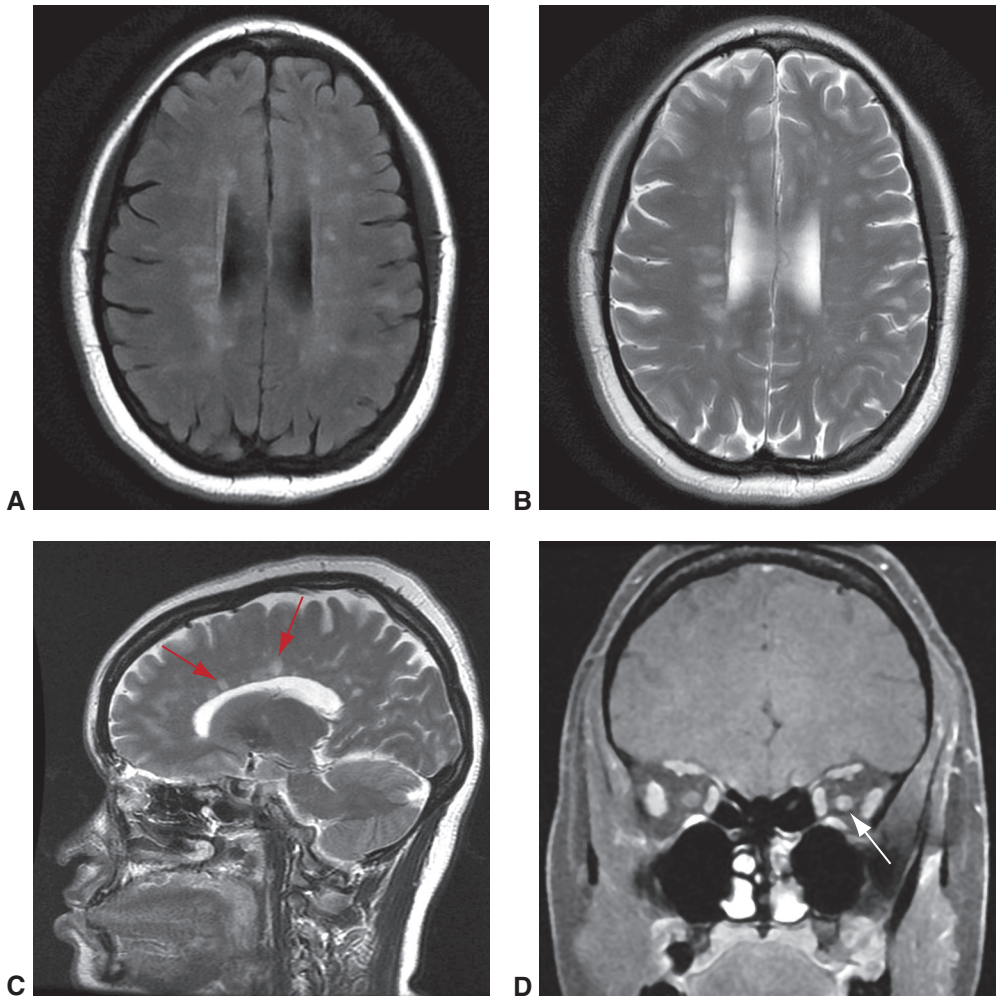
Rose TA Jr, Choi JW. Intravenous imaging contrast media complications: the basics that every clinician needs to know. *Am J Med.* 2015;128(9):943–949.

## Crucial Considerations in Neuroimaging

Although neuroimaging is widely available, it can be expensive and is not without risks. Accordingly, when selecting or interpreting an imaging study, the clinician should consider the following in the context of the current clinical dilemma:

- *when* to order
- *what* to order (Table 2-4)
  - choose the modality
  - select the unique technique or special imaging sequence
- *how* to order
  - specify the lesion and anatomical region of interest
  - discuss with the radiologist before ordering
- *how* to interpret
  - read the report and view the images
  - review the results with the radiologist





**Figure 2-9** MRI of a 30-year-old woman with acute optic neuritis of the left eye. Axial FLAIR (**A**) and T2-weighted (**B**) images show bilateral, scattered, periventricular, hyperintense white matter lesions, which are more conspicuous on the FLAIR image. **C**, Sagittal T2-weighted image demonstrates the same periventricular white matter changes perpendicular to the corpus callosum (*arrows*), also known as *Dawson fingers*. **D**, Coronal, post-gadolinium T1-weighted image with orbital fat suppression shows enhancement of the left optic nerve (*arrow*). (Courtesy of M. Tariq Bhatti, MD.)

**Table 2-3 Edema: DWI and ADC**

Type of Edema	DWI Signal	ADC Signal
Cytotoxic	Bright (high or restricted diffusion) <sup>a</sup>	Dark (low)
Vasogenic	Dark (low)	Normal (sometimes bright)

ADC = apparent diffusion coefficient; DWI = diffusion-weighted imaging.

<sup>a</sup> Bright signal on DWI represents restricted diffusion or decreased water movement.

**Table 2-4 Imaging Choice Based on Clinical Scenario**

Clinical Scenario	Imaging Study	Comments
Acute hemorrhage	CT, MRI	CT better for acute subarachnoid hemorrhage; MRI clarifies evolution of intraparenchymal hemorrhage
Aneurysm	MRA, CTA, angiography	May be missed by MRI and CT
Arteriovenous malformation	Angiography	
Bone disease	CT	
Calcification	CT	Most forms are poorly visualized on MRI
Carotid-cavernous fistula	MRA, angiography	MRA before angiography
Carotid dissection	MRI, MRA, CTA	
Carotid stenosis	Carotid Doppler imaging, MRA, CTA, angiography	
Cerebral vascular disease	MRA, CTA, CTV, angiography	
Cerebral venous disease	MRI, MRA, MRV, CTV	
Chiasmal syndrome	MRI	Poorly visualized on CT
Demyelination or multiple sclerosis	MRI	FLAIR best for demyelinating lesions; poorly visualized on CT
Foreign body	CT	MRI problematic with ferromagnetic objects such as vascular clips
Infection	MRI	Abscess, meningitis
Intracranial hypertension	MRI, MRV	Indirect signs of raised intracranial pressure seen on MRI and MRV
Meningeal disorders	MRI	Infectious, inflammatory, or neoplastic process
Middle cranial fossa disease	MRI, CT	
Neoplasm	MRI	MRI better than CT for edema and features, less so for bony involvement
Optic neuritis	MRI	Include contrast agent and fat suppression; poorly visualized on CT
Orbitopathy	MRI, CT	Include fat suppression with MRI
Paranasal sinus disease	CT, MRI	CT better than MRI for showing bony details
Parasellar disease	MRI	CT associated with bony artifact
Pituitary adenoma	MRI	Axial CT often misses pituitary abnormalities
Posterior cranial fossa disease	MRI	CT associated with bony artifact
Radiation damage	MRI	Include contrast material with MRI; poorly visualized on CT
Thyroid eye disease	MRI, CT, US	MRI: include orbital fat-suppression technique
Trauma	CT	Faster than MRI; shows acute blood and bony changes
White matter disease	MRI	Poorly visualized on CT

CT=computed tomography; CTA=computed tomography angiography; CTV=computed tomography venography; FLAIR=fluid-attenuated inversion recovery; MRA=magnetic resonance angiography; MRI=magnetic resonance imaging; MRV=magnetic resonance venography; US=ultrasonography.

## When to Order

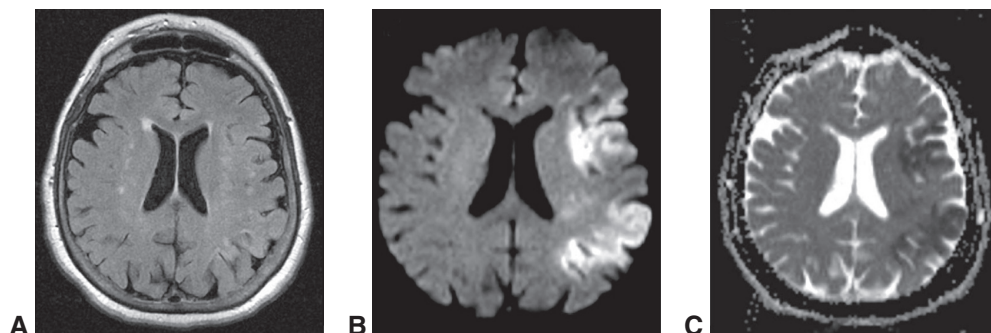
The decision concerning when to order a neuroimaging study should be based on the examination and the localization and expectation of particular findings. Furthermore, the information to be acquired by imaging should have some influence on patient management or should provide a more accurate prognosis based on the natural history of the disease.

In addition, the risks and the benefits of imaging must be weighed. For example, it has been estimated that children who receive a brain radiation dose of  $\geq 50$  milligray (mGy) have a risk of brain cancer that is 2.8 times higher than that of children without this amount of radiation. Ultimately, the urgency in obtaining imaging results depends on the clinical situation. For example, a patient with a cranial nerve (CN) III palsy that affects the pupil requires prompt neuroimaging (discussed in the vascular imaging section) to rule out an aneurysm (also see Chapter 8, Fig 8-8). Similarly, for patients with visual symptoms thought to herald other emergent neurological or life- or vision-threatening conditions, testing to confirm a diagnosis and commence treatment should be initiated immediately.

## What to Order

The choice of specific neuroimaging modality, including sequence, orientation, and direction, depends on both the expected pathology and its suspected location. With some important exceptions, MRI is better than CT at detecting CNS lesions and narrowing the differential diagnosis (see Tables 2-1, 2-4). For example, a patient with a progressively worsening CN IV palsy should undergo a brain MRI with gadolinium contrast and specifications to obtain fine cuts through the brainstem.

When pathology is localized to the orbit, fat provides excellent contrast with other orbital components; thus, either CT or MRI can provide useful information (see Figs 2-1, 2-2). In general, CT provides better visualization of bone and sinuses (Fig 2-11). In addition, its



**Figure 2-10** The value of MRI and DWI in acute infarction. **A**, The FLAIR image is normal except for nonspecific tiny foci of hyperintense signal in the deep white matter. **B**, DWI reveals abnormal restricted diffusion (high-intensity signal) near the left middle cerebral artery. **C**, The low-intensity signal on the apparent diffusion coefficient map is consistent with an acute infarction. (Courtesy of M. Tariq Bhatti, MD.)

faster acquisition times allow for imaging of the patient in Valsalva, which can detect orbital varices (Fig 2-12). In contrast, MRI of the orbit with fat-saturation techniques (to eliminate high-intensity T1 signal from fat) and gadolinium enhancement provide higher resolution of pathology within the orbits. This is best for identifying optic nerve pathology, such as optic neuritis, which cannot be visualized on CT (see Fig 2-9D). MRI of both the brain and the orbits is often required because MRI of the orbits provides details about the optic nerves and the surrounding tissues that may not be detected with brain imaging alone, but orbital scans alone may be too limited to pick up accompanying cortical lesions, such as the periventricular white matter lesions seen in multiple sclerosis (see Fig 2-9).

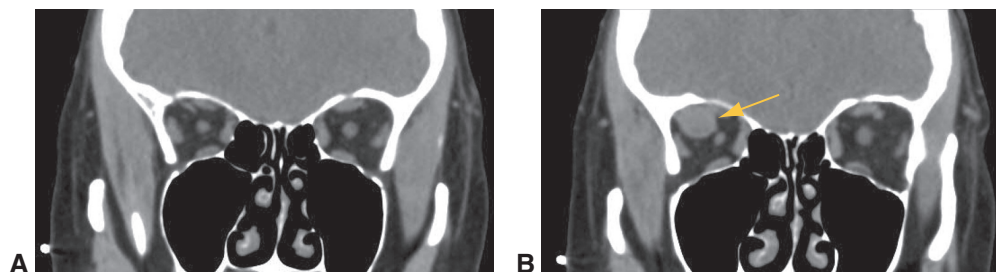
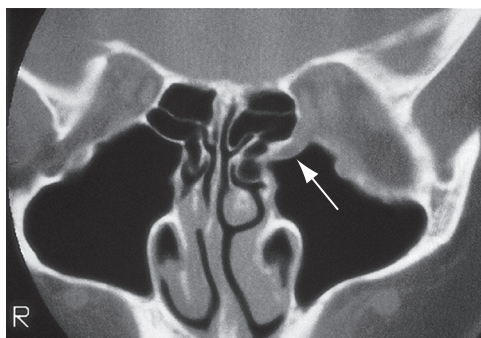
Khan SN, Sepahdari AR. Orbital masses: CT and MRI of common vascular lesions, benign tumors, and malignancies. *Saudi J Ophthalmol.* 2012;26(4):373–383.

Luccichenti G, Giugni E, Péran P, et al. 3 Tesla is twice as sensitive as 1.5 Tesla magnetic resonance imaging in the assessment of diffuse axonal injury in traumatic brain injury patients. *Funct Neurol.* 2010;25(2):109–114.

## How to Order

To obtain the most meaningful neuroimaging result, communication with the radiologist is vital and should include a complete but succinct patient history and the type of scan desired, the sequence, any contrast material, the scan thickness, the area of anatomical

**Figure 2-11** A 19-year-old man with double vision following a motor vehicle accident was noted to have limitation of adduction of the left eye and narrowing of the palpebral fissure on attempted abduction of the same eye. Coronal CT showed an entrapped left medial rectus muscle (arrow). (Courtesy of Steven A. Newman, MD.)



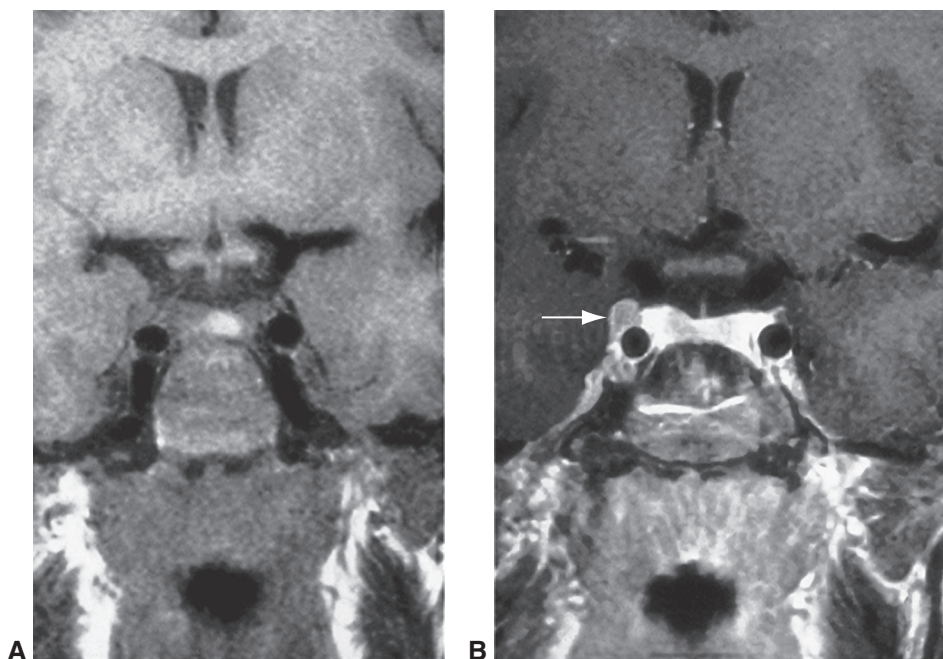
**Figure 2-12** CT of orbital varix with Valsalva maneuver. **A**, Normal under resting conditions. **B**, During Valsalva maneuver, a large orbital varix (arrow) is clearly evident. (Courtesy of John J. Chen, MD, PhD.)

interest, and any renal function testing (especially for patients with suspected kidney disease). Failure to supply detailed information often results in images that do not show the relevant anatomy or do so with insufficient detail. Inappropriate images (eg, images showing the wrong location or orientation, absence of contrast material, or overly thick slices) are often worse than no images at all because they may provide a false sense of security.

### How to Interpret

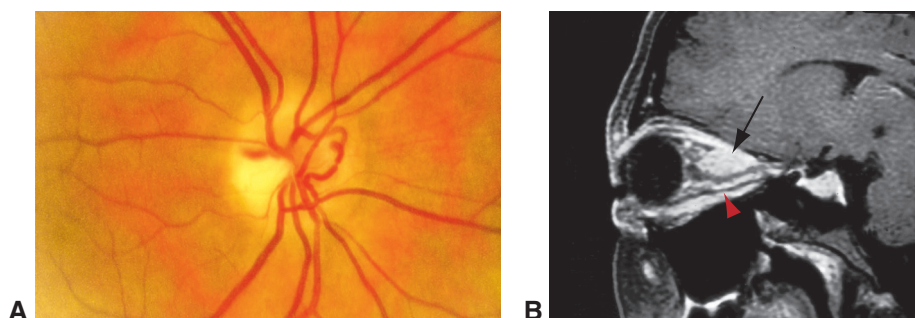After a neuroimaging study has been performed, the clinician should review the images or at a minimum personally read the radiology report. When the neuroimaging study gives an unexpected result or fails to demonstrate the expected pathology with respect to the clinical presentation, the clinician's first step is to reexamine the study parameters, ideally with a neuroradiologist. The following questions should be kept in mind:

- Were the appropriate studies performed, including required sequences and orientations?
- Was the area of interest adequately imaged (Fig 2-13)?
- Are the study results truly negative (Fig 2-14; see also Fig 2-13)?



**Figure 2-13** Delayed diagnosis of a right cranial nerve (CN) III schwannoma. **A**, Initial coronal, noncontrast T1-weighted MRI did not show an abnormality, but repeated MRI with fine cuts through the cavernous sinus demonstrated asymmetry, with a slight nodule in the superior portion of the cavernous sinus on the right. **B**, Post-gadolinium T1-weighted image clearly shows an enhancing lesion (*arrow*), consistent with a CN III schwannoma (*arrow*). (Courtesy of Steven A. Newman, MD.)





**Figure 2-14** A 41-year-old woman with progressive vision loss in the right eye had a visual acuity of 2/200 OD and 20/20 OS, with a right relative afferent pupillary defect. Findings from 2 previous MRI studies were reportedly normal. She was thought to have a swollen optic nerve due to multiple sclerosis. **A**, A fundus photograph of the right optic nerve head (ONH) demonstrates temporal pallor with optociliary shunt vessels. **B**, Sagittal, post-gadolinium T1-weighted image through the orbit shows the appearance of an abnormal optic nerve sheath consistent with an optic nerve sheath meningioma (arrow). The arrowhead points to the plaque portion of the meningioma. (Part A courtesy of Steven A. Newman, MD; part B courtesy of Eric Eggenberger, DO.)

When the ophthalmologist cannot personally review the studies, speaking directly with the radiologist may prompt a second review for overlooked lesions and can provide additional clinical information required to enhance the radiographic report's accuracy and usefulness.

## Vascular and Other Imaging Modalities

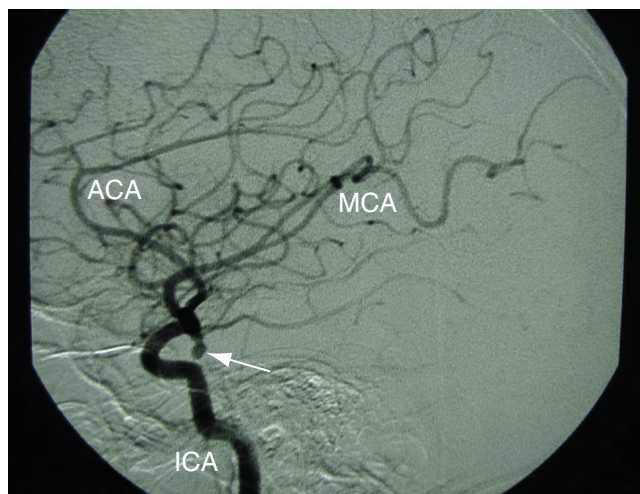
Several techniques are commonly used to image blood vessels (see Tables 2-1 and 2-4). These procedures can detect narrowing, blockage, aneurysm, and irregularities of the vasculature.

### Catheter Angiography

The gold standard for intracerebral vascular imaging remains catheter angiography. With this technique, a catheter is placed intra-arterially, and iodinated radiodense contrast dye is injected. The most commonly used form of angiography is *digital subtraction angiography (DSA)*, which is a technique that reduces artifacts by subtracting densities created by the overlying bony skull (Fig 2-15). The contrast dye outlines the column of flowing blood within the injected vessel and demonstrates stenosis, aneurysms, vascular malformations, flow dynamics, and vessel wall irregularities such as dissections or vasculitis. The procedure has an overall morbidity rate of approximately 1%, related primarily to ischemia from emboli or vasospasm, reactions to dye, or complications at the arterial puncture site (eg, hematoma).

Fifi JT, Meyers PM, Lavine SD, et al. Complications of modern diagnostic cerebral angiography in an academic medical center. *J Vasc Interv Radiol*. 2009;20(4):442–447.





**Figure 2-15** Digital subtraction angiogram, lateral view, demonstrates an aneurysm of the posterior communicating artery (*arrow*). ACA=anterior cerebral artery; ICA=internal carotid artery; MCA=middle cerebral artery. (Courtesy of Rod Foroozan, MD.)

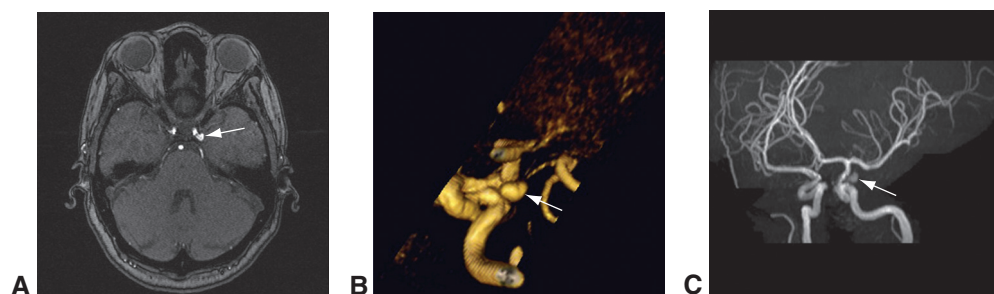
### Magnetic Resonance Angiography and Magnetic Resonance Venography

Because detection of an MRI signal requires brief excitation and decay of protons, moving tissue often passes out of the plane of assessment before the return signal can be detected; this results in the black “flow void” that characterizes scans of vascular channels with flow. However, because noncontrast MRA and MRV use a 3-dimensional assessment technique, protons that are excited in one slice and then move to another can be specifically imaged. MRA signals may also be obtained using gadolinium-enhanced images. This technique is particularly useful for visualizing the proximal large vessels of the chest and neck. MRA with gadolinium contrast also has a very short acquisition time, reducing the potential for patient movement-related artifacts.

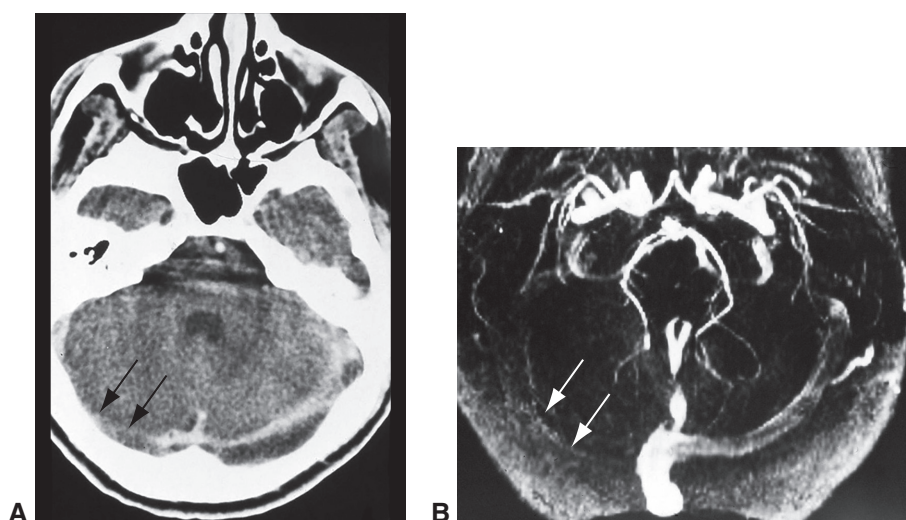
Overall, MRA noninvasively provides excellent information about large- and medium-size vessels (Fig 2-16). However, because the modality depends on flow physiology, it tends to overestimate vascular stenosis, and the reduced image resolution limits the ability to visualize smaller vessels or vasculitis. MRV may be helpful in excluding thrombosis within the dural venous sinuses (Fig 2-17), a condition that may cause papilledema (see Chapter 15).

### Computed Tomography Angiography and Computed Tomography Venography

Computed tomography angiography uses a high-speed spiral scanner that provides excellent vessel resolution, with 3-dimensional capability similar to that of MRA. The technique requires use of iodinated contrast dye and ionizing radiation and takes approximately 15 minutes to complete. Its sensitivity in detecting an aneurysm wider than 3 mm in diameter or stenosis greater than 70% is approximately 95%. Some medical centers prefer CTA over



**Figure 2-16** Magnetic resonance angiography (MRA) provides excellent information about large- and medium-size vessels in a noninvasive manner. **A**, An MRA source image shows an abnormality at the junction of the posterior communicating artery and the internal carotid artery (*arrow*). A volume-rendered 3-dimensional image (**B**) and a maximum intensity projection image (**C**) clearly show a posterior communicating artery aneurysm (*arrows*). (Courtesy of M. Tariq Bhatti, MD.)



**Figure 2-17** Venous sinus thrombosis. **A**, Postcontrast axial CT scan shows a right-sided transverse sinus thrombosis (*arrows*). **B**, Contrast-enhanced magnetic resonance venography shows complete thrombotic occlusion of the right transverse sinus (*arrows*). (Courtesy of Paul H. Phillips, MD.)

MRA for the detection of cerebral aneurysms, including those causing a CN III palsy (see Chapter 8, Fig 8-8). Multidetector CTA techniques can accurately detect aneurysms as small as 3–4 mm in diameter in nearly all patients with a CN III palsy. CTV is an excellent modality for visualizing the cerebral venous system and is less susceptible to artifacts than MRV is.

Vaphiades MS, ten Hove MW, Matthews T, Roberson GH, Sinclair A. Imaging of oculomotor (third) cranial nerve palsy. In: Lee AG, Sinclair AJ, Sadaka A, Berry S, Mollan SP, eds. *Neuro-Ophthalmology: Global Trends in Diagnosis, Treatment and Management*. Springer; 2019:133–151.

von Kummer R, Dzialowski I, Gerber J. Therapeutic efficacy of brain imaging in acute ischemic stroke patients. *J Neuroradiol*. 2015;42(1):47–54.

## Metabolic and Functional Imaging Modalities

*Magnetic resonance spectroscopy (MRS)*, *positron emission tomography (PET)*, and *single-photon emission computed tomography (SPECT)* are 3 examples of metabolic imaging modalities. MRS is used for diagnostic in vivo biochemistry and to obtain information about the integrity and metabolism of neural tissue. It can also distinguish edema from a tumor. PET involves the systemic administration of a short-half-life radioisotope, such as fluorodeoxyglucose, followed by imaging of the positrons produced during its decay. PET shows metabolic perfusion and can detect hypometabolism in patients with visual cortical dysfunction such as posterior cortical atrophy. SPECT uses an iodinated radiotracer or technetium-99m as a cerebral perfusion and extraction agent and is employed in situations similar to those for PET; however, it has poorer resolution and specificity.

*Functional MRI (fMRI)* depicts changes in regional blood flow in the brain in response to the performance of specific cognitive, sensory, or motor tasks. The biochemical basis of most fMRI techniques is the measurement of differences in blood oxygenation level-dependent (BOLD) responses during performance of tasks. fMRI is useful for intraoperative monitoring and for evaluating patients with cortical vision loss. Both functional and metabolic imaging may reveal altered regional metabolism from various causes in patients with cerebral visual impairment who have a normal MRI scan.

## Ultrasonography

Ultrasonography is a relatively inexpensive, rapid, noninvasive technique for imaging the carotid arteries, the orbit, and the globe. The images are based on the reflection of 8- to 20-MHz ultrasound waves at acoustic interfaces.

One form of ultrasonography, *carotid Doppler imaging*, is generally accurate at detecting cervical carotid artery stenosis. In ophthalmology, it is primarily used in patients with monocular transient visual loss due to acute retinal ischemia (see Chapter 6); however, it does not provide information about the more proximal or distal vessels. In addition, it is important to note that carotid Doppler imaging is not accurate at detecting a carotid artery dissection.

*Orbital Doppler ultrasonography* is useful for detecting reversal of normally retrograde venous blood flow within the superior ophthalmic vein in a suspected carotid-cavernous fistula. Orbital ultrasonography provides data on retrobulbar structures, including extraocular muscles, the optic nerve, and vessels, but it does not provide accurate imaging of the orbital apex. Orbital ultrasonography is also useful for evaluating the optic nerve head (ONH) and can help distinguish ONH edema from optic disc drusen, the latter being strongly echogenic (see Chapter 4, Fig 4-23C).

Ultrasonography is also used to image the temporal arteries in patients with giant cell arteritis (GCA). The accuracy of this modality is user dependent, with reported sensitivity of the “halo” sign ranging from 17.0% to 91.6%. Ultrasonography is commonly used in establishing the diagnosis of GCA in Europe, although it is used less commonly for this purpose in the United States.

Dejaco C, Ramiro S, Duftner C, et al. EULAR recommendations for the use of imaging in large vessel vasculitis in clinical practice. *Ann Rheum Dis*. 2018;77(5):636–643.

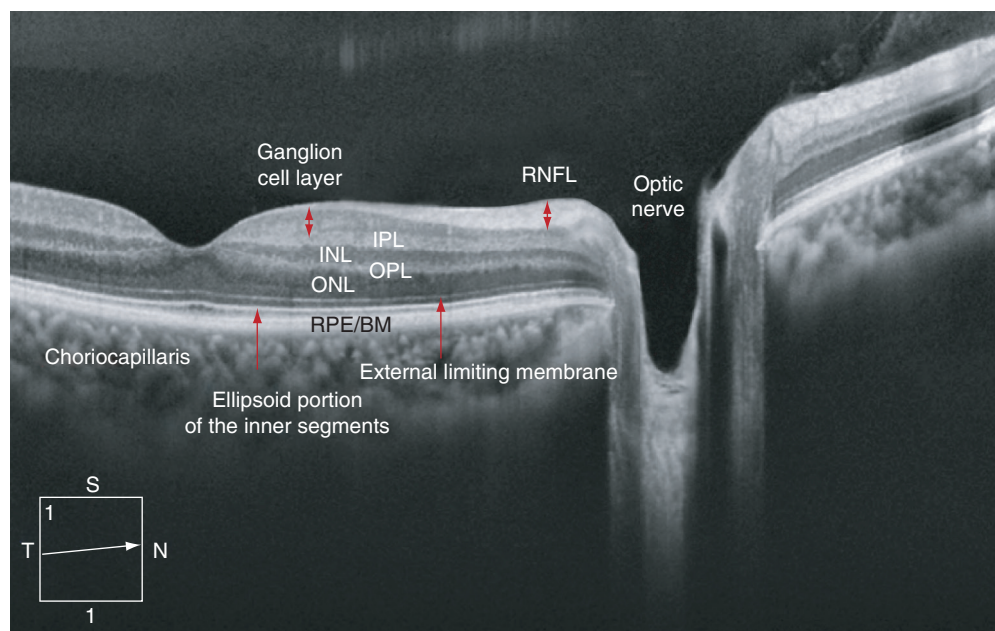
## Optical Coherence Tomography

By providing high-resolution images of the retinal layers and optic nerve, OCT has revolutionized the way we approach vision loss (Fig 2-18). The various layers of the retina can be segmented, and the presence or absence of thinning of the peripapillary retinal nerve fiber layer (pRNFL) and/or the ganglion cell–inner plexiform layer (GC-IPL) can help identify and differentiate optic neuropathies from retinopathies. Similarly, thickening of the pRNFL can be used to identify and follow papilledema.

As with neuroimaging, it is important to review the test results critically. In addition, systematic review of the OCT results is imperative for ensuring accurate interpretation of the data and identification of potential artifacts that, if misinterpreted, can lead to an incorrect diagnosis or false alarm or provide false reassurances.

A systematic approach to reading OCT results includes the following steps:

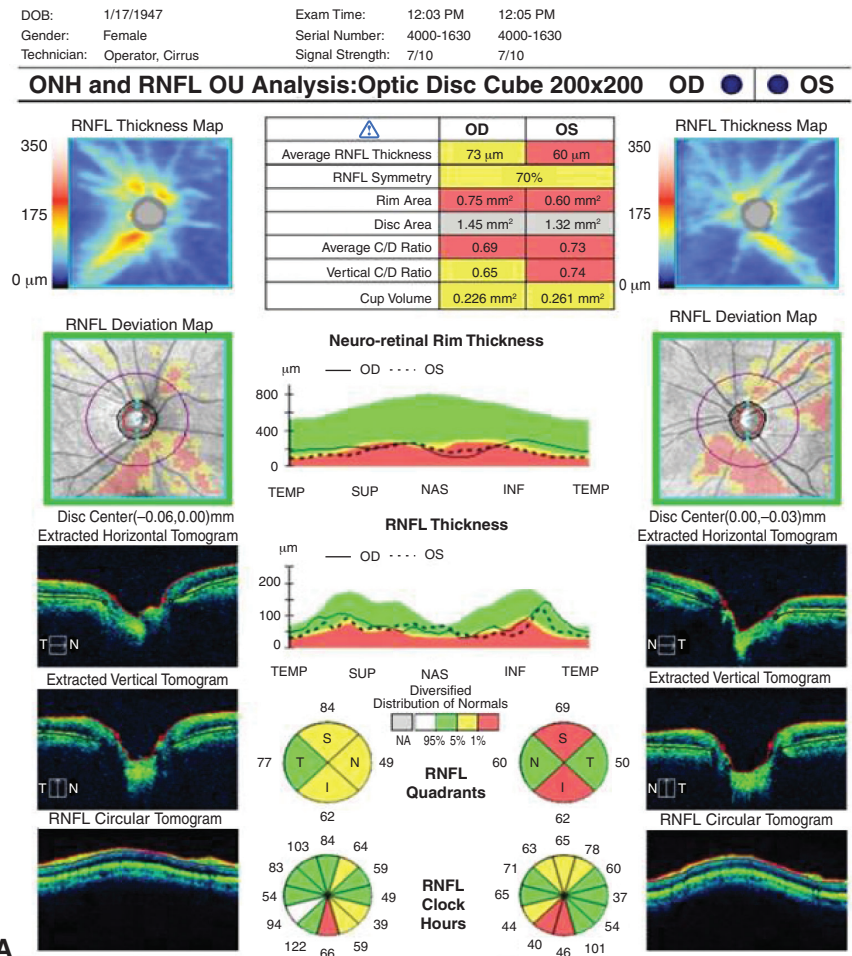
1. Confirm the patient's name and age.
  - Measurements are made against age-matched controls. If a date of birth is incorrectly entered, the absolute measurements will remain unchanged but the probability plot describing “normal” versus “abnormal” statistics will be off (Fig 2-19).



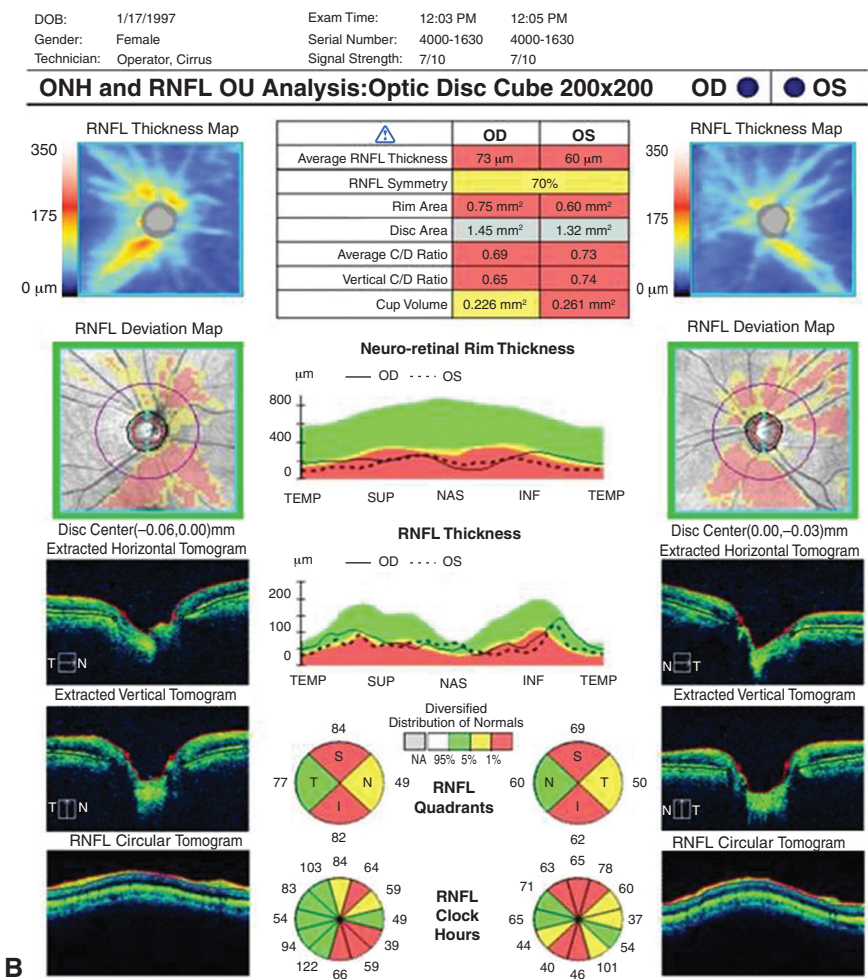
**Figure 2-18** Normal optical coherence tomography (OCT) scan of the optic nerve and retina. The layers of the retina are labeled. BM = Bruch membrane; INL = inner nuclear layer; IPL = inner plexiform layer; ONL = outer nuclear layer; OPL = outer plexiform layer; RNFL = retinal nerve fiber layer; RPE = retinal pigment epithelium. (Courtesy of John J. Chen, MD, PhD.)

2. Check the signal strength.
  - Lower signal strengths can preclude accurate location of retinal layer boundaries, creating significant artifacts in measurements of the pRNFL and GC-IPL (Fig 2-20).
3. Check the refractive error and, if available, the axial eye length.
  - Patients with high myopia (long axial eye length) or high hyperopia (short axial eye length) often have altered eye anatomy compared with that of patients with emmetropia. For example, patients with high myopia usually have a thinner measured pRNFL. In addition, the superior and inferior pRNFL bundles are typically displaced temporally compared with those of patients with emmetropia (Fig 2-21; see p. 81). Patients with high hyperopia may have the opposite changes. In patients who have pseudophakia or who have had refractive surgery, determination of axial eye length is particularly helpful because many of these changes in OCT measurements are anatomical and therefore are not affected by correction of the refractive error.
4. Interpret the optic nerve data.
  - The thickness and probability maps of the peripapillary retina should be examined for rectangular areas of absolute pRNFL loss that do not match the anatomical distribution of RNFL arcuate bundles. Nonanatomical areas of loss typically indicate errors in segmentation (see Fig 2-20). Signal dropout influences the pRNFL measurement only if it intersects the 3.4-mm circular ring around the ONH.
  - The fundus image and thickness maps should be compared to ensure that the identified ONH border and optic nerve cup correspond to the clinical estimation. Eye pathology, such as papilledema, can cause errors in these measurements (Fig 2-22; see pp. 82–83).
  - The OCT-based fundus image or en face image should be compared with the superimposed probability map for evidence of ocular torsion and to assess the angle of exit of the branches of the retinal arteries from the ONH, which roughly correlates with the distribution of the arcuate nerve bundles. This in turn helps to identify abnormal locations of the superior and inferior arcuate axonal bundles, which can cause “apparent” thinning compared with the normative database.
  - The temporal-superior-nasal-inferior-temporal (TSNIT) pRNFL plot should be examined and notes made of whether the location of the peaks corresponds to the location of the peaks from the normative database (see Fig 2-21). Common associations with a discrepancy are long or short axial eye length, abnormal location of vessels as they exit the ONH, and ocular torsion.
  - Unless a patient has long-standing severe optic neuropathy, local areas with pRNFL thickness less than 40  $\mu\text{m}$  are typically due to errors in segmentation.
5. Recognize that ocular disease can create errors in segmentation.
  - High degrees of papilledema impede identification of the layers of the retina, which can result in significant artifacts (see Fig 2-22).





- The measurement of macular GCL-IPL thickness is especially prone to segmentation error, especially in the presence of ONH edema or outer photoreceptor disease (eg, macular degeneration) (Fig 2-23 [see p. 84]; see also Fig 2-22). Unless a patient has long-standing severe optic neuropathy, GCL-IPL thickness less than 40  $\mu\text{m}$  is typically due to errors in segmentation.
6. Interpret subsequent scans to estimate disease progression.
- The same scan location should be compared between sequential scans.
  - Measurements using different brands of OCT machines cannot be directly compared.

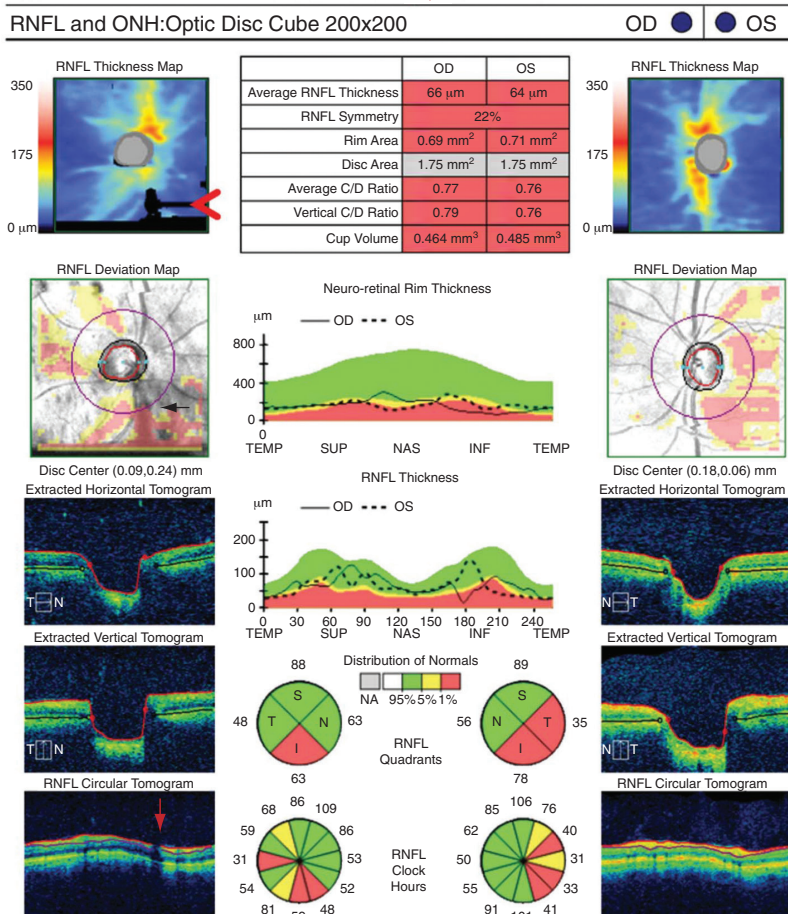


**Figure 2-19 (continued) B,** The date of birth is incorrectly entered as 1/17/1997 instead of 1/17/1947; therefore, this patient is compared against 24-year-old patients rather than 74-year-old patients. The absolute pRNFL thickness number does not change, but the right eye RNFL is now color coded red (<1% compared with age-matched controls) because of the error in the date of birth. (Courtesy of John J. Chen, MD, PhD.)

Figures 2-20 through 2-23 appear on pp. 80–84 of this chapter. A glossary of select neuroimaging terminology appears at the end of the chapter. The clinical applications of OCT are discussed further in Chapter 3.

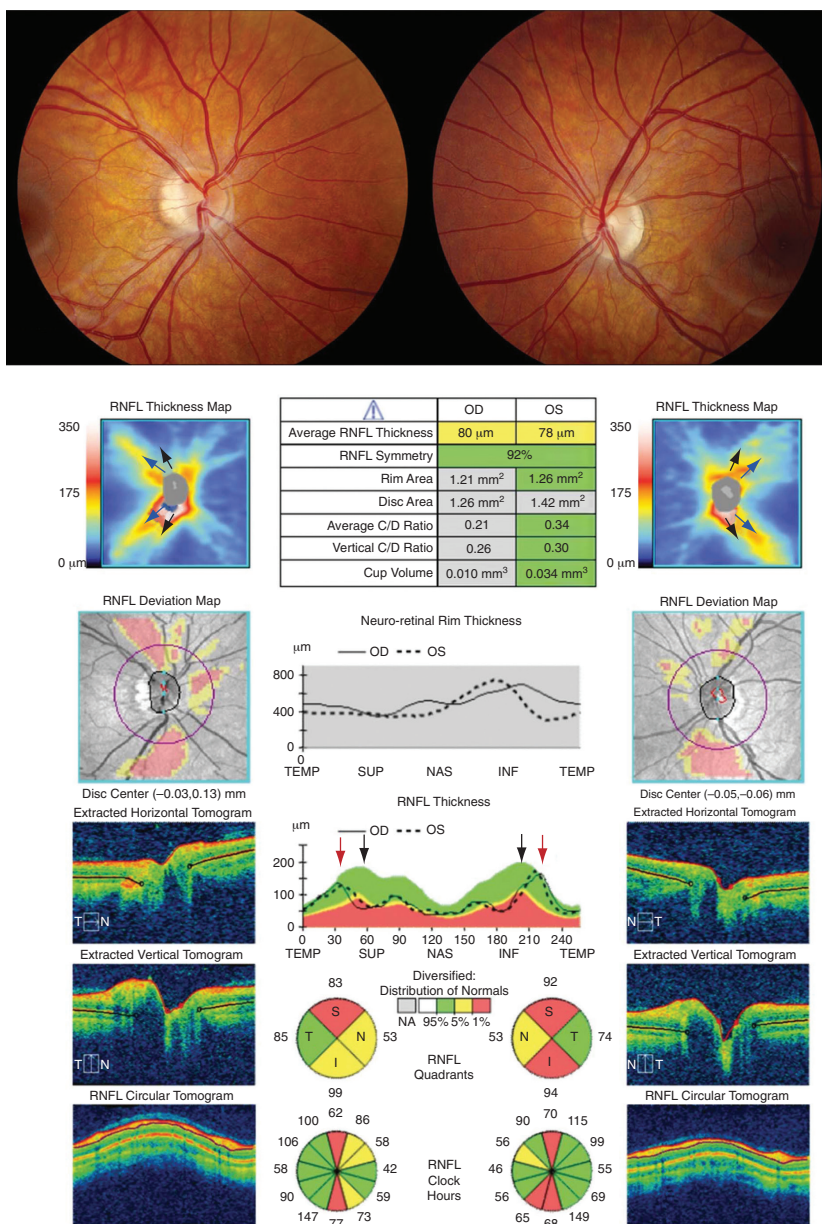
Chen JJ, Kardon RH. Avoiding clinical misinterpretation and artifacts of optical coherence tomography analysis of the optic nerve, retinal nerve fiber layer, and ganglion cell layer. *J Neuroophthalmol.* 2016;36(4):417–438.

DOB:                      Exam Time:  
Gender:                Technician: OPERATOR, CIRRUS  
Doctor:               Signal Strength: 6/10 ← 9/10

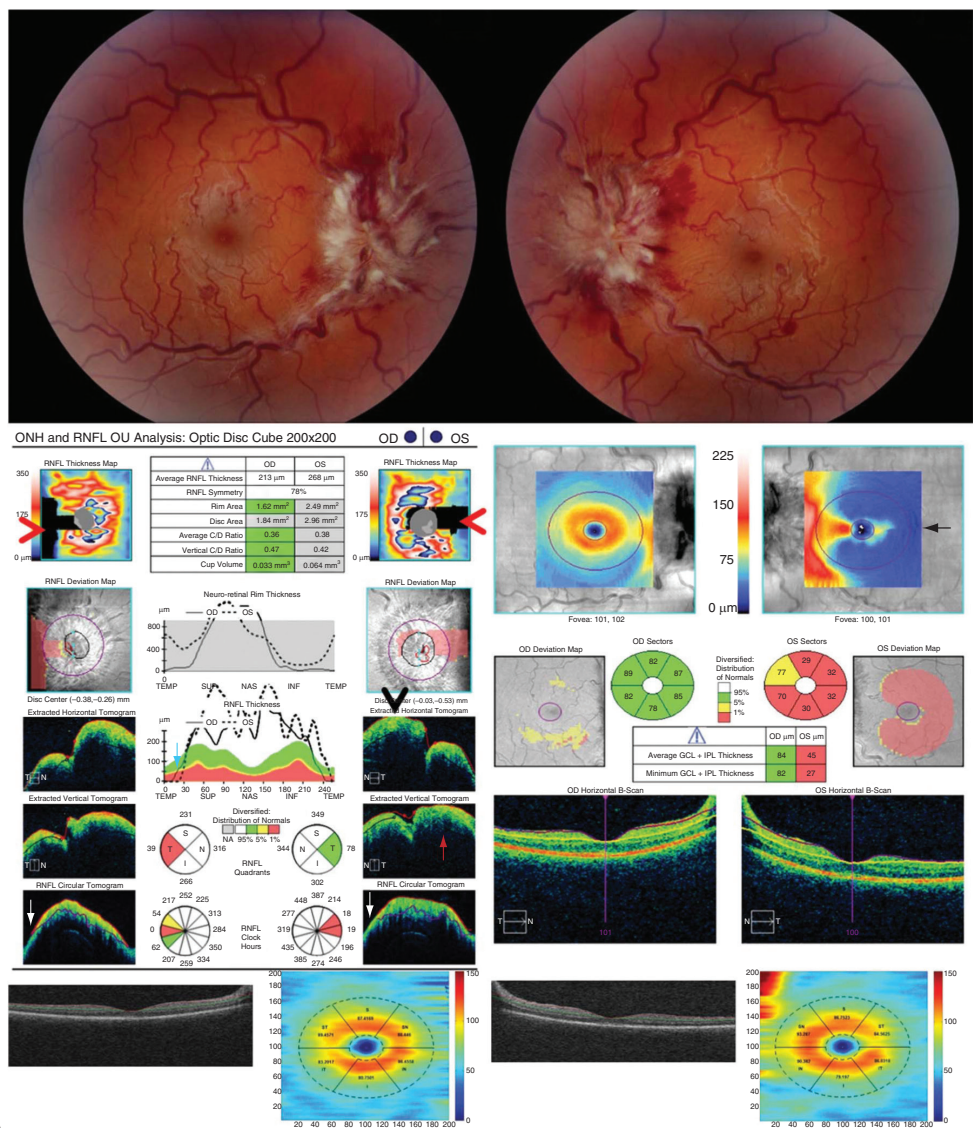


**Figure 2-20** Reduced signal strength can result in loss of retinal layer features and can introduce artifact in the pRNFL analysis. This patient has normal-tension glaucoma, left eye > right eye, and asteroid hyalosis in the right eye (*upper left image*), which has reduced the signal strength to 6/10 (*red arrow*). This causes an inferior regional error of segmentation of pRNFL thickness, seen as black rectangular areas of absolute thinning on the pRNFL thickness map (*red arrowhead*). Only a small portion of this segmentation error intersects the RNFL circular scan and has an effect on pRNFL thickness (pRNFL deviation map, *black arrow*), seen as a disruption of the normal segmentation on the RNFL circular tomogram (*red vertical arrow*). This causes an artificially low inferior quadrant pRNFL thickness in the right eye, especially at the 5 o'clock position. (*Reproduced with permission from Chen JJ, Kardon RH. Avoiding clinical misinterpretation and artifacts of optical coherence tomography analysis of the optic nerve, retinal nerve fiber layer, and ganglion cell layer. J Neuroophthalmol. 2016;36(4):417–438.*)





**Figure 2-21** Patients with myopia and long axial eye lengths have a decreased image size due to ocular magnification effects, leading to a smaller measured ONH size and an underestimation of pRNFL thickness. These patients also often have blood vessels and RNFL arcuate bundles deviated more temporally than those in a normal eye, which increases temporal pRNFL thickness and decreases superior and inferior pRNFL thicknesses. This patient is a  $-8$  D myope with an artifactually low average pRNFL thickness. In addition, pRNFL peaks and arteries are shifted temporally, resulting in superior and inferior pRNFL thinning on thickness analysis. The superior and inferior arcuate bundles (*blue arrows*) are more temporally displaced on the pRNFL thickness map compared to those of a patient without myopia (*black arrows*). The temporal shift of pRNFL peaks can also be seen by examining the temporal-superior-nasal-inferior-temporal (TSNIT) pRNFL thickness profile plot and by comparing the superotemporal and inferotemporal peaks of both eyes (*red arrows*) with those of the population shown in green (*black arrows*). Note how the shift in location of the peaks causes apparent abnormal red areas (less than or equal to the first percentile of normal) in the probability maps and sector plots. (Reproduced with permission from Chen JJ, Kardon RH. Avoiding clinical misinterpretation and artifacts of optical coherence tomography analysis of the optic nerve, retinal nerve fiber layer, and ganglion cell layer. J Neuroophthalmol. 2016;36(4):417–438.)

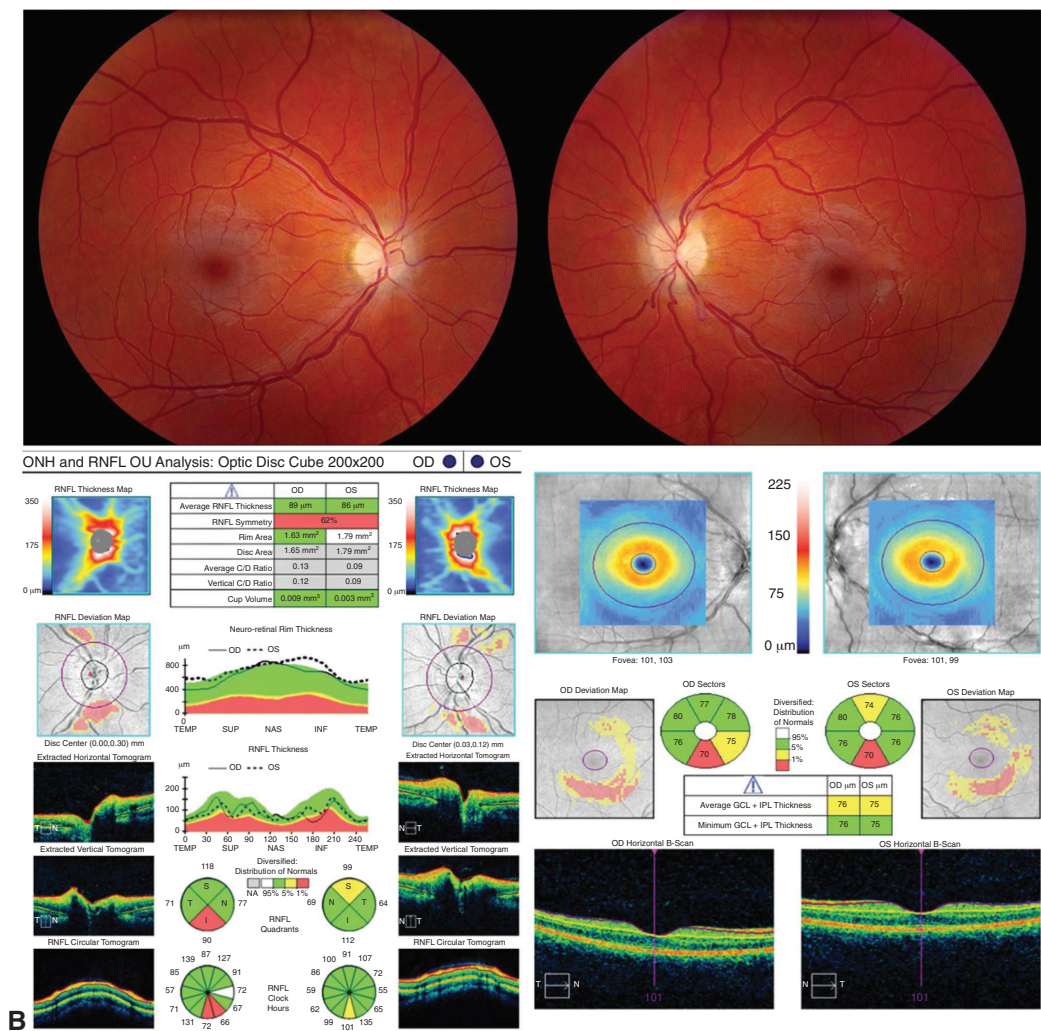


A

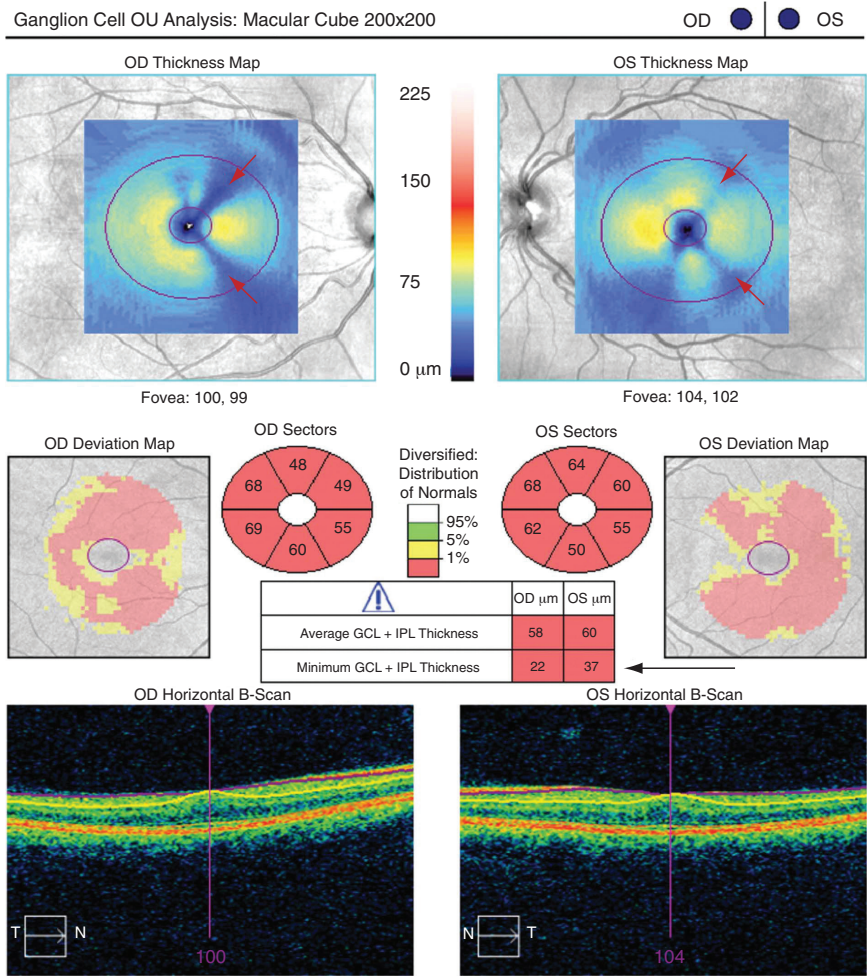
**Figure 2-22** Significant ONH edema causes errors in segmentation on OCT owing to distortion of the retinal layers surrounding the optic nerve. **A**, This patient presented with Frisén grade 4 papilledema in both eyes from idiopathic intracranial hypertension (*upper images*), which led to errors in measuring ONH area, rim area, and pRNFL thickness on OCT (*middle left*). The ONH area is artificially enlarged in the left eye because the termination of Bruch membrane is obscured by the edema and cannot be correctly identified as in the B scan (*red arrow*). The pRNFL thickness is underestimated because of the incorrect segmentation of the temporal pRNFL in both eyes and a small portion of the nasal pRNFL in the left eye, which is apparent as absolute defects (*black rectangles*) within the pRNFL thickness map that do not follow the anatomical distribution of the RNFL arcuate bundles (*red arrowheads*). This occurs because of a decreased ability to accurately segment the layers, owing to the ONH edema (temporal pRNFL, both eyes, *white arrows*) and decentering of the pRNFL data on the z-axis, resulting in truncation of the scan (nasal pRNFL, left eye, *black arrowhead*), which can be seen on the B scan. A nonphysiologic decrease in pRNFL thickness to 0  $\mu$ m temporally on the TSNIT pRNFL thickness plot can be seen in both eyes (*blue arrow*).

(Continued)





**Figure 2-22 (continued)** In addition, the ONH edema causes an error in segmentation of the ganglion cell layer–inner plexiform layer (GCL–IPL) complex in the left eye (*middle right, black arrow in part A on previous page*). Note the unusual distribution of the GCL–IPL thickness on the color map of the left eye, providing a clue that the algorithm is failing. The Iowa Reference algorithm, which utilizes 3-dimensional information, shows accurate segmentation of the GCL–IPL complex of both eyes (*lower images of part A on previous page*). **B**, OCT of patient shown in part A 3 months after medical treatment for idiopathic intracranial hypertension now shows accurate segmentation of the pRNFL, ONH size, and GCL–IPL with some residual loss of pRNFL and GCL–IPL thicknesses. (Reproduced with permission from Chen JJ, Kardon RH. Avoiding clinical misinterpretation and artifacts of optical coherence tomography analysis of the optic nerve, retinal nerve fiber layer, and ganglion cell layer. J Neuroophthalmol. 2016;36(4):417–438.)



**Figure 2-23** Errors in segmentation of the GCL-IPL complex. This patient has ocular hypertension with normal automated fields, but the GCL-IPL thickness is artificially decreased owing to errors in segmentation. This can be seen as spokes of blue “thinning,” or “propeller sign,” in the thickness maps (*red arrows*). The minimum GCL-IPL thickness is less than 40  $\mu\text{m}$  in both eyes (*black arrow*), which also often indicates an error in segmentation, especially when the average GCL-IPL thickness value is significantly greater than the minimum thickness (eg, 58  $\mu\text{m}$  vs 22  $\mu\text{m}$  for the right eye shown here). (*Reproduced with permission from Chen JJ, Kardon RH. Avoiding clinical misinterpretation and artifacts of optical coherence tomography analysis of the optic nerve, retinal nerve fiber layer, and ganglion cell layer. J Neuroophthalmol. 2016;36(4):417–438.*)

## Glossary of Select Neuroimaging Terminology

**BOLD (blood oxygenation level–dependent) imaging** The standard technique for fMRI studies used to demarcate areas of high activity in a patient’s brain while the patient performs a specific task.

**CTV (computed tomography venography)** CT technique in which the venous vasculature is visualized. It is less susceptible to artifacts than MRV is.

**DWI (diffusion-weighted imaging) and ADC (apparent diffusion coefficient)** MRI techniques used to detect acute and subacute cerebral ischemia and to differentiate vasogenic edema from cytotoxic edema.

**FLAIR (fluid-attenuated inversion recovery)** MRI technique that highlights T2-hyperintense abnormalities adjacent to cerebrospinal fluid (CSF)-containing spaces, such as the ventricles, by suppressing CSF signal intensity.

**fMRI (functional magnetic resonance imaging)** MRI technique that depicts brain areas of increased activity during a specific task, such as reading.

**Gadolinium** Paramagnetic contrast agent administered intravenously to enhance lesions; typically used for MRI.

**IR (inversion recovery) and TI (interpulse time)** MRI pulse sequence that nulls the bright signal of fat or water to create a FLAIR or STIR image. During MRI, initial 180° radiofrequency pulses are followed by a 90° pulse and immediate acquisition of the signal.

**mGy (milligray)** Unit used to measure the absorbed dose of radiation.  $1 \text{ mGy} = 10^{-3} \text{ Gy}$ .

**MRV (magnetic resonance venography)** MRI technique that is employed to visualize the venous vasculature.

**Relaxation** Process by which an element releases (re-emits) energy that has been absorbed from the radiofrequency pulses during an MRI sequence.

**SE (spin echo)** Most commonly, a 180° pulse that follows a 90° pulse. For T2-weighted images, the 90° pulse is followed by two 180° pulses. The first 180° pulse is administered at one-half the echo time (TE), and the second 180° pulse is administered 1 full TE later. The “first echo” image is referred to as *proton density*, and the “second echo” is T2-weighted.

**STIR (short tau [or TI] inversion recovery)** MRI technique that suppresses the bright signal of fat by combining short TI inversion recovery and a fast SE sequence.

**T1** Time required for 63% of protons to return to the longitudinal plane after cessation of a 90° radiofrequency pulse. This is also referred to as the *longitudinal*, or *spin-lattice*, relaxation time. T1 has a shorter TE and repetition time (TR) than T2.

**T2** Time required for 63% of the magnetic field in the transverse plane created by the radiofrequency pulse to dissipate. This dispersion of the magnetic vector corresponds to the exchange of spin among protons and is referred to as *transverse*, or *spin-spin*, relaxation time.

**TE (time to echo)** Time following the radiofrequency pulse in which a signal is assessed.

**Tesla (T)** The unit of measurement of magnetic field strength.

**TR (time to repetition)** Time following the radiofrequency pulse to repetition of the pulse.

---



# The Patient With Decreased Vision: Evaluation



*This chapter includes related videos. Go to [www.aao.org/bcscvideo\\_section05](http://www.aao.org/bcscvideo_section05) or scan the QR codes in the text to access this content.*

### Highlights

---

- Dropout of the peripapillary retinal nerve fiber layer may precede optic atrophy and can be visualized as rakelike defects with a red-free filter.
- Automated perimetry using Humphrey Field Analyzer (HFA) 30-2 and 24-2 programs can detect most visual field defects, as approximately 80% of the visual cortex is devoted to the central visual field.
- Due to the 6° test spacing of HFA 30-2 and 24-2 programs used in automated perimetry, HFA 10-2 perimetry may better delineate a small central or paracentral scotoma.
- Fluorescein angiography can be used to assess for delayed or absent choroidal filling, which is highly suggestive of giant cell arteritis.
- Optical coherence tomography can provide quantitative measurements of the peripapillary retinal nerve fiber layer thickness, which gives indirect information about the axonal integrity of the optic nerve.
- In cases of vision loss with minimal ophthalmoscopic findings, electroretinography can be extremely useful in evaluating for retinopathy.

### History

---

In cases of decreased vision, 3 aspects of the patient's history—in addition to the age of the patient—are crucial in determining the etiology:

- laterality of the vision loss
- time course of the vision loss
- signs and symptoms associated with the vision loss

### Unilateral Versus Bilateral Involvement

Establishing the laterality of the vision loss is essential to localizing the lesion. Unilateral vision loss typically indicates a lesion anterior to the optic chiasm, whereas bilateral vision



loss may reflect a bilateral ocular, chiasmal, or retrochiasmal lesion. Patients reporting vision loss should be asked whether they have checked the vision of each eye individually. A patient with a right homonymous hemianopia may mistake the right-sided visual field defect as a problem with the vision of the right eye only. Binocular involvement may not be appreciated until the patient is examined.

### **Time Course of Vision Loss**

Determining the speed of onset of vision loss can aid the clinician in determining the etiology. Sudden onset (ie, within minutes) without subsequent progression usually indicates an ischemic event, such as arterial occlusion. Sudden onset with subsequent progression over days to weeks can occur with ischemic optic neuropathy. Gradual vision loss that evolves over days to weeks typically signifies inflammation or demyelination. Gradual progression over months or years is typical of compressive lesions, toxic or nutritional optic neuropathies (although ethanol and methanol poisoning present more acutely), and open-angle glaucoma.

It is important to differentiate between sudden loss of vision and sudden awareness of vision loss. Patients may become acutely aware of a chronic process only upon covering the uninvolved eye or only after the second eye becomes affected. Although the time course may suggest a cause of vision loss, the time courses of the various etiologies overlap considerably (Table 3-1).

### **Associated Signs and Symptoms**

Ipsilateral periorbital pain that increases with eye movement occurs commonly in optic neuritis. Associated neurologic symptoms of focal weakness, numbness, tingling, imbalance, or urinary or stool incontinence may suggest demyelinating disease. Proptosis, change in facial sensation, or diplopia suggests an orbital or cavernous sinus process. Headache, jaw claudication, scalp tenderness, neck or ear pain, anorexia, weight loss, low-grade fever, or myalgias suggest giant cell arteritis (GCA). Symptoms such as metamorphopsia, nyctalopia, hemeralopia, floaters, photopsias, and photophobia suggest a retinal etiology.

### **Cognitive Status**

It is important that the clinician consider the patient's cognitive status when evaluating for a potential neuro-ophthalmic cause of vision loss. Patients with cognitive impairment often require extra testing time, which may determine the type of test selected or the way the test is conducted. Also, it is essential to ensure that uncorrected refractive error is ruled out. Refractive error can be efficiently assessed with retinoscopy. In some cases, color vision can be more accurately evaluated with tracing of the figures than with naming of the shapes or numbers. For visual field testing, manual tests may be more reliable than automated ones if a patient requires extra response time. Finally, the clinician should remember that polypharmacy may contribute to cognitive impairment and visual symptoms, especially in older patients.

**Table 3-1 Etiologies of Vision Loss Based on Time Course**

Time Course	Optic Nerve	Retina	Retrogeniculate Pathway
Acute, nonprogressive	ION	Retinal artery occlusion	Infarction, PRES
Acute, progressive	ACG, ION, orbital mucormycosis, pituitary apoplexy	CNV, CSC, posterior uveitis, retinal detachment, retinal vein occlusion, vitreous hemorrhage	Metastasis or primary brain tumors, PRES
Subacute (progression over days to weeks)	Autoimmune or demyelinating optic neuritis, infectious or inflammatory optic neuropathy, LHON, metabolic optic neuropathy (eg, MMA), neuroretinitis, TED with apical compression	Paraneoplastic retinopathy (CAR, MAR), posterior uveitis, pseudophakic macular edema, vasculitis	Metastasis or primary brain tumors
Chronic (progression over months to years)	Compressive optic neuropathy, DOA, nutritional or toxic optic neuropathy, OAG, papilledema	DME, macular ischemia, nonparaneoplastic autoimmune retinopathy, RP and other retinal degeneration	AVM or primary brain tumors

ACG = angle-closure glaucoma; AVM = arteriovenous malformation; CAR = cancer-associated retinopathy; CNV = choroidal neovascularization; CSC = central serous chorioretinopathy; DME = diabetic macular edema; DOA = dominant optic atrophy; ION = ischemic optic neuropathy; LHON = Leber hereditary optic neuropathy; MAR = melanoma-associated retinopathy; MMA = methylmalonic acidemia; OAG = open-angle glaucoma; PRES = posterior reversible encephalopathy syndrome; RP = retinitis pigmentosa; TED = thyroid eye disease.

*Note:* Unilateral retrogeniculate lesions result in homonymous hemianopic visual field defects. Bilateral retrogeniculate lesions result in bilateral hemianopic visual field defects or cortical visual impairment.

## Examination

Examination of the patient with decreased vision requires performing a full neuro-ophthalmic evaluation, which includes assessment of the following: corrected distance visual acuity and near visual acuity, color vision, pupils, peripheral vision, stereopsis, ocular motility and alignment, intraocular pressure, eyelids, orbit, anterior segment, and posterior segment.

## Visual Acuity Testing

Corrected distance visual acuity (CDVA; also called *best-corrected visual acuity*) should be obtained with refraction. Vision improvement with pinhole viewing indicates a refractive error. For patients with visual acuity levels worse than 20/400, the clinician should quantify


CDVA using a standard 20/200 E optotype with documentation of the distance at which the patient can identify the letter orientation using standard Snellen notation (eg, “5/200”). This test provides a more accurate and reproducible measurement than does the finger-counting method.

Distance and near corrected visual acuity should be similar; a disparity may suggest a specific pathology. The clinician should document the presence of eccentric fixation (possible central scotoma), tendency to read half of the eye chart (possible hemianopic field defect), or improvement in CDVA when single optotypes are read (which may suggest amblyopia).

### Color Vision Testing

Color vision testing complements visual acuity assessment. Optic nerve disease, particularly demyelinating optic neuritis, may disproportionately affect color vision compared with CDVA. In macular disease, visual acuity and color vision tend to decline correspondingly; the exception is cone dystrophy, in which color vision is more significantly decreased than visual acuity. Thus, an optic neuropathy rather than a maculopathy is the more likely etiology in the differential diagnosis for an eye with 20/30 visual acuity but severe loss of color vision. In optic neuropathy, persistent dyschromatopsia can occur even after recovery of visual acuity.

Color vision should be tested separately in each eye to detect unilateral disease. The Ishihara test (Fig 3-1A) uses a series of pseudoisochromatic color plates to test color discrimination along the protan (red) and deutan (green) axes. The plates were designed to detect congenital red-green color deficiencies and may fail to detect mild cases of acquired dyschromatopsia. Bilateral, symmetric color vision loss in men may signify congenital color deficiency rather than bilateral optic neuropathies. The Hardy-Rand-Rittler (HRR) plates can



**Figure 3-1** Pseudoisochromatic plates for color vision testing. **A**, Ishihara plate. **B**, Hardy-Rand-Rittler (HRR) plate. (Courtesy of Zoë R. Williams, MD. Photography by Brittany Figenscher, CRA.)

be used to screen for tritan (blue-yellow) axis defects as well as red-green defects (Fig 3-1B). Blue-yellow color defects often accompany acquired optic neuropathy but also can occur in a maculopathy.

More detailed color testing may comprehensively characterize a color vision defect. In the Farnsworth panel D-15 test, the patient is asked to arrange 15 colored discs in order of hue and intensity. The Farnsworth-Munsell 100-hue test is the most comprehensive test and provides the best discrimination; however, it requires a substantial amount of time to take (patients arrange 4 sets of 25 colored discs) and score, thus limiting its use in routine clinical testing. Color vision testing is discussed further in BCSC Section 12, *Retina and Vitreous*.

### Pupillary Testing

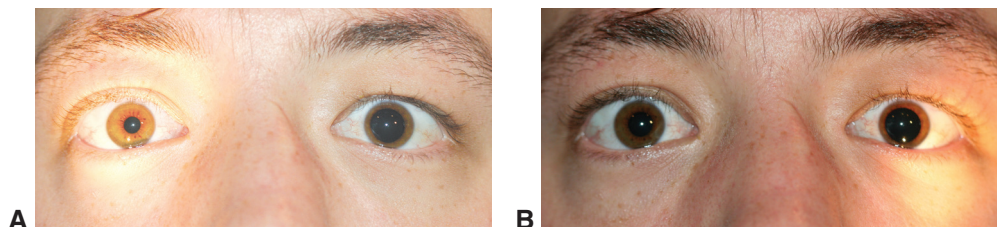
Normally, light directed at either pupil causes equal constriction of both pupils (see Chapters 1 and 11). When light is shined into an eye with impaired conduction of the afferent pupillomotor signal along its optic nerve, pupillary constriction in both eyes is slower and smaller in amplitude compared with the response that occurs when light is shined into the eye with normal optic nerve conduction. In other words, both the direct and the consensual response are sluggish. This equal consensual response enables detection of a relative afferent pupillary defect (RAPD) as the light is moved back from the side with the normal conduction to the side with impaired conduction, causing dilation of the pupil on the impaired conduction side.

The most popular clinical method for detecting an RAPD is the swinging flashlight test (Video 3-1), which compares the pupillary response in the 2 eyes when they are tested with the same light source. The test involves swinging a bright light (which is shined directly into the pupil along the visual axis) between the 2 eyes. If the afferent input is significantly asymmetric, the pupils redilate immediately when the light is shined into the affected eye (Fig 3-2).



#### VIDEO 3-1 Left relative afferent pupillary defect.

Courtesy of M. Tariq Bhatti, MD. Narration by Helen Danesh-Meyer, MD, PhD.



**Figure 3-2** Assessing for a relative afferent pupillary defect (RAPD) in a patient with left traumatic optic neuropathy; the left pupil is pharmacologically dilated. **A**, The right pupil *constricts* in response to light directed at the right eye only. **B**, The right pupil *dilates* in response to light directed at the left eye only, indicating a left RAPD. (Courtesy of Michael S. Lee, MD.)

**Testing for a Relative Afferent Pupillary Defect (RAPD)**

1. Dim the ambient lighting; it is easier to evaluate pupillary movement when the pupil size is larger.
2. Ask the patient to fixate at distance in order to avoid pupillary miosis from accommodation.
3. Use a well-charged, bright, steady source of diffuse light, such as a standard “muscle light.” A light source that is too dim or too bright may produce false-positive or false-negative results, respectively.
4. Stimulate 1 eye for 2–3 seconds, then quickly move across the bridge of the nose to stimulate the other eye for 2–3 seconds. Alternate several times. Do not rely on a single observation.
5. Observe the initial pupillary constriction (velocity and amplitude) and any pupillary dilation. A dense RAPD is easily detected because an affected eye’s pupil dilates when stimulated. A mild to moderate RAPD is more difficult to detect because the abnormal pupil may still constrict, but less vigorously than the normal pupil.
6. If 1 pupil does not react (eg, because of iris trauma, synechiae, or pharmacologic mydriasis or miosis), evaluate the direct and consensual responses of the functioning pupil. This will demonstrate the asymmetry of responses and enable detection of the RAPD (see Fig 3-2).
7. Grade the RAPD on a scale from trace to 4+, with 4+ representing highest severity, or quantify it using neutral-density filters. The filters, placed in front of the unaffected eye, decrease the intensity of the light stimulus. Beginning with the lowest 0.3 log unit, repeat the swinging flashlight test. If an RAPD is still detected, place increasingly darker filters over the unaffected eye until the RAPD “disappears.” At this balance point, the light input from the unaffected eye with the filter matches the light input from the affected eye. Quantify the RAPD by the strength of the neutral-density filter needed over the unaffected eye to reach the balance point.

**Notes:**

Bilateral optic neuropathies, when symmetric, may show sluggish pupillary responses but no relative difference between the 2 eyes (and therefore no RAPD).

The RAPD magnitude correlates with the differential degree of damage to retinal ganglion cells and their axons. A prominent RAPD can occur with normal visual acuity if significant visual field damage is present.

An RAPD does not cause anisocoria.

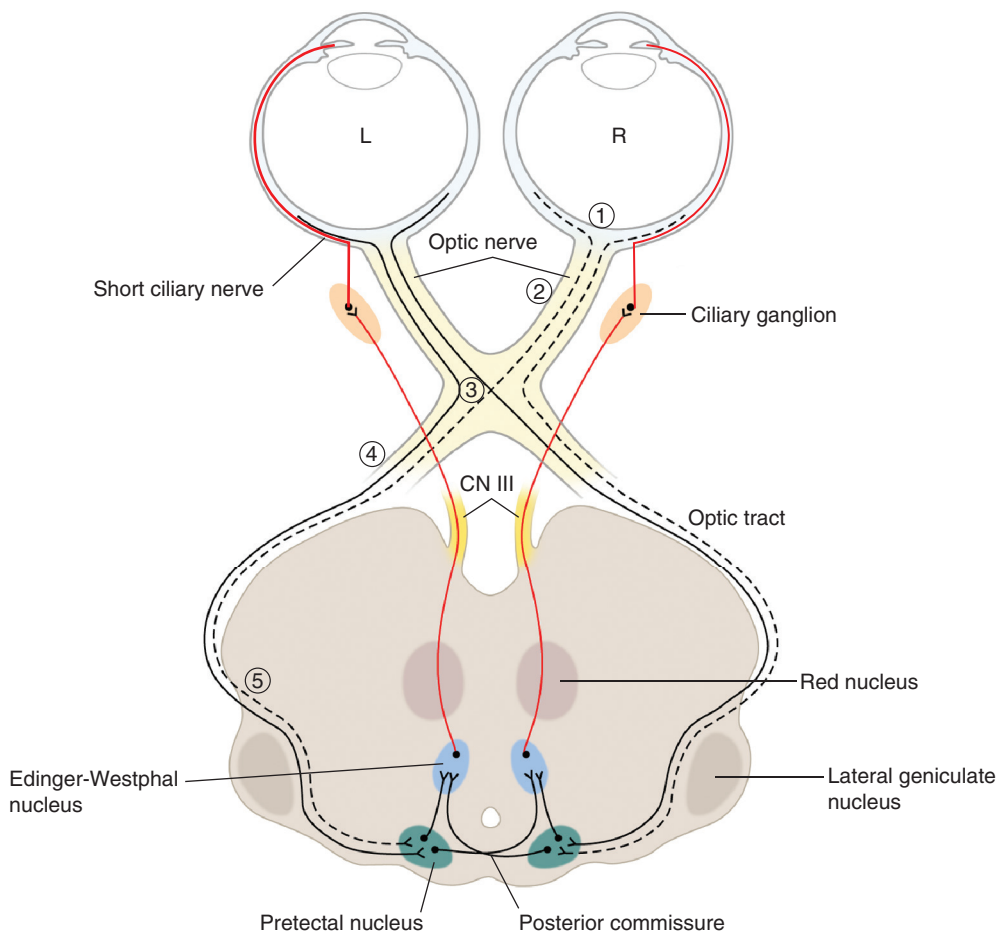
An RAPD is an extremely reliable and sensitive indicator of optic nerve dysfunction. Its absence generally indicates that there is no optic neuropathy or there is bilateral optic nerve involvement. Less commonly, an RAPD may result from substantial retinal disease, such as a central retinal artery occlusion, ischemic central retinal vein occlusion, macular scar, or retinal detachment. Chiasmal lesions may produce an RAPD secondary to asymmetric optic nerve involvement. In patients with a unilateral optic tract lesion, a mild



RAPD may exist on the side of the temporal visual field defect (contralateral to the side of the lesion). This has been explained by the difference in light sensitivity between the intact temporal and nasal hemifields. Melanopsin retinal ganglion cells, which are intrinsically photosensitive, are responsible for most of the pupillary light response, and the proportion of nerve fibers that cross is greater than the proportion of those that do not cross. An RAPD may also occur in the setting of a lesion of the brachium of the superior colliculus, in which case there is no loss of vision, color vision, or visual field (Fig 3-3).

### CLINICAL PEARL

In rare cases, media opacities such as a dense cataract can result in a contralateral RAPD, and dense amblyopia can induce an ipsilateral RAPD.



**Figure 3-3** A lesion occurring at the following locations can cause a right RAPD: 1, right retina; 2, right optic nerve; 3, chiasm (if an asymmetric lesion); 4, left optic tract; and 5, left brachium of the superior colliculus in the midbrain. (Illustration by Christine Gralapp.)

Certain factors, such as dark irides or sluggish, dilated, or miotic pupils, can make it difficult to elicit an RAPD. For evaluation of the pupillary light reflex in eyes with dark irides or miotic pupils, a modified technique, in which the patient views in upgaze and fixates at distance, may be helpful. Tests of perceived color intensity and subjective sense of brightness can suggest an underlying optic neuropathy associated with an RAPD, although these tests can lead to false-positives in suggestible patients. Red perception testing requires a red target, such as the cap of a cycloplegic eyedrop bottle. Assessment of brightness sense requires a bright light source, such as a muscle light or an indirect ophthalmoscope set at 6 V. For either test, the clinician directs the patient to look at the target, which is held 30 cm from the eye and is exposed to each eye for the same length of time. The clinician then asks the patient whether the light is of equal brightness (or whether the target is equally red) in both eyes. If the patient indicates a difference between the eyes, the target is held in front of the “brighter” or “redder” eye first, before the target is switched to the other eye. The patient is asked, “If the light is 100% bright (the target is 100% red) in this eye, what percentage is it in the other eye?” The subjective perception of dimmer light suggests the possibility of underlying optic neuropathy in that eye.

Danesh-Meyer HV, Papchenko TL, Savino PJ, Gamble GD. Brightness sensitivity and color perception as predictors of relative afferent pupillary defect. *Invest Ophthalmol Vis Sci*. 2007;48(8):3616–3621.

Hsu JL, Weikert MP, Foroozan R. Modified upgaze technique for pupil examination. *J Neuroophthalmol*. 2010;30(4):344–346.

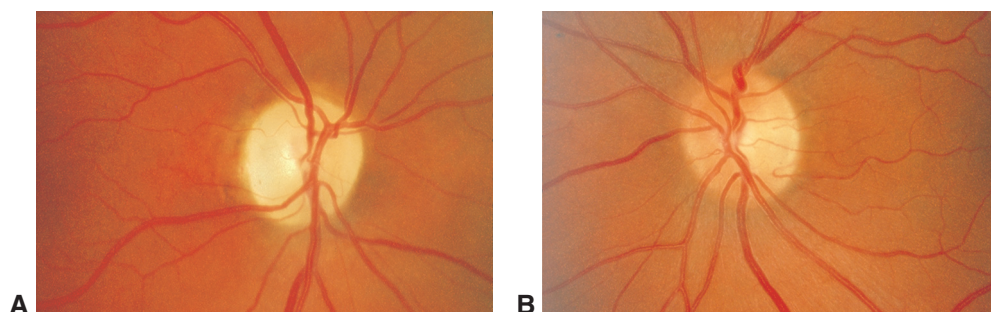
Kawasaki A, Miller NR, Kardon R. Pupillographic investigation of the relative afferent pupillary defect associated with a midbrain lesion. *Ophthalmology*. 2010;117(1):175–179.

## Fundus Examination

Fundus examination may reveal media opacities or fundus abnormalities that explain a patient’s decreased vision. The clarity of the view with the direct ophthalmoscope can suggest the degree of visual impairment caused by the media opacity. Using either direct ophthalmoscopy or slit-lamp biomicroscopy, the clinician can assess the appearance of the optic nerve head (ONH) and macula. The ONH is examined for evidence of pallor, edema, cupping, excavation, or other abnormalities. The macula is examined for evidence of pigmentary disturbance, edema, scarring, or other disruption of structural integrity.

### **Optic nerve head pallor**

Optic nerve head pallor indicates optic atrophy, which is the hallmark of damage to the retinal ganglion cells. Damage to any portion of the anterior visual pathway (from the ganglion cell bodies to their synapses at the lateral geniculate nucleus) can cause ONH pallor, which does not occur immediately after injury but takes at least 4–6 weeks from the time of axonal damage. Severe damage causes the ONH to appear chalky white (Fig 3-4). Mild forms of pallor remain more difficult to detect. Evaluation of the capillary net, the network of fine blood vessels on the ONH, may be helpful; the net becomes thin or absent in early atrophy even when pallor is still very mild. In addition, dropout of the peripapillary retinal nerve fiber layer (pRNFL) may precede the development of pallor. When viewed with a red-free filter, fine defects representing pRNFL dropout appear as dark bands among normal striations.



**Figure 3-4** Optic nerve head (ONH) pallor. **A**, Diffuse optic atrophy. **B**, Normal ONH appearance. (Courtesy of Steven A. Newman, MD.)

These defects, called *rakelike defects* owing to their similarity to rake marks in soil (Fig 3-5), initially affect the thickest portion of the pRNFL, the superior and inferior arcades.

True temporal pallor must be carefully distinguished from the apparent pallor of the ONH in a pseudophakic eye, which is caused by change in light filtration through the intraocular lens. Assessment for true ONH pallor can also be difficult in myopic eyes because of optic disc tilt. Optical coherence tomography of the pRNFL can be used to distinguish true ONH pallor from the appearance of pallor in a pseudophakic or myopic eye.

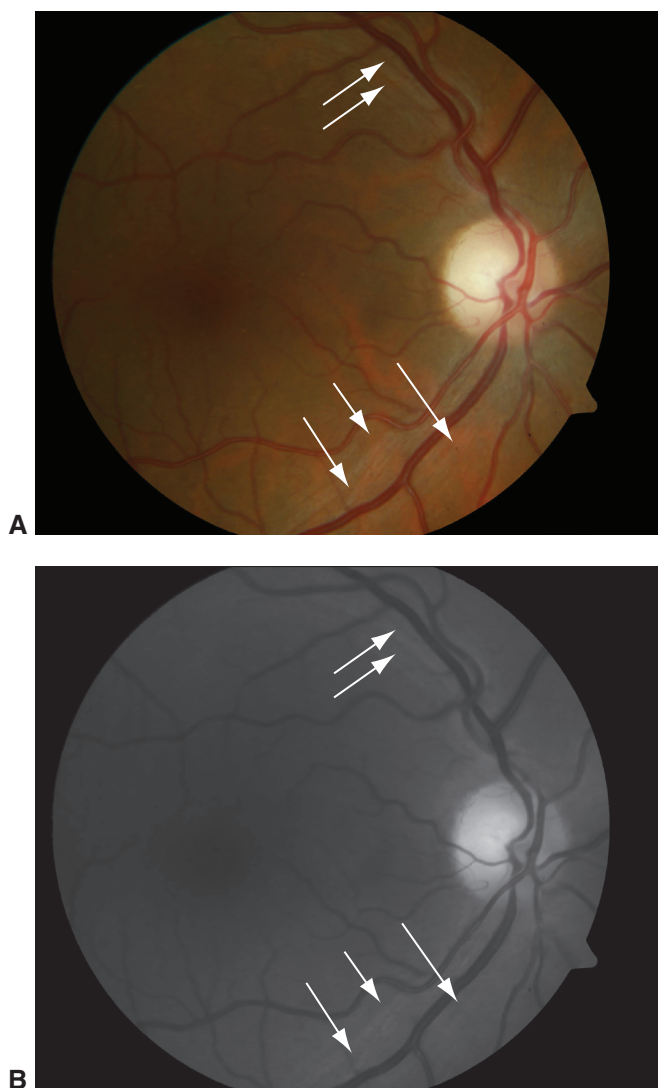
### **Optic nerve head edema**

Optic nerve head edema can be caused by increased intracranial pressure (Fig 3-6) (*papilledema*; see Chapter 4), local mechanical compression, ischemia, and inflammation. Either ONH hyperemia or pallor and arteriolar attenuation or venous engorgement can accompany ONH edema, depending on the cause. The following clinical features of ONH edema may be observed:

- elevation of the ONH with variable filling in of the physiologic cup; retinal vessels may appear to drape over the elevated ONH margin
- blurring of the ONH margins
- pRNFL opacification; the pRNFL becomes grayish white and opalescent with feathered margins, obscuring the ONH edge and portions of the retinal vessels that course within this level of the retina
- hyperemia of the ONH and dilation of the ONH surface capillary net
- retinal venous dilation and tortuosity
- peripapillary flame hemorrhages, exudates, or cotton-wool spots
- retinal or choroidal folds or macular edema

### **CLINICAL PEARL**

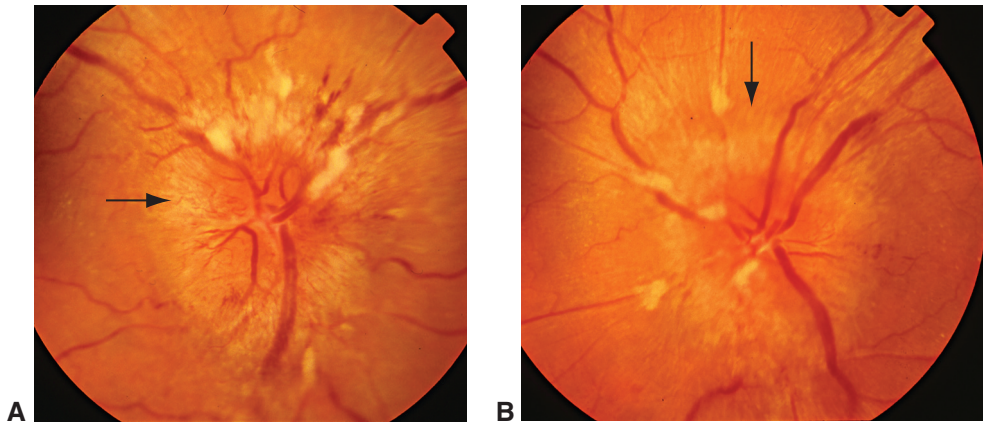
It is often difficult to determine the underlying cause of ONH edema on the basis of appearance alone. However, chalky white ONH edema is strongly suggestive of arteritic anterior ischemic optic neuropathy due to GCA, and peripapillary capillary telangiectasias associated with apparent ONH edema can be seen in Leber hereditary optic neuropathy.



**Figure 3-5** **A**, In this color fundus photograph, the ONH shows temporal pallor with loss of the nerve fiber layer in the papillomacular bundle. Superiorly and inferiorly along the arcades, raketlike defects (*arrows*) are seen in the peripapillary retinal nerve fiber layer (pRNFL). Use of the red-free filter on slit-lamp examination can aid in identification of these defects. **B**, Red-free photograph shows raketlike defects (*arrows*) along the arcades. (Courtesy of Zoë R. Williams, MD.)

### Visual Field Evaluation

Evaluation of the visual field helps localize a lesion along the afferent visual pathway, defines patterns of vision loss, and quantifies the defect, enabling measurement of change over time. The choice of technique depends on the degree of detail required and the patient's ability to cooperate. Patterns of visual field loss are discussed in detail in Chapter 4.



**Figure 3-6** Papilledema. **A**, Right eye. **B**, Left eye. The ONH margins are blurred, with grayish-white, opalescent thickening of the pRNFL (arrows); cotton-wool spots; and flame hemorrhages. The retinal vessels are partially obscured at the ONH margin and within the peripapillary retina. (Courtesy of Sophia M. Chung, MD.)

### Confrontation testing

Confrontation testing, which is easily performed at a patient's bedside or in the clinic, should take place during every ophthalmic examination. It is only a screening test and does not replace formal perimetry. Accepted methods of confrontation testing include

- *Description of the examiner's face.* The examiner sits 1 m from the patient. The patient covers 1 eye and fixates on the examiner's nose. The examiner asks the patient whether he or she is unable to see specific parts of the examiner's face. Affirmative responses may aid in identifying central or altitudinal (superior or inferior hemi-field) visual field defects.
- *Finger counting in the 4 quadrants.* The patient is asked to count 1 or 2 static fingers as they are presented sequentially in each of the 4 quadrants. The fingers are presented approximately 20° eccentric to fixation and equidistant from the quadrant borders. This technique tests for both altitudinal defects of the anterior visual pathways and homonymous visual field defects due to retrochiasmal lesions.
- *Kinetic red target test.* A 5-mm red-capped bottle is moved inward from beyond the boundary of each quadrant along a line bisecting the horizontal and vertical meridians. The patient is asked to report when the cap is first perceived to be red.
- *Finger or red comparison test.* With the finger comparison test, the examiner's index fingers are presented simultaneously on either side of the vertical meridian, first in the superior and then in the inferior quadrants. The patient is asked to report whether the fingers are equally in focus. During finger testing, children and nonverbal adults may be asked to mimic the examiner's finger movements. If the patient cannot identify fingers to mimic finger movements, the examiner presents progressively stronger stimuli, such as hand movement or a light, in each quadrant. In the red comparison test, 2 identical red targets are presented in the same manner as in the finger comparison test. The patient is asked whether the



targets are equally red. Color may appear altered, washed out, or absent in a damaged hemifield. Slow movement of the target across the vertical meridian may reveal an abnormality in color vision, which suggests damage to the chiasmal or retrochiasmal pathway.

### CLINICAL PEARL

Although confrontation visual field testing is limited as a screening test, it is useful for assessing hospital patients at bedside or individuals with poor reliability or impaired cognitive status.

Although these confrontation tests offer high specificity, their use is likely to result in many false-negatives because of their low sensitivity. The accuracy of confrontation testing depends on the density of the visual field defect. The single test with the best combination of sensitivity (74%) and specificity (93%) for detecting a visual field defect is kinetic testing with a red target.

*Extinction* refers to the inability to see a target in an affected hemifield *only* during simultaneous stimulation of both hemifields. A target presented only in the affected hemifield can be seen. This finding of visual neglect is characteristic of patients with parietal lobe lesions.

Kerr NM, Chew SS, Eady EK, Gamble GD, Danesh-Meyer HV. Diagnostic accuracy of confrontation visual field tests. *Neurology*. 2010;74(15):1184–1190.

### Amsler grid testing

Amsler grid testing screens the central 10° of the visual field (10° from fixation). In this test, the patient

- holds the Amsler grid at one-third of a meter (with optical correction for near vision if needed)
- covers 1 eye and looks at a fixation point in the center of the grid without scanning the grid
- describes any areas of distortion (ie, metamorphopsia) or missing vision (ie, scotoma)

Metamorphopsia suggests macular rather than optic nerve disease. Peripheral “bending” of the grid may represent an optical aberration from glasses and should be disregarded. Although Amsler grid testing is rapid and simple, its sensitivity is low.

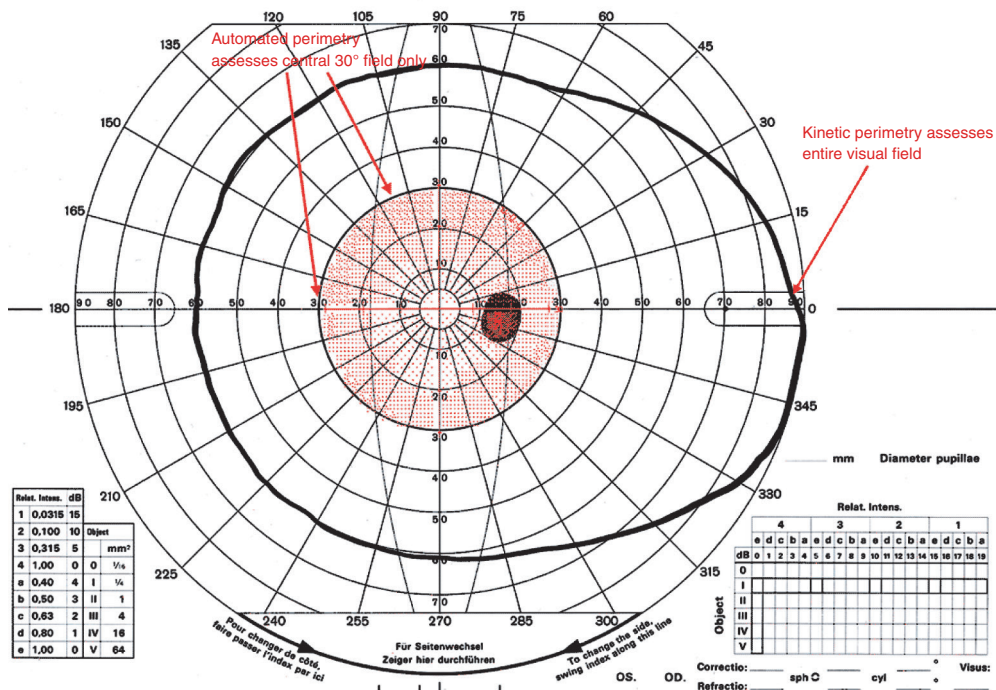
### Perimetry

Perimetry provides more detailed evaluation of the visual field than does confrontation testing. In both static and kinetic techniques, the visual field is analyzed for areas of decreased sensitivity, in location and in degree. In *static* testing, stimuli turn on and off at designated points within the region of the visual field being tested. In *kinetic* testing, a stimulus moves from a nonseeing to a seeing area of the visual field to determine the

location at which it is consistently detected by the patient. All points of equal sensitivity for a specific stimulus are connected to form an isopter, which represents the outer limit of visibility for that stimulus. Analysis of several isopters (plotted with different stimuli) produces a “contour map” of the island of vision.

**Kinetic (manual) perimetry** Kinetic perimetry (eg, Goldmann perimetry, the kinetic program on an Octopus perimeter [Haag-Streit]) can be used to evaluate the entire visual field (Fig 3-7). Stimuli of varying sizes and intensities are moved along each radial meridian from a peripheral to a central location. The stimulus sizes are numbered with Roman numerals I through V, each increasing by 4-fold in area, ranging from 0.25 mm<sup>2</sup> for a Size I stimulus to 64 mm<sup>2</sup> for a Size V stimulus. Typically, 2 or 3 isopters are plotted. Varying the stimulus size, intensity, and location can delineate the depths and borders of defects. Kinetic perimetry requires a skilled and knowledgeable perimetrist who can interact with patients to elicit optimal cooperation.

**Automated static perimetry** Automated static perimetry is considered the gold standard for evaluating visual field defects. Although this method is particularly difficult to use



**Figure 3-7** Kinetic versus automated perimetry. Diagrammatic representation of the extent of the visual field evaluated by kinetic perimetry versus the 30° central program in automated static perimetry. The largest isopter in kinetic perimetry testing extends 90° temporally and 60° in other quadrants; typical automated static perimetry evaluates only the central 30°. (Courtesy of Anthony C. Arnold, MD.)

with older or inattentive patients, it possesses numerous advantages over manual kinetic perimetry techniques:

- standardized testing conditions, which improve serial and inter-institutional comparisons of results
- less dependence on technicians
- better sensitivity
- numerical data amenable to statistical analysis for comparisons and clinical studies
- results amenable to electronic data storage

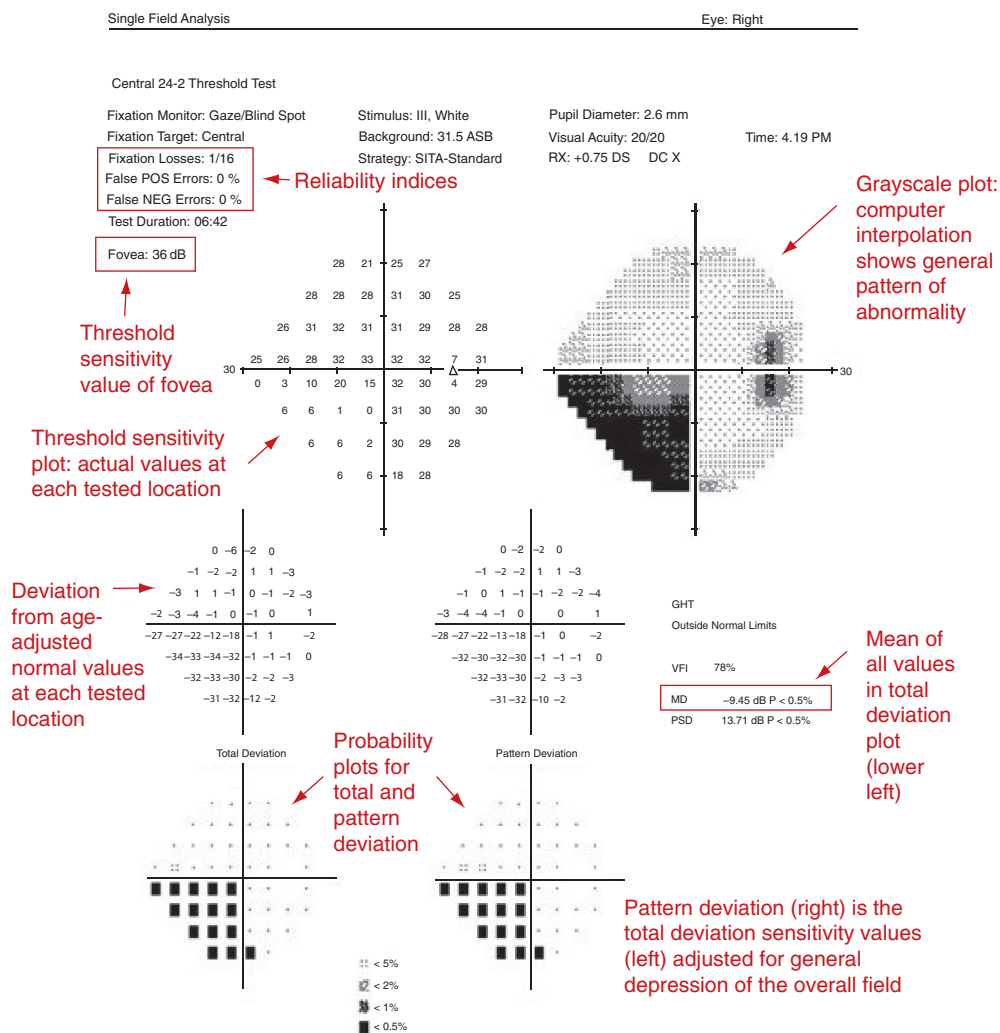
Most automated perimeters use static stimuli that are similar in size to the kinetic perimeter Size III stimulus, but the stimulus size can be increased to Size V for patients with poor visual acuity or severe visual field loss. The perimeter randomly presents stimuli at predetermined locations within a specified region of the visual field. The stimuli vary in brightness, and patient responses determine the minimum visible stimulus at each location—the sensitivity threshold.

Correct interpretation of automated perimetry results requires an understanding of the testing metrics as follows:

- *Sensitivity threshold* is defined as the intensity of the dimmest target identified 50% of the time at a given location.
- Threshold value is displayed in decibels (on a logarithmic scale of intensity, measuring attenuation from the maximum stimulus of the perimeter).
- A higher-value sensitivity indicates a dimmer stimulus that can be seen, reflecting greater visual sensitivity.
- Measured values are not absolute numbers and are not equivalent among perimeters because the machines have different maximum intensities, backgrounds, and durations of presentation.

A symbolic representation of the threshold values, the grayscale plot, depicts an overall topographic impression of the visual field data by using darker symbols for low-sensitivity points and lighter symbols for high-sensitivity points. The computer program interpolates between tested points to provide a user-friendly picture (Fig 3-8).

For clinical interpretation, the perimeter calculates for each value the statistical probability that the value falls outside the normal range among age-matched control subjects; the results are placed in a total-deviation plot. Optic neuropathy may cause substantial total-deviation depression with few or no pattern-deviation abnormalities. Because ocular media abnormalities (eg, refractive error, cataract) may depress the sensitivity of the entire visual field, a pattern-deviation plot is determined by reanalyzing the sensitivity values for all points measuring below the seventh-highest point. This reanalysis compensates for the overall sensitivity depression, allowing recognition of abnormal patterns (eg, scotomata, arcuate defects, homonymous defects) that might have been otherwise masked. Abnormal values are depicted topographically according to statistical probability: darker squares represent higher probability, and lighter squares represent lower probability. Global indices are calculated to help determine changes in sensitivity over time. Such indices include a center-weighted mean of the sensitivity depression across all points (ie, mean deviation)



**Figure 3-8** Humphrey 24-2 automated static perimetry report, with reliability indices, gray-scale map, probability plots, and statistical analysis. (Courtesy of Zoë R. Williams, MD.)

and different methods of addressing localized defects (eg, pattern standard deviation, corrected pattern deviation, loss variance).

The reliability of perimetry test results is assessed by identifying the following patient-response characteristics:

- *false-positive response rate*: how frequently the patient signals when no target is displayed (an acceptable rate is typically <25% on threshold testing and <15% on Swedish Interactive Threshold Algorithm [SITA] testing)
- *false-negative response rate*: how often the patient fails to signal when a target brighter than the previously determined threshold for that location is displayed (an

acceptable rate is typically <25%, but the rate increases in regions of true visual field loss because the patient is unable to reproduce responses accurately)

- *fixation losses*: how often the patient identifies the stimulus in the previously plotted physiologic blind spot, indicating that the eye is not aligned with the fixation target

The long duration and repetitiveness of the original full-threshold perimetry test can fatigue patients, reducing the accuracy of test results. Use of SITA, the standard method for threshold measurement used by the Humphrey Field Analyzer (HFA; Carl Zeiss Meditec), shortens the time needed to complete the full-threshold test by half but maintains the accuracy necessary for validity. The Octopus perimeter offers a tendency-oriented perimeter (TOP) algorithm to reduce testing time. See BCSC Section 10, *Glaucoma*, for more detailed discussion of testing strategies.

Because nearly 80% of the visual cortex correlates to the central visual field, testing the central 24° or 30° of the visual field is typically adequate for detecting most visual field defects. The HFA 24-2 and 30-2 programs test the central 24° or 30° of the visual field, and the Octopus perimeter implements these in the G2 and G1 patterns. Because of the 6° test point spacing of the HFA 30-2 and 24-2 programs and Octopus G2 and G1 programs, HFA 10-2 or Octopus C08 (which both have 2° test point spacing covering the central 10°) may better delineate a small central or paracentral scotoma. It is also critical to measure the foveal threshold (normal range 34–40 dB) because it estimates central visual function.

### CLINICAL PEARL

Size V full-threshold testing has been shown to have lower test–retest variability and an increased dynamic range compared with Size III SITA testing and can be very useful in monitoring patients with low vision.

Barton JJS, Benatar M. *Field of Vision: A Manual and Atlas of Perimetry*. Humana Press; 2003.

Bettis DI, Johnson CA. Update on automated perimetry. *Focal Points: Clinical Practice Perspectives*. American Academy of Ophthalmology; 2016, module 12.

## Examination: Adjunct Testing

### Contrast Sensitivity Testing

Loss of contrast sensitivity can cause visual symptoms that are out of proportion to measured visual acuity. Contrast sensitivity testing can detect and quantify vision loss in the presence of normal visual acuity. Such testing, however, is not specific for optic nerve dysfunction; media irregularities and macular lesions may also yield abnormal results. Also, interpretation of contrast sensitivity test data is more complex than interpretation of visual acuity data, particularly with regard to differentiating subtle abnormalities from normal presentation.

Unlike visual acuity testing, which uses targets that vary in size but have a single high level of contrast, contrast sensitivity testing uses targets with different contrast levels. Two types of contrast sensitivity tests exist: grating and letter. *Grating tests* display rows of sine



wave grating patches, each row reflecting a different spatial frequency. Although they are arguably superior to letter tests, grating tests are difficult to administer and to reproduce reliably. The Pelli-Robson chart, commonly employed for clinical letter testing, uses a size 20/60 optotype with letters that vary in contrast. The contrast of these letters decreases in groups of 3 from top to bottom and left to right within each line (Fig 3-9A). The minimum level of contrast at which 2 or 3 letters of the 3-letter block can be detected is recorded. The Early Treatment Diabetic Retinopathy Study (ETDRS) chart is available in high- and low-contrast options (Fig 3-9B, C).



**Figure 3-9** **A**, Pelli-Robson contrast sensitivity chart. **B**, Early Treatment Diabetic Retinopathy Study (ETDRS) high-contrast chart. **C**, ETDRS low (2.5%)–contrast chart. (Courtesy of Zoë R. Williams, MD. Photography by Brittany Figscher, CRA.)

Contrast sensitivity testing is discussed further in BCSC Section 3, *Clinical Optics and Vision Rehabilitation*, and Section 12, *Retina and Vitreous*.

### Photostress Recovery Testing

The photostress recovery test measures the amount of time it takes the macula to return to near-normal function after it is exposed to a bright light. This test may help differentiate vision loss caused by a macular lesion or ocular ischemia from that caused by an optic neuropathy. Before the test begins, CDVA is measured in each eye separately by the Snellen chart (a visual acuity of 20/80 or better is required). Tested monocularly, the patient gazes directly into a strong light held 2–3 cm from the eye for 10 seconds. As soon as possible after the light is removed, the patient attempts to read the next larger Snellen visual acuity line (eg, a patient with a CDVA of 20/25 attempts to read the 20/30 line). Normal photostress recovery time is less than 30 seconds, but patients with maculopathy or severe carotid artery stenosis have prolonged recovery times, frequently 90–180 seconds or more. Patients with optic neuropathy maintain normal photostress recovery times.

Glaser JS, Savino PJ, Summers KD, McDonald SA, Knighton RW. The photostress recovery test in the clinical assessment of visual function. *Am J Ophthalmol*. 1977;83(2):255–260.

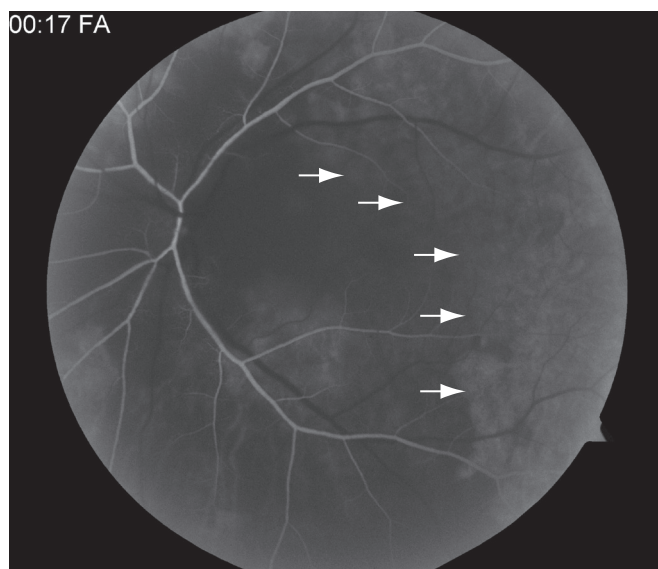
### Potential Acuity Meter Testing

Potential acuity meter (PAM) testing can help determine whether media irregularities or opacities are the cause of decreased vision. In this test, optotypes are projected onto the retina through a dilated pupil in order to bypass the media opacity, providing an estimate of best potential visual acuity. If visual acuity does not improve to 20/20 with PAM testing, the ophthalmologist should search for a cause other than media opacities (eg, optic neuropathy or maculopathy) to explain the decreased vision.

### Fluorescein and Indocyanine Green Angiography

Fluorescein angiography (FA) allows examination of the retinal and choroidal vasculature after intravenous administration of fluorescein. The peak excitation of fluorescein is 465–490 nm, and its peak emission is 520–530 nm in physiologic environments. Fluorescein is approximately 80% protein-bound in circulation; the blood–retina barrier normally prevents it from diffusing into retinal tissue. However, leakage can occur in areas with new vessel growth or regions with blood–ocular barrier defects induced by inflammation or ischemia. For detailed discussion of FA, including types of fluorescence, see BCSC Section 12, *Retina and Vitreous*.

FA has a role in the investigation of some neuro-ophthalmic conditions. Angiography can demonstrate delayed or absent choroidal filling, which is highly suggestive of GCA (Fig 3-10). Angiographic leakage can differentiate true edema from pseudoedema of the ONH (Fig 3-11); the latter, which is characteristic of Leber hereditary optic neuropathy, does not leak. FA can identify the branch retinal artery occlusions seen in Susac syndrome. In the setting of infectious or inflammatory disease with associated ONH edema,



**Figure 3-10** Fluorescein angiography image of the retina shows delayed choroidal filling in a patient presenting with no light perception vision due to giant cell arteritis. The fluorescein dye appears bright in this positive image. The retinal arteries are filled with fluorescein, and there is a large perfusion defect (dark area) in the choroid. Arrows mark the interface between normal choroidal filling (bright) and delayed filling (dark). (Courtesy of Zoë R. Williams, MD.)

FA is the most sensitive imaging modality to assess for vascular inflammation. In patients with uveitis, wide-field FA is especially useful for assessment of peripheral vessel leakage and nonperfusion.

Like FA, indocyanine green (ICG) angiography requires intravenous dye administration. ICG is a water-soluble dye that is nearly completely protein-bound, limiting diffusion through the choriocapillaris, thereby enabling assessment of choroidal blood flow. ICG fluoresces in the near-infrared range and is detected with infrared video angiography. This property enables better penetration of ICG than fluorescein through pigment, lipid, or hemorrhage, allowing visualization of deep choroidal lesions. For detailed discussion of ICG angiography and its uses, see BCSC Section 12, *Retina and Vitreous*.

Table 3-2 summarizes the indications for in-office diagnostic testing, including the advantages and disadvantages of each testing modality.

Lee AG, Brazis PW. Giant cell arteritis. *Focal Points: Clinical Modules for Ophthalmologists*. American Academy of Ophthalmology; 2005, module 6.

### Fundus Autofluorescence

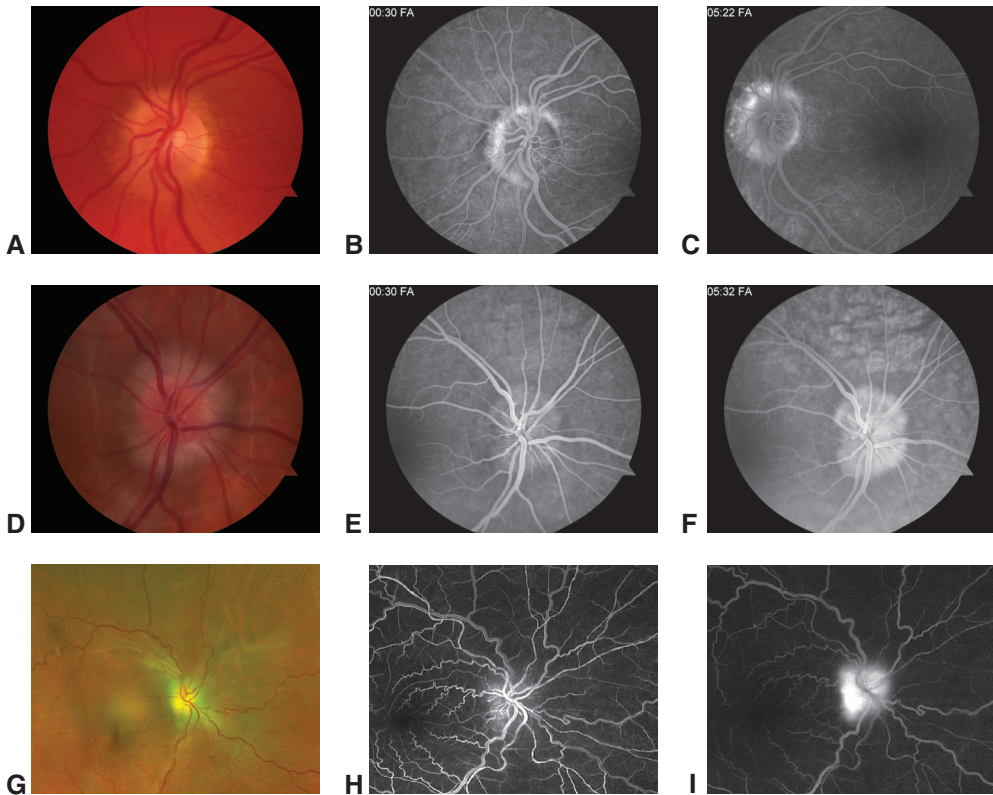
Fundus autofluorescence (FAF) is a rapid, noncontact, noninvasive way to visualize fluorophores in the fundus. It uses the same excitation and emission filters as FA but does not require injection of a contrast agent. The main application of FAF in neuro-ophthalmic

**Table 3-2 Ancillary In-Office Diagnostic Tests: Utility, Advantages, and Disadvantages**

Diagnostic Test	Utility	Advantages	Disadvantages
FA	Retinal circulation ONH leakage or hyperfluorescence	Detects: Delayed or absent choroidal filling Arterial occlusion Capillary nonperfusion Capillary leakage CNV	Invasive: requires injection of fluorescein Possible allergic reaction, including anaphylaxis
ICGA	Choroidal circulation CNV obscured by hemorrhage, lipid, or pigment Deep choroidal lesions Intraocular tumors	Fluoresces through pigment, hemorrhage, or lipid	Invasive: requires injection of ICG Possible allergic reaction Specialized infrared video angiography needed
FAF	Superficial optic disc drusen Lipofuscin accumulation in RPE cells Medication toxicity (hydroxychloroquine) Macular degeneration	Noninvasive, quick	Provides no information about retinal blood flow
OCT	pRNFL Axonal integrity ONH edema Optic disc drusen Macula Edema Subretinal fluid CNV Hyperreflectance in arterial occlusion Thinning of retinal layers	Noninvasive, quick	Requires fixation Nonspecific: cannot differentiate etiology of ONH edema Macular OCT results may appear normal in subacute period after retinal artery occlusion
Ultrasonography	Buried optic disc drusen Papilledema (30° test) Retinal detachment Retinal tear Choroidal detachment Globe rupture with media opacity Choroidal lesion/tumor Posterior scleritis	Noninvasive	Requires technical skill Provides no functional information

CNV=choroidal neovascularization; FA=fluorescein angiography; FAF=fundus autofluorescence; ICGA=indocyanine green angiography; OCT=optical coherence tomography; ONH=optic nerve head; pRNFL=peripapillary retinal nerve fiber layer; RPE=retinal pigment epithelium.

disorders is detection of superficial optic disc drusen (ODD), which demonstrate autofluorescence (Fig 3-12). However, vision loss from subtle maculopathy is sometimes mistaken for an optic neuropathy; in these cases, FAF can be a valuable diagnostic tool for neuro-ophthalmologists. Lipofuscin, which accumulates in higher amounts in damaged retinal pigment epithelium (RPE) cells, causes hyperfluorescence on FAF. This is seen



**Figure 3-11** **A–C:** ONH pseudoedema with no ONH leakage on fluorescein angiography (FA). Fundus photograph (**A**); early (**B**) and late (**C**) FA images. **D–F:** ONH edema with ONH leakage on FA. Fundus photograph (**D**); early (**E**) and late (**F**) FA images. **G–I:** ONH edema with ONH leakage on FA. Wide-field fundus photograph (**G**); early (**H**) and late (**I**) FA images. (Courtesy of Zoë R. Williams, MD.)

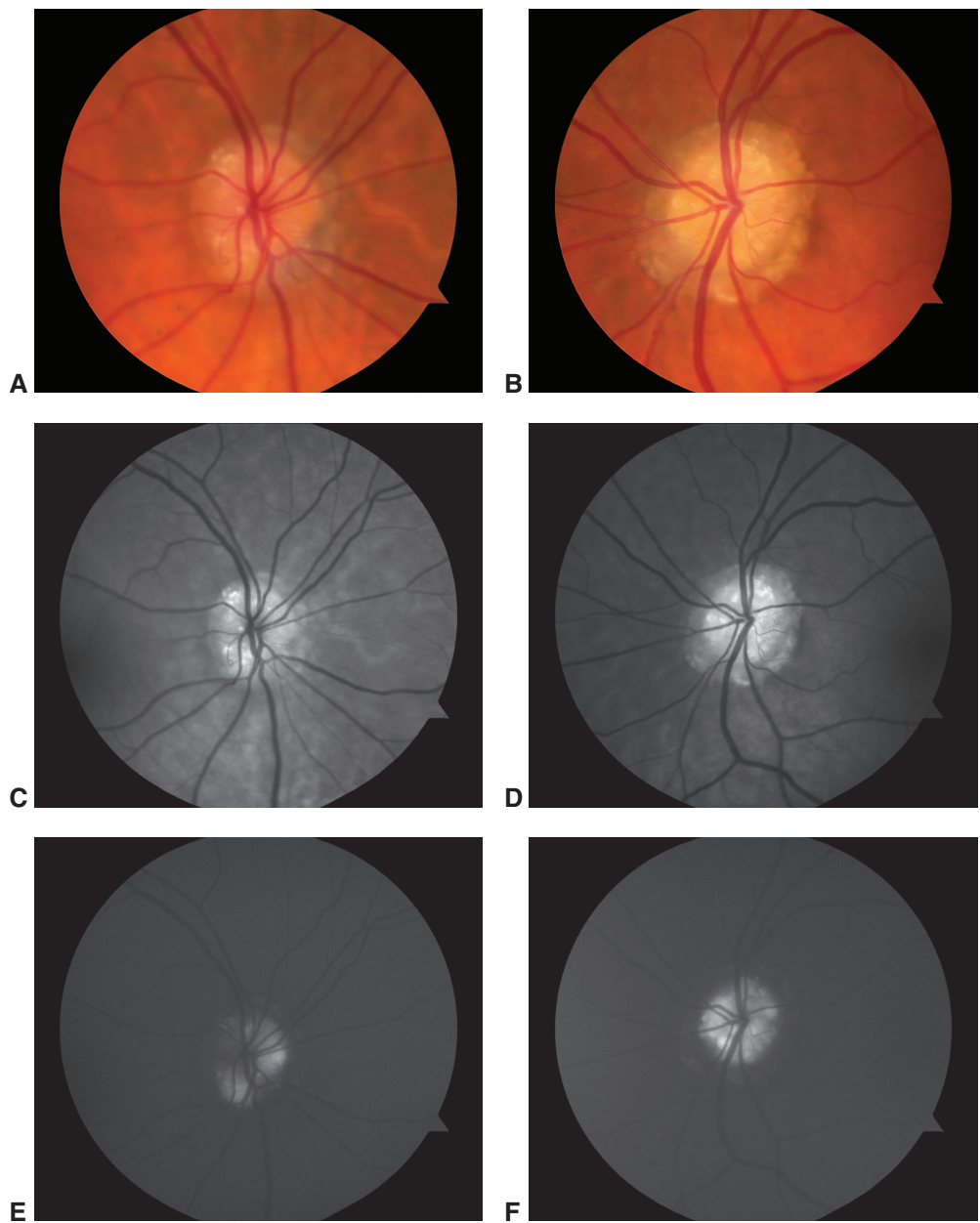
in some retinal pathologies with subtle ophthalmoscopic findings, such as multiple evanescent white dot syndrome (MEWDS), acute macular neuroretinopathy (AMN), acute zonal occult outer retinopathy (AZOOR) (Fig 3-13), and acute idiopathic blind-spot enlargement (AIBSE) syndrome. For more information on FAF, see Table 3-2 in this volume and BCSC Section 12, *Retina and Vitreous*.

### Optical Coherence Tomography

Optical coherence tomography (OCT) provides noninvasive, high-resolution in situ visualization of the various retinal layers and ONH. It is useful for structural measurement of pRNFL thickness, volumetric analysis of the ONH, and evaluation of macular anatomy (see Chapter 2 for a systematic approach to evaluating OCT data). OCT can be invaluable in monitoring patients for progression of age-related macular degeneration, macular edema, macular holes, central serous chorioretinopathy, intraocular tumors, and glaucoma or nonglaucomatous optic neuropathy.

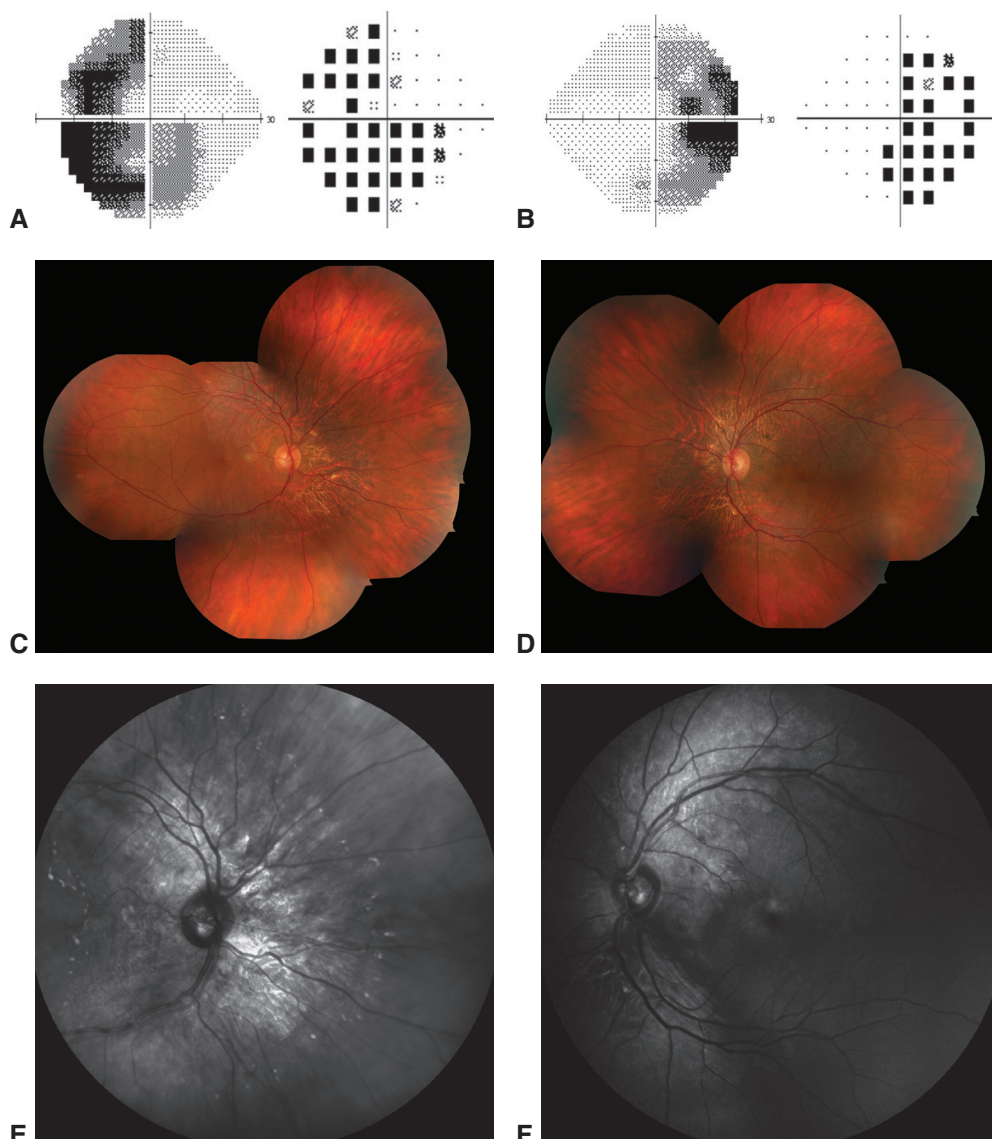
Advancements in OCT technology have helped make it perhaps the most widely used ocular imaging modality. The original time-domain OCT (TD-OCT) has been





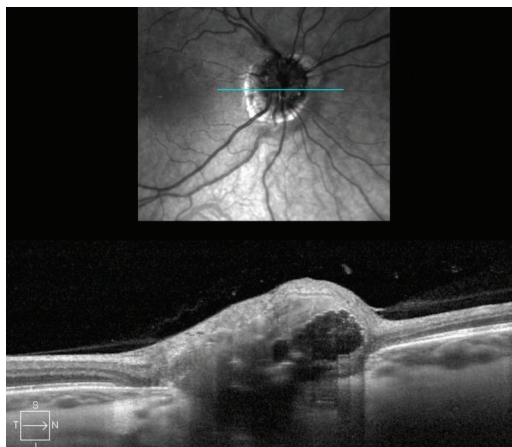
**Figure 3-12** **A and B**, Color photographs showing optic disc drusen (ODD). **C and D**, Red-free photographs showing autofluorescence of ODD. **E and F**, Fundus autofluorescence photographs showing hyperfluorescence of ODD. (Courtesy of Zoë R. Williams, MD.)

largely replaced by Fourier- or spectral-domain OCT (SD-OCT) with its superior resolution (now 5–7  $\mu\text{m}$ ), improved image acquisition speed, and resultant enhanced image quality and reproducibility. Additional advances in OCT technology include swept-source OCT (SS-OCT), enhanced depth imaging OCT (EDI-OCT), and OCT angiography (OCTA).



**Figure 3-13** Acute zonal occult outer retinopathy (AZOOR). **A and B**, Humphrey 24-2 Swedish Interactive Threshold Algorithm (SITA) Standard visual field shows bitemporal hemianopia not respecting the vertical meridian. **C and D**, Fundus photographs reveal retinal atrophy and pigmentary changes of the retinal pigment epithelium (RPE). **E and F**, Fundus autofluorescence shows hyperfluorescence corresponding with the visual field defects. (Courtesy of Zoë R. Williams, MD.)

SS-OCT is a type of Fourier-domain OCT technology that uses a tunable laser to perform a rapid sweeping scan over a broad bandwidth. The back reflectance of light is recorded by a photodetector, enabling a rapid scanning speed with less image distortion. SS-OCT increases depth of imaging by using a longer wavelength than SD-OCT, similar to SD-OCT with enhanced depth imaging, thereby enabling deeper tissue penetration with imaging of the choroid and pathologies such as buried ODD (Fig 3-14).



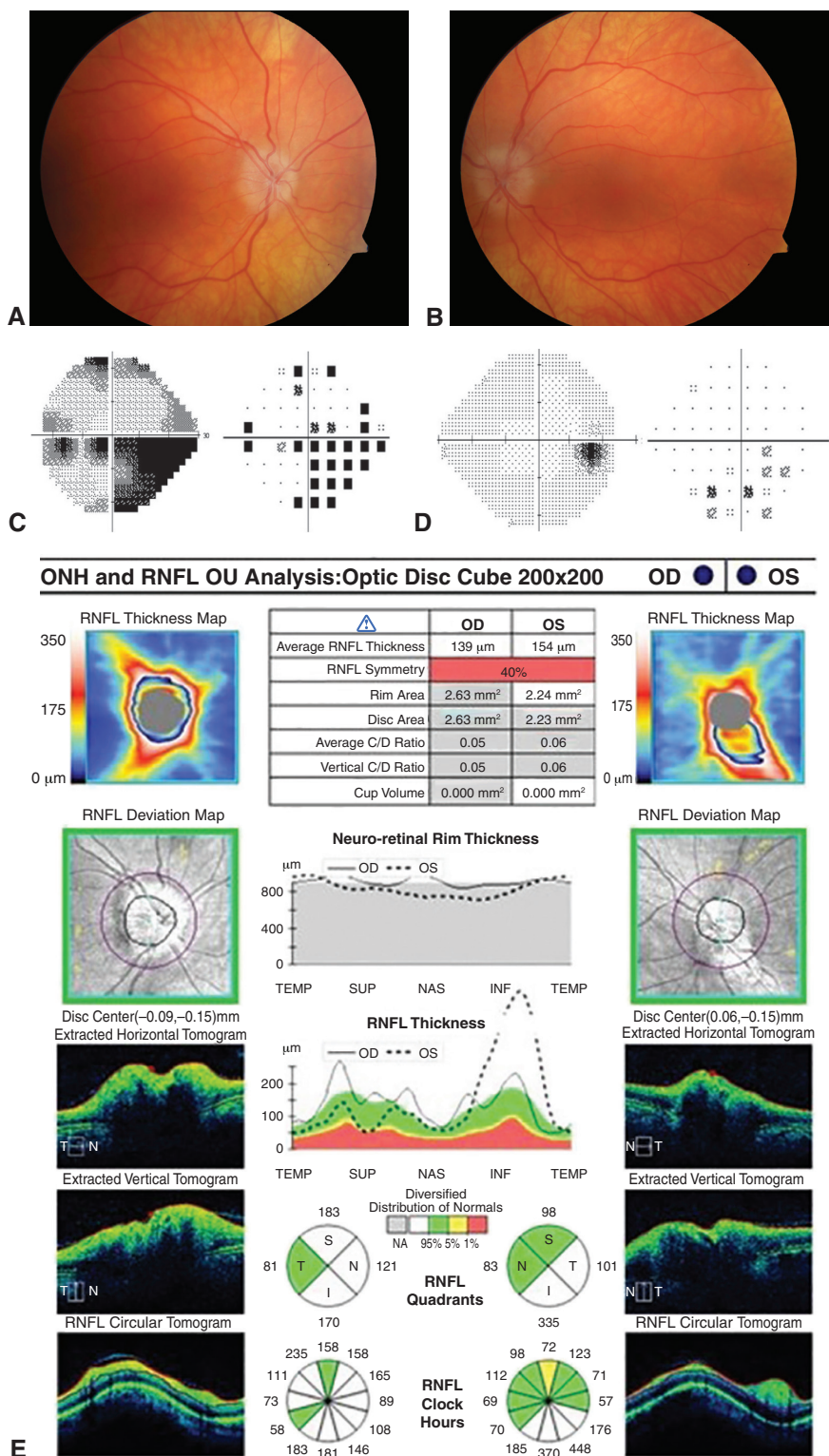
**Figure 3-14** This enhanced depth imaging optical coherence tomography (EDI-OCT) scan shows a buried ODD as a well-delineated signal-poor region with surrounding hyperreflective margins. (Courtesy of Heather E. Moss, MD, PhD.)

OCTA uses the techniques of speckle variance, phase variance, and amplitude decorrelation of blood flow to generate multiple en face images of depth-resolved retinal and choroidal vessels without administration of contrast material. Its noninvasive nature, rapid acquisition time, and ability to provide capillary-level imaging make OCTA a useful imaging modality in the assessment of proliferative diabetic retinopathy, neovascularization in age-related macular degeneration, and capillary nonperfusion associated with retinal vein occlusion. OCTA may be helpful in posterior uveitis for detection of vasculitis, capillary nonperfusion, and neovascularization. Applications of OCTA in optic nerve disease are still being studied. The disadvantages of OCTA include susceptibility to motion artifact (from patient eye or head movement) and shadowing (from media opacities), inability to detect capillary leakage, limited peripheral retina assessment, and limited ability to assess disease severity.

See BCSC Section 10, *Glaucoma*, and Section 12, *Retina and Vitreous*, for detailed discussion of the various incarnations of OCT, as well as the role of OCT in some of the conditions discussed in the following sections.

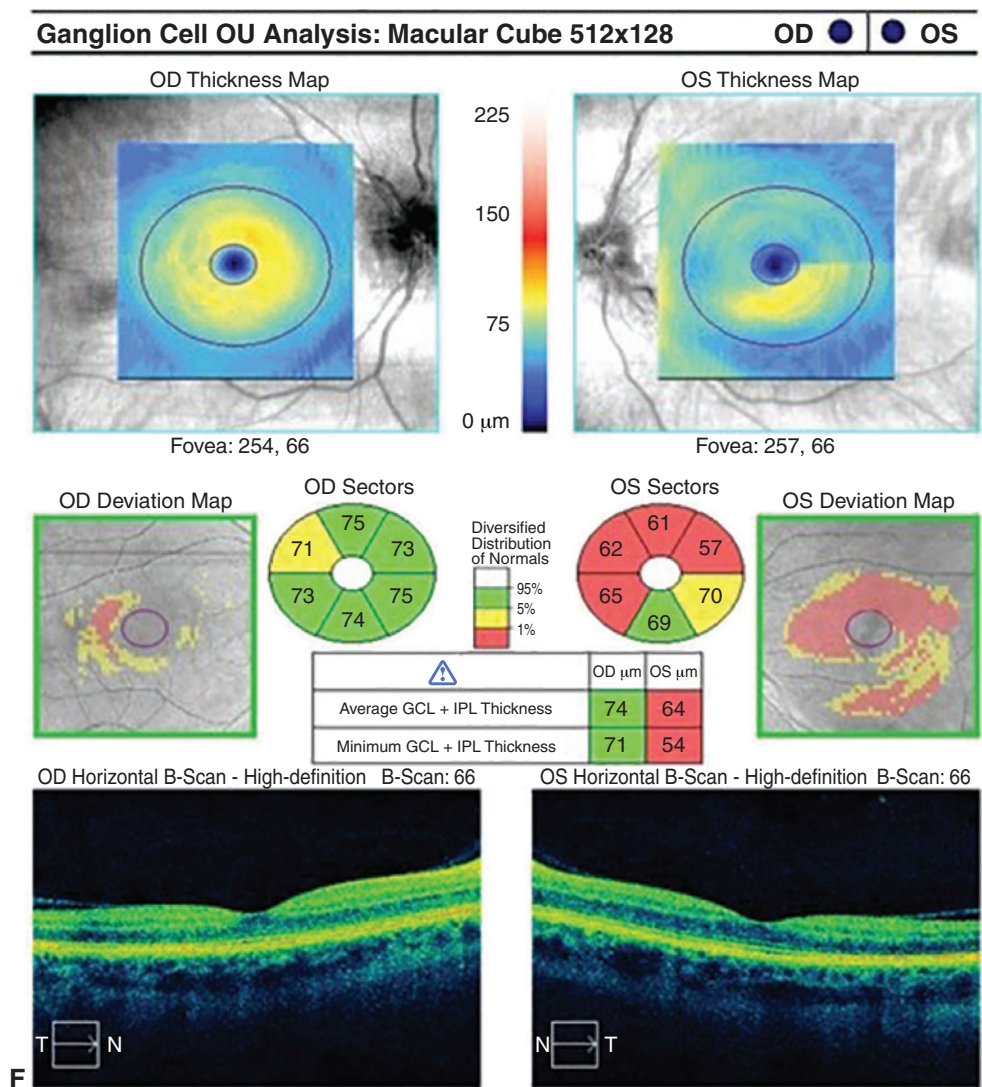
### ***OCT in specific conditions***

OCT can be very helpful in the evaluation and management of certain neuro-ophthalmic conditions. The pRNFL thickness measurement provides indirect information about the axonal integrity of the optic nerve. Automatic segmentation of the macula allows measurement of the inner retina. Thinning of the ganglion cell–inner plexiform layer (GC-IPL) has been associated with vision loss from glaucoma, optic neuritis, ischemic optic neuropathy, hereditary optic neuropathy, toxic optic neuropathy, optic nerve glioma, and chronic papilledema. Because the GC-IPL thickness does not increase with ONH edema, GC-IPL thinning can provide an early indication of neuronal loss in the setting of optic neuropathy with ONH edema (Fig 3-15).



(Continued)





**Figure 3-15 (continued) F,** The ganglion cell–inner plexiform layer (GC–IPL) shows superior thinning in the left eye corresponding to the inferior visual field defect in the left eye. (Courtesy of Zoë R. Williams, MD.)

**CLINICAL PEARL**

It is important to know that the test–retest variability of OCT pRNFL is 8  $\mu\text{m}$  in order to determine whether there is a clinically meaningful change.

**Multiple sclerosis** OCT RNFL has been studied extensively in patients with multiple sclerosis (MS) and has been shown to correlate with low-contrast visual acuity and visual field defects. However, in patients with MS, GC–IPL thickness better correlates with visual



acuity and quality of life than does pRNFL thickness. pRNFL thickness inversely correlates with neurologic disability and brain atrophy in MS. In addition, macular volume, which reflects the integrity of retinal ganglion cell neurons, is reduced in patients with MS.

The degree of pRNFL thinning correlates with subtypes of optic neuritis. Neuro-myelitis optica (NMO)-optic neuritis is associated with a higher degree of pRNFL thinning (typically  $>30\ \mu\text{m}$ ) than MS-optic neuritis (typically  $10\text{--}15\ \mu\text{m}$ ). The pRNFL loss also tends to be more diffuse in NMO (especially affects the superior and inferior quadrants) than in MS (typically affects the temporal quadrant).

**Papilledema** OCT can be useful for monitoring for resolution of papilledema with treatment, especially in patients with underlying congenital anomalous ONHs. Use of 5-line raster or radial OCT can be helpful in assessing for anterior displacement of Bruch membrane (upward deflection toward the vitreous), which occurs with papilledema. With normalization of intracranial pressure, this displacement resolves. Whether a decrease in pRNFL thickness reflects improving papilledema or axonal loss can be determined by assessing GC-IPL thickness, which is preserved with improving papilledema without axonal damage. With severe papilledema, OCT is less helpful as segmentation algorithms fail because of the obscuration of landmarks typically used for measurements.

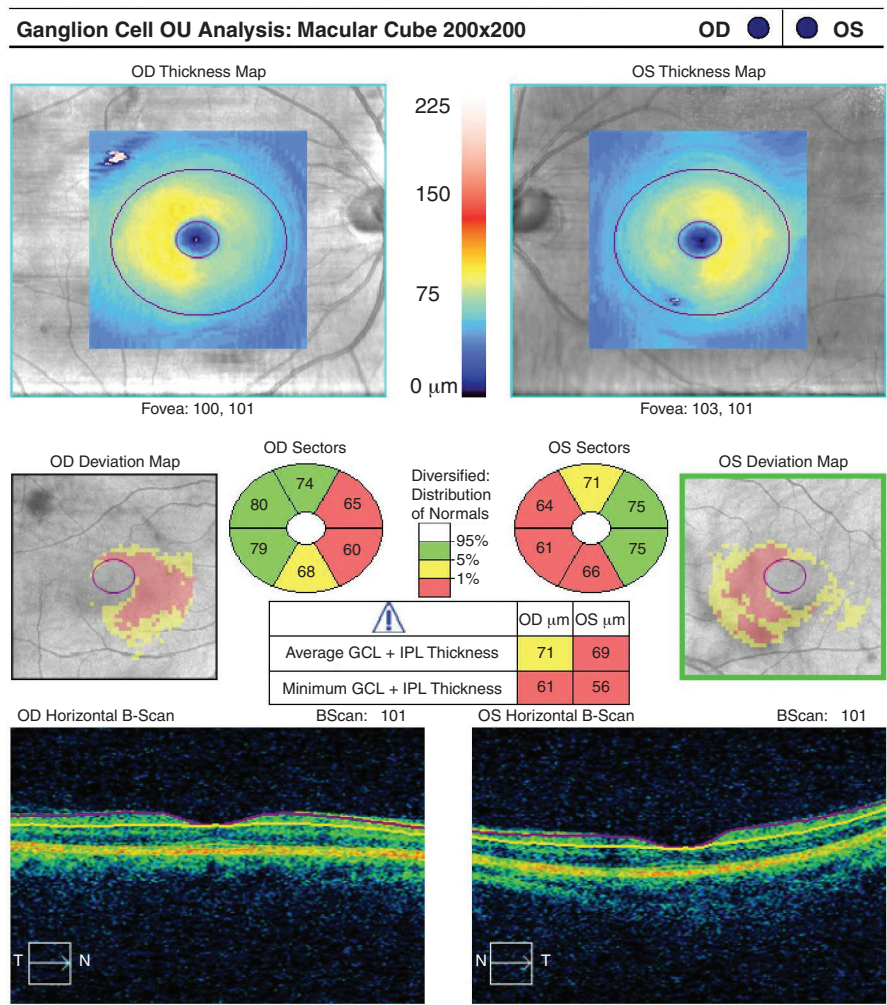
A clinical challenge often encountered in neuro-ophthalmology is differentiating papilledema from anomalous ONHs and ODD. Several OCT features may suggest the diagnosis; however, OCT currently cannot definitively distinguish mild papilledema from an anomalous, crowded ONH. Refinement of OCT techniques (SS-OCT and EDI-OCT) has enabled visualization of ODD as spheroidal and hyporeflective with hyperreflective margins or foci on their surface (see Fig 3-14).

**Chiasmal lesions** Chiasmal lesions can cause thinning of the nasal and temporal pRNFL sectors due to compression of the crossing nasal fibers (see Chapter 1, Fig 1-22C). On OCT, the GC-IPL may show binasal thinning with chiasmal compression (Fig 3-16). As in glaucoma, pRNFL thickness can be monitored over time using OCT in order to quantify axonal loss in patients with chronic diseases such as compressive optic neuropathy (Fig 3-17). The degree and site of pRNFL thinning on OCT correlate with the threshold sensitivity of the corresponding area of the visual field (Figs 3-18, 3-19).

Further, in patients with compressive chiasmal tumors, OCT findings have been shown to be predictive of the potential for visual recovery after surgery. Patients who have significant visual field defects but preserved pRNFL thickness (the threshold is approximately  $75\ \mu\text{m}$  but depends on age) typically have an excellent prognosis for visual recovery, irrespective of the degree of preoperative vision loss (Fig 3-20).

**Toxic and nutritional optic neuropathies** In toxic (eg, isoniazid-, ethambutol-related) optic neuropathy and nutritional optic neuropathies (eg, vitamin B<sub>12</sub> or folate deficiency), OCT shows pRNFL thinning in the papillomacular bundle (temporal quadrant). This thinning may precede the development of visual field defects. Vitamin D deficiency has been shown to decrease GC-IPL thickness before thinning of the pRNFL occurs.

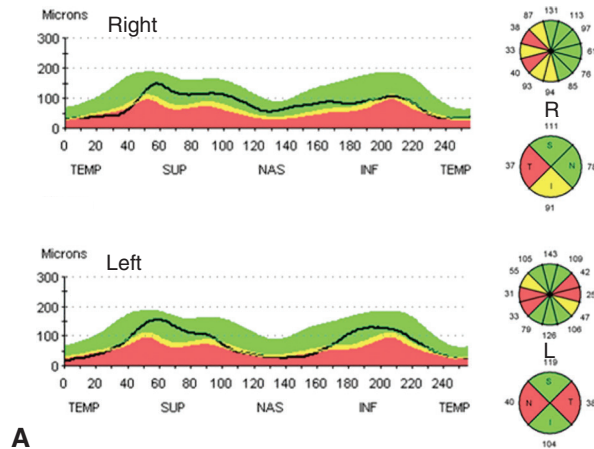
**Retinal conditions** Macular cube OCT and macular line scans can help identify occult retinal pathology in patients with unexplained vision loss. Not uncommonly, MS patients with



**Figure 3-16** OCT GC-IPL showing binasal thinning due to chiasmal compression from a pituitary adenoma. (Courtesy of John J. Chen, MD, PhD.)

vision loss are presumed to have optic neuritis until an OCT macular line scan shows subretinal fluid in the setting of central serous retinopathy. MEWDS, AZOOR, and AMN can also be detected via macular line scans showing disruption of the inner and outer segments of the retina, which is characteristic of these diseases (Fig 3-21). In autoimmune retinopathy (paraneoplastic or nonparaneoplastic), OCT studies have shown that the outer retinal layers (especially the ellipsoid zone, external limiting membrane, and outer nuclear layer) are preferentially affected. In addition to detecting and identifying retinal diseases, macular OCT can be used to monitor chloroquine and hydroxychloroquine retinal toxicity by detecting thinning of the foveal and parafoveal regions, which occurs in the early stages of toxicity.

Galetta KM, Calabresi PA, Frohman EM, Balcer LJ. Optical coherence tomography (OCT): imaging the visual pathway as a model for neurodegeneration. *Neurotherapeutics*. 2011;8(1):117–132.



**Figure 3-17** Pituitary adenoma with bitemporal visual field loss. OCT demonstrates nasal and temporal thinning of the pRNFL, left eye (**A**), which corresponds to the clinical appearance of horizontal band atrophy (**B**). (Courtesy of Helen V. Danesh-Meyer, MD, PhD.)

Malhotra K, Padungkiatsagul T, Moss HE. Optical coherence tomography use in idiopathic intracranial hypertension. *Ann Eye Sci.* 2020;5:7.

Mendoza-Santesteban CE, Gonzalez-Garcia A, Hedges TR III, et al. Optical coherence tomography for neuro-ophthalmologic diagnoses. *Semin Ophthalmol.* 2010;25(4):144–154.

## Ultrasonography

Ultrasonography is useful in diagnosing

- buried ODD, which are hyperechoic on B-scan (Video 3-2)
- posterior scleritis

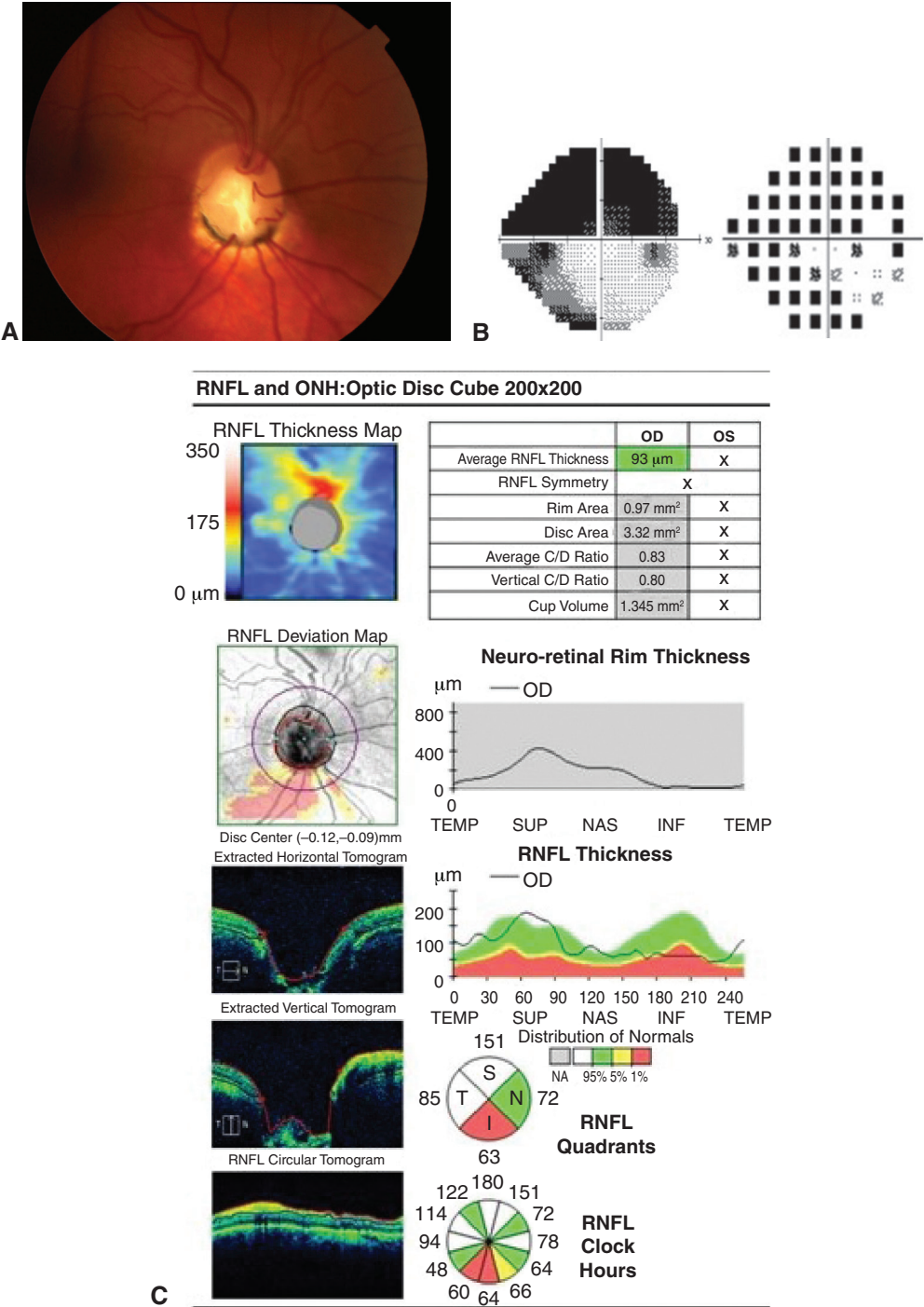


### VIDEO 3-2 Ultrasonography for detection of buried optic disc drusen.

Courtesy of Zoë R. Williams, MD. Ultrasonography performed by Terrance Schaefer, COMT. Narration by Zoë R. Williams, MD.



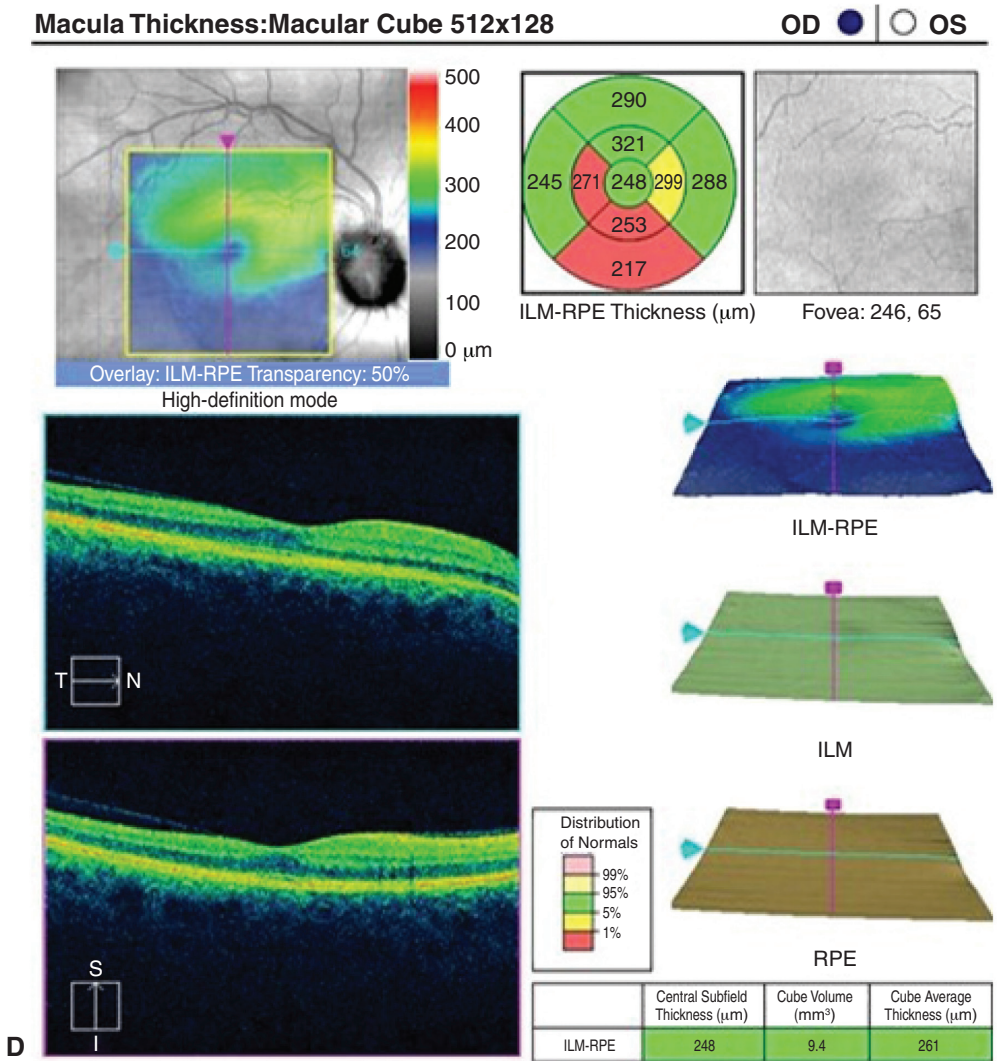
See Table 3-2 for additional information on the uses of ultrasonography in neuro-ophthalmology and its advantages and disadvantages.



**Figure 3-18** Optic nerve coloboma of the right eye. **A**, Color photograph shows inferior excavation of the ONH. **B**, Humphrey 24-2 SITA Standard visual field shows superior altitudinal and mild inferonasal defects. **C**, OCT RNFL shows inferior pRNFL loss.

(Continued)





**Figure 3-18 (continued) D,** Macular OCT shows inferior and temporal thinning, which correlates with the visual field defect. (Courtesy of Zoë R. Williams, MD.)

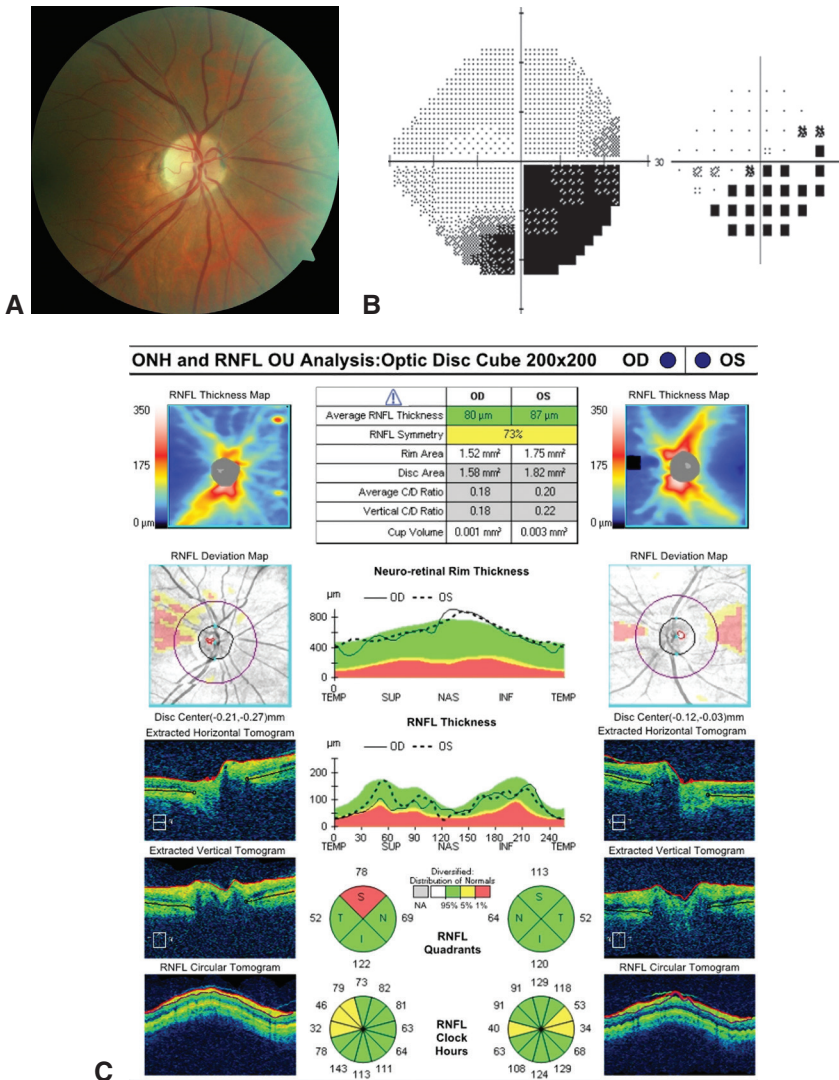
**Electrophysiologic Testing**

When a patient has central or peripheral vision loss but no obvious fundus abnormality, ancillary electrophysiologic testing may help confirm or rule out occult abnormalities of the optic nerve or retina. See also BCSC Section 12, *Retina and Vitreous*.

**Visual evoked potential testing**

Visual evoked potential (VEP) testing measures electrical signals produced in response to a visual stimulus. The signals are recorded at the scalp overlying the occipital cortex. The visual stimulus can be either light flashes or patterned stimuli (usually a black-and-white checkerboard that reverses its pattern on a TV monitor). Damage

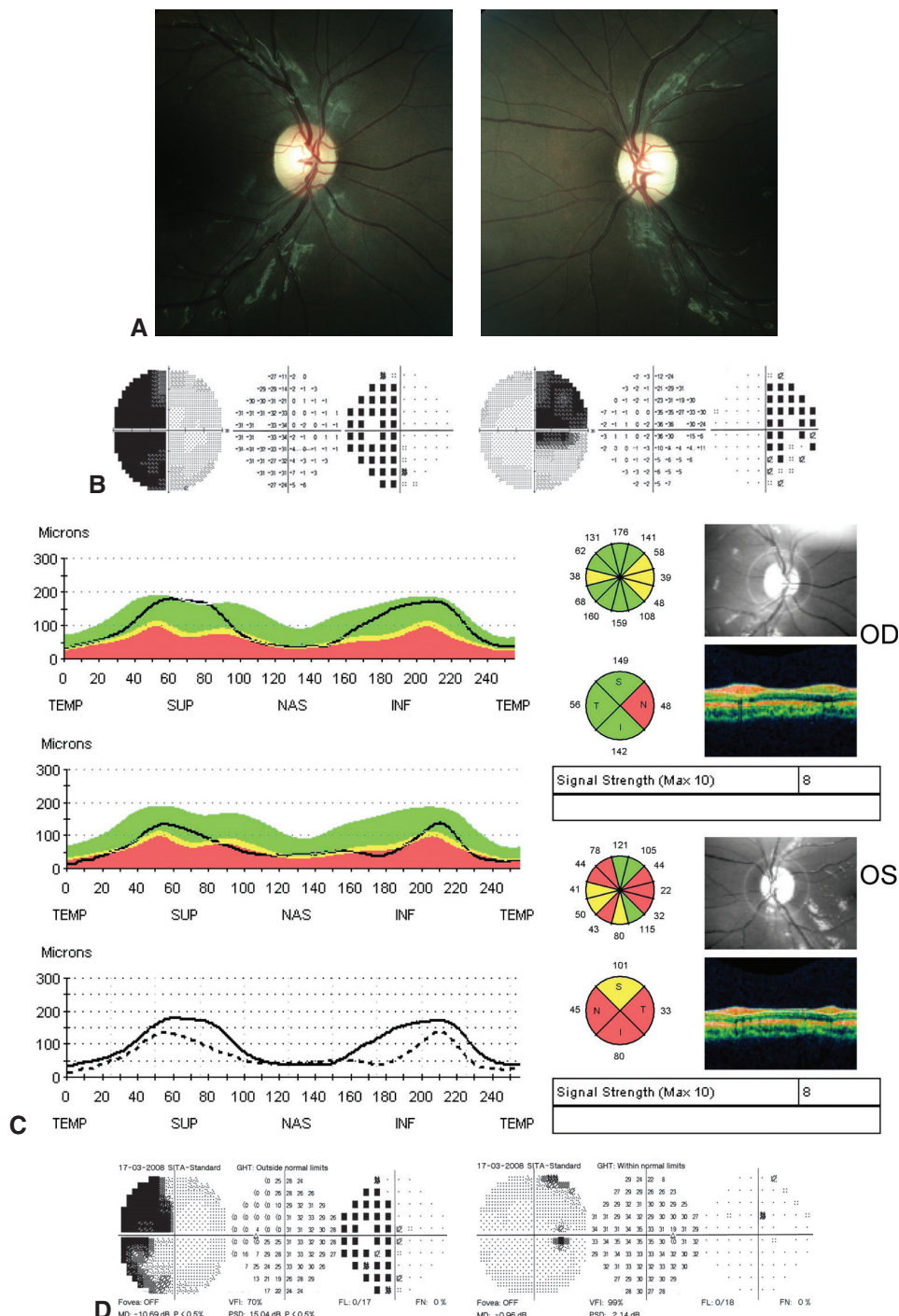


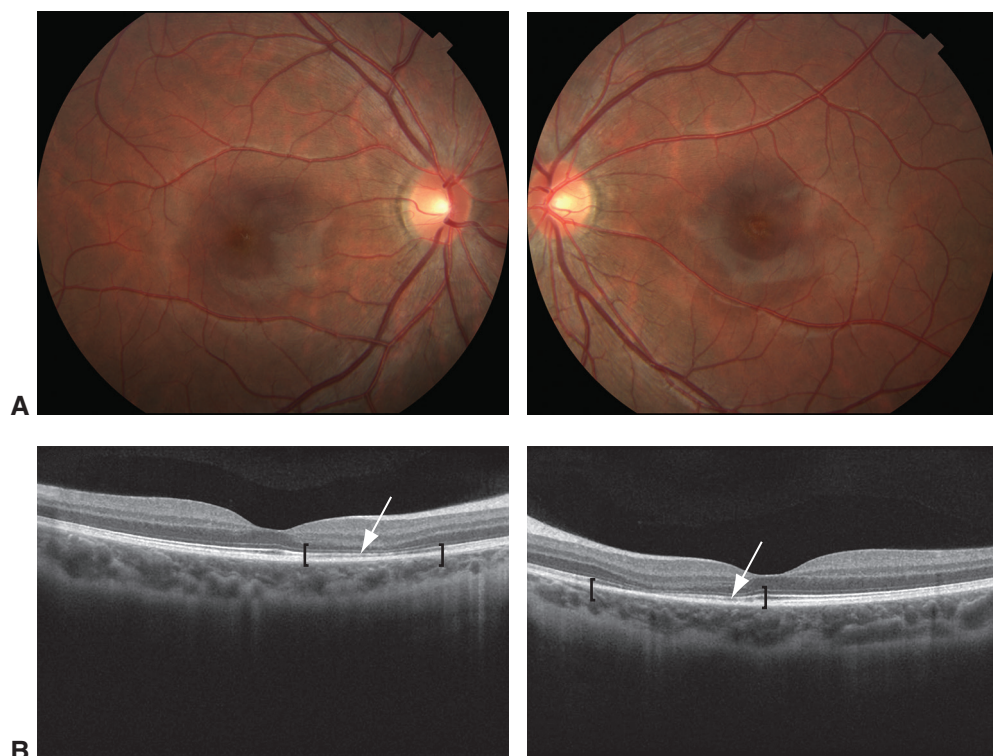


**Figure 3-19** Superior sectoral ONH pallor following nonarteritic anterior ischemic optic neuropathy, right eye. **A**, ONH photograph. **B**, Automated static perimetry shows an inferior visual field defect corresponding to the pallor shown in part **A**. **C**, OCT RNFL analysis demonstrates superior pRNFL thinning. (Courtesy of Helen V. Danesh-Meyer, MD, PhD.)

anywhere along the afferent visual pathway can reduce the amplitude or speed of the signal.

The VEP is clinically useful in 2 situations: (1) evaluation of the visual pathway in an inarticulate patient; and (2) confirmation of intact visual pathways in a patient with suspected nonorganic disease. A consistently abnormal flash response in an infant or inarticulate adult reflects gross impairment. Normal responses to patterned stimuli confirm intact visual pathways.





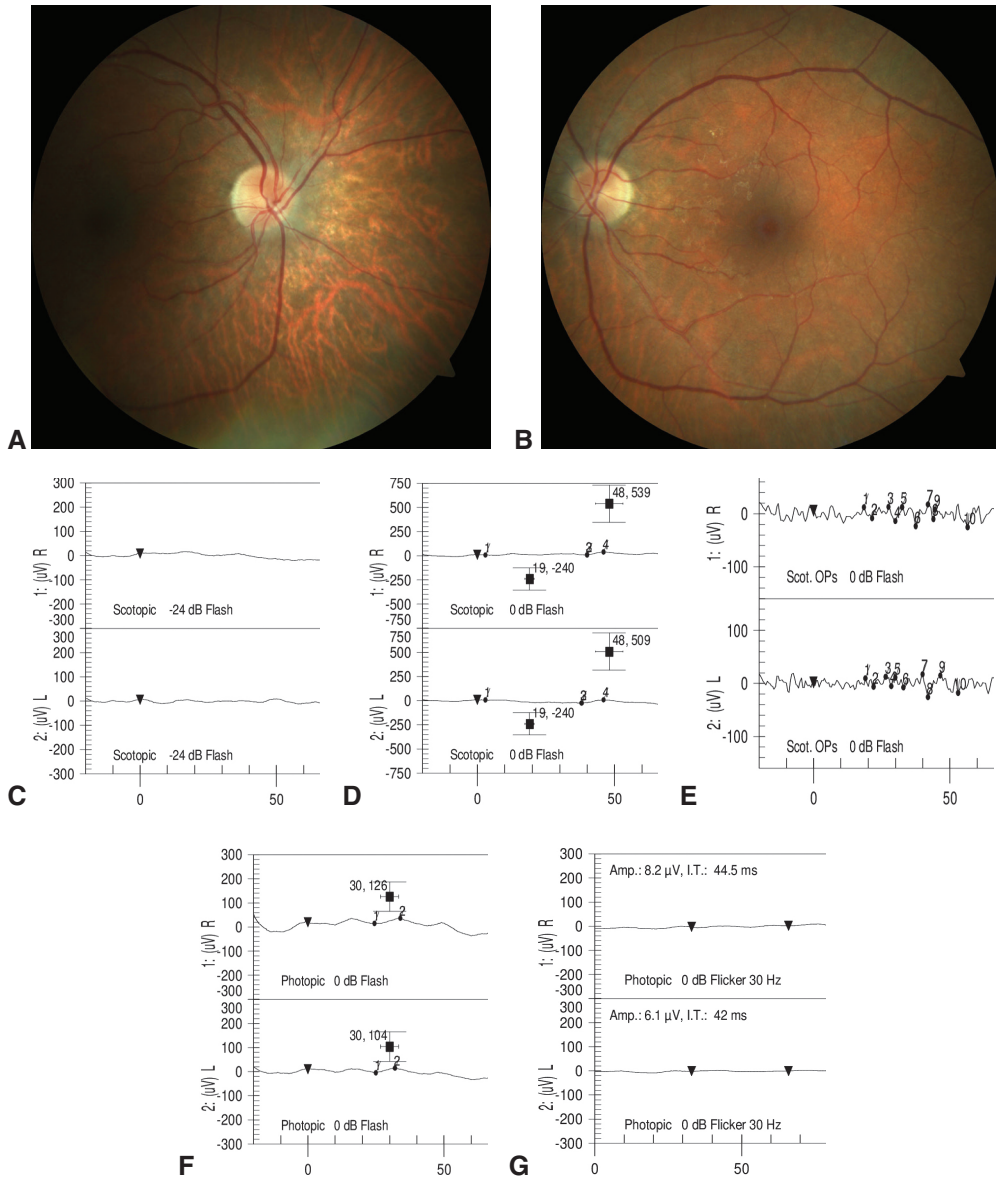
**Figure 3-21** Acute macular neuroretinopathy in a 16-year-old boy who presented with vision loss in both eyes. **A**, Fundus photographs reveal mild macular changes. **B**, Corresponding macular OCT line scans demonstrate the area of disruption (*brackets*) of the ellipsoid zone (*arrows*) in the nasal macula of each eye. (Reprinted with permission from Sitko KR, Athappilly G, Hedges TR III. *Ancillary testing in neuro-ophthalmology*. Focal Points: Clinical Modules for Ophthalmologists. American Academy of Ophthalmology; 2015, module 1.)

For a discussion of the technical aspects of the VEP, see BCSC Section 12, *Retina and Vitreous*.

### **Electroretinography**

Electroretinography (ERG) measures the electrical activity of the retina in response to various light stimuli under different states of light adaptation. Electrical activity is measured at the corneal surface by electrodes embedded in a contact lens worn for testing. For more detailed discussion of ERG, including technical aspects, see BCSC Section 12, *Retina and Vitreous*.

In *full-field ERG (ffERG)*, a Ganzfeld bowl uniformly illuminates the entire retina with a full-field luminance stimulus. The ffERG is useful in detecting diffuse retinal disease in cases of generalized or peripheral vision loss. Disorders such as retinitis pigmentosa (including the forms without pigmentation), rod-cone dystrophy, toxic retinopathies, and nonparaneoplastic and paraneoplastic syndromes (cancer-associated retinopathy [CAR], Fig 3-22; and melanoma-associated retinopathy [MAR]) may present with variably severe



**Figure 3-22** Cancer-associated retinopathy. **A and B**, Fundus photographs show mild arteriolar attenuation and findings of macular drusen and trace epiretinal membrane in the left eye. **C–G**: Full-field electroretinography testing is not recordable under scotopic conditions, and the maximum combined response is nearly extinguished. **C**, Dark-adapted, rod-specific response. **D**, Dark-adapted, mixed rod-cone response. **E**, Oscillatory potentials. **F**, Light-adapted, photopic single flash. **G**, Light-adapted, photopic flicker. (Courtesy of David A. DiLoreto Jr, MD, PhD.)

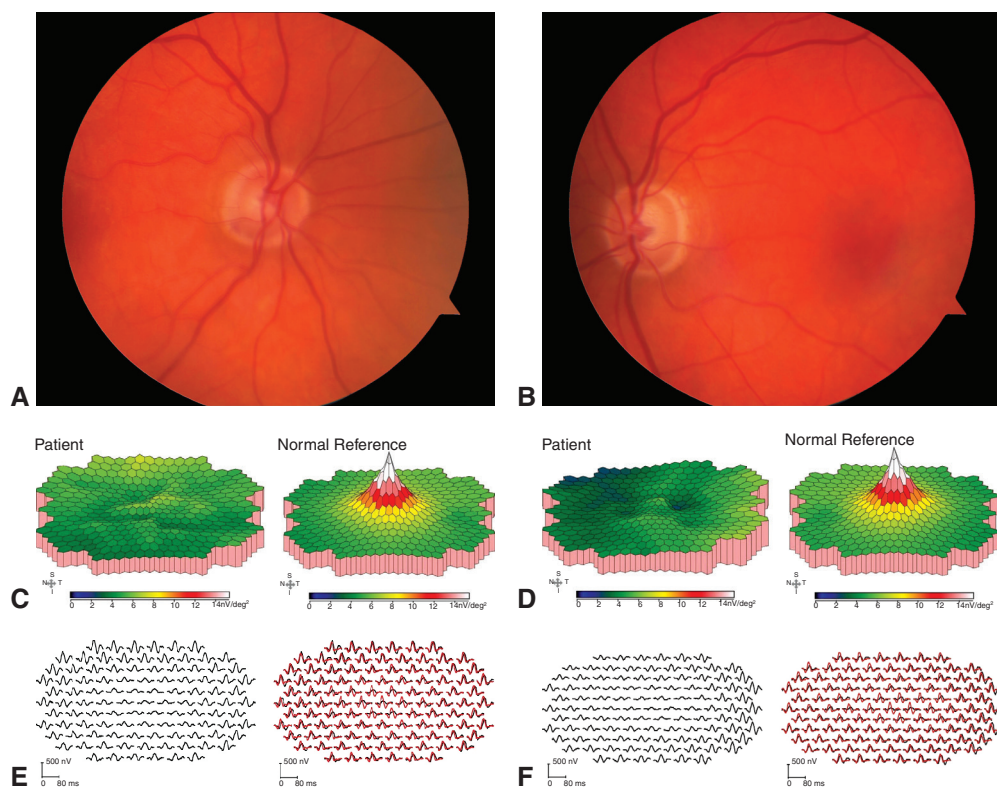
vision loss but minimal ophthalmoscopic findings. Invariably, the ERG pattern is severely depressed by the time substantial vision loss has occurred. However, in patients with minor or localized retinal disease, particularly maculopathy, the response may not be abnormal



even with severe vision loss, because the ffERG measures only a mass response of the entire retina.

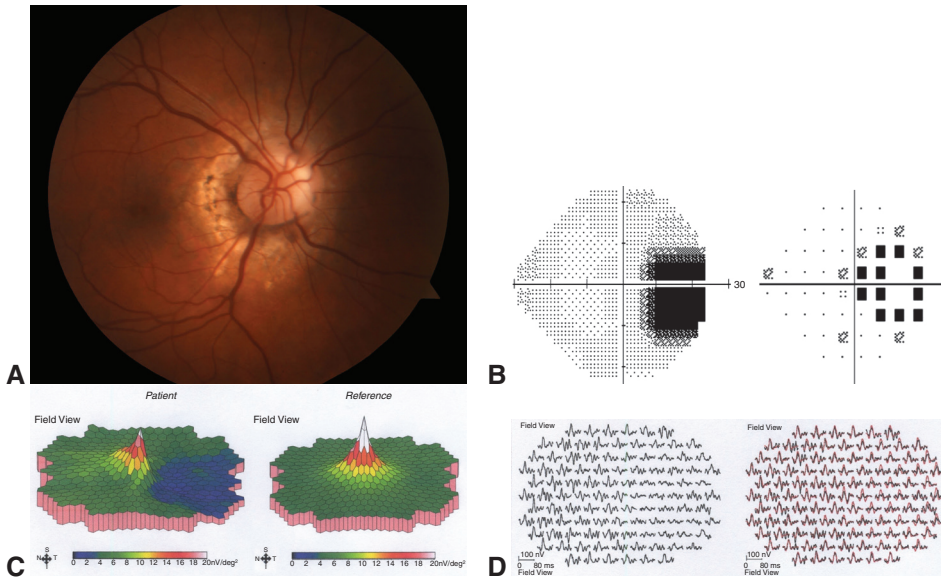
The *multifocal ERG (mfERG)* simultaneously records and topographically maps ERG signals from up to 250 focal retinal locations within the macula. As a light-adapted test, the mfERG evaluates the function of the cone system. Further, because responses from different regions of the retina are recorded with the mfERG, this modality is very useful in revealing occult focal retinal abnormalities, especially early cone (Fig 3-23) and cone-rod dystrophies. mfERG can differentiate optic nerve from macular disease in occult central vision loss, because the signal generally remains normal in optic nerve disease. Also, causes of outer retinal degeneration, such as MEWDS, AIBSE syndrome (Fig 3-24), AZOOR, and some toxic retinopathies (eg, metallosis), result in decreased waveforms on mfERG.

Hood DC, Odel JG, Chen CS, Winn BJ. The multifocal electroretinogram. *J Neuroophthalmol.* 2003;23(3):225–235.



**Figure 3-23** Early cone dystrophy. **A and B**, Color photographs show a normal-appearing fundus. **C and D**, Multifocal electroretinogram (mfERG) shows loss of the central peak bilaterally compared with normal reference. **E and F**, mfERG demonstrates flattening of the foveal waveforms bilaterally. (Courtesy of Zoë R. Williams, MD.)





**Figure 3-24** Acute idiopathic blind-spot enlargement (AIBSE) syndrome. **A**, Color photograph shows peripapillary pigmentary changes. **B**, Humphrey 24-2 SITA Standard visual field shows an enlarged blind spot with sensitivity of 0 dB in this region. **C and D**: mfERG shows depression (**C**) with flattening of waveforms in the region corresponding to the visual field defect (**D**). (Courtesy of Zoë R. Williams, MD.)



## CHAPTER 4

# The Patient With Decreased Vision Due to Retinal, Optic Nerve, and Chiasmal Diseases



*This chapter includes a related activity. Go to [www.aao.org/bcscactivity\\_section05](http://www.aao.org/bcscactivity_section05) or scan the QR code in the text to access this content.*

### Highlights

---

- The first step in obtaining an accurate diagnosis of visual loss is localizing the cause to a specific region(s) of the visual pathway.
- Optic neuritis is most commonly associated with multiple sclerosis, but myelin oligodendrocyte glycoprotein immunoglobulin G–associated disorder and neuromyelitis optica spectrum disorder should be considered as well.
- Visual field defects respecting the vertical meridian indicate a chiasmal or retrochiasmal lesion and should prompt neuroimaging.
- Visual field testing and optical coherence tomography provide valuable information to the clinician, but this information should be interpreted in the context of the history and examination findings.

### Introduction

---

When reduced vision is assessed in any patient, the initial goal is to localize the cause to a specific point in the visual pathway(s). Decreased vision may arise from refractive error or abnormalities in the ocular media, retina, optic nerve, optic tracts, lateral geniculate nucleus, optic radiations, or occipital cortex. Determining causation and ultimately management of the condition requires consideration of the patient's clinical history together with his or her physical examination and ancillary testing results, as outlined in Chapter 3. It is important to keep in mind that pre-chiasmal lesions cause monocular visual loss, whereas chiasmal and post-chiasmal lesions cause binocular visual loss (with the very rare exception of temporal crescent syndrome).

Because of the complexity of this process, diseases of the visual pathway have been divided into 2 chapters. This chapter covers diseases of the retina, optic nerve, and chiasm,

that is, the anterior visual pathway; and Chapter 5 discusses diseases of the optic tract to the visual cortex and its associated areas, that is, the posterior, or *retrochiasmal*, visual pathway.

## Ocular Media Abnormalities

Although irregularities or opacities of the ocular media tend to reduce visual acuity, they do not affect pupils, color vision, or the appearance of the posterior pole. In fact, corneal diseases such as dry eye or epithelial basement membrane dystrophy, as well as lenticular abnormalities and posterior capsule opacification in pseudophakic patients, may be subtle enough to be missed during a cursory ophthalmic examination. However, they may be identified by careful slit-lamp examination and may also cause generalized reduced sensitivity on automated perimetry testing. In cases of presumed unexplained vision loss, these conditions may be diagnosed only during a thorough neuro-ophthalmologic evaluation.

## Retinopathy

Although retinal disorders usually cause obvious abnormalities on fundus examination and the diagnosis is straightforward, in many cases retinal pathology can be subtle and may be overlooked. For example, maculopathies can mimic an optic neuropathy (Table 4-1). Either disease can cause decreased visual acuity and central visual field loss with variable color vision loss. However, maculopathy tends to cause parallel losses in color discrimination and visual acuity, unlike optic nerve disease, which may cause a disproportionately greater loss in color vision than in visual acuity, particularly if the disease is inflammatory or compressive. The exception is cone dystrophy, in which patients with severe color

**Table 4-1 Clinical Distinction Between Optic Neuropathy and Maculopathy**

Clinical Finding	Optic Neuropathy	Maculopathy
<b>Symptom</b>		
Metamorphopsia	Rare	Common
Dyschromatopsia	Common	Rare
Pain	Common in optic neuritis	None
Photophobia/glare	Rare	Sometimes
Photopsia	Rare	Common
<b>Finding</b>		
Amsler grid finding	Absent lines (scotoma)	Distorted lines
Ophthalmoscopy findings	Normal, pale, or swollen ONH Macula normal	Normal or pale ONH Macula normal or abnormal
Photostress test result	Normal	Delayed
Reduced visual acuity	Common	Common
Relative afferent pupillary defect	Present if unilateral or bilateral if asymmetric	None, unless there is extensive retinal damage
Visual field defect	Central scotoma, nerve bundle defect	Central scotoma

ONH = optic nerve head.

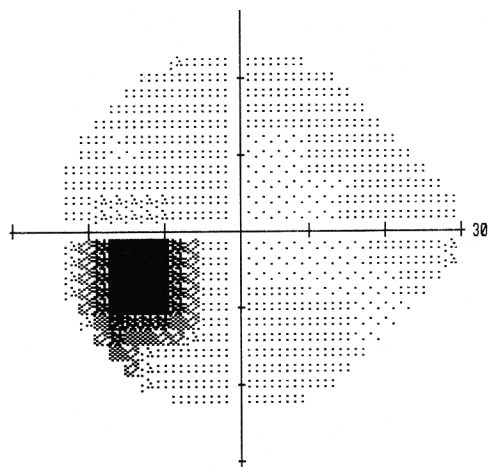
impairment may have relatively unimpaired central visual acuity. Also, unless there is extensive retinal abnormality, relative afferent pupillary defect (RAPD) is usually not present in maculopathy. In contrast, metamorphopsia almost always has a macular origin and is common in maculopathies but is rare in optic neuropathies. Finally, visual field deficits in maculopathy tend to be focal and central, whereas deficits in optic neuropathies tend to be larger, often cecentral, and part of a generalized depression of visual field sensitivity.

As mentioned earlier, findings on the fundus examination can facilitate diagnosis, as maculopathies generally produce visible abnormalities; however, when the abnormality is subtle, it can be mistaken for an optic neuropathy. Optical coherence tomography (OCT), autofluorescence imaging of the macula, fluorescein angiography, and multifocal electroretinography (mfERG) may also help detect an abnormality in retinal structure or function. (See Chapter 3 in this volume and BCSC Section 12, *Retina and Vitreous*, for further discussion of these imaging techniques.)

Common maculopathies and retinopathies that are often mistaken for optic nerve disease include acute idiopathic blind-spot enlargement (AIBSE) syndrome and acute zonal occult outer retinopathy (AZOOR), both of which overlap with multiple evanescent white dot syndrome (MEWDS) as well as cone dystrophy. Patients with these diseases may present with normal ophthalmoscopic findings. Rarer conditions include cancer-associated retinopathy and melanoma-associated retinopathy. Other retinal disorders that may be mistaken for optic neuropathies include central serous chorioretinopathy and cystoid macular edema (these disorders are discussed in detail in BCSC Section 12, *Retina and Vitreous*).

### AIBSE Syndrome, AZOOR, and MEWDS

Traditionally, enlargement of the blind spot (Fig 4-1) on visual field testing is associated with changes of the optic nerve head (ONH), such as edema or tilting. However, in *AIBSE syndrome* the prominent visual symptom is a monocular scotoma, which is often temporal in location and is associated with photopsias, thought to reflect disease of the outer retina. The main finding is an enlarged blind spot. The fundus may appear normal or may show



**Figure 4-1** Idiopathic blind-spot enlargement syndrome. A 32-year-old woman presented with a 6-month history of continuously flashing lights to the left side in her left eye. Visual acuity was 20/15 bilaterally with a  $<0.3$ -log unit left relative afferent pupillary defect. Humphrey 24-2 perimetry shows enlargement of the physiologic blind spot. This temporal defect does not respect the vertical midline. (Courtesy of Michael S. Lee, MD.)



evidence of ONH edema, peripapillary retinal lesions, choroiditis, changes in the retinal pigment epithelium (RPE), or uveitis. The mfERG shows depression in the peripapillary region, whereas a full-field electroretinography (ffERG) response may demonstrate depressed a-waves or substantial intereye asymmetry. Spectral-domain OCT may also reveal attenuation of the outer layers.

AZOOR is similar to AIBSE syndrome but is associated with more extensive retinal changes. This variability has led to questions about whether they are separate diseases or represent a spectrum of a single disorder. MEWDS exemplifies this controversy. Fundus examination for MEWDS may reveal characteristic small, deep, gray, white, or yellow-white dots in the posterior retina that usually last for weeks, resolving spontaneously. The transient nature of the lesions could explain the normal retinal appearance at first examination. Fluorescein angiography and indocyanine green angiography results are often abnormal.

Although patients with these 3 diseases may present with normal ophthalmoscopic findings, multimodal retinal imaging may help differentiate the disorders. Patients may also have a small RAPD, even though AIBSE syndrome, AZOOR, and MEWDS represent outer retinal disorders. In general, these patients have a good visual prognosis. See BCSC Section 9, *Uveitis and Ocular Inflammation*, and Section 12, *Retina and Vitreous*, for further discussion.

Jampol LM, Wiredu A. MEWDS, MFC, PIC, AMN, AIBSE, and AZOOR: one disease or many? *Retina*. 1995;15(5):373–378.

Marsiglia M, Gallego-Pinazo R, Cunha de Souza E, et al. Expanded clinical spectrum of multiple evanescent white dot syndrome with multimodal imaging. *Retina*. 2016;36(1):64–74.

Monson DM, Smith JR. Acute zonal occult outer retinopathy. *Surv Ophthalmol*. 2011;56(1):23–35.

Mrejen S, Khan S, Gallego-Pinazo R, Jampol LM, Yannuzzi LA. Acute zonal outer occult retinopathy: a classification based on multimodal imaging. *JAMA Ophthalmol*. 2014;132(9):1089–1098.

Volpe NJ, Rizzo JF III, Lessell S. Acute idiopathic blind spot enlargement syndrome: a review of 27 new cases. *Arch Ophthalmol*. 2001;119(1):59–63.

## Cone Dystrophy

Cone dystrophy is a rare disorder characterized by vision loss that may be mistaken for a bilateral optic neuropathy. Patients of any age with this disorder can present with a gradually progressive decline in visual acuity and color vision. Photophobia and hemeralopia (day blindness) are also common.

In the early stages of cone dystrophy, the fundus can appear normal or show a slightly blunted foveal reflex with granular macular pigmentation. As the disease progresses, however, the macular RPE becomes atrophic in a central oval region. A “bull’s-eye” pattern of depigmentation may also occur. Fluorescein angiography and fundus autofluorescence may reveal these abnormalities before they become clinically apparent. Results of ffERG may also be normal initially but eventually show markedly depressed photopic (cone) response and less prominently affected scotopic (rod) response, whereas mfERG studies reveal central depression. OCT scans may show thinning of outer macular layers, loss of

the ellipsoid zone, and outer cavitation. See BCSC Section 12, *Retina and Vitreous*, for further discussion.

## **Autoimmune Retinopathies and Paraneoplastic Retinopathies**

### ***Cancer-associated retinopathy***

Patients with cancer-associated retinopathy (CAR) present with bilateral progressive vision loss that may be unilateral or asymmetric in onset and impaired color vision. Associated symptoms include photopsias, nyctalopia (night blindness), impaired dark adaptation, ring scotoma, and peripheral and/or central visual field loss. Symptoms worsen over weeks to months, often before the underlying malignancy is identified.

Upon examination, the fundus may initially appear normal, but the ERG response shows markedly reduced amplitudes. As the disease progresses, the retinal arterioles become attenuated, the RPE thinned and mottled, and the ONHs atrophic. Vision loss is typically severe.

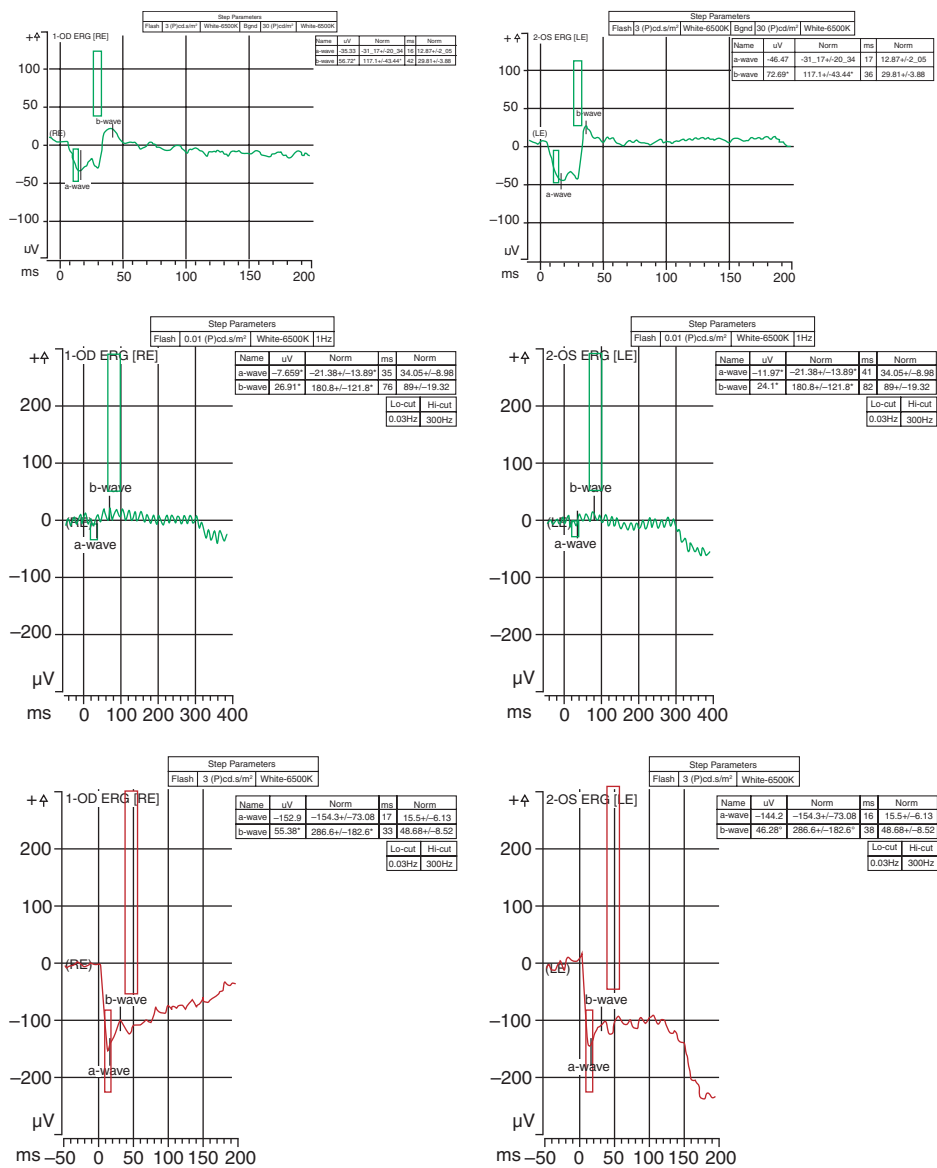
CAR is most often caused by small-cell lung carcinoma, although breast, uterine, cervical, and other lung malignancies have been reported. When CAR is suspected, the patient should be tested for the presence of antibodies against retinal proteins (ideally by both Western blot and immunohistochemical analyses). Serum antiretinal antibody testing is commercially available. It should be noted, however, that antiretinal antibodies are not specific and can be found in healthy individuals; also, results can differ depending on the laboratory. Antibodies against recoverin, the best-characterized antibody, are found in only a minority of patients with CAR. If clinical suspicion of CAR remains high but antibody test results are negative, the ophthalmologist should look for an underlying cancer.

Empiric treatment with various combinations of corticosteroids, plasmapheresis, and intravenous immunoglobulin (IVIG) has been reported; in general, however, the prognosis for vision is poor.

### ***Melanoma-associated retinopathy***

Melanoma-associated retinopathy (MAR) is a rare syndrome involving primarily rod bipolar cells that typically develops in patients with previously diagnosed melanoma. Although it may have a sudden onset, MAR usually develops over weeks to months. Visual acuity, color vision, and the central visual field are often initially normal with prominent bilateral peripheral visual field loss. Corresponding symptoms are photopsia and nyctalopia.

In patients with MAR, the fundus may appear normal, or it may show RPE irregularity, retinal arteriolar attenuation, or ONH pallor. The ffERG response reveals rod dysfunction but classically demonstrates an electronegative pattern: selective impairment of b-waves, particularly for the mixed rod–cone responses, indicating inner retinal dysfunction. An electronegative ERG has a limited differential diagnosis (central retinal artery occlusion [CRAO] and congenital stationary night blindness), and in patients with acute or subacute onset retinal degeneration is suggestive of MAR (Fig 4-2). The mfERG pattern is relatively preserved because MAR affects rod function.



**Figure 4-2** Melanoma-associated retinopathy. A 60-year-old woman presented with a 6-month history of photopsias, nyctalopia, and reduced peripheral vision in both eyes. Visual fields showed mild constriction in each eye. Fundus was unremarkable aside from subtle arteriolar attenuation. Full-field electroretinography demonstrated borderline cone responses (*top row*), nonrecordable rod responses (*middle row*), and reduced b-waves on mixed rod–cone responses (*bottom row*). This electronegative pattern indicates inner retinal dysfunction. Systemic workup revealed a pigmented thigh lesion that was pathologically confirmed to be a melanoma. (Courtesy of Gregory Van Stavern, MD.)

Unlike in CAR, in MAR visual function may remain stable and nonprogressive. No treatment has proven effective, but anecdotal success has been reported with IVIG.

Braithwaite T, Holder GE, Lee RW, Plant GT, Tufail A. Diagnostic features of the autoimmune retinopathies. *Autoimmun Rev*. 2014;13(4–5):534–538.

Gordon LK. Paraneoplastic syndromes in neuro-ophthalmology. *J Neuroophthalmol*. 2015;35(3):306–314.

### ***Nonparaneoplastic autoimmune retinopathy***

In 50% of affected patients, nonparaneoplastic autoimmune retinopathy (npAIR) is associated with an autoimmune disease. npAIR has a variable presentation that may include decreased visual acuity, peripheral visual field loss, positive visual phenomenon, or nyctalopia. ERG findings are also variable but usually depict cone-system dysfunction, either macular or generalized, with postphototransduction involvement. The clinician should diagnose npAIR only after a comprehensive systemic investigation to exclude occult malignancy. npAIR-associated antibody targets overlap with those of CAR, with the exception of recoverin, which has not been reported in npAIR to date.

Rahimy E, Sarraf D. Paraneoplastic and non-paraneoplastic retinopathy and optic neuropathy: evaluation and management. *Surv Ophthalmol*. 2013;58(5):430–458.

## **Optic Neuropathy**

---

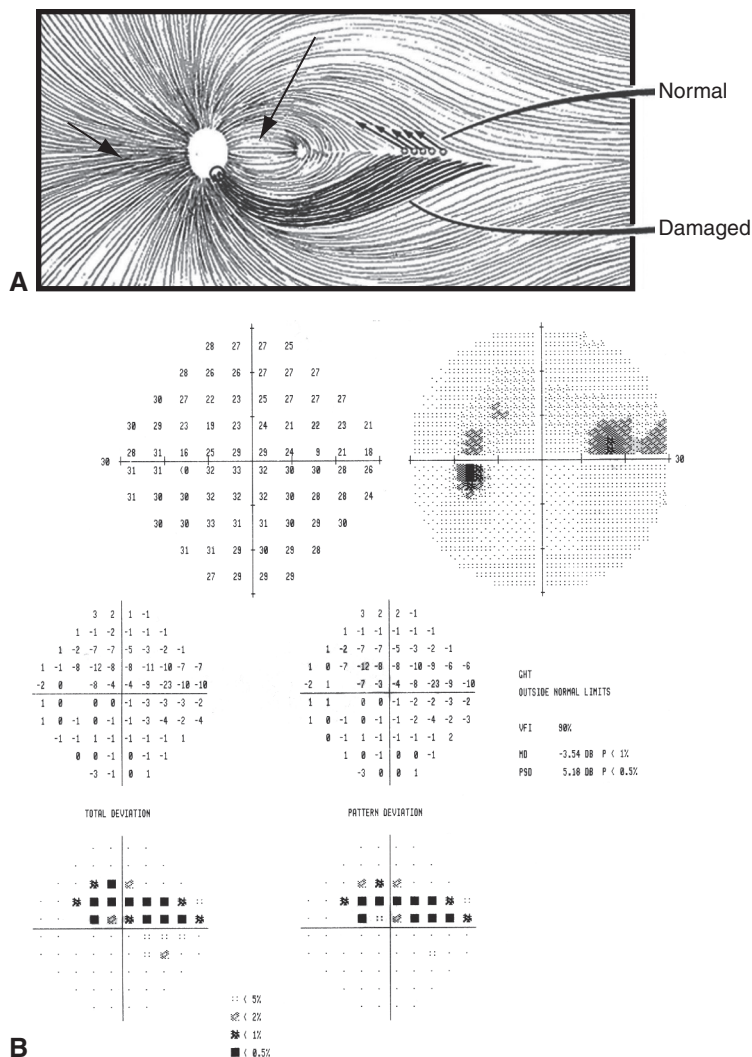
Typically, patients with optic neuropathies present clinically with visual acuity and visual field losses and dyschromatopsia; in addition, in those with unilateral or asymmetric damage, an RAPD is also common. The ONH may appear normal or acutely swollen; optic nerve pallor typically develops 4–6 weeks later, even after vision has recovered.

### **Visual Field Patterns in Optic Neuropathy**

Retinal ganglion cell nerve fibers enter the ONH in 3 major groups (Fig 4-3). Therefore, visual field loss attributable to lesions of the optic nerve may be associated with 3 types of fibers/visual field defects (Table 4-2):

- *papillomacular fibers*: cecentral scotoma (Fig 4-4A, left panel), paracentral scotoma (Fig 4-4A, right panel), and central scotoma (Fig 4-4B)
- *arcuate fibers*: arcuate scotoma (nerve fiber bundle) (Fig 4-4C), altitudinal defect (broader region of arcuate fibers) (Fig 4-4D), and nasal (step) defects (temporal portion of arcuate fibers) (Fig 4-4E). These fibers align along the temporal horizontal retinal raphe; when they are damaged, the resulting defects respect and do not cross the nasal horizontal meridian.
- *nasal radiating fibers*: temporal wedge defect

Blind-spot enlargement due to ONH edema from any cause results in displacement of the peripapillary retina (Fig 4-4F).



**Figure 4-3** Retinal ganglion cell nerve fibers. **A**, Schematic representation of retinal nerve fiber layer entering the optic nerve head (ONH). The fibers are classified as arcuate (*inferior bundle highlighted*), papillomacular (*long arrow*), and nasal radiating (*short arrow*). **B**, Humphrey 30-2 perimetry grayscale diagram of the left eye, showing a superior arcuate visual field defect corresponding to the inferior arcuate nerve fiber bundle (*damage highlighted*). (Part B courtesy of Michael S. Lee, MD.)

### Causes of Optic Neuropathy

When optic neuropathy is suspected or confirmed, the patient's clinical characteristics can help determine the underlying cause. These include the patient's age, mode of onset, laterality of the defect, presence of pain, color vision, type of visual field defects, optic nerve appearance, and results of orbital magnetic resonance imaging (MRI). The broad etiologic categories of this disorder, which are discussed in the following subsections and outlined in Table 4-3, should also be considered.



**Table 4-2 Glossary of Perimetric Terms**

Term	Characteristics
<b>Characteristics of the visual field defect</b>	
Absolute	No stimulus perceived in the affected area
Relative	Bigger and brighter stimuli may be perceived in the affected field, but smaller, dimmer targets are not seen. Therefore, size and shape of the visual field defect change inversely with changes in size and/or intensity of the presented stimulus. Defects may be described as shallow when only the smallest or dimmest targets cannot be identified or as deep when bright objects are not detected in the central portion of the defect.
<b>Terms describing the visual field defect</b>	
Scotoma	Represents area of depressed visual function surrounded by normal visual function (eg, the blind spot) (see Fig 4-4A)
Central	Involves fixation only (see Fig 4-4B)
Cecocentral	Extends from fixation temporally to the blind spot (see Fig 4-4A, left panel)
Paracentral	Involves a region next to, but not including, fixation (see Fig 4-4A, right panel)
Pericentral	Involves a region symmetrically surrounding, but not involving, fixation
Arcuate	Corresponds to and represents nerve fiber bundle loss (see Fig 4-4C)
Altitudinal	Represents a more extensive arcuate defect involving 2 quadrants in either the superior or inferior field (see Fig 4-4D)
Quadrantanopia	Involves 1 quadrant of the visual field
Hemianopia	Involves one-half of the visual field, either nasal or temporal (see Fig 4-26)
<b>Description of bilateral visual field defects with respect to spatial localization and extent</b>	
Homonymous	Same side of visual field affected in each eye (see Fig 4-26)
Bitemporal	Opposite temporal sides of visual field affected in each eye (see Fig 4-26)
Complete	Entire field affected
Incomplete	A portion of the field spared (see Fig 4-26)
Congruous	Symmetric homonymous defect (ie, having similar size, location, and shape in the fields of the right and left eyes)

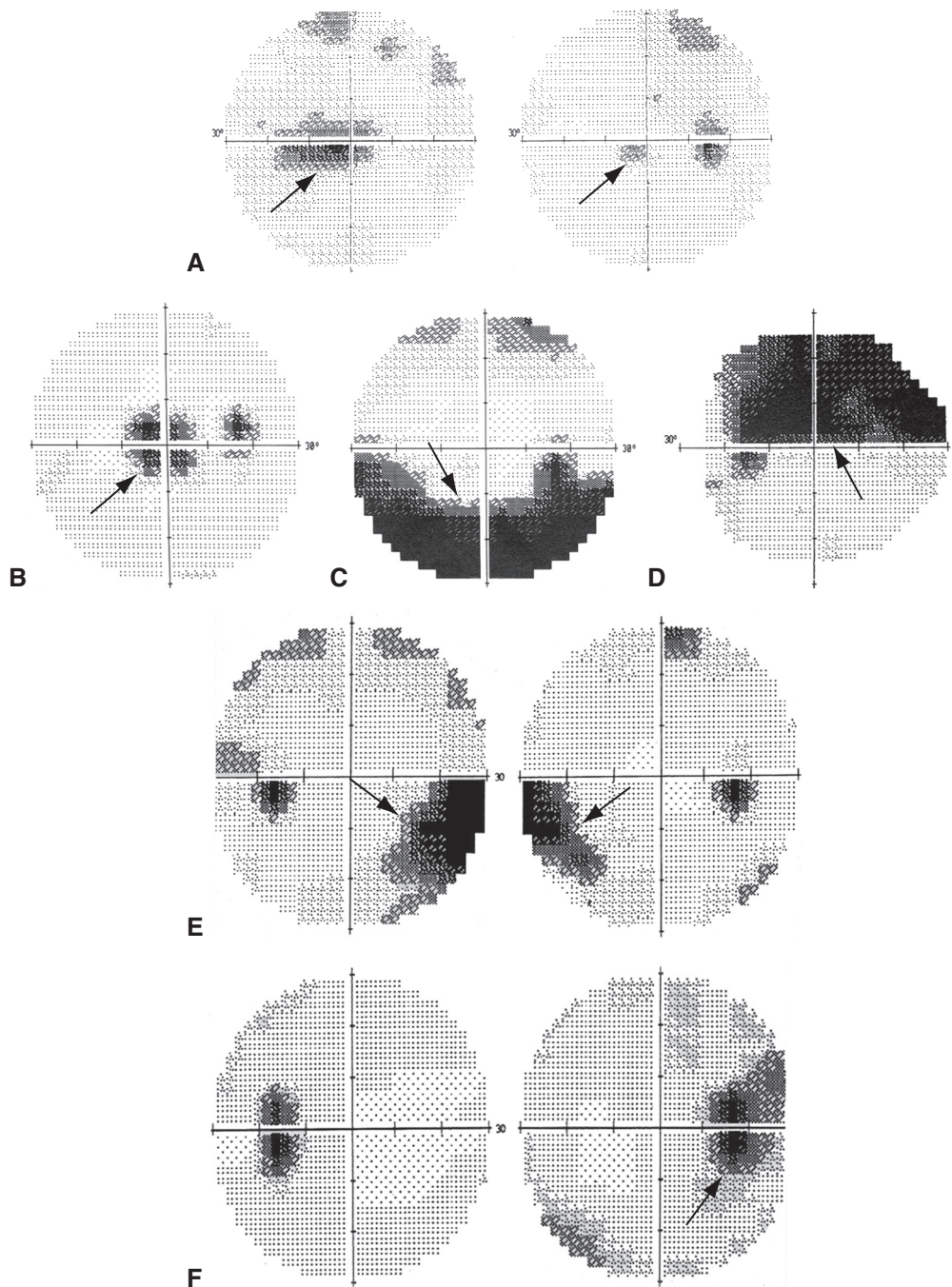
Biousse V, Newman NJ. Optic neuropathies. In: *Neuro-Ophthalmology Illustrated*. 2nd ed. Thieme; 2015:179–244.

### **Papilledema**

*Papilledema* refers to ONH edema resulting from increased intracranial pressure (ICP). Papilledema may result from a variety of conditions, including

- an intracranial mass
- hydrocephalus
- meningeal processes, such as an infection of the central nervous system (CNS) or infiltration by a granulomatous or neoplastic process
- increased venous pressure from cerebral venous thrombosis, venous sinus stenosis, or dural fistula
- idiopathic intracranial hypertension (IIH)

On ophthalmoscopy, papilledema is indistinguishable from other causes of ONH edema. Acute papilledema produces hyperemia of the ONH, with dilation of the existing



**Figure 4-4** Patterns of visual field loss in optic neuropathies, as shown on automated perimetry. **A**, Cecocentral scotoma in the left eye (*left; arrow*); paracentral scotoma in the right eye (*right; arrow*). **B**, Central scotoma in the right eye (*arrow*). **C**, Arcuate scotoma in the right eye (*arrow*). **D**, Broad arcuate (altitudinal) defect in the left eye (*arrow*). **E**, Nasal arcuate (step) defects in both eyes (*arrows*). **F**, Enlarged blind spot in the right eye (*arrow*), worse than in the left eye. (*Parts E and F courtesy of Anthony C. Arnold, MD.*)

**Table 4-3 Select Etiologies of Optic Neuropathy****Papilledema (increased intracranial pressure)****Glaucoma****Inflammatory disease (optic neuritis)**

- Idiopathic optic neuritis (associated with multiple sclerosis)
- Neuromyelitis optica spectrum disorder (Devic disease)
- Myelin oligodendrocyte glycoprotein immunoglobulin G–associated disorder
- Infections
- Systemic inflammatory disorders

**Vascular conditions (ischemic optic neuropathy)**

- Anterior/posterior
- Arteritic/nonarteritic

**Radiation optic neuropathy****Compressive/infiltrative lesions**

- Neoplastic
- Nonneoplastic

**Hereditary conditions****Toxic substances and nutritional deficiency****Trauma****Congenital optic nerve head anomalies**

- Optic nerve hypoplasia
- Tilted disc syndrome
- Excavated optic nerve head anomalies

**Optic disc drusen**

ONH surface capillary net and telangiectasia of the surface and radial peripapillary vessels. The edematous peripapillary retinal nerve fiber layer (pRNFL) is grayish white and opalescent, with feathered, striated margins that obscure the ONH edge and the retinal vessels coursing through it. Papilledema begins at the superior and inferior poles of the ONH. As it worsens, papilledema encompasses the nasal ONH, creating a C-shaped area of ONH edema with the opening along the temporal rim. The edema eventually involves the entire ONH and causes blurring of major vessels off the ONH. Late findings include absence of the physiologic cup and obscuration of vessels on the ONH itself.

Absence of spontaneous venous pulsations may reflect increased ICP, but this finding is of limited value at initial examination, as 20% of the general population has no spontaneous venous pulsations. However, the disappearance of these pulsations after prior documented presence does suggest ICP elevation. Other ophthalmoscopic findings may include ONH and peripapillary cotton-wool spots, exudates, and hemorrhage.

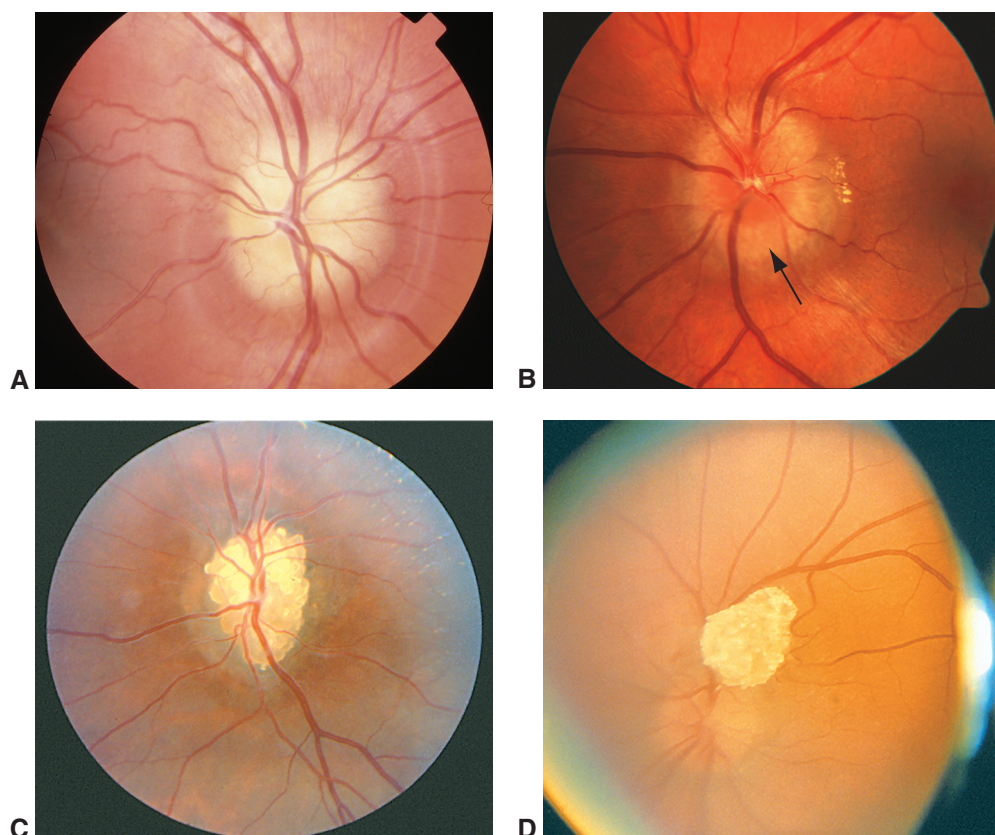
Most patients with elevated ICP report headache, nausea, and vomiting. Patients may also note transient visual obscurations—episodes of unilateral or bilateral vision loss lasting seconds. These episodes are described as “grayouts,” “whiteouts,” or “blackouts” of vision, often occurring with orthostatic changes. Of note, in patients with papilledema related to or secondary to IIH, these obscurations are not prognostic of optic nerve damage (discussed later in this chapter). In the early stages of papilledema, however, optic nerve function, including visual acuity and color vision, is usually normal. Pupillary responses are also normal, and visual fields demonstrate only enlargement of the blind spot (see Fig 4-1).

The clinician’s first step in managing suspected papilledema is to rule out pseudo-papilledema, a condition that usually results from optic disc drusen (ODD) (Fig 4-5; also

see the discussion of ODD later in this chapter). In contrast, as stated earlier, true ONH edema has the following ophthalmoscopic features:

- hyperemia
- microvascular abnormalities on the ONH surface, such as telangiectasia or flame hemorrhages
- opacification of the pRNFL

Other conditions that cause the ONH to appear elevated, mimicking papilledema, include hyaloid remnants and glial tissue on the ONH surface, congenital “fullness” of the ONH associated with entry of the optic nerve into the eye through a relatively small scleral



**Figure 4-5** Appearance of optic disc drusen. **A**, Fundus photograph of the ONH with buried drusen. The ONH margin is blurred, with yellowish opacity of the deep peripapillary tissue. The retinal vessels are clearly visible overlying the ONH. **B**, Fundus photograph of the ONH with papilledema. The ONH margin is blurred, with grayish-white, opalescent thickening of the peripapillary retinal nerve fiber layer (*arrow*). The retinal vessels are partially obscured at the ONH margin and within the peripapillary retina. Exudates from chronic edema are visible just temporal to the ONH. **C**, Surface drusen demonstrate prominent refractile nodules on the ONH surface, which do not obscure retinal vessels. **D**, Astrocytic hamartomas are nodular masses that arise from the peripapillary retina and obscure the retinal vessels. (*Parts A and B courtesy of Sophia M. Chung, MD; parts C and D reprinted from Arnold AC. Optic disc drusen. Ophthalmol Clin North Am. 1991;4:505–517.*)



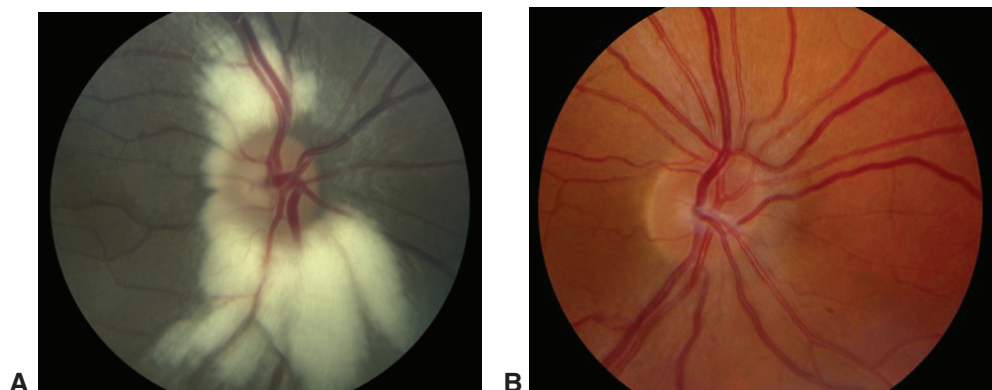
canal, and fullness associated with hyperopia. Vitreopapillary traction can also cause a swollen-appearing ONH. In addition, myelination of the RNFL, which typically occurs at the ONH margin, can obscure the ONH–retina border without elevation (Fig 4-6). Myelination in the RNFL also obscures the retinal vessels and produces a feathered edge that resembles true edema. However, myelination appears as a dense, white opacity, whereas true edema has a partially translucent, grayish-white appearance.

Suspicion of papilledema warrants urgent brain imaging, ideally MRI of the brain and orbits with contrast medium and magnetic resonance venography (MRV) to rule out an intracranial mass lesion and cerebral venous thrombosis. Normal brain imaging results should prompt lumbar puncture for evaluation of cerebrospinal fluid (CSF) opening pressure and composition.

Katz BJ. The anomalous optic nerve. *Focal Points: Clinical Modules for Ophthalmologists*. American Academy of Ophthalmology; 2011, module 3.

**Chronic papilledema** Optic nerve function may deteriorate in patients with chronically elevated ICP and long-standing papilledema (lasting months to years). The ONH may no longer appear hyperemic but may instead look pale as the result of chronic axonal loss (Fig 4-7). Additional features may include the following:

- *Gliosis of the pRNFL*, an opacification that appears grayish, less fluffy, and more membranous than edema. Gliosis tends to follow retinal vessels, producing vascular sheathing.
- *Optociliary shunt vessels (retinochoroidal collaterals)*, which are preexisting venous channels on the ONH surface that dilate in response to chronic central retinal vein obstruction (CRVO) from elevated ICP. Unlike congenital ONH anomalies or the retinal vascular anomalies often accompanying drusen, these collateral vessels follow an evolving course of enlargement over time and characteristically penetrate deep into the choroid immediately adjacent to the ONH.

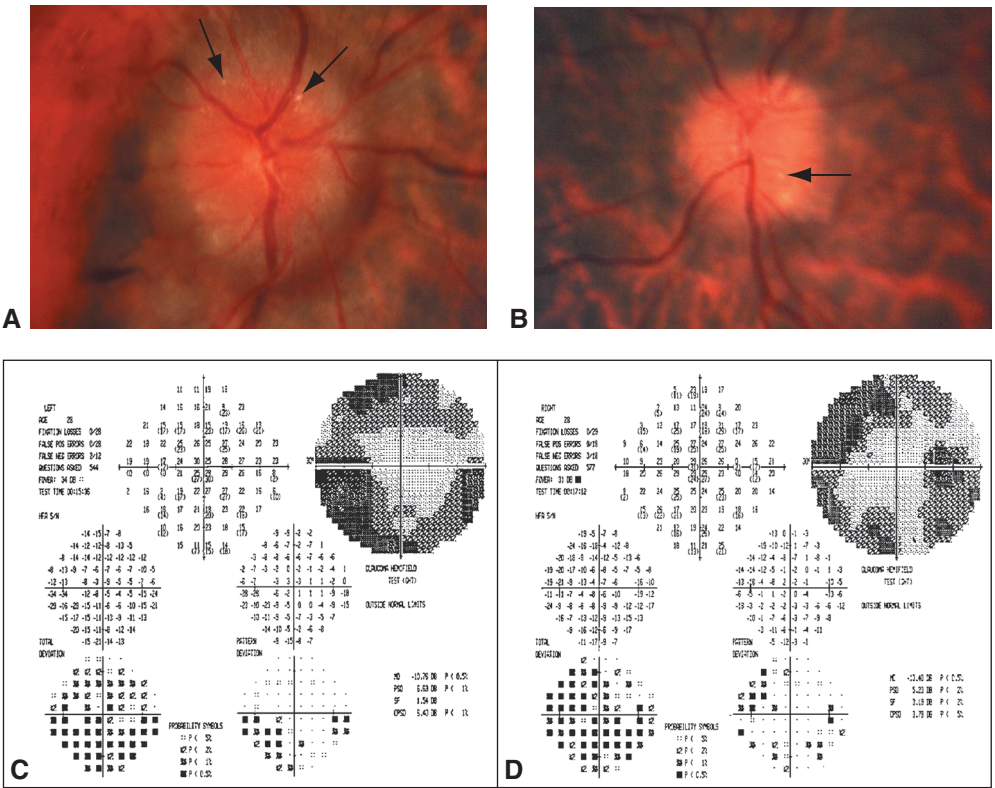
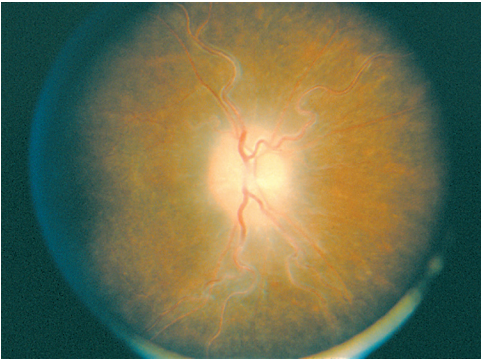


**Figure 4-6** Myelinated nerve patches are often present within the arcuate bundles, occasionally abutting the ONH. When contiguous, these nerve patches may be mistaken for ONH edema or cotton-wool spots. **A**, Myelinated nerve fibers. **B**, A normal ONH. (Courtesy of Gregory Van Stavern, MD.)



- *Refractile bodies of the ONH*, which are the result of chronic lipid-rich exudation (Fig 4-8). Unlike drusen, these bodies tend to be small and noncalcified. They remain on the ONH surface rather than within its substance, with frequent clustering at the ONH margin, and disappear as papilledema resolves.

**Figure 4-7** Chronic atrophic papilledema with gliosis and retinal vascular sheathing. (Courtesy of Anthony C. Arnold, MD.)



**Figure 4-8** Chronic papilledema. **A** and **B**, ONHs in chronic papilledema, with the development of refractile bodies (arrows) representing lipid exudates from chronic microvascular leakage. **C** and **D**, Visual field patterns confirm the presence of mild diffuse depression in sensitivity and superior and inferior arcuate defects. (Parts **A** and **B** courtesy of Anthony C. Arnold, MD; parts **C** and **D** courtesy of Steven A. Newman, MD.)

With chronic papilledema, visual field defects may include nasal field loss, arcuate scotomata, and generalized peripheral depression. Central visual field involvement with decreased visual acuity typically does not occur until late. The process is usually bilateral; when it is asymmetric, an RAPD may occur.

Chen JJ, Bhatti MT. Papilledema. *Int Ophthalmol Clin*. 2019;59(3):3–22.

**Idiopathic intracranial hypertension** Patients with IIH, also known as *pseudotumor cerebri*, present with symptoms and signs of elevated ICP. Headache is common. Neck and back pain, transient visual obscurations, diplopia (secondary to cranial nerve [CN] VI palsy), CN VII dysfunction, pulsatile tinnitus (pulse synchronous bruit), and nausea may also be reported. Almost all patients with IIH have papilledema. Neurologic abnormalities other than CN VI and CN VII dysfunction are not associated with IIH. As with early papilledema, early IIH manifests with normal visual acuity and enlarged blind spots on perimetry testing. Optic nerve function may deteriorate in long-standing, untreated, or severe cases.

The incidence of IIH peaks in the third decade of life. Ninety percent of affected patients are women, and 90% are obese. The disease is rare in prepubertal children (in whom obesity is less of a factor), men, and lean adults.

IIH has been associated with the use of exogenous substances such as vitamin A (>100,000 IU/day), tetracycline, minocycline, doxycycline, retinoic acid, and lithium, as well as the use of or withdrawal from corticosteroids. In studies that controlled for confounders such as reproductive age and obesity and in de-challenge and re-challenge cases, evidence of an association with IIH-type syndromes was strongest with use of cycline antibiotics (eg, doxycycline, tetracycline), retinoic acid, and vitamin A. Nevertheless, a clear correlation between IIH and these substances is lacking. Other potential causes of IIH are sleep apnea and anemia. Although hormonal changes occurring during pregnancy and hormonal abnormalities have been implicated in IIH, no endocrinologic dysfunction has been definitively linked with the disorder. In addition, the reason for the increase in ICP in IIH remains obscure.

Cerebral venous disorders that may lead to decreased venous outflow and thus increased ICP include cerebral venous thrombosis (resulting from trauma, childbirth, a hypercoagulable state, compression, or an ear or CNS infection), systemic or localized extracranial venous obstruction (eg, after radical neck dissection), a dural arteriovenous malformation, or systemic vasculitis. Risk factors for venous sinus thrombosis include hormonal contraceptive use, dehydration, and hereditary and acquired thrombotic disorders. The presence of any of these predisposing conditions, particularly in patients whose demographics are atypical for IIH, should raise concern for venous sinus thrombosis.

All patients with suspected IIH should undergo neuroimaging with MRI to rule out a mass, hydrocephalus, or meningeal lesion and MRV to assess for venous sinus occlusion (see Chapter 2, Fig 2-17). Characteristic (but not specific) MRI findings of intracranial hypertension include flattening of the globes, enlarged optic nerve sheaths, partially empty sella, and narrowing of the distal transverse venous sinus. A lumbar puncture should also be performed to confirm elevated ICP ( $\geq 25$  cm H<sub>2</sub>O in adults in the lateral decubitus position and  $\geq 28$  cm H<sub>2</sub>O in children) and to rule out infectious or inflammatory processes. Table 4-4 lists the diagnostic criteria of IIH for adults and children.

**Diagnostic Criteria for IIH Without Papilledema**

- In the absence of papilledema, a diagnosis of IIH can be made when the results of the neurologic examination are normal, CSF composition is normal, ICP is increased, MRI shows no mass or thrombosis, and there is unilateral or bilateral CN VI palsy.
- In the absence of papilledema or CN VI palsy, a diagnosis of IIH is suggested when the results of the neurologic examination are normal, ICP is increased, CSF composition is normal, and MRI shows no mass or thrombosis. In addition, there are at least 3 of the following neuroimaging findings:
  - empty sella
  - flattening of the posterior aspect of the globe
  - distention of the perioptic subarachnoid space with or without a tortuous optic nerve
  - transverse venous sinus stenosis

Information from Friedman DI, Liu GT, Digre KB. Revised diagnostic criteria for the pseudotumor cerebri syndrome in adults and children. *Neurology*. 2013;81(13):1159–1165.

**Table 4-4 Diagnostic Criteria for Idiopathic Intracranial Hypertension in Adults and Children**

Symptoms of increased ICP, such as headaches, neck pain, nausea, tinnitus, transient visual obscurations, or diplopia; no focal neurologic symptoms other than CN VI and CN VII dysfunction
Signs of isolated increased ICP, such as papilledema, unilateral or bilateral abducens nerve palsy, or divergence insufficiency
No evidence of ventriculomegaly or of mass, structural, or vascular lesions on brain imaging (ideally, MRI with contrast agent or CECT scan, associated with magnetic resonance venography or CT venography if presentation is atypical)
Documented elevated ICP in a properly performed lumbar puncture, typically a measurement $\geq 25$ cm H <sub>2</sub> O in adults in the lateral decubitus position ( $\geq 28$ cm H <sub>2</sub> O in children; $> 25$ cm H <sub>2</sub> O if the child is not sedated and is not obese)
Normal CSF composition

CECT=contrast-enhanced computed tomography; CN=cranial nerve; CSF=cerebrospinal fluid; CT=computed tomography; ICP=intracranial pressure; MRI=magnetic resonance imaging.

Adapted from Friedman DI, Liu GT, Digre KB. Revised diagnostic criteria for the pseudotumor cerebri syndrome in adults and children. *Neurology*. 2013;81(13):1159–1165.

The ophthalmologist plays a crucial role in the management of IIH. Careful long-term follow-up is essential to ensure that papilledema resolves and that vision remains intact. Regularly scheduled examinations should include testing of visual acuity and color vision and quantitative perimetry to document the level of optic nerve function. Photographs of the ONH are also essential during patient follow-up. Repeated OCT can document improvement of papilledema; however, OCT cannot be used in isolation to monitor the condition because secondary optic atrophy from untreated papilledema also results

in apparent improvement of the pRNFL thickness. The macular ganglion cell complex (GCC) may be helpful in differentiating a decrease in pRNFL thickness due to optic atrophy (in which the GCC will also show thinning) from resolution of papilledema (in which the GCC remains normal). The frequency of visual field testing depends on the severity of papilledema, the level of optic nerve dysfunction, and the patient's response to treatment.

Treatment for IIH depends on symptomatology and vision status. In some cases, the disease is self-limited. If headaches are mild or absent and optic nerve function is normal, no medical therapy may be required. However, untreated papilledema in IIH results in severe vision loss in 5%–10% of patients. Poor visual prognosis is also associated with male sex, African American race, morbid obesity, severe papilledema, and anemia. Patients with a fulminant course, with abnormal visual field test results at presentation, or with an RAPD (suggesting asymmetric damage to the optic nerve from severe papilledema) are also at high risk for permanent vision loss.

For patients with obesity, weight loss can be an effective treatment and is always recommended; even moderate weight loss can resolve the signs and symptoms of IIH. Referral to a nutritionist is helpful, and in some cases, bariatric surgery may be considered. For patients requiring medical therapy, acetazolamide is usually the first choice. In 2014, the Idiopathic Intracranial Hypertension Treatment Trial (IIHTT), a large randomized clinical study, showed that acetazolamide (1–4 g/day) in association with weight loss was effective in reducing ICP and improved papilledema in patients who had IIH and mild to moderate visual field defects (defined in the study as perimetric mean deviation between –2.0 and –7.0 dB). Topiramate may also be helpful for such patients, especially those experiencing chronic headaches; benefits include headache control, appetite suppression, and carbonic anhydrase inhibition. In patients who cannot tolerate acetazolamide or topiramate, furosemide may be an option.

Corticosteroids should be avoided. Although ICP can improve with their use, recurrence is common during corticosteroid taper, and these drugs may cause weight gain with subsequent worsening of IIH. However, a short course of high-dose IV corticosteroids may benefit patients with severe papilledema and vision loss (fulminant IIH). Repeated lumbar punctures are not recommended therapy for patients with IIH.

In cases of progressive vision loss despite maximally tolerated medical treatment, surgical therapy is recommended. In some patients with severe vision loss and papilledema, surgical intervention may be considered without waiting for definite evidence of progression. The options are optic nerve sheath fenestration (ONSF), a CSF diversion procedure (eg, lumboperitoneal or ventriculoperitoneal shunt), or venous sinus stenting.

ONSF is often preferred for patients with substantial loss of vision without prominent headache, because it directly protects the optic nerve and is associated with lower morbidity than shunting is. However, the overall risk of complications with ONSF is approximately 10%–15%, including a 1%–2% risk of vision loss from optic nerve injury, CRAO, or CRVO. ONSF does not significantly lower ICP and thus often does not reliably treat headache. In addition, bilateral ONSF may be required in order to reduce papilledema in the contralateral eye. The long-term success rate of ONSF remains unclear. Repeated ONSF procedures may be performed but are technically more difficult because of scarring.

Lumboperitoneal or ventriculoperitoneal shunt effectively lowers ICP, leading to improvement of headache, CN VI palsy (if present), and papilledema. Moreover, shunting entails no direct risk to the optic nerve. However, a shunt may become occluded or infected and may be dislocated, often requiring reoperation. Endovascular stenting of a narrow transverse venous sinus can also decrease CSF pressure and may alleviate headaches and papilledema.

Despite effective treatment of increased ICP and improvement of papilledema, many patients with IIH continue to have chronic headaches. The IIHTT reported no correlation between severity of these headaches and papilledema grade or CSF opening pressure, indicating that they are not directly related to the level of ICP. For medical management of these headaches, a neurologist should be consulted.

IIH also occurs in children. It appears to be a different disorder in prepubertal children, as there is no association with sex and more children without obesity are affected. Recent studies have shown that normal CSF opening pressure among healthy children is higher than previously believed and may be as high as 28 cm H<sub>2</sub>O. The treatment for pediatric IIH is similar to that for adult IIH.

Bidot S, Bruce BB. Update on the diagnosis and treatment of idiopathic intracranial hypertension. *Semin Neurol.* 2015;35(5):527–538.

Friedman DI, Liu GT, Digre KB. Revised diagnostic criteria for the pseudotumor cerebri syndrome in adults and children. *Neurology.* 2013;81(13):1159–1165.

Markey KA, Mollan SP, Jensen RH, Sinclair AJ. Understanding idiopathic intracranial hypertension: mechanisms, management, and future directions. *Lancet Neurol.* 2016;15(1):78–91.

Wall M, McDermott MP, Kieburtz KD, et al; NORDIC Idiopathic Intracranial Hypertension Study Group Writing Committee. Effect of acetazolamide on visual function in patients with idiopathic intracranial hypertension and mild visual loss: the Idiopathic Intracranial Hypertension Treatment Trial. *JAMA.* 2014;311(16):1641–1651.

### **Inflammatory disease**

The term *optic neuritis* refers to inflammation of the optic nerve from any cause. The neuritis may be isolated or related to either a neurologic inflammatory or infectious disorder or a local or systemic inflammatory disease. It may affect any portion of the nerve. When it affects the posterior portion of the optic nerve, the ONH appears normal at the time of vision loss (*retrobulbar optic neuritis*); when the inflammation involves the anterior portion of the nerve, the ONH appears edematous, a condition that is sometimes called *papillitis*. The ONH edema is usually hyperemic and diffuse.

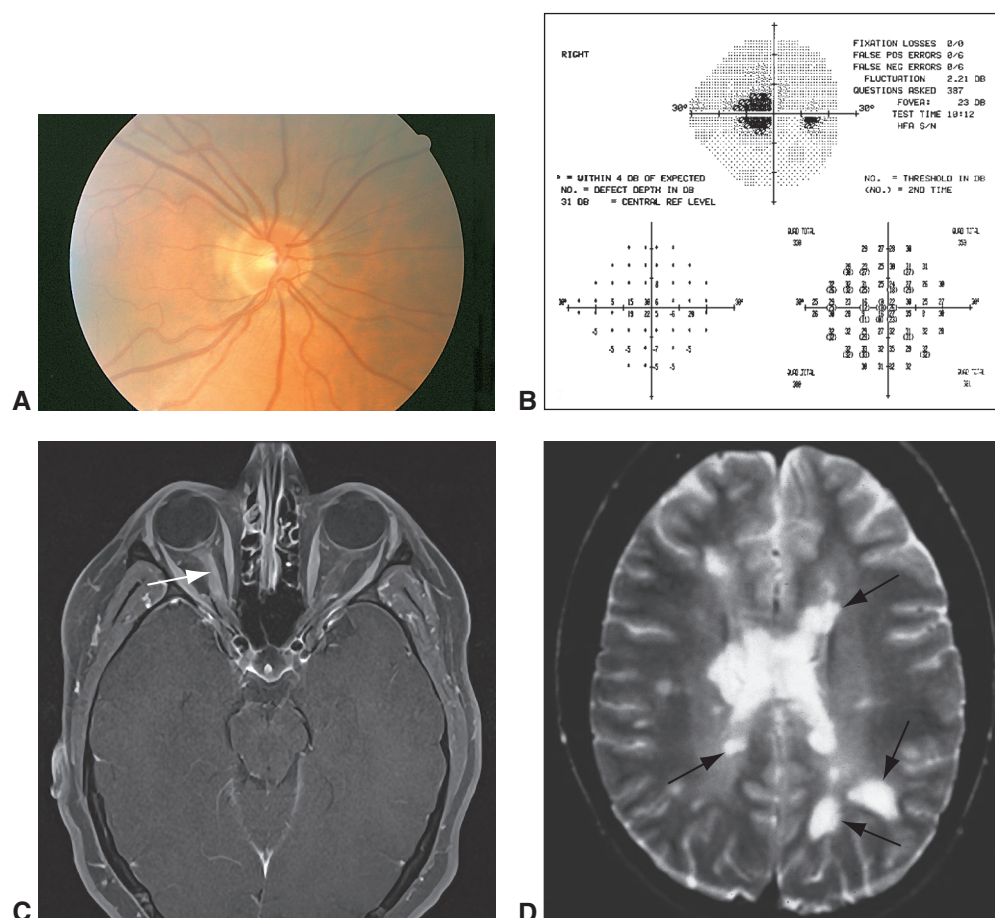
Papillitis is more common in postviral and infectious optic neuritis than in demyelinating optic neuritis, but considerable overlap exists. Children in particular manifest postviral optic neuritis and papillitis, which typically present with profound bilateral vision loss.

Beck RW, Trobe JD, Moke PS, et al; Optic Neuritis Study Group. High- and low-risk profiles for the development of multiple sclerosis within 10 years after optic neuritis: experience of the Optic Neuritis Treatment Trial. *Arch Ophthalmol.* 2003;121(7):944–949.

Optic Neuritis Study Group. Multiple sclerosis risk after optic neuritis: final Optic Neuritis Treatment Trial follow-up. *Arch Neurol.* 2008;65(6):727–732.



**Acute inflammatory demyelinating optic neuritis (idiopathic or associated with multiple sclerosis)** Acute inflammatory demyelinating optic neuritis typically occurs in young (mean age, 32 years) females (77% of cases) and presents as subacute monocular vision loss that develops over several days. Periorbital pain, particularly with eye movement, occurs in 92% of cases and often precedes vision loss. The retrobulbar form occurs in 65% of cases, and ONH edema in only one-third. An RAPD is also present when optic neuritis is unilateral or bilateral and asymmetric. Perimetry testing most often (48% of cases) shows a central depression or generalized reduction of sensitivity, but any pattern of visual field loss may appear (Fig 4-9). Dyschromatopsia, particularly for red-green, is nearly universal and is often out of proportion to the loss of visual acuity. In the vast majority of cases, optic neuritis shows spontaneous improvement within 1 month.



**Figure 4-9** Acute inflammatory demyelinating optic neuritis. **A**, Fundus photograph of the ONH with acute retrobulbar optic neuritis, showing typical appearance. **B**, Automated perimetry shows a central scotoma in the right eye. **C**, T1-weighted axial magnetic resonance imaging (MRI) scan of the orbits with fat suppression and gadolinium administration, showing enhancement of the right intraorbital optic nerve (arrow). **D**, T2-weighted axial MRI scan of the brain, demonstrating multiple white matter hyperintensities (arrows) consistent with multiple sclerosis. (Parts A and B courtesy of Steven A. Newman, MD; part C courtesy of Michael S. Lee, MD; part D courtesy of Anthony C. Arnold, MD.)

Most cases of acute inflammatory demyelinating optic neuritis are either idiopathic and isolated (eg, clinically isolated syndrome [CIS]) or are part of a demyelinating disorder (eg, multiple sclerosis [MS]). Atypical features that should prompt evaluation for alternative etiologies include older age, lack of pain, persistent pain or vision loss, significant swelling of the ONH with peripapillary hemorrhages or exudates, inflammatory ocular features (eg, uveitis, phlebitis, choroiditis, pars planitis), retinal changes, bilateral vision loss, involvement of other CNs, steroid-responsive optic neuropathy, and lack of any vision recovery by 1 month.

Additional hematologic, serologic, or other testing may be of value in atypical cases but need not be performed routinely. They include

- serum and CSF rapid plasma reagin and fluorescent treponemal antibody absorption testing for syphilis
- serum testing for *Bartonella* infection
- serum testing for Lyme disease (if endemic)
- chest x-ray or chest computed tomography (CT), gallium scan or full-body positron emission tomography (PET), or serum angiotensin-converting enzyme testing for sarcoidosis
- erythrocyte sedimentation rate (ESR) determination, antinuclear antibody testing, and anti-DNA antibody testing for systemic lupus erythematosus or vasculitis
- antineutrophil cytoplasmic antibodies (ANCA) for granulomatosis with polyangiitis
- serum aquaporin-4 immunoglobulin G (AQP4-IgG) antibody testing and spinal MRI for neuromyelitis optica spectrum disorder (NMOSD) (discussed later in this chapter)
- serum myelin oligodendrocyte glycoprotein immunoglobulin G (MOG-IgG) antibody testing for MOG-IgG-associated disorder (MOGAD) (discussed later in this chapter)
- genetic testing for Leber hereditary optic neuropathy (LHON)
- brain and orbit MRI with gadolinium contrast agent for compressive, infiltrative disorders
- lumbar puncture with cytology for a meningeal process

Several studies have clarified the natural history of acute inflammatory demyelinating optic neuritis. The Optic Neuritis Treatment Trial (ONTT) 10-year follow-up study reported that optic neuritis recurred in the affected or fellow eye in 35% of cases overall and in 48% of patients with conversion to MS. Most eyes with a recurrence had regained normal or almost-normal vision. After 15 years of follow-up in the ONTT, 92% of patients with optic neuritis had recovered visual acuity of 20/40 or better; 3% had final visual acuity of 20/200 or worse. Despite their seemingly excellent prognosis, patients with optic neuritis usually remain aware of visual deficits in the affected eye after recovery. Studies using measures of visual function other than Snellen visual acuity (ie, color vision, contrast sensitivity, motion detection, stereopsis, perimetry) showed residual abnormalities in up to 90% of patients with visual acuity of at least 20/30.

In the absence of a known diagnosis of MS, MRI of the brain should be performed in every case of optic neuritis. Evaluation for periventricular white-matter lesions consistent

with demyelination is the best way to assess the risk of future MS in patients with isolated optic neuritis and to guide subsequent decisions on the use of immunomodulation therapy (see the following section). The 15-year data from the ONTT found that the risk of MS was 25% in patients with no lesions on MRI versus 72% for patients with at least 1 lesion, with the highest rate of conversion within the first 5 years. Patients with normal MRI results and no conversion to MS by year 10 had only a 2% risk of conversion by year 15 (see Chapter 15). Among patients with normal baseline MRI results, a lower risk of future MS was associated with male sex, ONH swelling, and atypical features of optic neuritis (absence of pain, no light perception vision, peripapillary hemorrhages, and retinal exudates).

**TREATMENT OF ACUTE INFLAMMATORY DEMYELINATING OPTIC NEURITIS** The ONTT demonstrated that corticosteroid therapy for optic neuritis had no long-term beneficial effect on vision, although the use of IV methylprednisolone, 250 mg every 6 hours for 3 days, followed by oral prednisone, 1 mg/kg/day for 11 days (with a quick taper of 4 days), sped recovery by 1–2 weeks. Patients receiving oral prednisone alone experienced no improvement in vision, and their recurrence rate was twice as high as that of the other groups. Therefore, oral prednisone (1 mg/kg/day) is not recommended for the treatment of idiopathic acute inflammatory demyelinating optic neuritis.

Regarding clinically definite MS after the initial optic neuritis, the use of high-dose IV corticosteroids reduced the rate of development only in the subgroup of patients with MRI scans showing 2 or more white matter lesions. At 2 years, the risk of MS was 36% for the untreated group versus 16% for the treated group. However, by follow-up year 3 and thereafter, this “protective” effect was lost. More recent studies showed that megadose oral corticosteroids (1000 mg methylprednisolone per day, 1250 mg prednisone per day, or 200 mg dexamethasone per day) administered for 3 consecutive days hastened recovery and were not associated with a long-term risk of recurrent demyelinating events.

Given that the benefits of therapy and additional diagnostic evaluation for MS are uncertain, each patient with acute inflammatory demyelinating optic neuritis should be individually assessed. In those for whom a rapid return of vision is essential (eg, monocular patients or patients with an occupational need), IV methylprednisolone may be considered.

In patients with the relapsing-remitting form of MS, immunomodulatory therapy has proven benefits in reducing morbidity. In addition, studies have shown that these drugs can delay conversion to MS in patients with acute optic neuritis or other CIS associated with abnormalities on MRI (see Chapter 15 for a discussion of MS treatments).

Beck RW, Cleary PA, Anderson MM Jr, et al. A randomized, controlled trial of corticosteroids in the treatment of acute optic neuritis: the Optic Neuritis Study Group. *N Engl J Med*. 1992;326(9):581–588.

Eckstein C, Bhatti MT. Currently approved and emerging oral therapies in multiple sclerosis: an update for the ophthalmologist. *Surv Ophthalmol*. 2016;61(3):318–332.

Galetta SL, Villoslada P, Levin N, et al. Acute optic neuritis: unmet clinical needs and model for new therapies. *Neurol Neuroimmunol Neuroinflamm*. 2015;2(4):e135.

Le Page E, Veillard D, Laplaud DA, et al. Oral versus intravenous high-dose methylprednisolone for treatment of relapses in patients with multiple sclerosis

(COPOUSEP): a randomized, controlled, double-blind, non-inferiority trial. *Lancet*. 2015;386(9997):974–981.

Optic Neuritis Study Group. Multiple sclerosis risk after optic neuritis: final Optic Neuritis Treatment Trial follow-up. *Arch Neurol*. 2008;65(6):727–732.

Optic Neuritis Study Group. Visual function 15 years after optic neuritis: a final follow-up report from the Optic Neuritis Treatment Trial. *Ophthalmology*. 2008;115(6):1079–1082.e5.

**Chronic relapsing inflammatory optic neuropathy** Chronic relapsing inflammatory optic neuropathy (CRION) is an isolated inflammatory optic neuritis that is very steroid responsive and steroid dependent. It usually occurs chronically over months or years and requires long-term corticosteroid and/or immunosuppressive therapy. CRION is not associated with MS. In cases of suspected CRION, other inflammatory disorders such as sarcoidosis and MOGAD must be ruled out.

Petzold A, Plant GT. Chronic relapsing inflammatory optic neuropathy: a systematic review of 122 cases reported. *J Neurol*. 2014;261(1):17–26.

**Neuromyelitis optica and neuromyelitis optica spectrum disorder** Optic neuritis and acute transverse myelitis characterize neuromyelitis optica (NMO), also known as Devic disease. NMOSD encompasses a first attack or limited form of optic neuritis or transverse myelitis as well as typical clinical NMO associated with cerebral, diencephalic, or brain-stem lesions. Table 4-5 presents a set of diagnostic criteria for NMOSD developed by an international group of experts. These criteria have 99% sensitivity and 90% specificity. The serum AQP4-IgG test alone, which is a cell-based assay included in the expert guidance, has 76% sensitivity and 99% specificity.

Although many patients with NMOSD experience transverse myelitis and optic neuritis within weeks to months of each other, the episodes may be separated by several years. The episodes of vision loss tend to recur, and severe visual impairment (<20/200) is common in at least 1 eye. Testing for AQP4-IgG should be considered for patients with optic neuritis and the following:

- profound vision loss
- irreversible vision loss (lack of vision improvement by 1 month)
- bilateral vision loss
- recurrent vision loss
- longitudinally extensive enhancement of the optic nerve on MRI
- normal brain MRI study or atypical brain lesions not consistent with MS

Vision and neurologic prognoses in NMO are poorer than in MS. The mainstay of treatment during the acute period remains high-dose IV corticosteroids. For poorly responsive NMO, administration of plasma exchange (PLEX) or IVIG, in addition to high-dose IV methylprednisolone, may be considered. Use of other immunosuppressive drugs such as azathioprine or rituximab can reduce the risk of relapse. At the time this chapter was written, the US Food and Drug Administration (FDA) had approved eculizumab, a recombinant humanized monoclonal antibody against the complement protein C5, and inebilizumab, a B-cell-depleting anti-CD19 antibody, for NMOSD.

**Table 4-5 Criteria for the Diagnosis of NMOSD in Adult Patients**

Core Clinical Characteristics	Diagnostic Criteria for NMOSD With AQP4-IgG	Diagnostic Criteria for NMOSD Without AQP4-IgG or NMOSD With Unknown AQP4-IgG Status	Additional MRI Requirements for NMOSD Without AQP4-IgG and NMOSD With Unknown AQP4-IgG Status
1. Optic neuritis	1. At least 1 core clinical characteristic	1. At least 2 core clinical characteristics	1. Acute optic neuritis: a brain MRI showing normal findings (or only nonspecific white matter lesions) or an optic nerve MRI with a T2-weighted hyperintense lesion or a T1-weighted gadolinium-enhanced lesion extending over more than one-half of the optic nerve length or involving the optic chiasm
2. Acute TM	2. Positive test result for AQP4-IgG	resulting from 1 or more clinical attacks and meeting all of the following requirements:	
3. Area postrema syndrome: episode of otherwise-unexplained hiccups or nausea and vomiting	3. Exclusion of alternative diagnoses	a. At least 1 core clinical characteristic that is optic neuritis, acute TM with LETM lesions, or area postrema syndrome	2. Acute TM: MRI showing an associated intramedullary lesion extending over $\geq 3$ contiguous segments (LETM) or alternatively in patients with a history compatible with acute TM, $\geq 3$ contiguous segments of focal spinal cord atrophy
4. Acute brainstem syndrome		b. Dissemination in space (2 or more different core clinical characteristics)	3. Area postrema syndrome: associated dorsal medulla/area postrema lesions
5. Symptomatic narcolepsy or acute diencephalic clinical syndrome with NMOSD-typical diencephalic lesions on MRI		c. Fulfillment of additional MRI requirements, as applicable	4. Acute brainstem syndrome: associated periependymal brainstem lesions
6. Symptomatic cerebral syndrome with typical NMOSD brain lesions		2. Negative test result for AQP4-IgG	
		3. Exclusion of alternative diagnoses	

AQP4=aquaporin-4; IgG=immunoglobulin G; LETM=longitudinally extensive transverse myelitis; MRI=magnetic resonance imaging; NMOSD=neuromyelitis optica spectrum disorder; TM=transverse myelitis.

Adapted with permission from Wingerchuk DM, Banwell B, Bennett JL, et al. International consensus diagnostic criteria for neuromyelitis optica spectrum disorders. *Neurology*. 2015;85(2):177–189.

Papais-Alvarenga RM, Carellos SC, Alvarenga MP, Holander C, Bichara RP, Thuler LC.

Clinical course of optic neuritis in patients with relapsing neuromyelitis optica. *Arch Ophthalmol*. 2008;126(1):12–16.

Pittock SJ, Berthele A, Fujihara K, et al. Eculizumab in aquaporin-4-positive neuromyelitis optica spectrum disorder. *N Engl J Med*. 2019;381(7):614–625.

Wingerchuk DM, Banwell B, Bennett JL, et al; International Panel for NMO Diagnosis.

International consensus diagnostic criteria for neuromyelitis optica spectrum disorders. *Neurology*. 2015;85(2):177–189.

**Myelin oligodendrocyte glycoprotein immunoglobulin G-associated disorder** MOGAD is associated with CNS demyelinating events such as recurrent optic neuritis, myelitis,



and encephalitis (including acute disseminated encephalomyelitis [ADEM]). Optic neuritis is the most common sign of MOGAD, especially in adults. Compared with typical MS–optic neuritis, MOG-IgG–optic neuritis is more likely to be bilateral, recurrent, and associated with ONH edema. In addition, perineural enhancement is often observed on MRI (enhancement extending to the sheath and surrounding periorbital fat). Periventricular demyelinating lesions are rare in patients with MOG-IgG–optic neuritis.

Although vision loss at presentation is often severe with isolated MOG-IgG–optic neuritis, the visual prognosis is generally good, and some patients recover spontaneously. Because of the good recovery, visual outcomes are more similar to those of MS–optic neuritis than NMO–optic neuritis. Approximately 50% of patients have a monophasic course, whereas 50% have a chronic, relapsing course. Some cases of isolated MOG-IgG–optic neuritis are steroid dependent and follow a CRION phenotype. Initial treatment is similar to that for MS– and NMO–optic neuritis (ie, IV corticosteroids and possibly PLEX or IVIG if no response). Long-term treatment with medications such as rituximab, mycophenolate mofetil, or periodic IVIG infusions may lower the risk of recurrence and disability in patients with relapsing disease.

Ophthalmologists should consider testing for the presence of MOG-IgG in the following clinical scenarios:

- prominent or severe ONH swelling
- bilateral optic neuritis
- recurrent optic neuritis
- longitudinally extensive or perineural optic nerve enhancement on MRI
- history of acute disseminated encephalomyelitis

Table 4-6 reviews the clinical and radiologic features of MS–, NMO–, and MOG-IgG–optic neuritis.

Chen JJ, Flanagan EP, Jitrapaikulsan J, et al. Myelin oligodendrocyte glycoprotein antibody-positive optic neuritis: clinical characteristics, radiologic clues, and outcomes. *Am J Ophthalmol.* 2018;195:8–15.

Jurynczyk M, Messina S, Woodhall MR, et al. Clinical presentation and prognosis in MOG-antibody disease: a UK study. *Brain.* 2017;140(12):3128–3138.

**Glial fibrillary acidic protein astrocytopathy optic neuritis** Autoimmune glial fibrillary acidic protein (GFAP) astrocytopathy is a recently characterized condition that presents as a meningoencephalitis, with patients experiencing altered mental status, involuntary movements, seizures, ataxia, and vision loss. The optic neuritis in this condition is variable but generally involves ONH swelling with or without elevated ICP. Isolated optic neuritis has not been reported in this condition. Treatment usually consists of immunomodulation with corticosteroids as well as PLEX and IVIG. GFAP antibodies are commercially available.

**Neuroretinitis** This inflammatory disorder is characterized by acute loss of vision associated with ONH edema and a star pattern of exudates in the macula (Fig 4-10). Mild vitritis and choroidal lesions may also occur. The diffuse ONH edema spreads through the outer plexiform layer along the papillomacular bundle and around the fovea. As

**Table 4-6 Comparison of MS–, AQP4-IgG–, and MOG-IgG–Optic Neuritis**

Characteristics	MS	AQP4-IgG–Positive	MOG-IgG–Positive
Age (years)	20s	40s	30s (and children)
Sex	Female > Male	Female >> Male	Female ≈ Male
Optic neuritis			
Eye pain	Very frequent	Frequent	Very frequent
Bilateral simultaneous visual loss	Sometimes	Frequent	Frequent
Visual acuity (at nadir)	Less severe	Severe	Severe
Recurrent visual loss	Sometimes	Frequent	Frequent
Rapid recovery	Sometimes	Rare	Frequent
Steroid dependence	Rare	Rare	Frequent
Visual outcome	Good	Poor	Good
Other characteristics			
ADEM	Rare	Rare	Frequent
Area postrema	Rare	Frequent	Rare
LETM	Rare	Very frequent	Frequent
Enhancement of the optic nerve on MRI	Typically short	Long and may involve the chiasm	Long and often includes perineural enhancement
Findings on brain MRI	Periventricular white matter lesions	Hemispheric cerebral white matter, periependymal diencephalon, dorsal medulla lesions	Deep gray matter, diffuse brainstem, multifocal white matter lesions
CSF oligoclonal bands	Very frequent	Rare	Rare

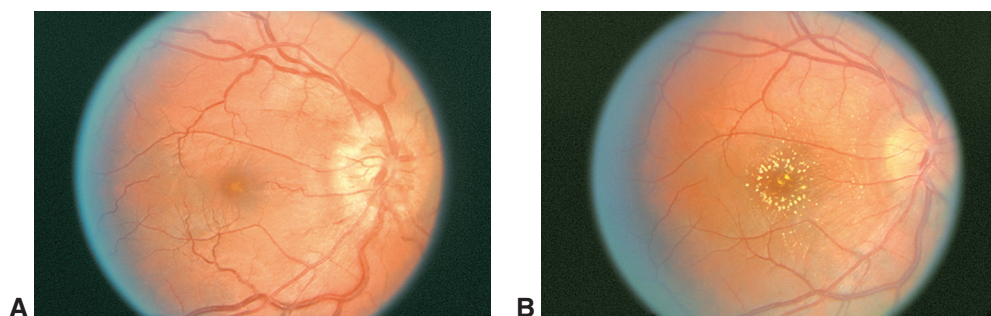
ADEM = acute disseminated encephalomyelitis; AQP4 = aquaporin 4; CSF = cerebrospinal fluid; IgG = immunoglobulin G; LETM = longitudinally extensive transverse myelitis; MOG = myelin oligodendrocyte glycoprotein; MRI = magnetic resonance imaging; MS = multiple sclerosis.

Adapted from Chen JJ, Bhatti MT. Clinical phenotype, radiological features, and treatment of myelin oligodendrocyte glycoprotein-immunoglobulin G (MOG-IgG) optic neuritis. *Curr Opin Neurol*. 2020;33(1):48.

the fluid resorbs, the lipid precipitates in a characteristic radial pattern in the Henle layer. The macular star can appear at initial presentation or several days later. Macular OCT can sometimes detect subretinal fluid before development of the macular star and may provide a useful clue to the diagnosis. Recognizing fluid or lipid exudates in the papillomacular bundle is crucial for establishing the correct diagnosis and differentiating neuroretinitis from optic neuritis, as patients with neuroretinitis do not have an increased risk of MS.

Neuroretinitis is usually an infectious or postviral autoimmune process, frequently associated with elevated antibody IgM titers for *Bartonella quintana* or *Bartonella henselae*—the most common cause of neuroretinitis and cat-scratch disease. Other potential infectious and inflammatory causes of neuroretinitis include Lyme disease, sarcoidosis, syphilis, toxoplasmosis, tuberculosis, and viruses. See BCSC Section 9, *Uveitis and Ocular Inflammation*, for a complete discussion of ocular bartonellosis and neuroretinitis, as well as other possible causes.

No definitive evidence has shown that corticosteroids and antibiotics have a beneficial effect on visual outcome in neuroretinitis.



**Figure 4-10** Neuroretinitis. A 23-year-old man with a 2-day history of blurred vision on the right (visual acuity: 20/40 OD, 20/20 OS). **A**, The ONH on the right side is elevated and hyperemic, with obscuration of the nerve fiber layer. **B**, Five weeks after onset, ophthalmoscopic examination shows a macular star, and the ONH edema is now less prominent. (Courtesy of Steven A. Newman, MD.)

Chi SL, Stinnett S, Eggenberger E, et al. Clinical characteristics in 53 patients with cat scratch optic neuropathy. *Ophthalmology*. 2012;119(1):183–187.

**Optic perineuritis** Optic perineuritis is inflammation of the optic nerve sheath. Similarities between optic perineuritis and optic neuritis include acute, painful vision loss and greater frequency in females. However, patients with optic perineuritis are generally older (36% are older than 50 years), their vision loss is often milder (central vision is relatively spared but with peripheral vision loss) and progresses over several weeks, and their pain persists until treatment is initiated. Orbital MRI shows enhancement of the optic nerve (dural) sheath rather than enhancement of the optic nerve itself. Although the neuroimaging results can appear similar to those of optic nerve sheath meningioma, pain helps differentiate the 2 conditions.

Distinguishing optic perineuritis from optic neuritis is important with respect to not only treatment but also potential development of MS, as optic perineuritis is not associated with this condition. Although most cases of optic perineuritis are idiopathic, patients with the condition should undergo a thorough evaluation to rule out the following systemic disorders:

- syphilis
- sarcoidosis
- granulomatosis with polyangiitis
- IgG4-related disease

MOGAD-associated optic perineuritis responds immediately and dramatically to corticosteroid treatment, but patient relapse is common with short courses of treatment. Without treatment, patients experience progressive loss of vision.

Purvin V, Kawasaki A, Jacobson DM. Optic perineuritis: clinical and radiographic features. *Arch Ophthalmol*. 2001;119(9):1299–1306.

### Vascular conditions

Depending on which segment of the optic nerve is affected, ischemic optic neuropathy is classified as either anterior ischemic optic neuropathy (AION) or posterior ischemic optic neuropathy (PION). AION accounts for 90% of all ischemic optic neuropathies.

**Anterior ischemic optic neuropathy** AION is the most common acute optic neuropathy in patients older than 50 years. Patients with AION experience painless monocular vision loss that develops over hours to days. Visual acuity may be relatively preserved, but visual field loss always occurs. Altitudinal and other variants of arcuate defects are typical, although any defect may occur. An RAPD is present unless the optic neuropathy becomes bilateral. By definition, there is always ONH edema at onset, which may precede the vision loss.

AION is subclassified as either *arteritic anterior ischemic optic neuropathy* (AAION), in which case it is associated with vasculitis, most commonly giant cell arteritis (GCA), or *nonarteritic anterior ischemic optic neuropathy* (NAION) (Table 4-7). The most important initial step in evaluating AION is to distinguish between these 2 subtypes.

**ARTERITIC ANTERIOR ISCHEMIC OPTIC NEUROPATHY** AAION is less frequent (5%–10% of AION cases) than NAION and occurs in patients older than 50 years (mean age, 70 years). It is caused by inflammatory and thrombotic occlusion of the short posterior ciliary arteries. Systemic signs and symptoms of GCA are usually present, including headache, scalp tenderness, jaw claudication, malaise, anorexia, weight loss, and fever. However, up to 25% of patients with vision loss from GCA have no systemic symptoms (so-called occult GCA). Although ESR and C-reactive protein (CRP) levels are usually elevated in GCA, one or both of these test results may be normal, at least initially. Transient vision loss or transient diplopia preceding AION is very suggestive of GCA.

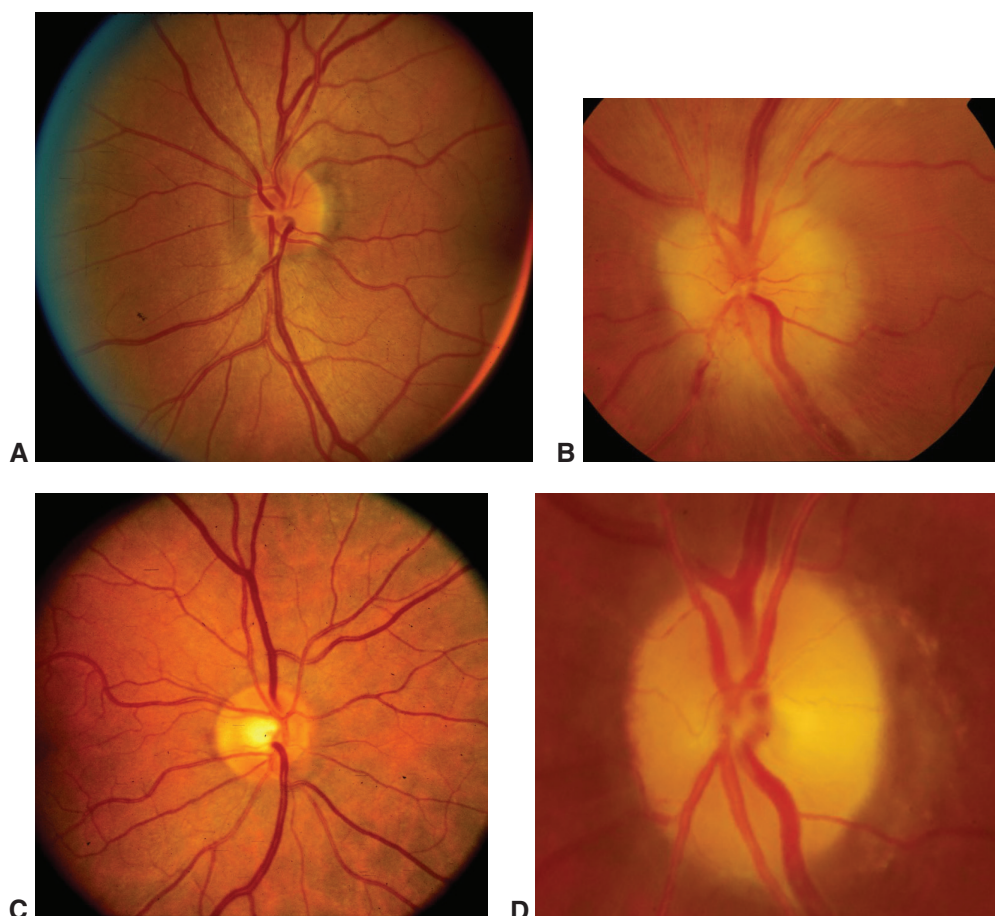
**Table 4-7 Arteritic Versus Nonarteritic Anterior Ischemic Optic Neuropathy**

Characteristic	Arteritic Features	Nonarteritic Features
Mean age	70 years	60 years
Sex	Affects more females than males	Affects males and females equally
Associated symptoms	Headache, scalp tenderness, jaw claudication, transient vision loss	Usually none
Visual acuity	<20/200 in >60% of cases	>20/200 in >60% of cases
ONH/fundus findings	Pallid ONH edema common Cup normal or large Cotton-wool spots Choroidal or retinal ischemia	Hyperemic ONH edema Cup small
ESR	Elevated	Normal
CRP	Elevated	Normal
Platelet count	Elevated or normal	Normal
Fluorescein angiography findings	Delayed ONH and choroidal filling Condition rarely improves	Delayed ONH filling 31% of cases improve
Natural history	Untreated fellow eye involved, 54%–95% within 1–2 weeks	Fellow eye involved, 15% at 5 years
Treatment	Systemic steroids	None proven

CRP = C-reactive protein; ESR = erythrocyte sedimentation rate; ONH = optic nerve head.

Vision loss is typically severe (visual acuity is  $<20/200$  in  $>60\%$  of patients), and a lack of light perception vision should prompt an aggressive evaluation for GCA. Ophthalmoscopic clues to a diagnosis of AAION over NAION include the following:

- chalky-white ONH edema (in NAION, the ONH is often hyperemic) (Fig 4-11)
- cotton-wool spots away from the ONH, which indicate concurrent retinal ischemia (cotton-wool spots on or adjacent to the ONH can be present in NAION)
- delayed choroidal filling on fluorescein angiographic studies (normally, the choroid fills completely within 3–5 seconds, before the retinal arteries do) (see Chapter 3, Fig 3-10)
- normal or large cup in the fellow eye (in NAION, a small cup–disc ratio is common)



**Figure 4-11** ONH appearance in nonarteritic anterior ischemic optic neuropathy (NAION) and arteritic anterior ischemic optic neuropathy (AAION). **A**, The healthy eye demonstrates a characteristic crowded appearance, which has been called “disc at risk.” **B**, ONH appearance in NAION. Edema is segmental, with mild superimposed pallor and flame hemorrhages. **C**, The healthy eye demonstrates a normal cup–disc ratio. Lack of a disc at risk should suggest AAION. **D**, ONH appearance in AAION. Pallor is more pronounced. (Courtesy of Gregory Van Stavern, MD.)



When AAION due to GCA is suspected, immediate initiation of high-dose corticosteroid therapy is crucial. Adjunctive daily aspirin can also be prescribed. A temporal artery biopsy should be done to confirm the diagnosis as soon as possible, but it can be delayed for 1–2 weeks without compromising test results. IV methylprednisolone (1 g/day for the first 3–5 days) is usually recommended. Thereafter, oral prednisone (1 mg/kg/day) may be used (up to 100 mg/day, tapered slowly over 12 months or more, depending on response). Treatment should never be delayed while waiting for temporal artery biopsy because second-eye involvement can occur.

The primary goal of AAION therapy (apart from avoiding systemic vascular complications) is to prevent contralateral vision loss. Untreated, the fellow eye becomes involved in up to 95% of cases within 1–2 weeks. Although the initially affected eye may improve somewhat, the patient's vision does not fully recover. The risk of recurrent or contralateral optic nerve involvement during corticosteroid withdrawal has been reported at 7%. Therefore, tapering must be done slowly and carefully. Recurrent symptoms or elevation of ESR or CRP level should prompt reevaluation for disease activity.

For a discussion of the systemic effects, diagnostic evaluation, and treatment of GCA, see Chapter 15.

Dasgupta B; Giant Cell Arteritis Guideline Development Group. Concise guidance: diagnosis and management of giant cell arteritis. *Clin Med (Lond)*. 2010;10(4):381–386.

Hayreh SS, Bioussé V. Treatment of acute visual loss in giant cell arteritis: should we prescribe high-dose intravenous steroids or just oral steroids? *J Neuroophthalmol*. 2012;32(3):278–287.

Lee AG, Brazis PW. Giant cell arteritis. *Focal Points: Clinical Modules for Ophthalmologists*. American Academy of Ophthalmology; 2005, module 6.

Parikh M, Miller NR, Lee AG, et al. Prevalence of a normal C-reactive protein with an elevated erythrocyte sedimentation rate in biopsy-proven giant cell arteritis. *Ophthalmology*. 2006;113(10):1842–1855.

**NONARTERITIC ANTERIOR ISCHEMIC OPTIC NEUROPATHY** Compared with AAION, NAION is more common (accounting for 90%–95% of AION cases) and occurs in a relatively younger age group (mean age, 60 years), although it can occur at any age. The annual incidence is approximately 3.6–10.2 per 100,000. NAION is presumably related to compromised ONH microcirculation in eyes with structural “crowding” of the ONH. Histologic studies have shown that the area of infarction is located within the scleral canal alone, a finding supporting a potential local compartment syndrome. The initial course may remain *static*, in which case vision loss is stable from onset, or it may become *progressive*, which involves either episodic, stepwise decrements or a steady decline of vision over a few days to weeks before eventual stabilization. The progressive form occurs in approximately 12% of NAION cases and may be explained by the compartment syndrome theory. NAION is typically not associated with any systemic symptoms.

Vision loss is usually less severe in NAION (visual acuity >20/200 in more than 60% of cases) than in AAION. Visual acuity and color vision may be normal if fixation is spared but an RAPD is present. The most common pattern of visual field loss is an altitudinal defect, but any pattern may be observed. The ONH edema in NAION may be diffuse or segmental and is usually initially hyperemic (see Fig 4-11). The ONH in the contralateral

eye is typically small in diameter and demonstrates a small or absent physiologic cup (“disc at risk”).

Within 6–8 weeks of NAION onset, the ONH usually becomes atrophic; persistence of edema past this point may suggest an alternative diagnosis. The 5-year risk of contralateral involvement is 15%. Occurrence in the second eye produces the clinical appearance of *pseudo-Foster Kennedy syndrome*, in which the previously affected ONH is atrophic and the currently involved ONH is edematous. By contrast, in true Foster Kennedy syndrome, which is secondary to an intracranial mass, one ONH is atrophic because of chronic compression by the mass, whereas the other ONH is edematous because of elevated ICP.

NAION is associated with the following risk factors:

- structural crowding of the ONH (also known as disc at risk)
- diabetes mellitus (particularly in young patients)
- systemic hypertension
- hyperlipidemia
- obstructive sleep apnea

Neither carotid occlusive disease nor a cardiac source of emboli is a proven risk factor for NAION. Hypercoagulable disorders rarely cause the disorder and should be investigated in young patients and patients with known thrombophilia or a family history of thrombosis. Nocturnal hypotension has been suggested as a precipitating factor, but this remains controversial. An association with phosphodiesterase 5 (PDE5)–inhibitor drugs used primarily to treat erectile dysfunction has been suggested but is debated. Amiodarone may trigger an anterior optic neuropathy with ONH edema similar to NAION.

NAION must be differentiated from optic neuritis, especially in younger patients (Table 4-8). In unclear cases, contrast-enhanced MRI of the orbits (with fat suppression) can facilitate the differentiation. The affected optic nerve appears normal in NAION (95% of cases) but is enhanced in optic neuritis (90% of cases).

NAION generally remains stable after visual function has reached its low point, but the Ischemic Optic Neuropathy Decompression Trial (IONDT) showed that 43% of patients with a visual acuity worse than 20/64 at presentation regained at least 3 lines on the Snellen eye chart within 6 months. Recurrent episodes of vision loss in the same eye 3 months after

**Table 4-8 NAION Versus Optic Neuritis: Typical Features**

	NAION	Optic Neuritis
Age at onset	>50 years	<40 years
Associated pain	Unusual	With eye movement, 92%
Pupil	+ RAPD	+ RAPD
Visual field defect	Altitudinal	Central
ONH findings	Edema, 100%	Edema, 33%
Retinal hemorrhage	Common	Unusual
Fluorescein angiography findings	Delayed ONH filling	No delayed ONH filling
MRI findings	No optic nerve enhancement	Optic nerve enhancement

MRI = magnetic resonance imaging; NAION = nonarteritic anterior ischemic optic neuropathy; ONH = optic nerve head; RAPD = relative afferent pupillary defect.

onset are unusual in NAION (up to 6.4%) and should trigger a more extensive evaluation for an underlying systemic disorder or an alternative cause of the optic neuropathy.

There is no proven therapy for NAION. The IONDT showed that ONSF had no benefit in NAION. Treatment with steroids or neuroprotective drugs is not supported by any high-quality clinical studies.

There is also no proven prophylaxis for the fellow eye. Although aspirin is known to reduce the risk of secondary stroke, its role in reducing the incidence of fellow eye involvement after the initial episode remains unproven. Because at least 60% of patients with NAION have systemic vascular risk factors, the clinician should look for and treat these factors when present. Patients may also have increased risk of cerebral ischemic stroke and should be referred for risk factor modification and management. Although some studies recommend screening patients with NAION for sleep apnea, no high-quality evidence shows that treating sleep apnea prevents second eye involvement.

Arnold AC. Pathogenesis of nonarteritic anterior ischemic optic neuropathy. *J Neuroophthalmol*. 2003;23(2):157–163.

Campbell UB, Walker AM, Gaffney M, et al. Acute nonarteritic anterior ischemic optic neuropathy and exposure to phosphodiesterase type 5 inhibitors. *J Sex Med*. 2015;12(1):139–151.

Hayreh SS, Zimmerman MB. Non-arteritic anterior ischemic optic neuropathy: role of systemic corticosteroid therapy. *Graefes Arch Clin Exp Ophthalmol*. 2008;246(7):1029–1046.

Lee YC, Wang JH, Huang TL, Tsai RK. Increased risk of stroke in patients with nonarteritic anterior ischemic optic neuropathy: a nationwide retrospective cohort study. *Am J Ophthalmol*. 2016;170:183–189.

Newman NJ, Scherer R, Langenberg P, et al; Ischemic Optic Neuropathy Decompression Trial Research Group. The fellow eye in NAION: report from the Ischemic Optic Neuropathy Decompression Trial follow-up study. *Am J Ophthalmol*. 2002;134(3):317–328.

**Posterior ischemic optic neuropathy** PION causes acute ischemic damage to the retrobulbar portion of the optic nerve. This rare disease is characterized by abrupt, often severe vision loss, an RAPD, and initially normal-appearing ONHs. PION is rare and is a diagnosis of exclusion. It occurs in 3 distinct scenarios: (1) perioperative situations (most often during spine, cardiac, and head or neck procedures); (2) arteritic disorders (especially GCA); and, in rare instances, (3) nonarteritic or idiopathic conditions (with risk factors and a clinical course similar to those of NAION).

Sadda SR, Nee M, Miller NR, Bioussé V, Newman NJ, Kouzis A. Clinical spectrum of posterior ischemic optic neuropathy. *Am J Ophthalmol*. 2001;132(5):743–750.

**Perioperative ischemic optic neuropathy** Both AION and PION may be precipitated by various nonocular surgical procedures, often with profound and irreversible bilateral vision loss. The 2 procedures most commonly associated with ischemic optic neuropathies are coronary artery bypass grafting and prolonged spinal-fusion surgery with the patient in the prone position. Overall, AION occurs more frequently with cardiac surgery, whereas PION occurs more often with spine surgery. However, a wide variety of procedures have been associated anecdotally with PION, including total hip arthroplasty and liposuction. Although this complication occurs in only 0.3% of nonophthalmic surgical

procedures, perioperative AION and PION have undergone increased scrutiny because of the growing number of reports and the potential medicolegal implications. Lack of understanding about the causes of PION and the likelihood that multiple factors contribute to the incidence of these neuropathies have complicated their management.

Lee LA, Roth S, Posner KL, et al. The American Society of Anesthesiologists Postoperative Visual Loss Registry: analysis of 93 spine surgery cases with postoperative visual loss. *Anesthesiology*. 2006;105(4):652–659.

Lee MS, Armbrust KR. Perioperative visual loss in ocular and nonocular surgery. *Focal Points: Clinical Modules for Ophthalmologists*. American Academy of Ophthalmology; 2012, module 10.

**Diabetic papillopathy** Diabetic papillopathy, which is related to NAION, can occur in patients with either type 1 or type 2 diabetes mellitus. Affected patients may have no symptoms or may report nonspecific symptoms such as blurred vision or “distortion” without pain. Evidence of optic nerve dysfunction (found via testing of visual acuity and visual field and for an RAPD) is typically absent. Although the optic nerve reveals hyperemic edema, 50% of patients show marked dilation of the ONH surface microvasculature (Fig 4-12) that appears similar to neovascularization of the disc (NVD). However, in NVD the vessels proliferate into the vitreous cavity and leak fluorescein in angiographic studies. Because diabetic retinopathy is not universal among patients with diabetic papillopathy (occurring in 63%–80% of patients with the condition), the absence of retinopathy does not preclude a diagnosis of diabetic papillopathy.

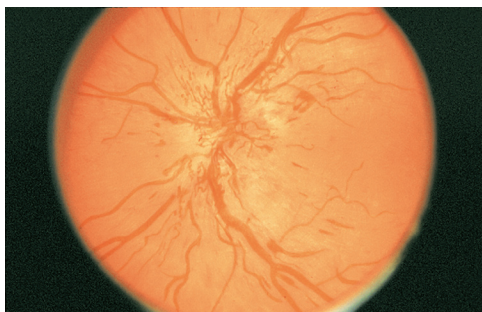In general, the dilated, radially oriented vessels and ONH edema in diabetic papillopathy resolve slowly over 2–10 months. In rare cases, the disorder progresses to vision loss (ie, AION). The pathophysiology is unclear but is thought to be mild, reversible ischemia. Thus, the distinction of diabetic papillopathy as an entity unique from AION remains controversial; the 2 disorders may instead represent a spectrum. There is no proven therapy for diabetic papillopathy. Diabetes mellitus is discussed in BCSC Section 1, *Update on General Medicine*; associated ocular disorders are discussed in Section 12, *Retina and Vitreous*.

Regillo CD, Brown GC, Savino PJ, et al. Diabetic papillopathy: patient characteristics and fundus findings. *Arch Ophthalmol*. 1995;113(7):889–895.

### **Radiation optic neuropathy**

See the Radiation Therapy section in Chapter 15 for discussion of this condition.

**Figure 4-12** Fundus photograph of an ONH in diabetic papillopathy shows edema with prominent surface telangiectasia. (Reprinted from Arnold AC. *Differential diagnosis of optic disc edema*. Focal Points: Clinical Modules for Ophthalmologists. American Academy of Ophthalmology; 1999, module 2.)



### ***Papillophlebitis***

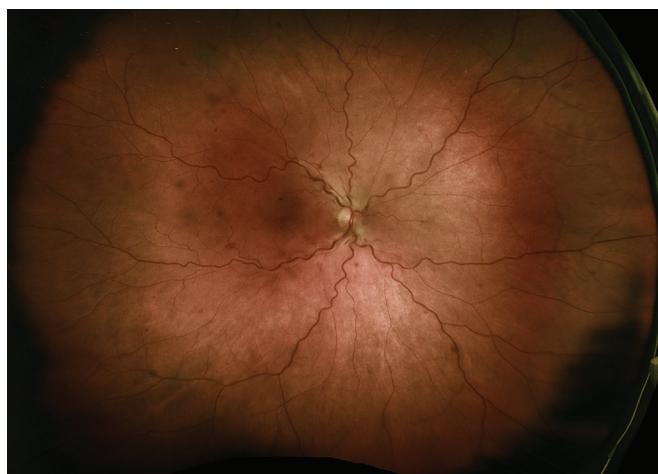Papillophlebitis, which represents a subset of CRVO, usually presents with vague blurring of vision or even transient visual obscurations. Visual acuity is typically normal or only mildly diminished. The pupils and color vision are normal, and visual field testing shows blind-spot enlargement. Fundus examination shows marked retinal venous engorgement associated with hyperemic ONH edema (Fig 4-13). Retinal hemorrhages extending to the equatorial region are common. Fluorescein angiographic studies typically show retinal venous staining and leakage associated with circulatory slowing, without the regions of capillary occlusion observed in ischemic CRVO. An evaluation for hypercoagulable disorders should be considered.

The condition usually resolves spontaneously over 6–12 months, with either no vision loss or only mild impairment related to incompletely resolved maculopathy. For further discussion of CRVO, see BCSC Section 12, *Retina and Vitreous*.

### ***Compressive and infiltrative lesions***

Patients with intraorbital or intracranial compressive lesions typically present with slowly progressive vision loss, an RAPD, and monocular visual field loss. There may be associated signs of orbital disease such as eyelid edema, eyelid retraction, lid lag, proptosis, ptosis, or ophthalmoplegia. The ONH may be normal or mildly atrophic at presentation, although anterior orbital lesions may cause ONH edema. Optociliary shunt vessels (discussed in the next section) or choroidal folds may also be present.

The lesions that most commonly produce optic neuropathy include optic nerve sheath meningioma (ONSM) and optic pathway glioma (OPG). Cavernous hemangioma, though common in the orbit, only occasionally produces a compressive optic neuropathy. Infiltration (through inflammatory, infectious, or neoplastic mechanisms) of the optic nerve is usually a retrobulbar process, but anterior involvement may present with ONH edema.



**Figure 4-13** Papillophlebitis. ONH edema in a 28-year-old woman with engorgement and tortuosity of the retinal venous system. Visual acuity was 20/30. (Courtesy of Gregory Van Stavern, MD.)



The ONH may simply be edematous or may display features of superimposed cellular infiltration. Visible prelaminar cellular infiltrate (diffuse or focal) tends to be more opaque, with a grayish or yellowish discoloration (Fig 4-14); the infiltrate may be denser and more opaque than in nonspecific edema. Focal granulomatous infiltration may consist of a focal nodule on the ONH surface.

Infiltrative optic neuropathies are generally more rapidly progressive than compressive lesions, and patients may have more systemic symptoms (including a known, preexisting cancer diagnosis). When ONH edema and vision loss persist or progress in a way that is atypical for the common causes of optic neuropathy (eg, optic neuritis) or when prelaminar infiltrate is visible, ancillary testing for an infiltrative lesion should be performed.

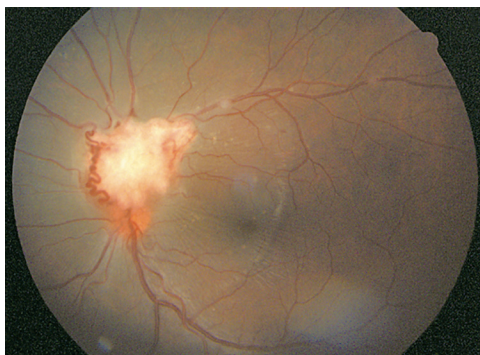
When an orbital compressive lesion is suspected, neuroimaging is indicated. Although MRI with contrast material and fat suppression is best for evaluating soft-tissue abnormalities in the orbits, particularly in differentiating meningioma from glioma, a thin-section CT scan of the orbits with contrast material remains a satisfactory option and is preferred for evaluation of calcification and bony abnormalities.

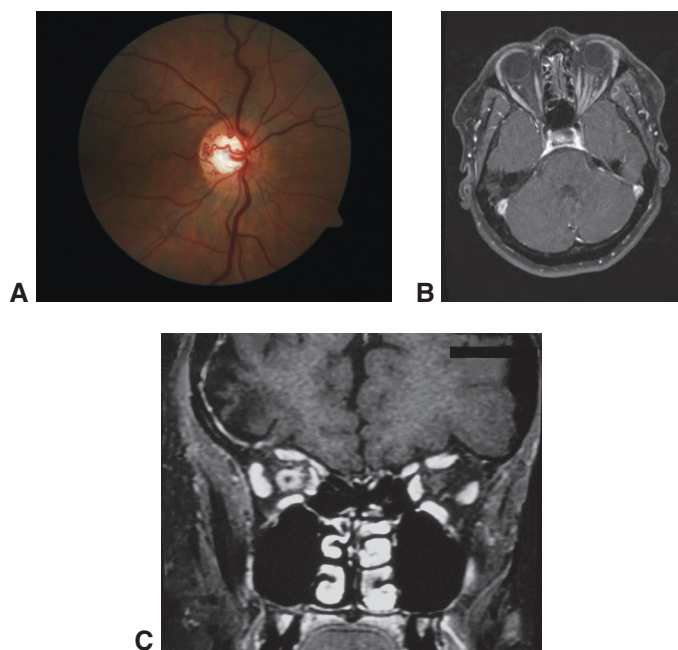
**Optic nerve sheath meningioma and intracranial meningioma** ONSMs arise from proliferations of the meningoepithelial cells lining the sheath of the intraorbital or intracanalicular optic nerve. In contrast, intracranial meningiomas involving the optic nerve are the result of compression from the involved sphenoid wing or tuberculum sella (Fig 4-15; see also Chapter 2, Fig 2-7). Most meningiomas that involve the orbit represent extensions from intracranial sites, whereas true primary ONSMs are far less common (ie, 1%–2% of all meningiomas, although they account for one-third of primary optic nerve tumors, second only to OPGs in prevalence/frequency). Distinguishing an intracranial meningioma from an ONSM is important because surgical resection is a viable treatment option for intracranial meningioma.

Most ONSMs (95%) are unilateral. They are usually detected in middle-aged women and are rare in children. Some patients may present with the classic diagnostic triad:

- painless, slowly progressive monocular vision loss (see Chapter 2, Fig 2-14)
- optic atrophy
- optociliary shunt vessels

**Figure 4-14** Sarcoid optic neuropathy. A 25-year-old man with a 1-month history of blurred vision had visual acuity of 20/50 and a moderate left relative afferent pupillary defect. The dense white elevation on the ONH represents granulomatous inflammation. A chest x-ray showed hilar adenopathy, and bronchoscopy confirmed sarcoidosis. (Courtesy of Steven A. Newman, MD.)





**Figure 4-15** Optic nerve sheath meningioma. **A**, Fundus photograph shows ONH atrophy, with optociliary shunt vessels (retinochoroidal collaterals) visible at the 9- and 12-o'clock positions. **B**, Axial fat-saturated orbital MRI reveals the “tram track” sign, diffuse enlargement of the right intraorbital optic nerve extending anteriorly to the globe, with enhancement of the optic nerve sheath. **C**, “Ring sign” in meningioma. Coronal orbital MRI scan shows similar optic nerve sheath enhancement surrounding a relatively normal, darker optic nerve on the right. (Parts A and B courtesy of Gregory Van Stavern, MD. Part C reprinted from Arnold AC. Optic nerve meningioma. Focal Points: Clinical Modules for Ophthalmologists. American Academy of Ophthalmology; 2004, module 7.)

Optociliary shunt vessels (also known as retinochoroidal collaterals) occur in approximately 30% of patients with ONSM but are nonspecific and can also be seen in sphenoid wing meningioma, OPG, CRVO, and chronic papilledema. These preexisting ONH channels dilate in response to chronic obstruction of outflow through the central retinal vein and shunt retinal venous outflow to the choroidal circulation. Patients with ONSM also demonstrate an RAPD and an optic nerve–related visual field defect. Minimal to mild proptosis and mild ocular motility defects can also occur. ONH edema may be present, especially if the tumor extends anteriorly. Neuroimaging findings confirm the diagnosis (Table 4-9).

Stereotactic fractionated radiation therapy is the treatment of choice for ONSM and can produce stability or vision improvement in up to 95% of patients. However, it remains unclear whether radiation should be administered immediately upon diagnosis or when tumor growth or progressive vision loss is documented, because patients with ONSM may have minimal loss of vision for several years. In rare cases, radiation retinopathy and pituitary dysfunction have been reported as late radiation complications.

Surgery (ie, biopsy or excision of the meningioma) is typically not advised because of the considerable potential for significant vision loss. However, if the tumor extends

**Table 4-9 Comparative Neuroradiologic Features Between Optic Nerve Sheath Meningioma and Optic Nerve Glioma**

Optic Nerve Sheath Meningioma	Optic Nerve Glioma
Adjacent bony hyperostosis on CT scan	No calcification or hyperostosis on CT scan
Apical expansion of the tumor	Kinking or buckling of the optic nerve
Calcification of the nerve sheath on CT scan	Smooth sheath margins (no extradural extension)
Diffuse, tubular enlargement of the optic nerve	Fusiform or globular enlargement of the optic nerve
Extradural tumor extension	Regions of low intensity within the nerve (cystic spaces)
Isointense or mildly hyperintense to brain on T1- and T2-weighted MRI	Isointense or mildly hypointense to brain on T1-weighted MRI; hyperintense on T2-weighted MRI
Prominent contrast enhancement on CT and MRI	Variable-contrast (CT scan) and gadolinium (MRI) enhancement
Sheath thickening and enhancement, with relative sparing of optic nerve substance ("tram track" or "railroad track" sign)	Thickening of both nerve and sheath by tumor

CT=computed tomography; MRI=magnetic resonance imaging.

intracranially or, in very rare cases, across the planum sphenoidale, the risk of contralateral vision loss may warrant surgical debulking, particularly with severe ipsilateral vision loss. For residual tumors, radiation therapy is often performed after surgery.

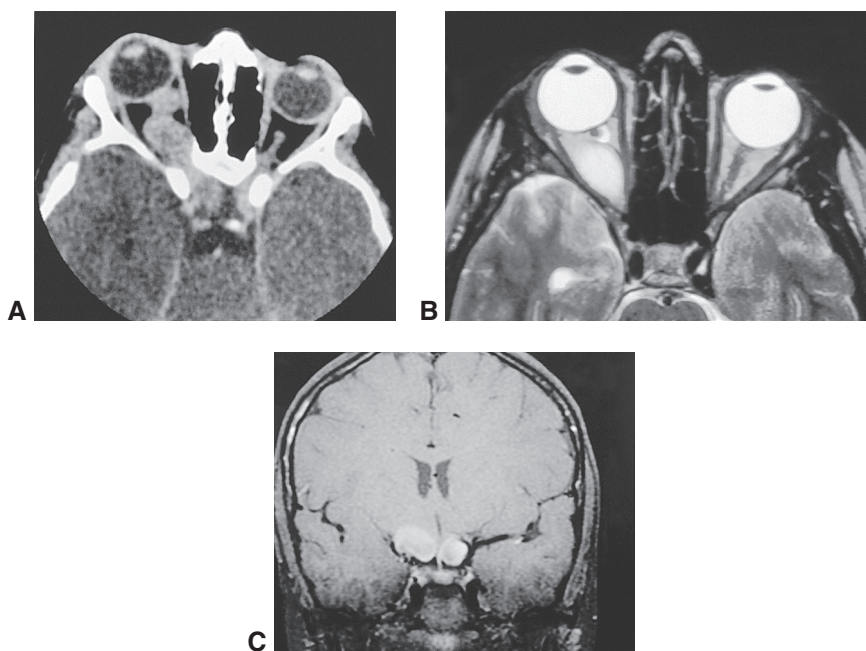
When there is no change in visual function or tumor size, observation is appropriate. ONSMs in children may be more aggressive, with more rapid vision loss and more frequent recurrence after therapy. Therefore, children must be monitored more frequently than adults.

Shapey J, Sabin HI, Danesh-Meyer HV, Kaye AH. Diagnosis and management of optic nerve sheath meningiomas. *J Clin Neurosci.* 2013;20(8):1045–1056.

**Optic pathway glioma** Although OPGs (also known as *pilocytic astrocytomas*) account for only approximately 1% of intracranial tumors, they are the most common primary tumor of the optic nerve. They may involve the optic nerve, the chiasm, or both (Fig 4-16).

Approximately 70% of OPGs are detected during the first decade of life and 90% by the second decade; however, they may occur at any age. There is no definitive sex association. The most common presenting signs are proptosis (occurring in 94% of patients with OPG), vision loss (87.5%), ONH pallor (59%), ONH edema (35%), and strabismus (27%). OPGs involving the chiasm may show bitemporal or bilateral optic nerve–related visual field defects and (as with any chiasmal tumor) may produce see-saw nystagmus or a monocular shimmering nystagmoid oscillation (pseudo-spasmus nutans). Large tumors may cause obstructive hydrocephalus with elevated ICP, headache, and papilledema. In prepubertal children, involvement of the hypothalamus may result in precocious puberty or diencephalic syndrome.

Patients infrequently present with asymptomatic isolated optic atrophy. An RAPD is usually present in unilateral or asymmetric cases, along with a typical optic nerve–related



**Figure 4-16** Optic pathway glioma. **A**, Contrast-enhanced axial orbital computed tomography (CT) image shows an enlarged and kinked optic nerve with mild hypodense cystic change centrally. The tumor extends intracranially. **B**, T2-weighted axial MRI scan (non-contrast-enhanced) of the orbits shows an enlarged, hyperintense, globular glioma of the right optic nerve. **C**, T1-weighted coronal MRI scan shows prominent enlargement at the junction of the optic nerves and chiasm.

visual field defect. Optociliary shunt vessels may be present on the affected ONH, although they are noted less commonly than with ONSMs. Diagnosis is confirmed by neuroradiologic findings (see Table 4-9).

In patients with neurofibromatosis 1 (NF1), the prevalence of OPG is 7.8%–21.0%. In contrast, in patients with OPG, the prevalence of NF1 is 10%–70%. The wide variance probably relates to referral bias, differences in neuroimaging detection rates, and criteria for diagnosis. Similarly, the relationship between NF1 and the progression/course of OPG is unclear, although patients with NF1 may have a more benign prognosis. Neurofibromatosis is discussed further in Chapter 15 of this volume and in BCSC Section 6, *Pediatric Ophthalmology and Strabismus*.

As with ONSMs, biopsy of OPGs is generally not required because high-resolution neuroimaging has improved diagnostic accuracy and biopsy of the optic nerve substance may cause additional vision loss.

There is no universally accepted treatment of OPGs. Most patients show stability or very slow progression over years and sometimes experience spontaneous regression. Thus, observation is indicated for patients with relatively good vision and stable radiographic appearance. For patients who present with severe vision loss or evidence of progression, chemotherapy is offered as initial treatment. Radiotherapy is controversial

because of inconclusive results and potential complications (particularly in children), including panhypopituitarism and cognitive impairment. Surgical excision may be indicated in patients with severe vision loss associated with disfiguring proptosis. Surgery has also been suggested to prevent advancement into the chiasm; however, such extension is rare. Hydrocephalus may require CSF shunting.

Malignant gliomas of the anterior visual pathway, or *malignant optic gliomas of adulthood (MOGAs)*, are rare neoplasms that almost always occur in adults. The mean age at presentation is in the 60s, and there is no sex association. Vision loss is often very rapid. Patients may present with acute-onset periorbital pain; in this scenario, tumors may be misdiagnosed as optic neuritis or NAION. With unilateral lesions, the second eye invariably becomes involved (via the chiasm) within weeks. In most cases, the ONH appears normal or pale at presentation, but ONH edema and retinal obstruction can cause venous stasis retinopathy or CRVO. When the tumor originates in the distal portion of the optic nerve or the optic chiasm, vision loss may be simultaneously bilateral and associated with a pale or normal-appearing ONH.

MRI of the brain and orbits with contrast agent most often shows diffuse intrinsic enlargement and enhancement of the affected optic nerves, chiasm, and optic tracts, with inhomogeneity due to cystic spaces within the tumor. Occasionally, a large exophytic component may encroach on the suprasellar cistern. Histologically, MOGAs are classified as either anaplastic astrocytomas or glioblastoma multiforme.

Although radiotherapy and chemotherapy have been attempted, treatment is usually unsuccessful, with blindness developing 2–4 months after onset of vision loss. The tumor is aggressively infiltrative, and death from hypothalamic and brainstem involvement usually occurs within 12 months.

Fried I, Tabori U, Tihan T, Reginald A, Bouffet E. Optic pathway gliomas: a review.

*CNS Oncol.* 2013;2(2):143–159.

Lee AG. Neuroophthalmological management of optic pathway gliomas. *Neurosurg Focus.*

2007;23(5):E1. doi: 10.3171/FOC-07/11/E1

Listernick R, Ferner RE, Liu GT, Gutmann DH. Optic pathway gliomas in neuro-

fibromatosis-1: controversies and recommendations. *Ann Neurol.* 2007;61(3):189–198.

Traber GL, Pangalu A, Neumann M, et al. Malignant optic glioma—the spectrum of disease

in a case series. *Graefes Arch Clin Exp Ophthalmol.* 2015;253(7):1187–1194.

**Retrobulbar infiltration of the optic nerve** Infiltration of the optic nerve by neoplastic or inflammatory cells causes progressive, often severe, vision loss. This visual dysfunction, which is often associated with pain, progresses over days to weeks with or without other CN involvement. The optic neuropathy may present in one or both eyes and can herald systemic disease. With retrobulbar infiltration, the ONH may initially appear normal. In cases of ONH edema, the cellular infiltrate creates a swollen appearance that may be distinct from that of simple edema (see Fig 4-14). The presence of vitreous cells or peripheral vasculitis may signal an infiltrative process.

The most common causes of infiltration include leukemia, lymphoma, syphilis, and granulomatous inflammatory processes such as fungal infections, sarcoidosis, or tuberculosis. Metastasis to the optic nerve is rare, usually occurring from breast or lung



carcinoma. In 15%–40% of cases, carcinomatous infiltration of the meninges at the skull base may cause not only vision loss but also progressive involvement and dysfunction of multiple CNs. Onset may precede, coincide with, or follow diagnosis of the underlying malignancy.

Securing a correct diagnosis of infiltrative optic neuropathy is essential to ensure timely treatment and prevent life-threatening complications. Evaluation of suspected cases should include MRI of the brain and orbits with fat suppression and gadolinium enhancement to rule out compressive lesions and confirm pachymeningeal or meningeal infiltration. MRI may show diffuse thickening and enhancement of the dura and the surrounding subarachnoid space in affected regions, including the optic nerve sheaths; however, abnormalities may not be visible in the early stages. Perineural invasion can be notoriously difficult to detect even with MRI. Therefore, when infiltration and perineural invasion are suspected, obtaining good quality orbital and skull base imaging and providing accurate information to the neuroradiologist are critical. Repeated neuroimaging is warranted if clinical progression occurs. Serologic testing includes screening tests for myeloproliferative, inflammatory, and infectious disorders. Finally, CSF analysis may reveal malignant cells, an elevated white blood cell count, and elevated protein levels consistent with a neoplastic, infectious, or inflammatory cause. The sensitivity of a single lumbar puncture is low, and repeated testing is often necessary. Treatment is highly dependent on the specific disease process.

de Fátima Soares M, Braga FT, da Rocha AJ, Lederman HM. Optic nerve infiltration by acute lymphoblastic leukemia: MRI contribution. *Pediatr Radiol*. 2005;35(8):799–802.

Millar MJ, Tumuluri K, Murali R, Ng T, Beaumont P, Maloof A. Bilateral primary optic nerve lymphoma. *Ophthalm Plast Reconstr Surg*. 2008;24(1):71–73.

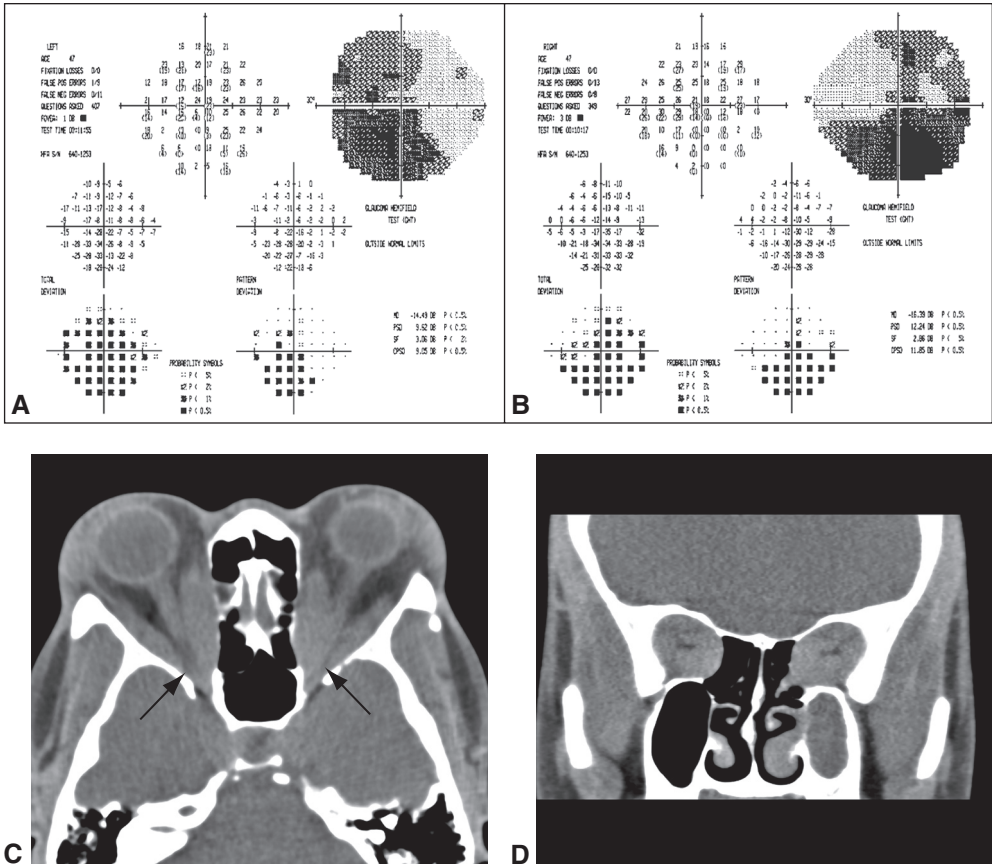
Yeung SN, Paton KE, Dorovini-Zis K, Chew JB, White VA. Histopathologic features of multiple myeloma involving the optic nerves. *J Neuroophthalmol*. 2008;28(1):12–16.

### **Thyroid eye disease**

Thyroid eye disease (TED) often presents with progressive enlargement of extraocular muscles or orbital fat hypertrophy. In rare cases, progressive proptosis can stretch the optic nerve and cause dysfunction. The extraocular muscles can also enlarge, compressing the optic nerve at the orbital apex (Fig 4-17). In addition to proptosis, patients usually present with associated signs (eg, eyelid retraction and lid lag) and possibly orbital congestion (eg, eyelid and conjunctival edema). However, some patients demonstrate only minimal orbital findings and present with isolated diplopia, usually due to involvement of the medial rectus or inferior rectus muscle.

The vision loss associated with TED is usually slowly progressive, insidious, and bilateral. Dyschromatopsia may be an early sign of optic neuropathy. Results of visual field testing show central or diffuse depression, and an RAPD is present when the optic neuropathy is asymmetric or unilateral. The ONH is commonly normal but may be mildly edematous. Optic atrophy may be present in chronic cases.

In the acute phase, use of systemic steroids reduces compression on the optic nerve. In some cases, surgical decompression of the posterior orbit is required. The use of radiation therapy alone is controversial and is not indicated to treat acute optic neuropathy



**Figure 4-17** Thyroid eye disease (TED) in a 48-year-old man with a 6-month history of weakness, gradual swelling around the eyes, and progressively decreased visual acuity over the previous month. Visual acuity was 20/200 OD and 20/80 OS, with a mild right relative afferent pupillary defect. **A and B**, Automated perimetry testing shows bilateral central and inferior visual field loss. Axial (**C**) and coronal (**D**) CT images show the optic nerve becoming compressed (arrows in C) by enlarged extraocular muscles. Enlargement of extraocular muscle in TED typically spares the muscle tendon. (Parts A and B courtesy of Steven A. Newman, MD; parts C and D courtesy of Michael S. Lee, MD.)

(unless it is combined with systemic steroids). Teprotumumab, a humanized monoclonal antibody that inhibits the insulin-like growth factor-1 receptor on orbital fibroblasts, is FDA approved for TED.

TED is discussed at greater length in BCSC Section 7, *Oculofacial Plastic and Orbital Surgery*.

### Hereditary conditions

**Leber hereditary optic neuropathy** LHON results from a mitochondrial (mt) DNA mutation, most frequently at the 11778 position, less commonly at the 3460 or 14484 location.

The point mutation is transmitted by mtDNA, which is inherited only from the mother. Most LHON cases are homoplasmic (ie, mtDNA is either uniformly normal or uniformly mutant, as opposed to heteroplasmic, in which normal and mutant mtDNA is variably divided among the progeny cells in a given individual). However, family history may be negative because of a *de novo* mutation or lack of phenotypic expression.

LHON typically affects boys and men aged 15–35 years, but it may occur much earlier or later in life (the possible range is 1–86 years of age). Symptomatic women account for only 10%–20% of cases.

The syndrome generally presents with acute, painless, sequential, and severe vision loss (visual acuity <20/200) associated with central or cecocentral visual field impairment (Fig 4-18). The classic fundus appearance consists of

- hyperemia and elevation of the ONH, with thickening of the peripapillary retina; although the ONH appears swollen, it does not leak on fluorescein angiography (“pseudoedema”)
- peripapillary telangiectasia
- tortuosity of the medium-sized retinal arterioles

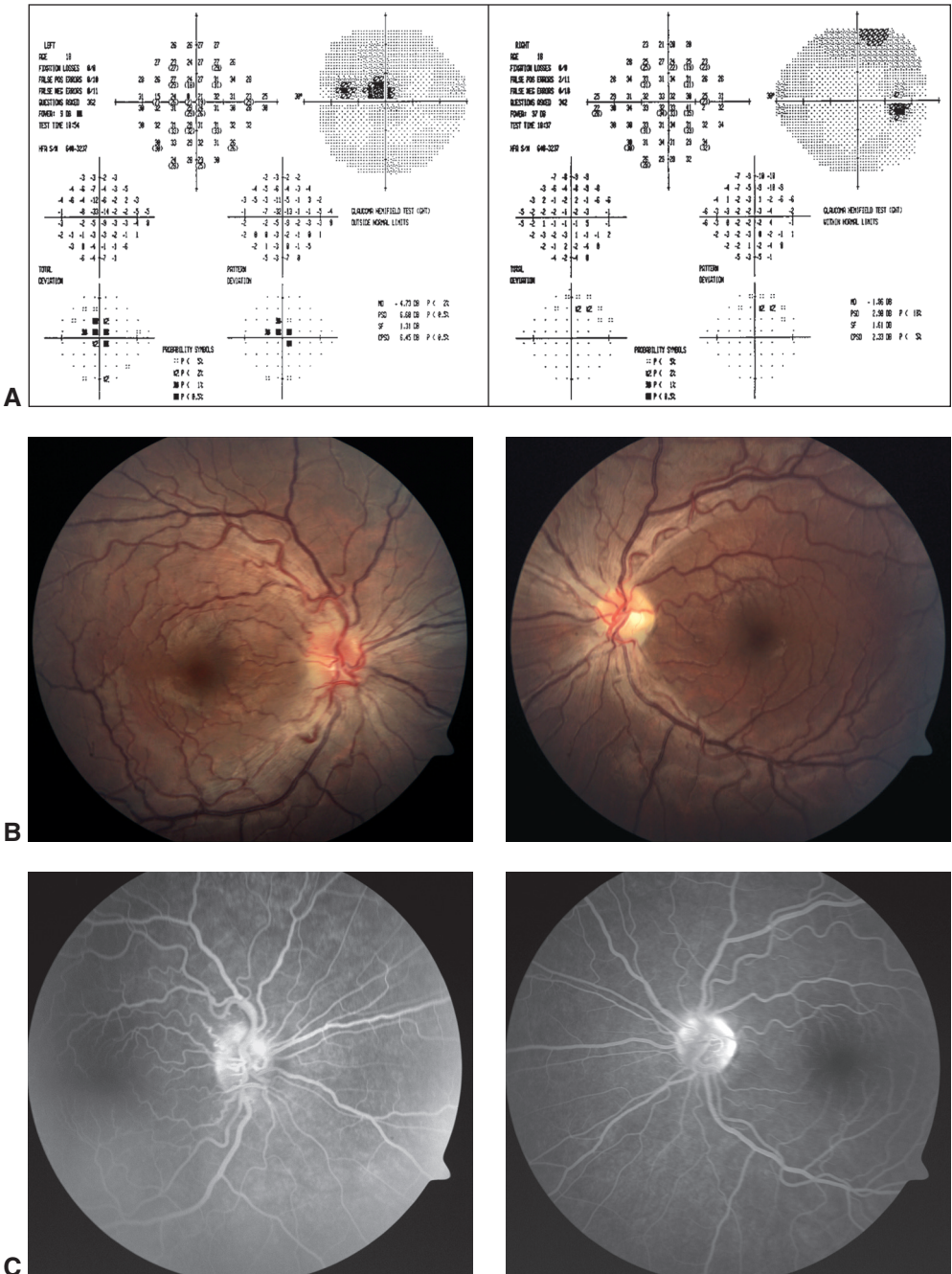
However, these findings may be noted before vision loss begins, and the fundus may appear entirely normal on presentation. In addition, not all men with affected mitochondria experience vision loss, and affected women experience visual symptoms only infrequently. The reasons for this selective male susceptibility remain unknown. Changes on OCT corresponding to the appearance of ONH edema, hyperemia, and microvascular changes on fundus examination include predominant early thickening of the superior and inferior pRNFL and normalization of the temporal pRNFL as it begins to atrophy.

Temporal thinning then develops, and by 9 months, superior and inferior thinning is apparent as well. Although the unaffected eye typically becomes symptomatic within weeks to months, in rare cases, the interval between initial and fellow eye involvement can be longer (up to 8 years).

The differential diagnosis of LHON includes all other types of optic neuropathies, particularly optic neuritis, compressive optic neuropathy, and infiltrative optic neuropathy. For patients with a negative family history, neuroimaging should be performed. Occasionally, patients demonstrate cardiac conduction abnormalities or other mild neurologic deficits that warrant further evaluation.

Mitochondrial testing for the 3 primary mutations is commercially available. Blood testing for these mutations confirms the diagnosis, permits genetic counseling, and provides information about prognosis. Children and adult patients with the 14484 mutation have a greater chance (up to 65%) of late spontaneous improvement in central visual function, whereas those with the 11778 mutation have a lower chance (estimated at 4%).

No treatment has been effective in reversing the visual loss associated with LHON. Corticosteroids are not beneficial. The effect of idebenone on visual outcome remains controversial. One study showed a potential benefit for patients early in the disease course, but there is no evidence that idebenone is beneficial in the later stages of the disease.



**Figure 4-18** Leber hereditary optic neuropathy. A 17-year-old experienced severe, painless vision loss in his left eye. **A**, Visual field testing demonstrated a central scotoma in the left eye. Two months later, the patient lost vision in the right eye. Mitochondrial genetic testing revealed the 11778 mutation. **B**, Fundus photographs demonstrate hyperemic ONHs with blurred margins and moderately tortuous vasculature. The left ONH shows mild temporal pallor. **C**, No leakage is seen on fluorescein angiography. (Parts B and C courtesy of Michael S. Lee, MD.)

### Post Hoc Visual Function Analysis From the Randomized, Placebo-Controlled Trial of Idebenone in LHON

The improvement in visual function achieved with idebenone in a clinical trial, reported by Klopstock et al, was found only on post hoc analysis. Post hoc analyses have inherent limitations. Because they assess differences that were not part of the original study design and rely on multiple comparisons, the results may simply be due to chance. Although they can be valuable for generating a hypothesis and planning for future studies, post hoc findings should be integrated into medical decision-making with caution.

Tobacco use or excessive alcohol intake may stress mitochondrial function and thus contribute to vision loss; therefore, patients with LHON should avoid the use of tobacco and should curtail alcohol consumption.

Fraser JA, Biousse V, Newman NJ. The neuro-ophthalmology of mitochondrial disease. *Surv Ophthalmol*. 2010;55(4):299–334.

Klopstock T, Yu-Wai-Man P, Dimitriadis K, et al. A randomized, placebo-controlled trial of idebenone in Leber's hereditary optic neuropathy. *Brain*. 2011;134(pt 9):2677–2686.

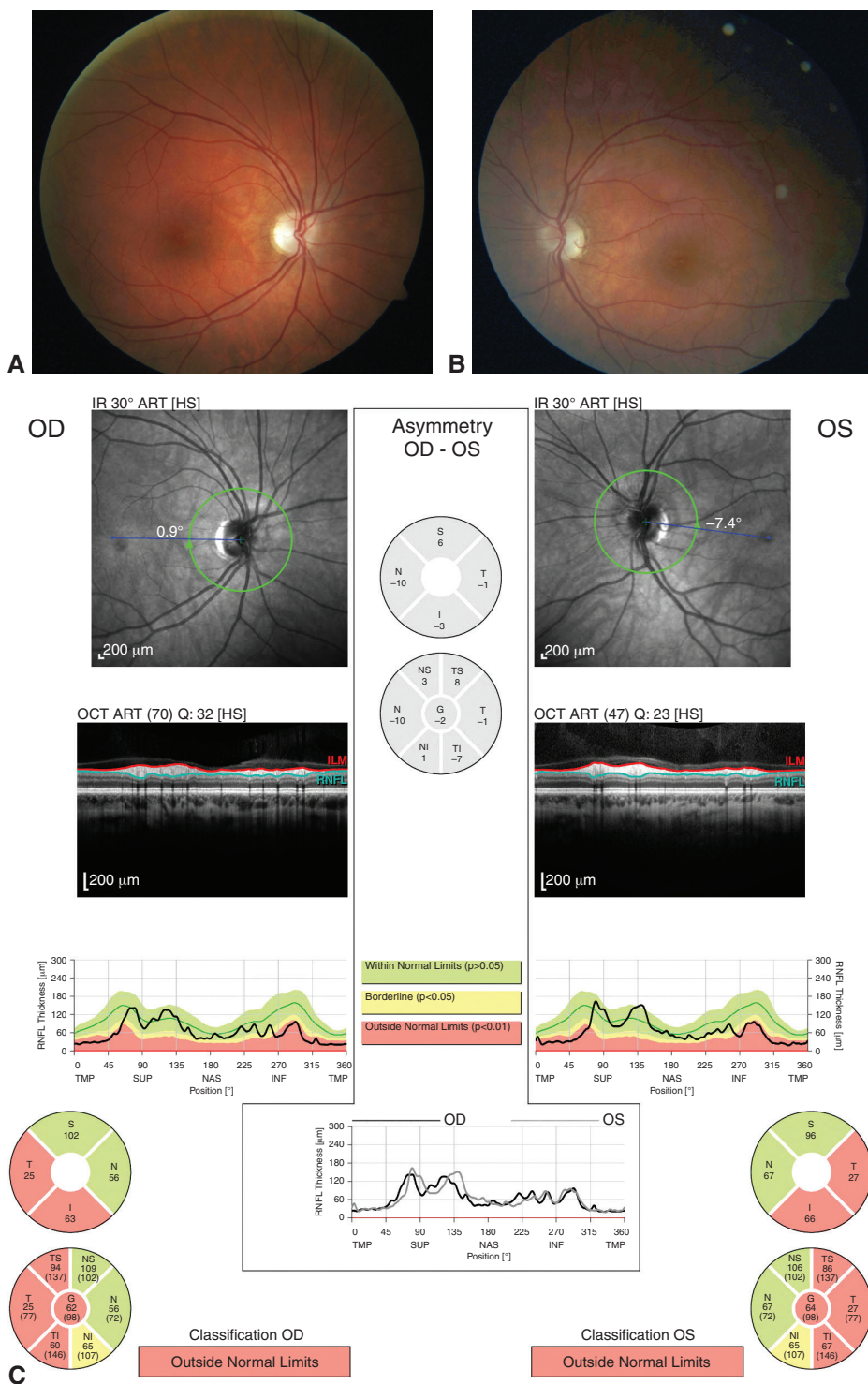
Newman NJ. Treatment of hereditary optic neuropathies. *Nat Rev Neurol*. 2012;8(10):545–556.

**Autosomal dominant optic atrophy** The most common hereditary optic neuropathy (estimated incidence, 1 case per 50,000) is autosomal dominant optic atrophy (ADOA). Also known as Kjer disease, ADOA has a dominant inheritance pattern with variable penetrance and expression. Genetic linkage studies have localized an ADOA gene (*OPA1*) to a region on chromosome 3. The *OPA1* protein is widely expressed and most abundant in the retina. It encodes dynamin-related guanosine triphosphatase, which is anchored to mitochondrial membranes; thus, mutations result in loss of mitochondrial membrane integrity and function, with subsequent retinal ganglion cell degeneration and optic atrophy. Mutations in the *OPA3* gene account for a subset of patients with ADOA; some mutations can also cause cataracts and peripheral polyneuropathy in addition to an optic neuropathy.

ADOA usually presents in the first decade of life, with insidious onset of vision loss; it is often first detected during routine school vision screenings. Involvement is usually bilateral and relatively symmetric. At detection, visual acuity loss is usually mild to moderate, ranging from 20/30 to 20/60, although acuity may decline progressively. Most patients preserve a visual acuity >20/200. Color vision deficits, usually tritanopia (blue-yellow), are invariably present. These patients may pass evaluation with the Ishihara pseudoisochromatic color plates, which test red-green deficits. Tritanopia detection may require testing by Hardy-Rand-Rittler plates or the Farnsworth panel D-15 or D-100 test.

In most cases, visual field testing demonstrates central or cecocentral loss. The defects typically do not respect the vertical midline. Affected ONHs usually show focal, wedge-shaped temporal pallor and excavation (Fig 4-19), but diffuse pallor can also occur. OCT





**Figure 4-19** Autosomal dominant optic atrophy in a 39-year-old woman with a 25-year history of poor vision, with slow decline. **A and B**, Color fundus photographs show temporal pallor with some excavation and cupping. **C**, OCT shows diffuse peripapillary retinal nerve fiber layer thinning with prominent temporal thinning in each eye. (Courtesy of Gregory Van Stavern, MD.)

shows pRNFL thinning, which affects the entire ONH but is most pronounced temporally and inferiorly, then superiorly, and is least pronounced nasally.

The clinical diagnosis is based on examination findings and negative neuroimaging results (neuroimaging should be performed in all suspected cases). Genetic testing is commercially available but does not test for all mutations that cause ADOA, so it is helpful only when positive. The clinical course is generally stable or characterized by very slow progression over the patient's lifetime (loss of approximately 1 Snellen line per decade). No treatment is available.

There are a variety of other hereditary optic neuropathies, but most are accompanied by other neurologic or systemic manifestations (ie, polysymptomatic). Wolfram syndrome (also known as diabetes insipidus, diabetes mellitus, optic atrophy, and deafness [DIDMOAD syndrome]) can present with vision loss in childhood. The hereditary ataxias also include optic neuropathy in the phenotype, but the presentation is usually dominated by the other neurologic manifestations. These conditions are best evaluated and managed along with a neurologist or clinical geneticist. Table 4-10 summarizes the clinical features of some of these disorders.

Skidd PM, Lessell S, Cestari DM. Autosomal dominant hereditary optic neuropathy (ADOA): a review of the genetics and clinical manifestations of ADOA and ADOA+. *Semin Ophthalmol*. 2013;28(5-6):422-426.

Yu-Wai-Man P, Chinnery PF. Dominant optic atrophy: novel *OPA1* mutations and revised prevalence estimates. *Ophthalmology*. 2013;120(8):1712-1712.e1.

### **Toxic substances and nutritional deficiency**

Optic neuropathies resulting from toxic exposure or nutritional deficiency constitute a heterogeneous group of conditions that are generally characterized by gradual, progressive, and painless vision loss that is bilateral and symmetric. They share many characteristics with hereditary optic neuropathies, as they generally involve mitochondrial dysfunction with selective involvement of the papillomacular bundle.

Initial findings may include a subtle depression of central vision sensitivity on Amsler grid or perimetry testing focused within the central 10°. As the disturbance becomes more

**Table 4-10 Hereditary Optic Neuropathies: Leber Hereditary Optic Neuropathy, Autosomal Dominant Optic Atrophy, and Wolfram Syndrome**

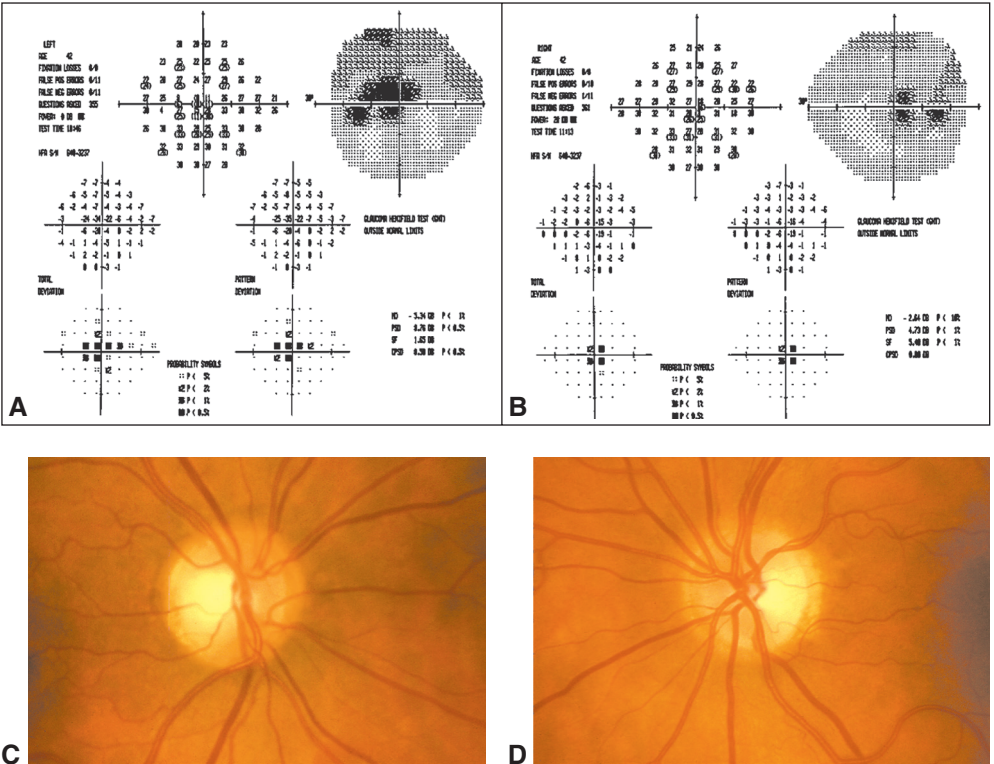
	<b>Leber Hereditary Optic Neuropathy</b>	<b>Autosomal Dominant Optic Atrophy</b>	<b>Wolfram (DIDMOAD) Syndrome</b>
Mode of inheritance	Mitochondrial	Autosomal dominant	Autosomal recessive
Age at presentation	Usually 15–35 years	First decade of life	<10 years
Classic optic nerve head appearance	Acute hyperemia with peripapillary telangiectasia	Wedgelike excavation of optic nerve head	Temporal optic nerve head pallor
Sex	Male > Female	None	None
Gene	Mitochondrial DNA point mutations (11778, 3460, 14484)	<i>OPA1</i> in most	<i>WFS1</i>

DIDMOAD = diabetes insipidus, diabetes mellitus, optic atrophy, and deafness.

severe, however, central vision loss worsens, accompanied by decreases in visual acuity and color vision and a central scotoma (Fig 4-20). Occasionally, decreased vision has a more rapid onset. Optic atrophy eventually develops when the cause is not corrected. In rare cases, the ONHs may exhibit mild to moderate edema on presentation.

OCT typically shows temporal pRNFL thinning and loss of the ganglion cell–inner plexiform layer (GC-IPL). This loss may precede temporal pRNFL thinning and point to a vitamin deficiency or drug toxicity. A thorough patient history can also reveal exposure to medications or toxic agents, substance abuse, or dietary deficiency (as may occur after bariatric surgery or colectomy) as the cause of the optic neuropathy.

Causation is usually multifactorial, and definite proof of optic nerve toxicity by a single toxic agent or nutritional deficiency is rare. The most commonly implicated agents in the development of toxic optic neuropathies are methanol, ethylene glycol, organic solvents, lead (in children), tobacco, usually cigars (tobacco use has long been implicated in optic nerve dysfunction, but the evidence supporting this association is questionable),



**Figure 4-20** Nutritional deficiency optic neuropathy. A 42-year-old woman with a history of 4 bowel resections presented with bilateral blurred vision and trouble recognizing colors. Visual acuity was 20/70 OD and 20/200 OS, without a relative afferent pupillary defect. **A and B**, Visual fields demonstrate a cecocentral scotoma on the left and a relative central scotoma on the right. **C and D**, Fundus photographs show mild temporal optic atrophy in both eyes, with papillomacular nerve layer dropout. After the patient was treated with multivitamins and hydroxocobalamin injections, the visual field defects resolved completely, and visual acuity returned to 20/20. (Courtesy of Steven A. Newman, MD.)

ethambutol, linezolid, amiodarone, disulfiram, ciprofloxacin, and the antineoplastic drugs cisplatin and vincristine. Because it may contribute to malnutrition, ethanol abuse is probably indirectly associated with optic neuropathy. Methanol and ethylene glycol toxicity cause a rapid onset of severe bilateral vision loss with prominent ONH edema.

Other medications recognized as potential causes of toxic optic neuropathies include interferon and anti-tumor necrosis factor  $\alpha$  agents (eg, etanercept, infliximab, and adalimumab), which may cause an acute demyelinating optic neuritis. Some toxic optic neuropathies are more commonly associated with ONH swelling. Amiodarone toxicity may present with bilateral vision loss and ONH edema. It may be differentiated from NAION by its subacute onset, bilaterality, diffuse rather than altitudinal visual field loss, and slow resolution of ONH edema over months after discontinuance of the medication. Interferon alfa has been reported as a cause of bilateral NAION. PDE5-inhibitor use has been associated with an increased risk of NAION, but this association is controversial. A large number of other pharmaceutical agents and toxins are also reported to cause optic neuropathy. However, many of these drugs are associated with optic neuropathy on an anecdotal basis, and a specific cause-effect relationship remains unproven. It may also be challenging to implicate a specific medication in patients using multiple agents. Therefore, ophthalmologists should be cautious about discontinuing a therapy without a thorough discussion with the patient and the prescribing physician.

Diagnosing nutritional optic neuropathy can be difficult, particularly in patients whose symptoms are vague and who show little objective abnormality. For example, although a careful and detailed dietary patient history may help pinpoint a neuropathy, persons who misuse ethanol may obscure or falsify details of food and ethanol ingestion. Likewise, deficiencies of vitamin B<sub>12</sub>, copper, folate, and thiamine may cause an optic neuropathy, but exact deficiencies are difficult to identify and are detected only infrequently on blood testing. Nevertheless, thiamine deficiency should be considered in all patients with suspected nutritional optic neuropathy, as rapid treatment can prevent the development of other neurologic deficits, such as encephalopathy, ataxia, and nystagmus.

The differential diagnosis of toxic or nutritional optic neuropathies includes subtle maculopathies and hereditary, compressive, demyelinating, and infiltrative optic neuropathies. Fluorescein angiographic studies, hematologic and serologic testing, and CSF analysis (in rare cases) can be helpful in questionable cases. Neuroimaging is performed routinely to rule out a compressive etiology.

The goal of treatment is to reverse the inciting cause, such as stopping medication or substance abuse and resolving dietary deficiencies. Prognosis for vision recovery is good if optic atrophy has not supervened; however, recovery is highly variable. Improvement of vision typically occurs slowly over several months.

Campbell UB, Walker AM, Gaffney M, et al. Acute nonarteritic anterior ischemic optic neuropathy and exposure to phosphodiesterase type 5 inhibitors. *J Sex Med.* 2015;12(1):139–151.

Fraunfelder FW, Sadun AA, Wood T. Update on ethambutol optic neuropathy. *Expert Opin Drug Saf.* 2006;5(5):615–618.

Peragallo J, Biousse V, Newman NJ. Ocular manifestations of drug and alcohol abuse. *Curr Opin Ophthalmol.* 2013;24(6):566–573.

Rucker JC, Hamilton SR, Bardenstein D, Isada CM, Lee MS. Linezolid-associated toxic optic neuropathy. *Neurology*. 2006;66(4):595–598.

Van Stavern GP. Metabolic, hereditary, traumatic, and neoplastic optic neuropathies. *Continuum (Minneap Minn)*. 2014;20(4 Neuro-ophthalmology):877–906.

Wang MY, Sadun AA. Drug-related mitochondrial optic neuropathies. *J Neuroophthalmol*. 2013;33(2):172–178.

**Glaucoma**

Patients with glaucoma do not usually note impaired vision until central vision is affected. Primary open-angle glaucoma is usually characterized by slowly progressive arcuate and peripheral visual field loss, sparing fixation until late in the course. Glaucoma is also distinguished from other optic neuropathies by the following features: preserved color vision, characteristic excavation of the optic cup (with increased diameter and depth of the physiologic cup, often with focal notching at the inferior or superior pole), and lack of pallor of the neuroretinal rim (until the disease is advanced).

Table 4-11 summarizes clinical features distinguishing glaucomatous from nonglaucomatous optic neuropathies. All aspects of glaucoma are discussed at length in BCSC Section 10, *Glaucoma*.

Differentiating glaucomatous from nonglaucomatous optic neuropathy can occasionally be challenging. Excavation of the ONH may also be present in diseases other than glaucoma, including compressive, hereditary (LHON, ADOA), and severe ischemic (AAION) processes. However, in these cases, the ONH is pale in addition to being cupped. Chiasmal compressive lesions typically produce temporal (hemianopic) rather than nasal visual field loss. In addition, these optic neuropathies affect visual acuity and color vision, which are late findings in glaucoma. Furthermore, the ONH may demonstrate early and more prominent pallor, with less severe excavation and notching than in glaucoma (Fig 4-21).

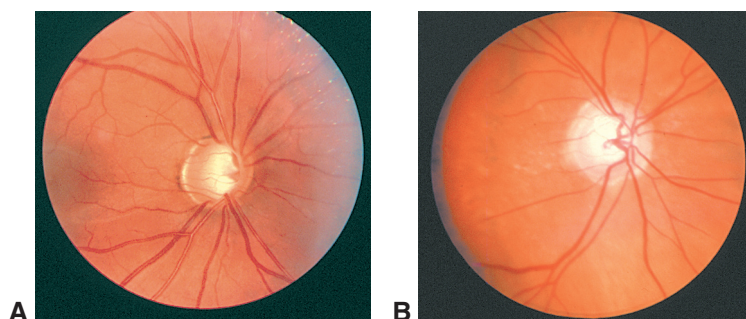
**Trauma**

The optic nerve may be damaged by trauma to the head, orbit, or globe. Direct trauma occurs less frequently than indirect optic nerve injury. *Direct* traumatic optic neuropathy (TON) may be caused by injury to the nerve itself or by laceration with bone fragments or other foreign bodies (Fig 4-22). Compressive optic neuropathy may be secondary to

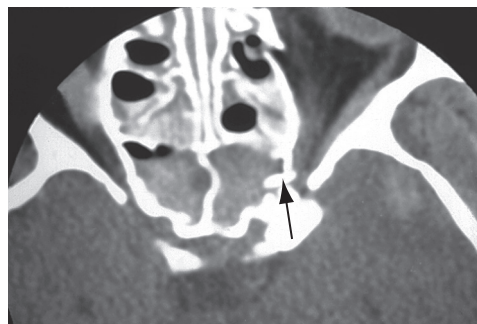
**Table 4-11 Glaucomatous Versus Nonglaucomatous Optic Neuropathy**

	Glaucomatous Optic Neuropathy	Nonglaucomatous Optic Neuropathy
Optic nerve head cupping	Extensive, with preservation of rim color	Variable, but pallor out of proportion to cupping
Visual field	Nasal arcuate defects	Variable but more commonly central; may respect vertical meridian
Relative afferent pupillary defect	Uncommon	Very common
Age at presentation	<50 years	Variable
Papillomacular bundle involvement (visual acuity, color)	Absent unless extensive visual field loss	Common





**Figure 4-21** Optic nerve excavation. **A**, Fundus photograph of *glaucomatous* damage; the remaining temporal rim of neuroretinal tissue generally retains a relatively normal pink color despite severe excavation. **B**, Fundus photograph of *nonglaucomatous* damage; the rim is pale relative to the degree of excavation. (Courtesy of Anthony C. Arnold, MD.)



**Figure 4-22** Traumatic optic neuropathy. CT scan from an 18-year-old involved in a severe motor vehicle accident. The patient noted decreased vision on the left side. The CT image shows a fracture in the area of the left optic canal, with a bone fragment (*arrow*) impinging on the left optic nerve. Visual acuity improved after transethmoidal decompression of the canal. (Courtesy of Steven A. Newman, MD.)

intraorbital or intrasheath hemorrhage from an injury. *Indirect* TON may occur even with a relatively minor head injury. The trauma involves the frontal or maxillary bone, and the transmitted forces damage the optic nerve at the orbital apex. Avulsion of the nerve may also occur. The pathophysiology presumably involves shear forces on the nerve and possibly its vascular supply in the optic canal. Vision loss is typically immediate and often severe (24%–86% of patients have no light perception at presentation). However, external evidence of injury may be scarce. An RAPD is invariably present when there is unilateral vision loss. Although the ONH usually appears normal at onset, it becomes pale within 4–6 weeks.

Management of suspected TON requires neuroimaging (head, orbit, and facial CT) to assess the extent of injury and to detect any associated intracranial and facial injuries, intraorbital fragments, or hematoma. Orbital or cranial surgery may be necessary but may not affect the prognosis for the optic nerve.

Therapy for indirect TON is controversial. Although the potential for vision recovery is generally poor, numerous reports have described occasional spontaneous recovery of some visual function. The International Optic Nerve Trauma Study—a nonrandomized, multicenter, comparative analysis of treatment outcomes after indirect TON—found no clear benefits with IV corticosteroids or optic canal decompression, and no consensus exists for their use, whether alone or in combination. The Corticosteroid Randomization

After Significant Head Injury (CRASH) study enrolled more than 10,000 patients and compared results of treatment with high-dose IV methylprednisolone (2-g bolus followed by 0.4 g for 48 hours in a 20-mL/hour infusion) versus placebo within 8 hours of head trauma. The study was terminated early after initial analysis revealed that the corticosteroid group had a statistically significantly higher rate of mortality than the placebo group. This finding raised concerns regarding the safety of high-dose corticosteroids in the treatment of TON, particularly in patients with severe head trauma. Because no high-quality evidence supports any treatment for TON, therapy should be offered only on a case-by-case basis.

Carta A, Ferrigno L, Salvo M, Bianchi-Marzoli S, Boschi A, Carta F. Visual prognosis after indirect traumatic optic neuropathy. *J Neurol Neurosurg Psychiatry*. 2003;74(2):246–248.

Edwards P, Arango M, Balica L, et al; CRASH trial collaborators. Final results of MRC CRASH, a randomised placebo-controlled trial of intravenous corticosteroid in adults with head injury—outcomes at 6 months. *Lancet*. 2005;365(9475):1957–1959.

Levin LA, Beck RW, Joseph MP, Seiff S, Kraker R. The treatment of traumatic optic neuropathy: the International Optic Nerve Trauma Study. *Ophthalmology*. 1999;106(7):1268–1277.

Steinsapir KD, Goldberg RA. Traumatic optic neuropathy: an evolving understanding. *Am J Ophthalmol*. 2011;151(6):928–933.e2.

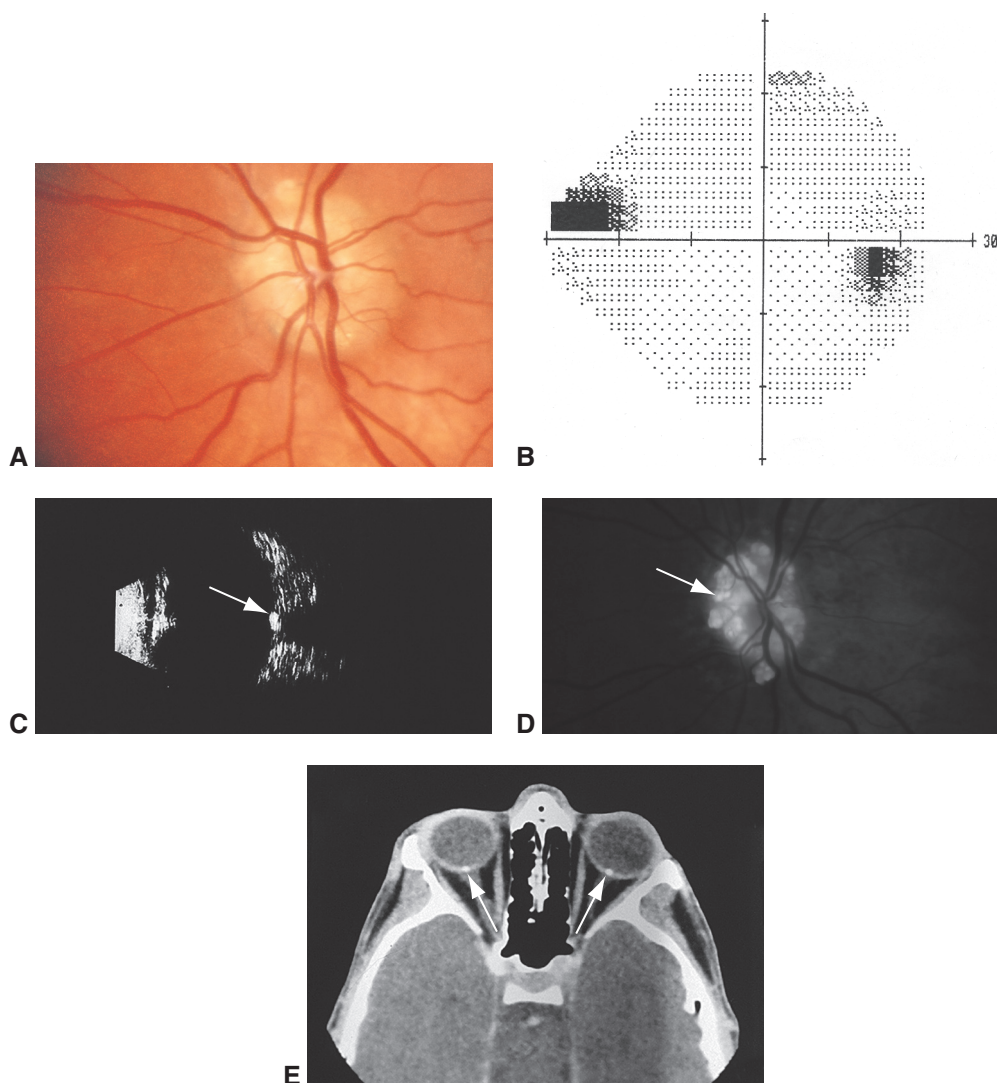
### **Optic disc drusen**

Optic disc drusen (ODD), also known as *hyaline* or *colloid bodies*, represent refractile, often calcified nodules located within the ONH (Fig 4-23). The prevalence ranges from 0.34% (clinical) to 2% (autopsy). ODD are found in males and females with equal frequency but rarely affect nonwhites. The drusen are often bilateral (75%–86% of patients with ODD) but can be asymmetric. They may be isolated or dominantly inherited.

The pathophysiology of ODD is unclear. Most theories suggest a process of impaired ganglion cell axonal transport, likely related to a small scleral canal and mechanical obstruction. Metabolic abnormalities associated with impaired transport may result in intra-axonal mitochondrial damage. The drusen represent the product of deteriorating axons, which extrude their contents into the interstitial space. Over time, the extruded material congeals and calcifies. ODD may be associated with retinitis pigmentosa and pseudoxanthoma elasticum.

Although most patients with ODD do not experience symptoms, some (8.6%) may have transient visual obscurations when there is ONH swelling. In rare cases, vascular complications (eg, flame hemorrhage, AION, or peripapillary subretinal neovascularization) occur. The location of visual field loss does not necessarily correlate with visible ODD. Nerve fiber bundle visual field defects occur in 75%–87% of cases, but most go unnoticed by the patient. Visual field defects either remain stable or worsen very slowly; therefore, patterns should be monitored over time. In patients with asymmetric visual field loss, an RAPD may be present. Visual acuity declines only in rare cases; thus, when acuity does decline or progressively worsen, other causes of vision loss should be explored.

The ONHs of patients with ODD appear elevated and small in diameter, with indistinct or irregular margins and associated anomalous vascular branching patterns.



**Figure 4-23** Optic disc drusen (ODD). **A**, Fundus photograph shows blurred ONH margin with scalloped edge, refractile bodies on the ONH surface and at the superior pole, mild pallor, and no obscuration of retinal blood vessels. **B**, Visual field patterns confirmed the presence of a nasal step produced by drusen involving the right ONH. **C**, B-scan ultrasonogram demonstrates highly reflective (due to calcification) focal elevation within the ONH (*arrow*) that persisted when the gain was decreased. **D**, Preinjection fundus photograph demonstrates autofluorescence (*arrow*). **E**, CT scan of the orbits. Calcified ODD are visible bilaterally at the posterior globe–optic nerve junction (*arrows*). (Part A courtesy of Steven A. Newman, MD; part B courtesy of Michael S. Lee, MD; parts C and E courtesy of Anthony C. Arnold, MD; part D courtesy of Hal Shaw, MD.)

Blurring of the margin between the ONH and the retina arises from axoplasmic stasis in the axons deep within the ONH, which creates a hazy, yellowish appearance that obscures the border but leaves the view of the retinal vessels intact. This contrasts with the fluffy, striated, whitish appearance of RNFL edema in true papilledema. In addition, with ODD, the ONH does not show hyperemia or dilation of the surface microvasculature.

In children, ODD are initially buried, becoming more visible over the years. Once visible, ODD appear as round, whitish-yellow refractile bodies. Frequently present at the nasal ONH margin, surface drusen may have a scalloped appearance. Occasionally, they are located within the RNFL just adjacent to the ONH.

To differentiate ODD from ONH edema (eg, papilledema), ancillary testing may be useful (see Fig 4-23):

- *B-scan ultrasonography* may differentiate calcified drusen from papilledema in 2 ways. First, ODD are highly reflective. Calcified drusen maintain this high echogenicity with lowering of the ultrasound gain (see Fig 4-23C). In contrast, with papilledema, the signal intensity decreases along with the remainder of the ocular signal. Of note, although ultrasonography may help identify drusen in suspected cases, this technique may not detect noncalcified, buried ODD. Second, with papilledema, the intraorbital portion of the optic nerve is typically widened and decreases in width with prolonged lateral gaze (*30° test*), whereas ODD do not produce widening of the intraorbital nerve.
- *Autofluorescence* is also effective for identifying ODD. On preinjection images using the fluorescein filter, refractile drusen that are close enough to the ONH surface demonstrate autofluorescence, in which refractile bodies are brightly visible (see Fig 4-23D).
- *Fluorescein angiography* may show early diffuse hyperfluorescence in true ONH edema, with late leakage overlying and adjacent to the ONH. Conversely, ODD do not cause leakage. However, in cases where ODD are associated with ONH edema, there may be leakage on fluorescein angiography.
- *Neuroimaging* may be indicated in rare cases to rule out an intracranial or optic nerve tumor and to attempt direct confirmation of calcified drusen. CT is superior to MRI for detection of drusen because calcium is poorly imaged by MRI. On CT, calcified drusen produce a bright, easily detected signal at the junction site of the globe and optic nerve (see Fig 4-23E).
- *OCT* using a line scan through the optic nerve can show discrete hyperreflective drusen. Although newer OCT techniques, such as enhanced depth imaging (EDI), offer improved images of drusen, this is not evident in all cases.

With chronic papilledema, refractile bodies occasionally develop on the ONH surface, simulating ODD (see Fig 4-8). These lesions (probably residual exudate) typically form near the temporal margin of the ONH rather than within its substance, are usually smaller than ODD, and disappear with resolution of the papilledema.

Astrocytic hamartomas of the retina, most common in tuberous sclerosis and NF, may take the form of so-called mulberry lesions. When located adjacent to the ONH, they

may closely resemble ODD (and were initially termed *giant drusen of the optic disc*) (see Fig 4-5D). However, in contrast to true ODD, ONH hamartomas

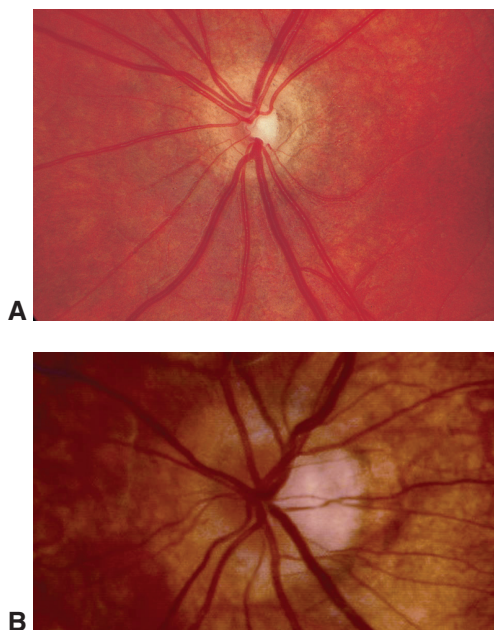
- originate at the ONH margin, with extension to the peripapillary retina
- arise in the inner retinal layers and typically obscure retinal vessels
- may have a fleshy, pinkish component
- do not autofluoresce and may show tumorlike vascularity on fluorescein angiography

Auw-Haendrich C, Staubach F, Witschel H. Optic disk drusen. *Surv Ophthalmol.* 2002;47(6):515–532.

### ***Congenital optic nerve head anomalies***

**Optic nerve hypoplasia** Visual acuity in eyes with optic nerve hypoplasia ranges from 20/15 with minimal visual field defects to no light perception. However, nearly all eyes affected by this condition have visual field loss, and 56%–92% of patients have bilateral involvement. The ONH is small, usually one-half to one-third of normal diameter; subtle cases may require a comparison of the 2 eyes. In addition, retinal vessel diameter may seem large relative to ONH size, and the vessels may appear tortuous. The ONH may be pale, gray, or (less commonly) hyperemic and may be surrounded by a yellow peripapillary halo, which in turn is bordered by a ring of increased or decreased pigmentation (the *double-ring sign*) (Fig 4-24).

Unilateral or bilateral optic nerve hypoplasia may be associated with midline or hemispheric brain defects, endocrinologic abnormalities (deficiency of growth hormone and other pituitary hormones), and congenital suprasellar tumors. Skull-base defects may be associated with basal encephaloceles. The syndrome of optic nerve hypoplasia, absent



**Figure 4-24** Optic nerve hypoplasia. **A and B,** In these images from 2 patients, the small ONH is surrounded by a relatively hypopigmented ring of tissue (double-ring sign). The retinal vessels have a normal appearance. (Part A reprinted from Kline LB, Foroozan R, eds. *Optic Nerve Disorders*. 2nd ed. *Ophthalmology Monographs* 10. Oxford University Press, in cooperation with the American Academy of Ophthalmology; 2007:158. Part B courtesy of Gregory Van Stavern, MD.)

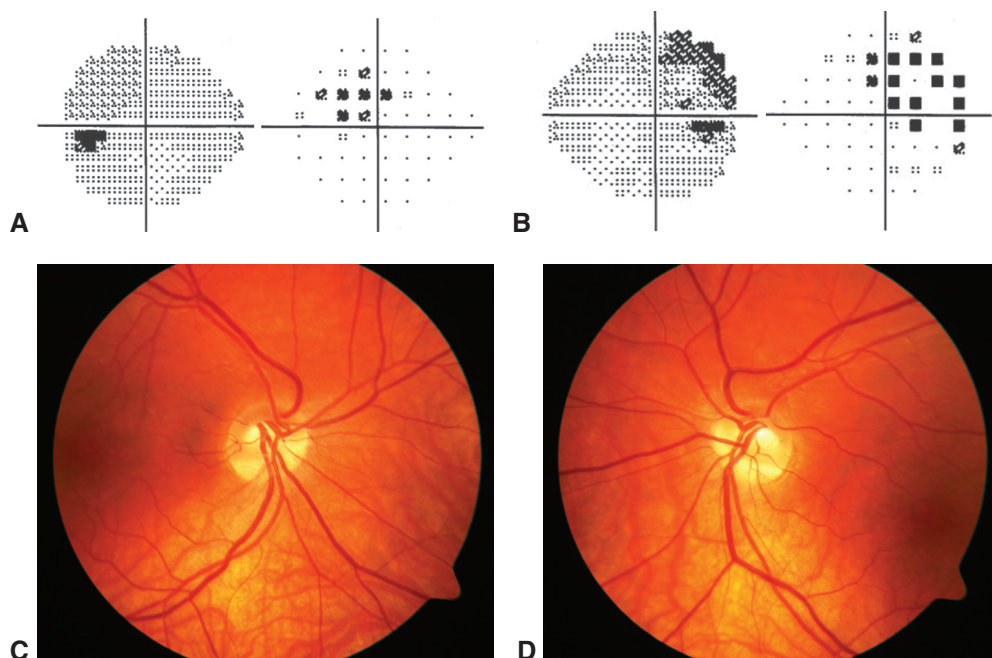


septum pellucidum, and hypothalamic-pituitary axis dysfunction (*septo-optic dysplasia*, or *de Morsier syndrome*) is most common. The corpus callosum may be thinned or absent. A variant called *superior segment hypoplasia* occurs most often in children of mothers with diabetes mellitus; the affected eyes have a corresponding inferior visual field defect. Recognized teratogens associated with optic nerve hypoplasia include quinine, ethanol, and anticonvulsants.

Comparing the horizontal ONH diameter with the ONH–macula distance may help in detecting optic nerve hypoplasia. MRI is recommended in all cases, and endocrinologic evaluation is necessary because hypoglycemic seizures or growth retardation may develop without appropriate treatment.

For further details on optic nerve hypoplasia, see BCSC Section 6, *Pediatric Ophthalmology and Strabismus*.

**Tilted disc syndrome** Congenital tilted disc syndrome is usually bilateral (in up to 80% of patients) and should not be confused with simple myopic tilted ONHs with temporal crescent. The congenital syndrome produces an inferonasal colobomatous excavation of the nerve tissue, often associated with thinning of adjacent RPE and choroid. The remaining superotemporal portion of the ONH remains relatively intact, making the ONH appear tilted around a predominantly horizontal axis. The superior portion can sometimes seem elevated, simulating mild ONH edema (Fig 4-25). The retinal vessels are often nasalized.



**Figure 4-25** Congenital tilted disc syndrome. **A and B**, Visual field testing shows bilateral relative superotemporal defects that do not respect the vertical midline. Fundus photographs show tilted discs in the right eye (**C**) and in the left eye (**D**). (Parts A and B courtesy of Anthony C. Arnold, MD; parts C and D courtesy of Sophia M. Chung, MD.)

The visual field defects may mimic those of chiasmal compression but are differentiated by their failure to respect the vertical midline and their partial improvement with myopic refractive correction.

**Excavated optic nerve head anomalies** Excavated ONH anomalies cover a spectrum of severity, ranging from optic nerve pits through colobomas and dysplastic nerves to the morning glory syndrome:

- An *optic nerve pit* is a depression of the ONH surface that is often gray, yellowish, or white, located inferotemporally, and associated with a mild visual field defect (usually paracentral or arcuate). Serous detachment of the macula develops in 25%–75% of cases, possibly related to liquefied vitreous entering the subretinal space through communication between the optic nerve pit and the macula.
- *Colobomas* of the nerve result from incomplete closure of the embryonic fissure and usually occur inferiorly; they occasionally extend to the adjacent choroid and retina. Visual field defects and an RAPD can occur, depending on the degree of abnormality. Colobomas of other structures, such as the iris and choroid, may also be present.
- The *dysplastic nerve* of papillorenal syndrome or renal coloboma syndrome appears excavated with absence or attenuation of the central retinal vessels and multiple cilioretinal vessels emanating and exiting from the ONH edge. Visual acuity is often normal, but perimetry may reflect superonasal visual field defects. Controversy exists regarding whether the nerves are colobomatous from incomplete embryonic fissure closure or from a primary dysplasia of the optic nerve. This characteristic optic nerve appearance may indicate renal failure secondary to renal hypoplasia and is linked to mutations in the *PAX2* gene (which are autosomal dominant).
- The *morning glory syndrome* is a funnel-shaped staphylomatous excavation of the optic nerve and peripapillary retina. It is more common in females and is usually unilateral. The ONH is enlarged, pink or orange, and either elevated or recessed within the staphyloma. Chorioretinal pigmentation surrounds the excavation, and white glial tissue is present on the central ONH surface. The characteristic feature is the emanation of retinal vessels from the periphery of the ONH. Visual acuity can be normal but is often 20/200 or worse and accompanied by an RAPD. Nonrhegmatogenous serous retinal detachments occur in approximately a third of cases. Neuroimaging is warranted to evaluate for a basal encephalocele and CNS vascular anomalies.

For additional discussion, see BCSC Section 6, *Pediatric Ophthalmology and Strabismus*.

Brodsky MC. Congenital optic disk anomalies. *Surv Ophthalmol*. 1994;39(2):89–112.

Lee BJ, Traboulsi EI. Update on the morning glory disc anomaly. *Ophthalmic Genet*. 2008;29(2):47–52.

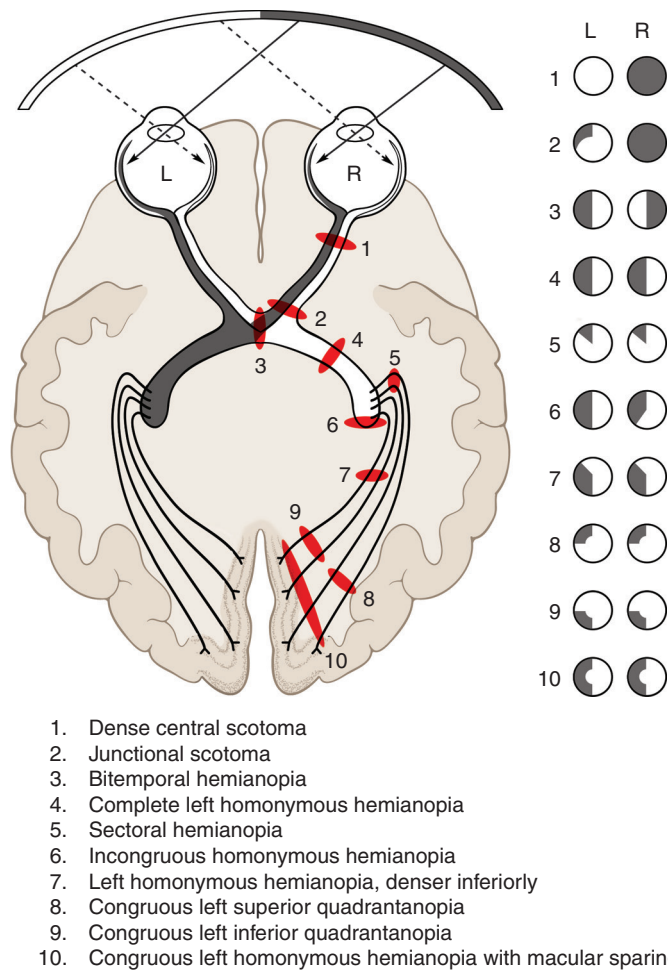
Nicholson B, Ahmad B, Sears JE. Congenital optic nerve malformations. *Int Ophthalmol Clin*. 2011;51(1):49–76.

# Chiasmal Lesions

Because nasal and temporal retinal fibers are segregated at the chiasm, visual field loss due to chiasmal and retrochiasmal lesions is characterized by defects that align along the vertical meridian. Compressive lesions are the most common cause of chiasmal injury. The most common visual field defect of chiasmal compression is a bitemporal hemianopia. The hemianopia may appear relative or complete. It may involve only the paracentral temporal field, with visual acuity often not affected until late (Fig 4-26; Activity 4-1).



**ACTIVITY 4-1** Visual pathways.  
*Developed by Gregory Van Stavern, MD. Illustration by Christine Gralapp.*



**Figure 4-26** Schematic illustration of the visual pathways with numbered locations of the most common visual pathway lesions. The visual field patterns shown on the right represent potential findings corresponding to lesions of the same number shown along the visual pathways. (Illustration by Christine Gralapp.)

In chiasmal syndromes, the ONHs may appear normal initially, even with significant visual field loss. Early on, pRNFL dropout and mild ONH pallor develop. With progressive damage, the ONHs show typical atrophy, often in the temporal portion, and cupping may increase. A tumor compressing the chiasm almost never produces ONH edema. Lesions that involve the chiasm—whether compressive or infiltrative—result in gradually progressive, bilateral, often asymmetric vision loss. The peripheral (temporal) visual fields are usually involved first.

Bilateral visual field defects can be caused by a lesion involving the chiasm. The clinician must carefully evaluate perimetry testing results for respect of the vertical midline. Any of the variations on bitemporal visual field loss described in the following sections may occur. An affected optic nerve may cause reduced visual acuity, dyschromatopsia, and an RAPD on the affected side. Markedly asymmetric visual field loss without direct optic nerve damage may also produce an RAPD. OCT shows loss of pRNFL and GC-IPL thickness, with GC-IPL thinning sometimes developing before the pRNFL thinning.

### Visual Field Loss Patterns

Lesions that injure an optic nerve at its junction with the optic chiasm cause *junctional scotomas* (presumably due to disruption of fibers within Wilbrand knee). Diminished visual acuity and central visual field loss occur in the ipsilateral eye, and a temporal hemianopia develops in the opposite eye (Fig 4-27). A unilateral temporal hemianopia that respects the vertical midline, with no involvement of the visual field in the opposite eye (also known as a *junctional scotoma of Traquair*), can also indicate a chiasmal abnormality. Presumably, the mass compresses only the crossing nasal fibers from 1 eye.

### Etiology of Chiasmal Disorders

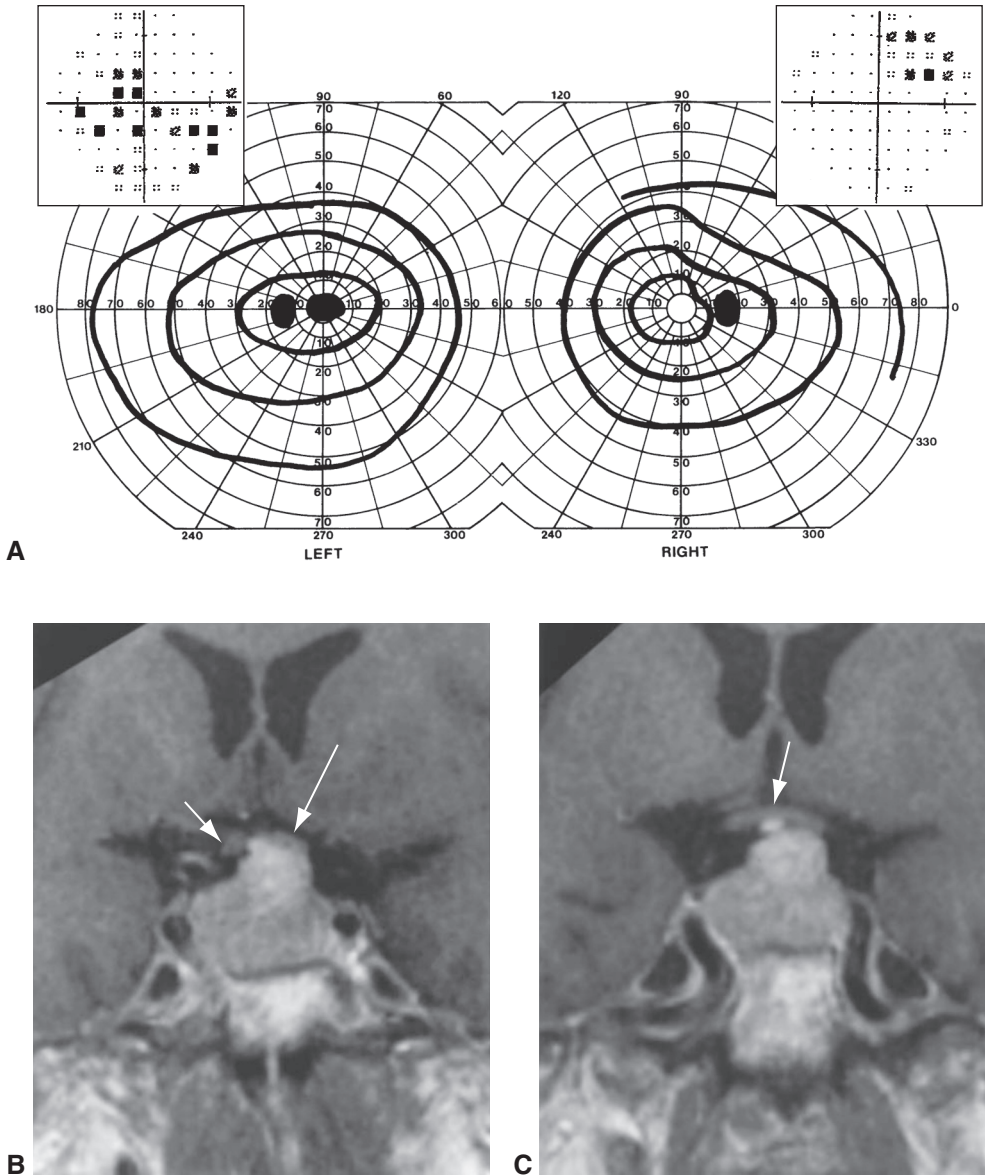
Lesions of the chiasm can be either extrinsic or intrinsic.

#### Extrinsic lesions

The most common lesions producing a chiasmal syndrome include pituitary adenoma (Fig 4-28), parasellar meningioma, craniopharyngioma, and parasellar internal carotid artery aneurysm. Other CNS mass lesions can produce third-ventricle dilation and secondary posterior chiasmal compression.

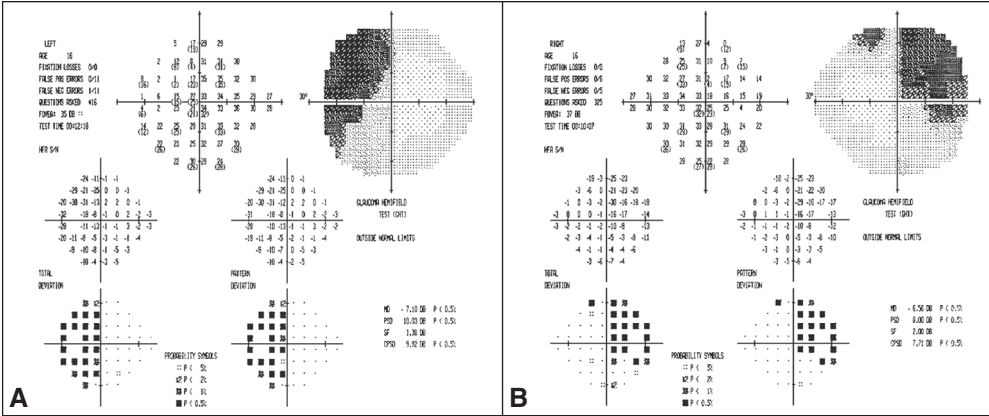
**Pituitary adenomas** These are the most common cause of chiasmal compression and may occur at any age, although they are rare in childhood. Patients with nonsecreting tumors typically present with vision loss, their tumors having reached a relatively large size without causing other symptoms. Tumors that actively secrete hormones (such as prolactin or growth hormone) are often detected before vision loss occurs because of their systemic endocrine symptoms. For example, pituitary tumors may enlarge during pregnancy and produce chiasmal compression.

Acute hemorrhage or infarction of a pituitary tumor, known as *pituitary apoplexy*, is a potentially life-threatening event heralded by severe headache, nausea, and altered consciousness (Fig 4-29). Neuro-ophthalmic findings include diplopia and loss of vision or visual field. Sudden expansion of the tumor into the adjacent cavernous sinuses can

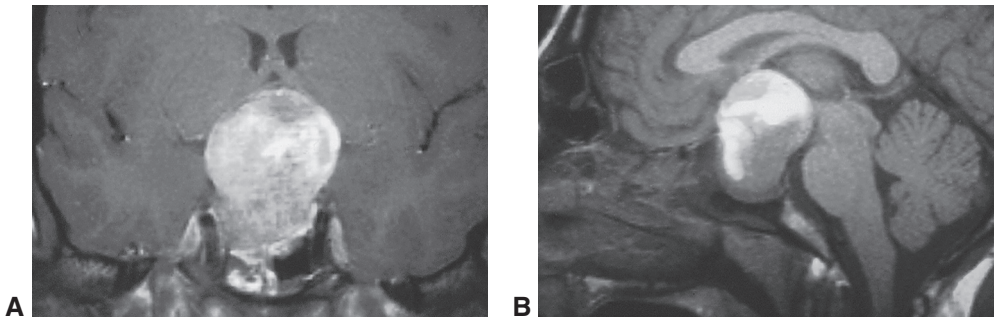


**Figure 4-27** Junctional scotoma. **A**, Visual field patterns from kinetic perimetry testing and Humphrey 30-2 program testing (*insets*). Note the central scotoma in the patient's left eye along with the superotemporal depression in the right eye. **B and C**, Postcontrast-enhanced T1-weighted (time to repetition=650 ms; time to echo=14 ms) MRI scans using a slice thickness of 3 mm. **B**, Coronal image of a section in front of the optic chiasm showing a tumor compressing the prechiasmal segment of the left optic nerve (*long arrow*) but not the right optic nerve (*short arrow*). **C**, Coronal image at the level of the optic chiasm showing minimal rostral displacement (*arrow*) but no notable direct mass effect. (Reprinted from Karanjia N, Jacobson DM. Compression of the prechiasmal optic nerve produces a junctional scotoma. *Am J Ophthalmol*. 1999;128(2):256–258, with permission from Elsevier.)





**Figure 4-28** Pituitary adenoma. **A and B**, Visual field patterns from a patient with a pituitary tumor, showing bitemporal depression that is worse superiorly, with margination along the vertical midline. **C**, T1-weighted coronal MRI scan shows an intrasellar enhancing mass with extension into the suprasellar cistern and upward displacement and compression of the chiasm (arrow). (Parts A and B courtesy of Steven A. Newman, MD; part C courtesy of Sophia M. Chung, MD.)



**Figure 4-29** Pituitary apoplexy. Coronal (**A**) and sagittal (**B**) MRI scans show a large pituitary tumor with suprasellar extension. Inhomogeneity within the tumor represents hemorrhage and infarction. (Courtesy of Steven A. Newman, MD.)

cause dysfunction of CNs III, IV, V, and VI (CN III is most commonly affected). Superior extension causes severe vision loss ranging from normal visual acuity with bitemporal hemianopia to no light perception. Extravasation of blood into the subarachnoid space causes numerous symptoms, including a decreased level of consciousness and vasospasm with secondary stroke. Acute endocrine abnormalities may lead to numerous complications, including adrenal crisis. Therefore, recognition of pituitary apoplexy is crucial so that neurosurgical treatment can be initiated promptly.

**Parasellar meningiomas** These lesions occur most often in middle-aged women. They frequently arise from the tuberculum sellae, planum sphenoidale, or anterior clinoid. Most often, they cause asymmetric bitemporal vision loss. During pregnancy, parasellar meningiomas may enlarge, causing chiasmal compression.

**Craniopharyngiomas and internal carotid artery aneurysms** Craniopharyngiomas are common in children but may present at any age, with a second incidence peak in adulthood. Although these tumors often arise superiorly (ie, in the suprasellar or suprachiasmatic space), they commonly cause *inferior* bitemporal visual field loss. Craniopharyngiomas may be more difficult to completely resect than macroadenomas, and they have a higher risk of recurrence.

Internal carotid artery aneurysms, particularly in the supraclinoid region, may produce a markedly asymmetric chiasmal syndrome, with optic nerve compression on the side of the aneurysm.

**Treatment** Treatment of parasellar tumors is complex and depends on the patient's age; the nature, location, and extent of the tumor; its hormonal activity; and symptom severity, particularly the extent of vision loss. Treatments include

- observation only, if visual field is normal
- surgery (usually transsphenoidal procedure or craniectomy)
- medical therapy (primarily bromocriptine or cabergoline for prolactin-secreting pituitary tumors)
- radiation therapy (as either primary or adjunctive therapy for incompletely resectable tumors)

With surgical resection of the tumor and relief of anterior visual pathway compression, vision recovery is usually rapid and may be dramatic, even in patients who experienced severe vision loss. Medical therapy for pituitary adenomas has a more gradual effect, taking days to weeks, but it also shrinks the tumor and improves visual function in responsive cases. Prognosis is poor if mean pRNFL thickness on OCT scans is less than 75  $\mu\text{m}$  (see Chapter 3, Fig 3-17).

The ophthalmologist's role in managing sellar and parasellar tumors is crucial, because vision loss may be the first sign of recurrence. Visual field, visual acuity, and color vision testing should be performed 2–3 months after treatment and at intervals of 6–12 months thereafter, depending on the course. Visual acuity and visual fields should be rechecked more often if the patient reports any ongoing change. Periodic neuroimaging is essential.

Delayed vision loss after therapy for sellar/parasellar lesions should prompt the following considerations:

- tumor recurrence
- delayed radionecrosis
- chiasmal distortion due to adhesions or secondary empty sella syndrome with descent and traction on the chiasm
- chiasmal compression from expansion of fat overpacked in the sella intraoperatively

Neuroimaging effectively helps differentiate among these extrinsic lesions and guides further management.

Bresson D, Herman P, Polivka M, Froelich S. Sellar lesions/pathology. *Otolaryngol Clin North Am.* 2016;49(1):63–93.

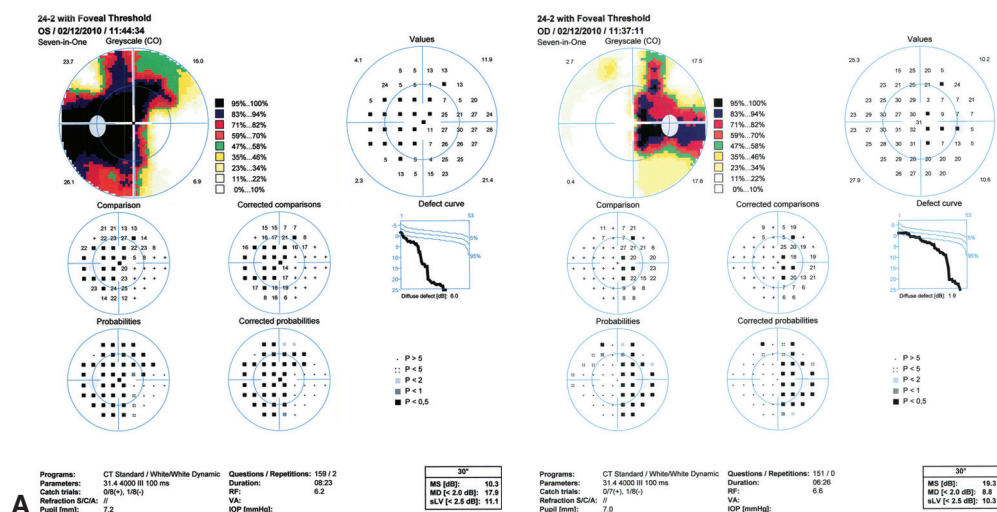
Danesh-Meyer HV, Papchenko T, Savino PJ, Law A, Evans J, Gamble GD. In vivo retinal nerve fiber layer thickness measured by optical coherence tomography predicts visual recovery after surgery for parasellar tumors. *Invest Ophthalmol Vis Sci.* 2008;49(5):1879–1885.

Farrell CJ, Nyquist GG, Farag AA, Rosen MR, Evans JJ. Principles of pituitary surgery. *Otolaryngol Clin North Am.* 2016;49(1):95–106.

Fraser CL, Biousse V, Newman NJ. Visual outcomes after treatment of pituitary adenomas. *Neurosurg Clin N Am.* 2012;23(4):607–619.

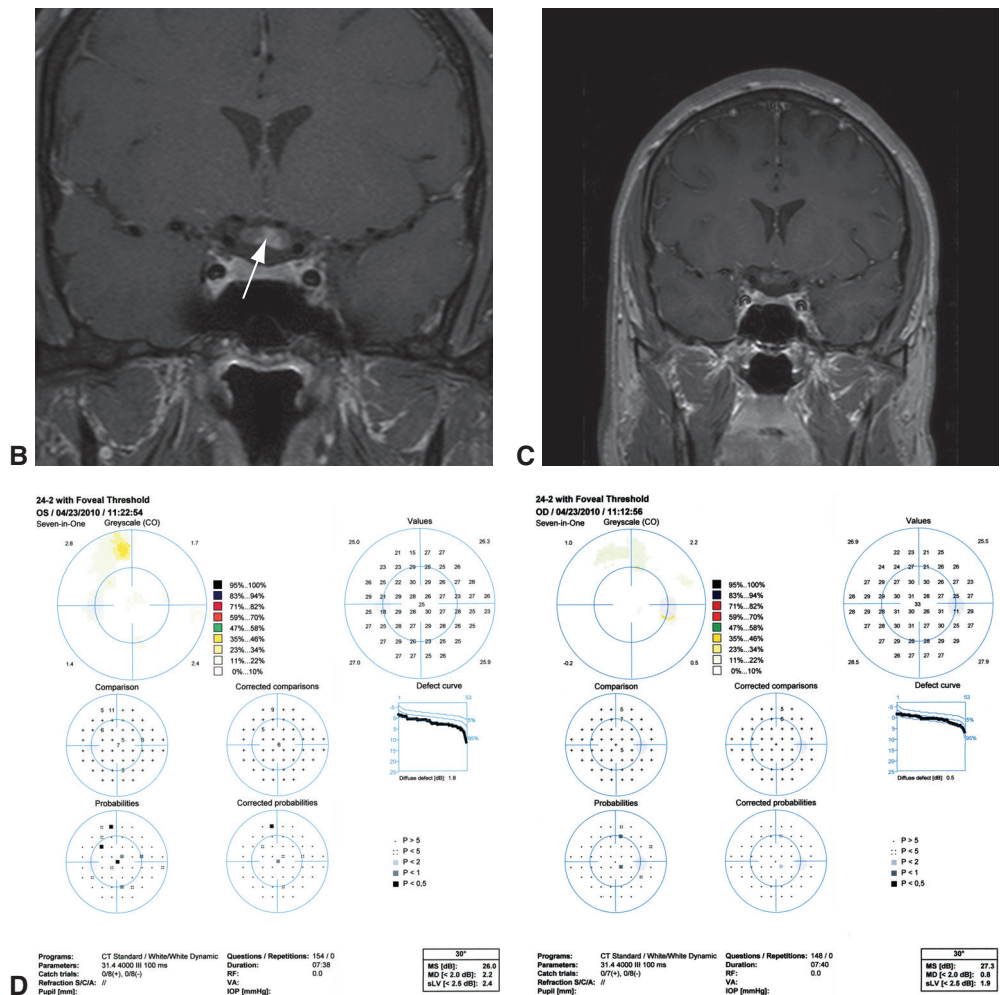
### Intrinsic lesions

Other, infrequent causes of chiasmal disorders include infections (eg, tuberculosis, Lyme disease) and inflammation (eg, sarcoidosis, MS) (Fig 4-30), as well as neoplasms, which



**Figure 4-30** Chiasmal neuritis in a 36-year-old man with sudden-onset visual changes in both eyes. **A**, Visual field testing shows a “junctional scotoma” with a central visual field defect in the left eye (*left panel*) and a temporal hemianopic defect in the right eye (*right panel*).

(Continued)



**Figure 4-30 (continued)** **B**, T1-weighted coronal, postgadolinium MRI scan shows enhancement (arrow) of predominantly the left side of the chiasm. **C**, Follow-up MRI scan depicts resolution of the enhancement shown in **B**. **D**, Repeated visual field testing shows substantial improvement in both eyes. (Courtesy of Julie Falardeau, MD.)

can be either primary (eg, OPGs) or secondary (eg, metastasis). In addition, significant closed-head trauma can injure the optic chiasm, causing a bitemporal hemianopia. Para-sellar radiation therapy can also affect this site. In contrast, ischemia of the chiasm is very uncommon because of its robust collateral blood supply.

# The Patient With Visual Dysfunction Due to Retrochiasmal Disease

### Highlights

---

- Certain characteristics of visual field defects can localize pathology to a specific region of the retrochiasmal visual pathway and lead to a targeted workup.
- Retrochiasmal lesions result in visual field defects that respect the vertical meridian.
- Cortical visual impairment can be the initial manifestation of neurodegenerative disorders, such as Alzheimer disease.
- Diagnosis of retrochiasmal visual dysfunction may be delayed, and patients may undergo unnecessary treatments and procedures.

### Introduction

---

The initial goal in the assessment of reduced vision in any patient is to localize the cause of vision loss to a specific part of the visual pathway(s). Decreased vision may arise from refractive errors or from abnormalities in the ocular media, retina, and anterior and posterior visual pathways. Evaluation of the patient with vision loss requires consideration of the clinical history together with results of the examination and ancillary testing, as outlined in Chapter 3, to determine causation and management. Chapter 4 discusses diseases of the retina, optic nerve, and chiasm. This chapter discusses diseases involving the posterior, or *retrochiasmal*, visual pathway, which begins with the optic tract and ends in the visual cortex and its associated areas.

### Retrochiasmal Lesions

---

The retrochiasmal pathway begins posterior to the optic chiasm and consists of the following:

- optic tract
- lateral geniculate nucleus (LGN; also called lateral geniculate body)



- optic radiations of the temporal, parietal, and occipital lobes
- visual cortex and its associated areas

Within the chiasm, fibers from the nasal retina cross to the opposite side to join the corresponding contralateral fibers (see Chapter 1). Thus, retrochiasmal damage results in homonymous visual field defects that respect the vertical midline. As the fibers travel posteriorly along the retrochiasmal pathway, those from corresponding retinal regions of each eye tend to run increasingly closer together. If the corresponding fibers from the 2 eyes are close to each other, the visual field defect in each eye is identical, or *congruous*. Hence, lesions of the optic radiations classically produce dissimilar (*incongruous*) homonymous visual field defects, and more posterior lesions result in more similar homonymous defects. Although a highly congruous homonymous hemianopia might be expected to reflect occipital disease, the possibility of a more anterior lesion involving the optic tract or the LGN cannot be excluded. Lesions severe enough to produce complete hemianopic defects may occur at any anteroposterior retrochiasmal location. A complete homonymous hemianopia thus suggests a lesion located anywhere from the contralateral optic tract to the occipital cortex. Stroke is the most common cause of homonymous hemianopias, followed by traumatic brain injury and tumor.

Kedar S, Zhang X, Lynn MJ, Newman NJ, Biousse V. Congruency in homonymous hemianopia. *Am J Ophthalmol*. 2007;143(5):772–780.

Zhang X, Kedar S, Lynn MJ, Newman NJ, Biousse V. Homonymous hemianopias: clinical-anatomic correlations in 904 cases. *Neurology*. 2006;66(6):906–910.

## Optic Tract

Lesions of the optic tract cause homonymous defects in the hemifields contralateral to the affected optic tract (see Chapter 4, Fig 4-26). Damage to the optic tract often results from mass lesions such as aneurysms or tumors. These lesions may be associated with an ipsilateral relative afferent pupillary defect (RAPD) when the optic nerve is also involved (involvement of only the optic tract is discussed below). Inflammatory and demyelinating lesions occasionally occur. Ischemic lesions of the optic tract are uncommon and result from occlusion of the anterior choroidal artery. Because the fibers involved are primary neurons and axons in the visual pathway (ie, retinal ganglion cells), the homonymous hemianopic visual field loss due to isolated optic tract disease is accompanied by other findings, which together make up the *optic tract syndrome*:

- “Bow-tie” *optic atrophy*. Because the optic tract carries crossed fibers from the contralateral eye, the corresponding chronic atrophy of crossed retinal fibers (those nasal to the fovea) involves the papillomacular fibers and the nasal radiating fibers in the contralateral eye, causing atrophy in the corresponding nasal and temporal horizontal portions of the optic nerve head (ONH), known as band or bow-tie atrophy (see Chapter 1, Fig 1-22). Chronic atrophy in the ipsilateral eye involves only the arcuate temporal bundles, which enter the ONH at the superior and inferior poles, giving the appearance of vertical bow-tie atrophy.

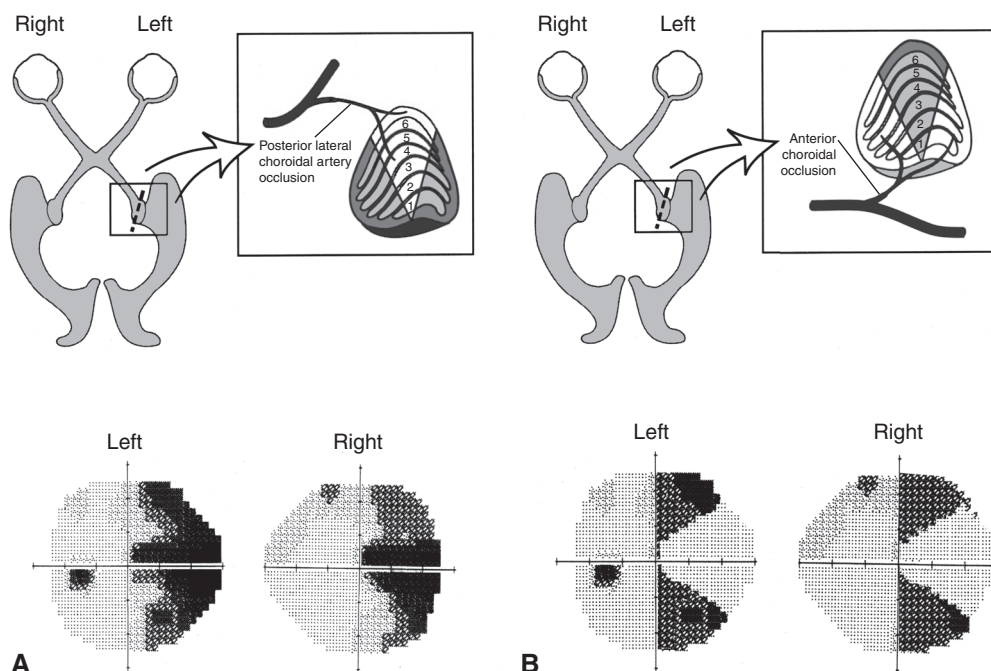
- *Mild RAPD in the contralateral eye.* This finding stems from the greater sensitivity of the nasal retina compared with the temporal retina and the presence of more crossed than uncrossed pupillary fibers in the optic tract, which causes more pupillary fibers from the contralateral eye to be damaged by an optic tract lesion.

Kardon R, Kawasaki A, Miller NR. Origin of the relative afferent pupillary defect in optic tract lesions. *Ophthalmology*. 2006;113(8):1345–1353.

Savino PJ, Paris M, Schatz NJ, Orr LS, Corbett JJ. Optic tract syndrome. A review of 21 patients. *Arch Ophthalmol*. 1978;96(4):656–663.

## Lateral Geniculate Nucleus

The LGN is a highly organized and layered retinotopic structure; therefore, lesions in this region can cause highly localized visual field defects. For example, disruption within the vascular distribution of the posterior lateral choroidal artery, a branch of the posterior cerebral artery, results in a congruous horizontal sectoranopia. Disruption of the anterior choroidal artery, a branch of the middle cerebral artery (Fig 5-1; also see Chapter 1, Fig 1-13), causes



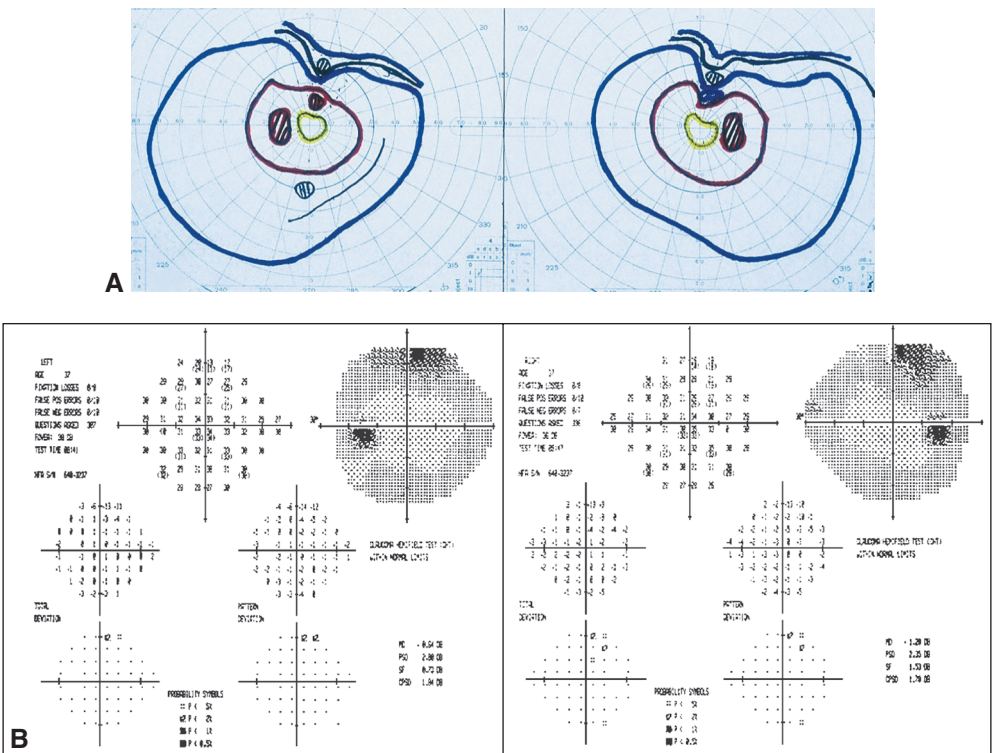
**Figure 5-1** Visual fields obtained with automated perimetry show defects resulting from lesions occurring in the region of the lateral geniculate nucleus. **A**, A central wedge-shaped homonymous sectoranopia caused by posterior lateral choroidal artery occlusion. **B**, Loss of the upper and lower homonymous quadrants, with preservation of the horizontal wedge resulting from occlusion of the anterior choroidal artery. (Reproduced with permission from Trobe JD. *The Neurology of Vision*. Contemporary Neurology Series. Oxford University Press; 2001:130. Reproduced with permission of the licensor through PLSclear.)

loss of the upper and lower homonymous quadrants (known as *quadruple sectoranopia*) with preservation of a horizontal wedge. Unlike the uncommon wedge defect observed in glaucoma, these visual field defects respect the vertical meridian. LGN lesions can also result in sectoral optic atrophy, and in rare cases, bilateral LGN lesions cause blindness.

Luco C, Hoppe A, Schweitzer M, Vicuña X, Fantin A. Visual field defects in vascular lesions of the lateral geniculate body. *J Neurol Neurosurg Psychiatry*. 1992;55(1):12–15.

### Optic Radiations of the Temporal Lobe

From the LGN, inferior visual fibers first course anteriorly and then laterally and posteriorly to the *Meyer loop* of the temporal lobe (approximately 2.5 cm from the anterior tip of the temporal lobe). Superior fibers course more directly posteriorly in the parietal lobe. Lesions affecting the Meyer loop thus produce superior incongruous homonymous visual field defects contralateral to the lesion. These defects (so-called *pie in the sky* defects) spare fixation (Fig 5-2; also see Chapter 4, Fig 4-26). Damage to the temporal lobe anterior to the Meyer loop does not cause visual field loss. Lesions affecting the radiations posterior to the loop produce homonymous hemianopic defects that extend inferiorly.



**Figure 5-2** Visual field patterns after partial left temporal lobectomy for seizure disorder. **A**, Kinetic perimetry results show a predominantly peripheral right superior homonymous quadrantanopia that spares fixation. **B**, Automated 30-2 perimetry testing detects a minimal portion of the visual field defects. (Courtesy of Steven A. Newman, MD.)

Tumors within the temporal lobe are a common cause of visual field loss. Neurologic findings for temporal lobe lesions include seizure activity, including olfactory seizures and formed visual hallucinations. Surgical excision of seizure foci in the temporal lobes may also lead to visual field defects.

### **Optic Radiations of the Parietal Lobe**

Lesions of the parietal lobe, which often result from stroke or neoplasms, tend to involve superior fibers first, causing contralateral inferior homonymous hemianopic defects. More extensive lesions affect the superior visual fields but remain denser inferiorly. Parietal lobe syndromes encompass a wide variety of other neurologic effects, including perceptual problems (agnosia) and apraxia. Lesions of the dominant parietal lobe cause Gerstmann syndrome, a combination of acalculia, agraphia, finger agnosia, and left–right confusion. Lesions in the nondominant parietal lobe can cause contralateral hemispatial neglect (see Chapter 7).

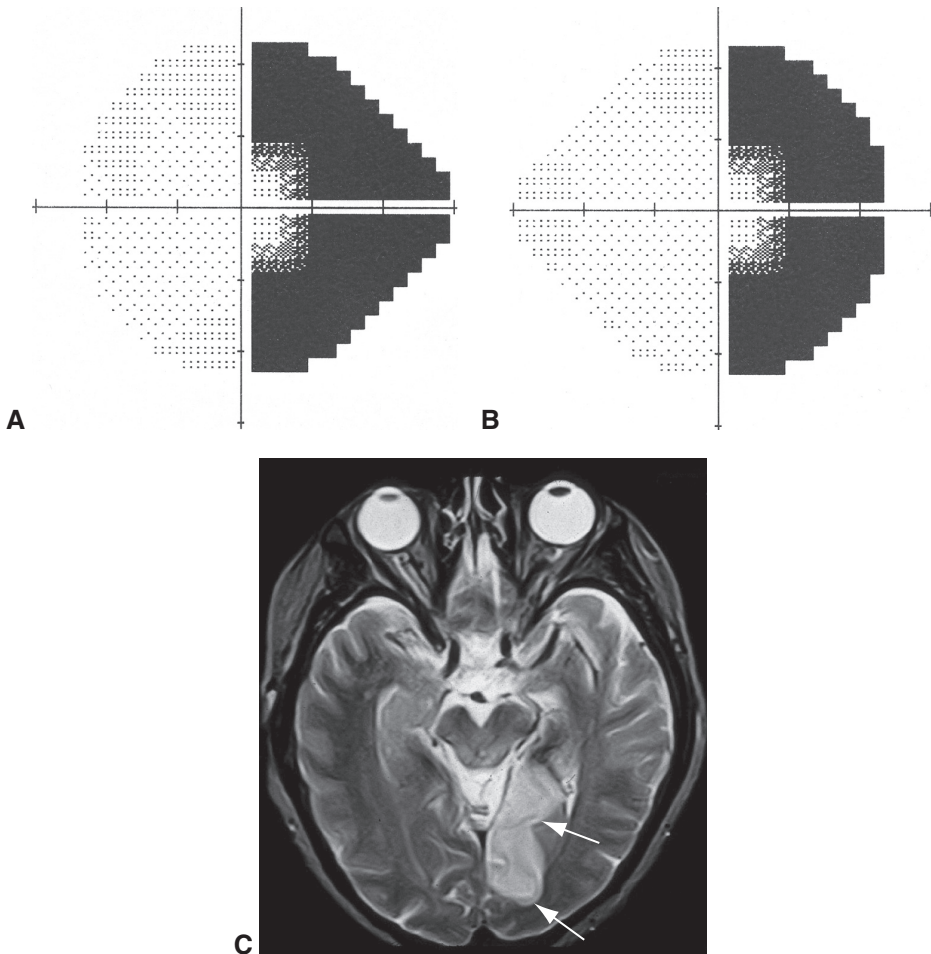
Damage to pursuit pathways that converge in the posterior parietal lobes (near the optic radiations) may cause abnormalities in optokinetic nystagmus (OKN). The examiner can elicit an impaired OKN response by moving targets toward the side of the lesion, inducing attempts to use the damaged pursuit pathway. Thus, a patient with a homonymous hemianopia due to a parietal lobe lesion will have a reduced OKN response with the target moving toward the affected side, whereas a patient with a homonymous hemianopia due to a lesion of the optic tract or occipital lobe will have an intact OKN response (see Chapter 9).

### **Optic Radiations of the Occipital Lobe**

As the visual fibers approach the occipital lobes, the congruity of visual field defects produced by lesions in this area becomes an important characteristic of these defects. The central fibers become separate from the peripheral fibers and course to the occipital tip, whereas the peripheral fibers travel to the anteromedial cortex. Furthermore, there is cortical magnification of the area that corresponds to central vision in the posterior part of the striate cortex; the central 10° of visual field corresponds to approximately 50%–60% of the visual cortex that extends from the posterior portion of the medial area to the occipital tip.

Because of the disparity in the number of crossed versus uncrossed fibers, some of the peripheral nasal fibers leading to the anteromedial region are not matched with the corresponding uncrossed fibers. Consequently, the anteromedial region of the occipital lobe subserves a monocular “temporal crescent” of visual field in the far periphery (60°–90° from fixation). Finally, fibers within the occipital cortex are located superior and inferior to the calcarine fissure. Thus, visual field defects resulting from occipital lobe lesions may have the following characteristics in the hemifields contralateral to the lesion:

- congruous homonymous hemianopia, possibly sparing the fixation region (Fig 5-3; also see Chapter 4, Fig 4-26)
- monocular defect of the temporal crescent involving only the most anterior portion of the occipital lobe; best detected with kinetic perimetry testing



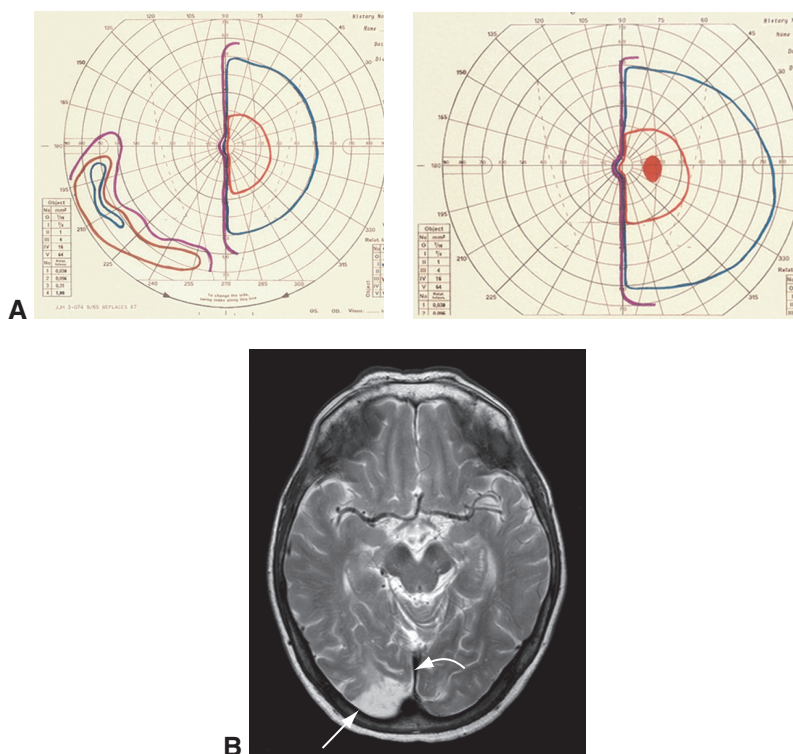
**Figure 5-3** Macula-sparing, congruous homonymous hemianopia due to occipital lobe infarction. **A and B**, Visual field patterns show a congruous right homonymous hemianopia respecting the vertical meridian and sparing fixation. **C**, Axial T2-weighted magnetic resonance imaging (MRI) shows left parieto-occipital stroke (arrows) sparing the occipital tip. (Parts A and B courtesy of Michael S. Lee, MD; part C courtesy of Steven A. Newman, MD.)

- homonymous defects sparing the temporal crescent in the eye contralateral to the lesion (Fig 5-4); best detected with kinetic perimetry testing
- homonymous quadrantanopia (superior or inferior) respecting the horizontal meridian

Most occipital lobe lesions result from stroke (infarction in the territory of the posterior cerebral artery) and cause no neurologic deficits other than vision loss.

A *macula-sparing homonymous hemianopia* suggests a stroke involving the portion of the primary visual cortex supplied by the posterior cerebral artery. The tip of the occipital lobe receives a dual blood supply from the middle cerebral artery and the posterior cerebral artery. Occlusion of the posterior cerebral artery damages the primary visual





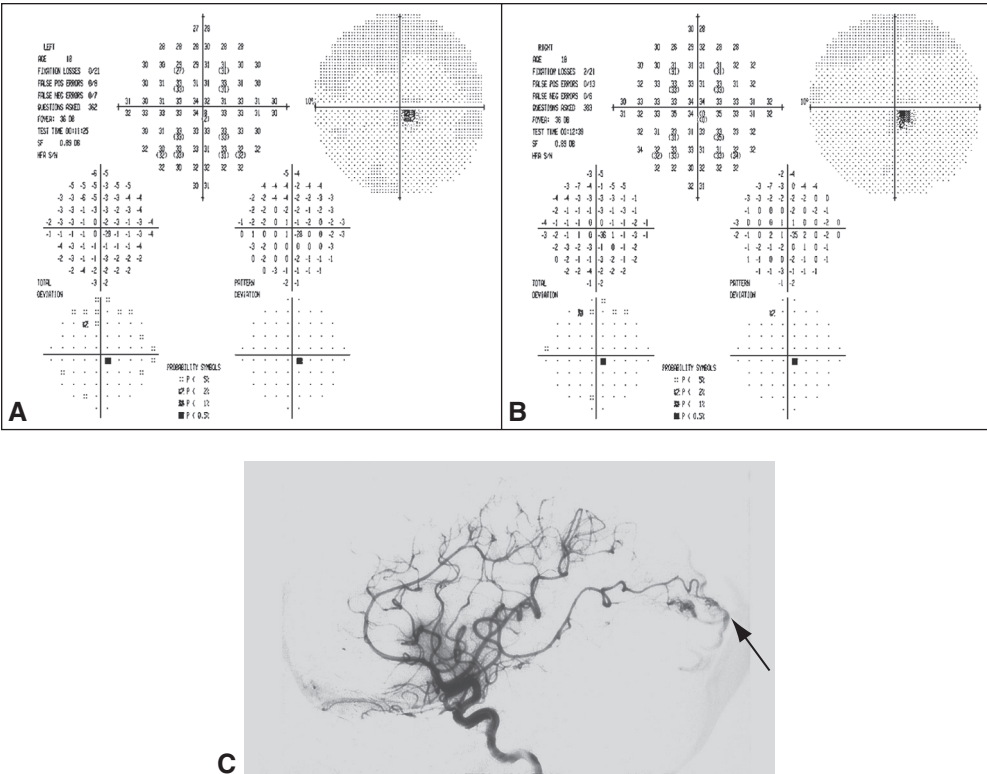
**Figure 5-4** A 60-year-old woman presented with 3 episodes of transient visual loss to the left side. Her visual acuity was 20/20 bilaterally, but visual field patterns demonstrated a left homonymous hemianopia (**A**). The temporal crescent was intact on the left side, and an MRI scan (**B**) confirmed the presence of a right occipital lobe lesion (*straight arrow*) resulting from a stroke, as well as sparing of the anterior visual cortex (*curved arrow*). (Part A courtesy of Steven A. Newman, MD; part B courtesy of Sophia M. Chung, MD.)

cortex, except for the region representing the macula at the posterior tip of the occipital lobe, which remains perfused by the middle cerebral artery.

Systemic hypoperfusion often damages the occipital tip because the tip sits in a watershed area supplied by distal branches of the posterior and middle cerebral artery systems. This highly vulnerable region may be the only injured area, causing homonymous hemianopic scotomata (Fig 5-5).

*Cerebral blindness* results from bilateral occipital lobe damage. Normal pupillary responses and optic nerve appearance distinguish cerebral blindness from total blindness caused by lesions anterior to the LGN. Anton syndrome (denial of blindness), though classically associated with cortical visual impairment (CVI; see the next section), can be due to a lesion at any level of the visual system that is severe enough to cause blindness (see Chapter 7). Infrequently, patients with bilateral occipital lobe lesions have some residual visual function.

Disturbances of the primary visual cortex due to neoplasms, migraine, or drugs may cause *unformed visual hallucinations*. *Formed hallucinations* are usually attributed to lesions of the extrastriate cortex or temporal lobe. Patients with injury to the occipital cortex sometimes perceive moving targets but not static ones. This *staticokinetic dissociation*



**Figure 5-5** An 18-year-old woman presented with an 8-day history of sharp, left-sided headaches. Visual acuity was 20/20 bilaterally, and she missed letters on the right side of the chart. **A and B**, Visual fields obtained with the Humphrey Field Analyzer 10-2 program demonstrate a tiny 2° homonymous scotoma just below and to the right of fixation in both eyes. **C**, The angiogram reveals an arteriovenous malformation involving the occipital tip (arrow). (Courtesy of Steven A. Newman, MD)

(also called Riddoch phenomenon), which may also occur with lesions in other parts of the visual pathway, probably stems from cells in the visual system responding better to moving stimuli than to those that are static. See Chapter 7 for additional discussion of hallucinations and disorders of higher cortical function.

Barton JJ. Higher cortical visual deficits. *Continuum (Minneapolis)*. 2014; 20(4 Neuro-ophthalmology):922–941.

Riddoch G. Dissociation of visual perceptions due to occipital injuries, with especial reference to appreciation of movement. *Brain*. 1917;40:15–57.

## Cortical Visual Impairment

Ophthalmologists frequently encounter patients with CVI. These patients often present with a variety of visual symptoms, such as cerebral alexia, visual agnosia, and visual-spatial dysfunction. Visual acuity is often relatively preserved, and the diagnosis of CVI may be

missed or delayed, frequently resulting in unnecessary diagnostic testing and treatments (eg, eyedrops, cataract extraction).

Alzheimer disease (AD) is a frequent cause of CVI. In some cases, CVI is the initial manifestation and cognitive function is spared, later developing into conventional AD in almost all cases. This condition, *posterior cortical atrophy*, although most commonly caused by AD, can be associated with a variety of other neurodegenerative disorders. A cortical origin for visual symptoms is suggested by a known history of dementing illness or cortical injury, poor performance on the Ishihara test (representing simultanagnosia, in which the patient has difficulty integrating multiple elements of a visual scene), and abnormal results on the clock-drawing test. Neuroimaging is warranted in all patients with CVI in order to exclude structural and vascular lesions. See Chapter 7 for discussion of specific cortical visual syndromes and their localization.

Winterkorn JMS, Fraser CE, Nirenberg MJ. Ophthalmic features of neurodegenerative diseases. *Focal Points: Clinical Modules for Ophthalmologists*. American Academy of Ophthalmology; 2010, module 4.

## Vision Rehabilitation

---

Ophthalmologists are encouraged to recognize the impact of vision loss on a patient's life and advise the patient of available vision rehabilitation options, including referral to a rehabilitation specialist. An evaluation at a low vision clinic can be beneficial in terms of orientation and mobility, and through the evaluation, the patient may learn about compensatory techniques, such as computer training or use of prisms. A variety of technology-based low vision devices are available that can improve visual function and independence; dedicated low vision services can help introduce patients to these devices.

Counseling regarding driving is also essential for patients with visual acuity loss or visual field defects. It is important for the ophthalmologist to be aware of specific visual acuity and visual field requirements for driving because they vary by state. Also important is recognizing that although patients may meet the strict legal criteria for driving, it may not be safe for them to do so, as driving involves many neurologic domains. A formal driver's evaluation (often offered by occupational therapy services) can be valuable for these patients.

The following training and strategies are also available for patients with vision loss:

- Wayfinding training can guide the compensatory strategies used for navigation.
- For patients with homonymous hemianopia, an optical method to redirect images from the blind field into the seeing field is peripheral sector prism eyeglasses, in which small high-power prisms are placed on eyeglasses, specifically, on the lens ipsilateral to the homonymous hemianopia (ie, for *left* homonymous hemianopia, prism on the *left* lens). This substitution technique may be considered for motivated patients.
- Relatively simple strategies that can improve reading fluency are using a bright marker to indicate the margin on the side of the visual field loss and using a straight-edge to help follow lines of text.

- For patients with hemianopic dyslexia, saccadic training, in which the patient learns to make predictive saccades in the direction of the text, can mitigate letter-by-letter reading.
- Laterally scrolling text, which moves text into the seeing field, may be helpful.
- Alternative strategies for acquiring visual information (eg, books on tape, text recognition) are also available.

For additional information about vision rehabilitation, see BCSC Section 3, *Clinical Optics and Vision Rehabilitation*.

American Academy of Ophthalmology Preferred Practice Pattern Vision Rehabilitation Committee. *Vision Rehabilitation Preferred Practice Pattern*. American Academy of Ophthalmology; 2017. [www.aao.org/ppp](http://www.aao.org/ppp)

# The Patient With Transient Visual Loss

## Highlights

---

- The most important cause of monocular transient visual loss (TVL) is acute retinal ischemia due to temporary occlusion of the central retinal artery or its branches by emboli.
- In patients older than 50 years who present with TVL in one or both eyes, it is crucial to consider giant cell arteritis as the cause of the vision loss.
- Migraine is the most common cause of binocular TVL.
- Patients with monocular TVL thought to be due to acute retinal ischemia require immediate referral to a stroke service or emergency department, and their management should be similar to that of patients with cerebral transient ischemic attacks.
- When obtaining the history of a patient with TVL, the examiner should inquire about vascular risk factors such as atheromatous disease, diabetes mellitus, hypertension, dyslipidemia, smoking, sleep apnea, and history of connective tissue disease or vasculitis, as well as conditions suggesting a cardiac source of emboli (eg, arrhythmia, valvular disease).

## Clinical Characteristics

---

Transient visual loss (TVL) may be caused by a variety of benign and pathogenic mechanisms. For the purposes of this chapter, TVL is defined as the sudden loss of visual function (partial or complete) in 1 or both eyes that lasts less than 24 hours. In this context, the most important cause of monocular TVL is acute retinal ischemia due to temporary occlusion of the central retinal artery or its branches by emboli. The most common cause of binocular TVL is migraine. A systematic approach is needed to localize the cause of TVL, including, first and foremost, a detailed historical account that addresses the following key points:

- *Monocular versus binocular.* Establishing TVL as monocular or binocular is important for localizing the causative lesion. Monocular loss suggests a prechiasmal problem (ie, occurring anywhere from the cornea to the optic nerve), whereas binocular loss indicates a chiasmal or retrochiasmal (intracranial) problem. In rare instances, binocular TVL can reflect a bilateral ocular disorder. Patients should be asked whether



they occluded each eye during the episode of vision loss. Clinicians should be aware that transient homonymous hemianopia is frequently misperceived as monocular vision loss in the eye with the temporal visual field deficit.

- **Age.** Although cerebrovascular disease is the most common cause of monocular TVL in older patients, giant cell arteritis (GCA) should be suspected and considered in all patients older than 50 years.

Migraine is the most likely cause of binocular TVL. An important exception is pregnant women with eclampsia; in these cases, TVL may be a harbinger of more serious and permanent vision loss, usually occurring within days of delivery (see Chapter 15). Central retinal artery vasospasm can cause monocular TVL, typically in younger patients, although not commonly. Retinal vasospasm should be considered only after appropriate investigation for other potential causes.

- **Duration of visual loss.** Monocular or binocular TVL lasting seconds is often referred to as *transient visual obscurations*. Often precipitated by a change in posture (eg, bending over), they are commonly reported by patients with optic disc drusen or papilledema. Monocular TVL lasting several minutes (typically no more than 15 minutes) is suggestive of retinal ischemia (either from emboli or GCA). The duration of vision loss from central retinal artery vasospasm varies; it may last for seconds to an hour. TVL resulting from ocular hypoperfusion or venous insufficiency can persist up to 30 minutes. Occipital seizures are very brief binocular visual disturbances that typically last only a few seconds, whereas the binocular scintillating scotoma typical of migraine lasts 20–30 minutes.
- **Pattern/description of visual loss and recovery.** The classic description of TVL due to retinal emboli is a descending (or ascending) curtain in 1 eye; however, tunnel-like constriction of vision or sudden complete loss of vision may also occur. An altitudinal aspect of visual loss strongly suggests retinal emboli, but central retinal artery vasospasm can sometimes cause similar visual symptoms. Visual loss or disturbance precipitated by exercise can be caused by vasospasm, pigment dispersion syndrome, or demyelinating disease. *Uhthoff phenomenon* (transient visual blurring resulting from physical activity or elevation in body temperature) frequently occurs in patients with a current or previous episode of optic neuritis (see Chapter 4). Posterior circulation ischemia typically causes complete binocular TVL (ie, cortical visual impairment) or a homonymous hemianopia, often in association with brainstem and/or cerebellar symptoms. Binocular visual disturbances with a geometric quality (eg, “fortification” pattern) strongly suggest occipital lobe dysfunction (eg, migraine, ischemia, or seizure). Whiteout of vision in both eyes or gradual constriction (ie, “closing in”) of peripheral vision without positive visual phenomena may also signal occipital lobe ischemia.
- **Associated symptoms and additional clinical features.** Positive visual phenomena and headache accompanying binocular TVL suggest migraine. Persistent headaches and pulsatile tinnitus are suggestive of increased intracranial pressure. In a patient older than 50 years, TVL accompanied by symptoms such as headaches, jaw claudication, and scalp tenderness strongly suggests GCA (see the section “Vasculitis” later in the chapter for a complete list of signs and symptoms of GCA).

The presence of other neurologic symptoms and signs can help localize the vascular territory involved. Loss of consciousness, dizziness, diplopia, dysarthria, or focal weakness accompanying binocular TVL suggests cerebral ischemia in the posterior circulation (basilar artery territory), whereas focal weakness contralateral to monocular TVL or aphasia suggests cerebral ischemia in the anterior circulation (internal carotid artery territory). Ipsilateral periorbital pain in a patient with ipsilateral Horner syndrome may indicate an internal carotid artery dissection (see Chapter 11, Fig 11-4). TVL associated with exercise or change in position may suggest hypoperfusion (see the section “Ocular ischemic syndrome” later in the chapter). Skin or joint changes or Raynaud phenomenon may accompany systemic vasculitis. TVL associated with ocular discomfort or irritation may suggest dry eye as the underlying cause. In this setting, the TVL lasts seconds and improves with blinking. It is also aggravated by activities that require prolonged concentration and/or screen time (and decreased blinking), such as driving, using the computer, or watching television.

- *Predisposing conditions.* The examiner should conduct a careful interview, eliciting information about the presence of vascular risk factors such as atheromatous disease (carotid stenosis, coronary artery disease, peripheral arterial disease, aortic aneurysm), diabetes mellitus, hypertension, dyslipidemia, smoking, sleep apnea, conditions suggesting a cardiac source of emboli (previous myocardial infarction, valvulopathy, arrhythmia), intravenous drug use, family or personal history of a clotting disorder, systemic cancer, and history of connective tissue disease or vasculitis (eg, GCA or Takayasu arteritis).

Donders RC; Dutch TMB Study Group. Clinical features of transient monocular blindness and the likelihood of atherosclerotic lesions of the internal carotid artery. *J Neurol Neurosurg Psychiatry*. 2001;71(2):247–249.

Lawlor M, Perry R, Hunt BJ, Plant GT. Strokes and vision: the management of ischemic arterial disease affecting the retina and occipital lobe. *Surv Ophthalmol*. 2015; 60(4):296–309.

## Examination

Although the patient may report complete recovery of visual function, a thorough examination is crucial to rule out ocular and orbital causes of TVL (see the following section), to assess the afferent visual function, and to look for retinovascular clues (eg, emboli, cotton-wool spots, vascular attenuation, or hemorrhage) that might suggest a specific diagnosis. This process includes testing for corrected distance visual acuity (also called best-corrected visual acuity), color vision, and intraocular pressure (IOP), as well as an examination of the pupils (testing for relative afferent pupillary defect or Horner syndrome), a slit-lamp examination, automated perimetry, and a dilated ophthalmoscopic examination. A positive photostress recovery test may indicate macular ischemia (see Chapter 3). When a vascular mechanism is suspected, retinal fluorescein angiography may be helpful.

## Monocular Transient Visual Loss

Figure 6-1 outlines the most common ocular, orbital, and systemic causes of monocular TVL and summarizes the appropriate investigations. Figure 6-2 presents a management pathway for patients with monocular TVL.

### Ocular Causes

Nonvascular ocular conditions that can cause monocular TVL are very common and are usually excluded by a detailed examination of the anterior and posterior segments of the eye.

Tear film abnormalities often result in blurred vision that improves with blinking or use of a tear supplement. These abnormalities may be associated with brief sharp or stabbing ocular pain. Slit-lamp examination may reveal a poor tear film, rapid tear breakup time, significant meibomian gland dysfunction, or corneal abnormalities. Dry eye can provoke blepharospasm, which can lead to moments of TVL (see Chapter 12, Fig 12-10). TVL related to dry eye is rarely monocular and more commonly bilateral.

Opacities, inflammation, or blood in the media of the anterior chamber or the vitreous can also cause episodic visual disturbance. For example, recurrent hyphema occasionally causes monocular TVL in patients with intraocular lenses who have uveitis-glaucoma-hyphema (UGH) syndrome. Release of pigment in the anterior chamber during exercise may occur in pigment dispersion syndrome.

Monocular TVL that is accompanied by halos and pain should prompt gonioscopy of the anterior chamber angle to assess for angle-closure glaucoma. The anterior lens should be inspected for glaukomflecken, which indicate previous episodes of angle-closure glaucoma. (See BCSC Section 10, *Glaucoma*, for further discussion of angle-closure glaucoma.)

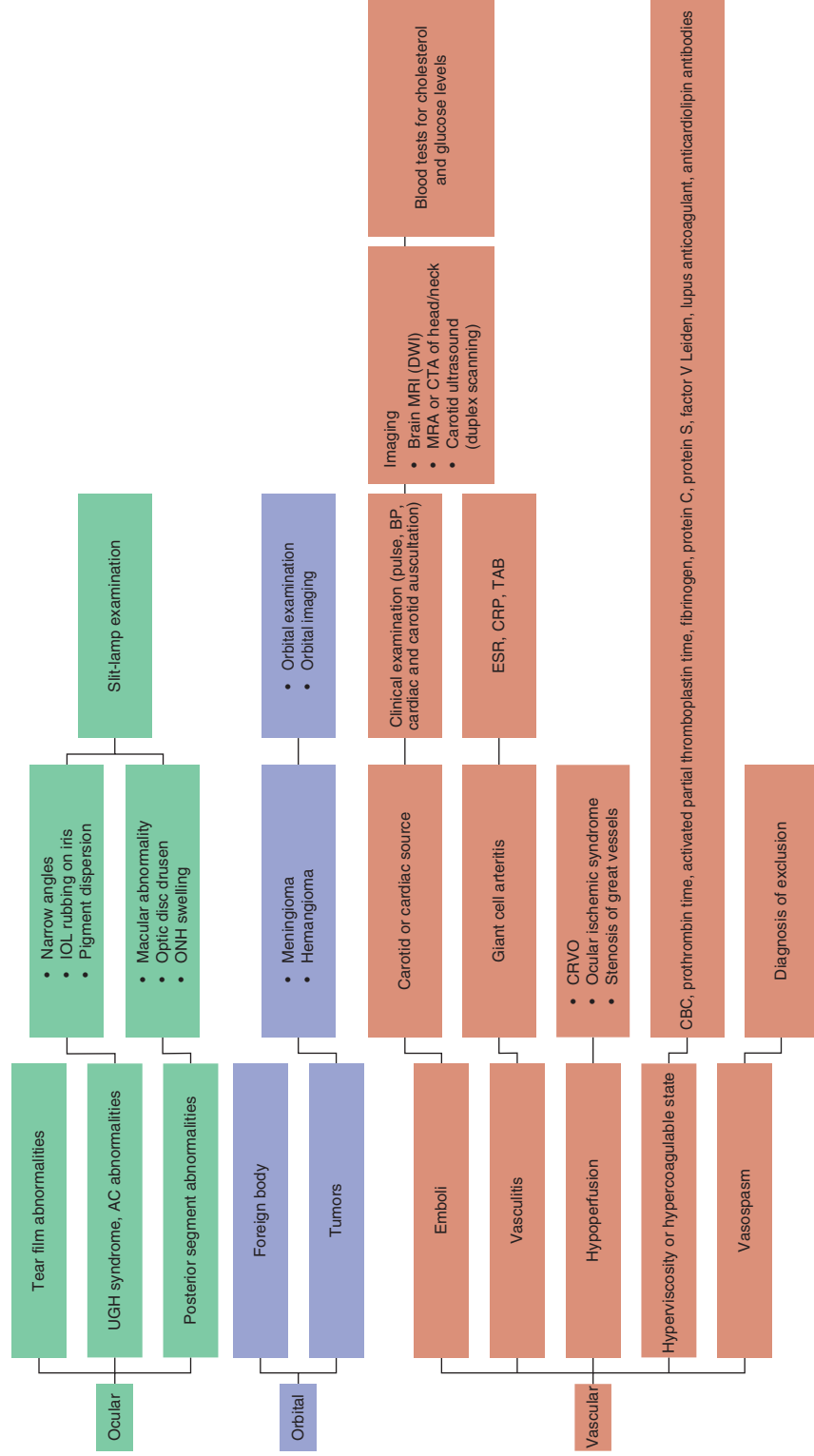
TVL, prolonged visual recovery, or persistent afterimages following exposure to bright light suggest a macular disorder such as serous detachment, age-related macular degeneration, or ocular ischemia. In patients with these disorders, results of the photo-stress recovery test are often abnormal (see Chapter 3 for further discussion of this test).

Patients with papilledema or congenital optic nerve head anomalies (eg, drusen) may experience transient visual obscurations. Typically, these are brief (less than 10 seconds) and are precipitated by changes in posture.

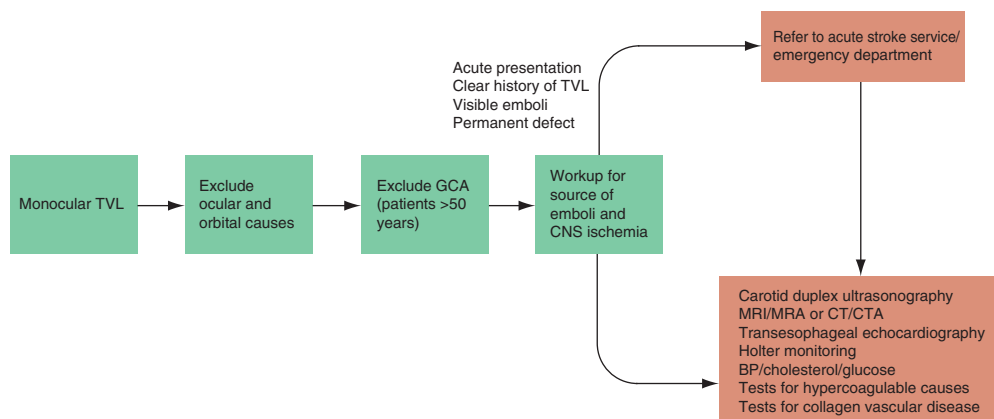
Kaiboriboon K, Piriyaawat P, Selhorst JB. Light-induced amaurosis fugax. *Am J Ophthalmol*. 2001;131(5):674–676.

### Orbital Causes

Monocular TVL that is induced specifically by eye movements in a certain direction (gaze-evoked TVL) suggests an orbital mass such as hemangioma or meningioma or a foreign body. The TVL probably results from a combination of direct compression of the optic nerve and ischemia from reduction of intraocular blood flow, caused by compression of the vasculature by the lesion (which returns to normal after the eye moves out of the field of gaze in which the TVL occurs). Careful examination usually reveals other orbital findings, such as proptosis or limited ocular motility.



**Figure 6-1** Flowchart for the classification of causes of monocular transient visual loss (TVL) and appropriate investigations. AC=anterior chamber; BP= blood pressure; CBC= complete blood count; CRP= C-reactive protein; CRVO= central retinal vein occlusion; CTA= computed tomography angiography; DWI= diffusion-weighted imaging; ESR= erythrocyte sedimentation rate; IOL= intraocular lens; MRA= magnetic resonance angiography; MRI= magnetic resonance imaging; ONH= optic nerve head; TAB= temporal artery biopsy; UGH= uveitis-glaucoma-hypophema. (Created by Helen Danesh-Meyer, MD, PhD.)



**Figure 6-2** Management pathway for monocular transient visual loss (TVL). BP=blood pressure; CNS=central nervous system; CT=computed tomography; CTA=computed tomography angiography; GCA=giant cell arteritis; MRA=magnetic resonance angiography; MRI=magnetic resonance imaging. (Created by Helen Danesh-Meyer, MD, PhD.)

Otto CS, Coppit GL, Mazzoli RA, et al. Gaze-evoked amaurosis: a report of five cases. *Ophthalmology*. 2003;110(2):322–326.

## Vascular Causes

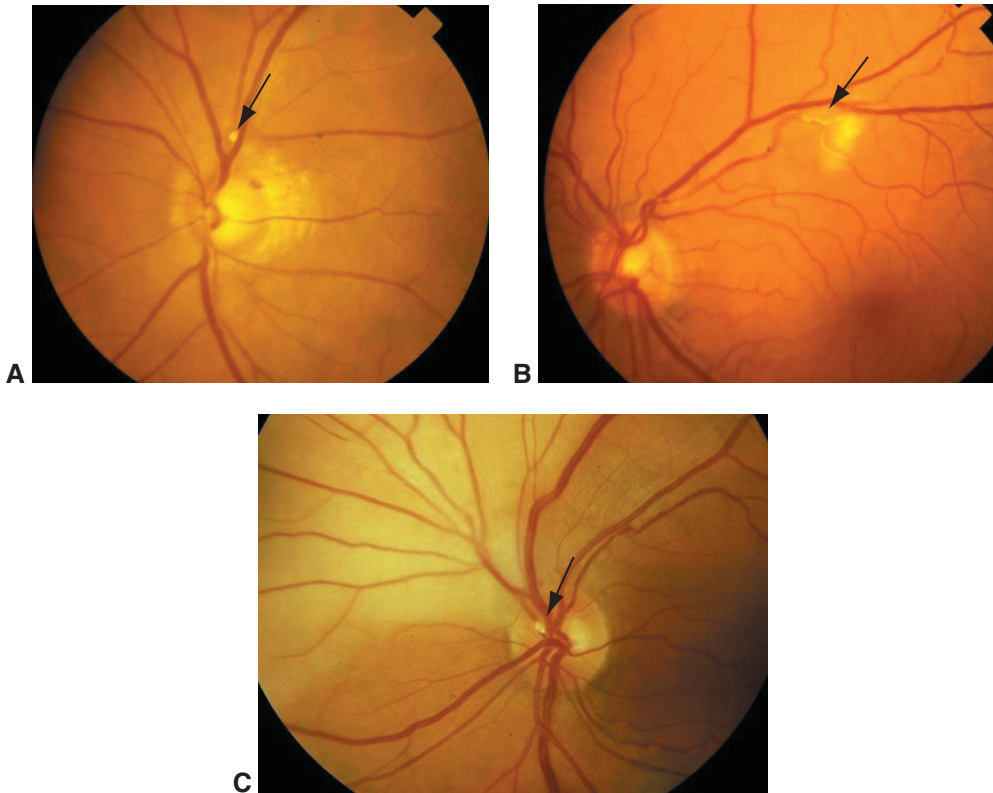
After localized ocular and orbital pathologies have been ruled out, vascular causes must be considered. The term *amaurosis fugax* refers specifically to a retinal transient ischemic attack (TIA). Retinal arterial ischemia, whether transient or permanent, is a form of ischemic stroke of the anterior circulation that results from decreased blood flow in the ophthalmic branches of the internal carotid artery.

Vascular-induced TVL is a recognized prodromal syndrome of cerebral infarction. Vascular causes of monocular TVL are most often related to retinal emboli. However, TVL may also result from optic nerve ischemia in patients with GCA or from diffuse ocular hypoperfusion in patients with severe carotid artery disease (ie, ocular ischemic syndrome), or it may precede central retinal vein occlusion. Retinal emboli typically result in acute, painless visual loss in 1 eye, which is often described as a descending (or ascending) curtain over part or all of the visual field. The visual loss usually resolves over a few minutes. The examiner should conduct a careful interview and neurologic examination in order to assess for contralateral neurologic symptoms and signs such as weakness and aphasia, which suggest cerebral ischemia. Results of the ocular examination are often normal, although abnormalities of the retinal vasculature can occasionally be seen.

## Emboli

Figure 6-3 shows the 3 most common types of emboli: cholesterol (Hollenhorst plaque), platelet-fibrin, and calcium. The characteristics of these emboli are reviewed in Table 6-1. Other less common varieties of emboli include those resulting from cardiac tumors





**Figure 6-3** Common retinal emboli. **A**, Cholesterol embolus (Hollenhorst plaque) at the bifurcation of a retinal arteriole (*arrow*). **B**, Platelet-fibrin embolus (*arrow*). **C**, Calcific embolus with branch retinal artery occlusion (*arrow*). (Courtesy of Karl C. Golnik, MD.)

(myxoma), fat (long-bone fractures), sepsis, talc inhalation, air bubbles (from trauma), silicone, and administration of depot drugs (corticosteroids).

Atheroma formation occurs most commonly at the bifurcation of the common carotid artery into the internal and external carotid arteries and in the carotid siphon (Fig 6-4). Atheromas can remain stationary, become fibrotic, ulcerate, narrow and occlude the lumen, or release emboli. The internal carotid lumen must be reduced by 50%–90% before distal flow is affected; however, emboli can occur with any degree of stenosis if there are ulcerated or unstable atheromatous plaques. Emboli from aortic arch atheromas are also common. In addition, emboli may occur from hypercoagulable states and inflammation, such as acute pancreatitis (ie, Purtscher-like retinopathy). Treatable risk factors include hypertension, diabetes mellitus, hypercholesterolemia, and smoking. In patients with TVL and periorbital pain or headache, a carotid dissection should be considered.

Cardiac emboli can arise from many causes, including cardiac arrhythmia (particularly atrial fibrillation), ventricular aneurysms, hypokinetic wall segments, patent foramen ovale, endocarditis (infectious [associated with bacterial endocarditis] and noninfectious [marantic]), and valvular heart disease (including atrial myxoma).

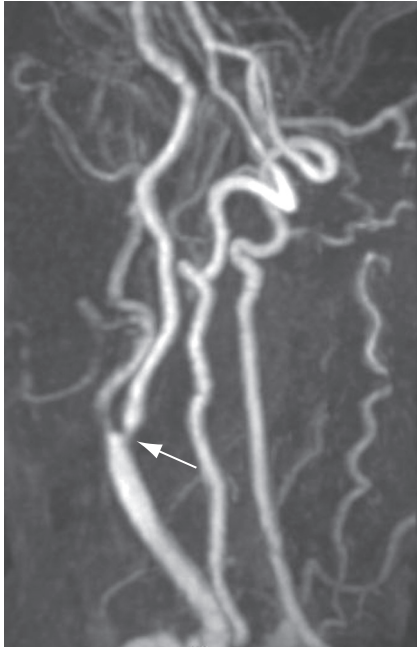**Table 6-1 Clinical Aspects of Common Retinal Emboli**

Type	Appearance and Location	Source	Evaluation
Cholesterol (see Fig 6-3A)	Yellow-orange or copper color Refractile Globular or rectangular Usually located at major bifurcations	Usually common or internal carotid artery In rare instances, aorta or innominate artery	General medical evaluation <sup>a</sup> Noninvasive studies of carotid patency and aortic arch Cardiac assessment, including Holter monitoring and echocardiography
Platelet-fibrin (see Fig 6-3B)	Dull gray-white color Long, smooth shape Concave meniscus at each end Usually mobile; can lodge along course of vessel	Wall of atherosclerotic vessel Heart, especially valves	General medical evaluation <sup>a</sup> Noninvasive studies of carotid patency and aortic arch Cardiac assessment, including Holter monitoring and echocardiography Hematologic studies
Calcium (see Fig 6-3C)	Chalky white Large Round or ovoid Lodges in first or second bifurcation May overlie optic nerve head	Heart or great vessels, particularly as a result of rheumatic heart disease, calcific aortic stenosis, or calcification of mitral valve annulus	General medical evaluation <sup>a</sup> Noninvasive study of aortic arch Cardiac assessment, including echocardiography

<sup>a</sup>The evaluation is necessary not for determining the source of the embolus, but because these emboli are associated with an increased risk of cardiac disease and death.

**Clinical and laboratory evaluation** When an embolic cause of TVL is suspected in a patient, a complete vascular and cardiac evaluation is urgently required; patients with TVL due to emboli have increased rates of morbidity and mortality from stroke, myocardial infarction, aortic aneurysm, and other related vascular events (see the following sections). Clinical examination should include assessment of the patient's pulse (in particular, examining for atrial fibrillation) and blood pressure, cardiac auscultation, and carotid artery auscultation (best done at the angle of the jaw, where the bifurcation is located). A carotid bruit indicates turbulent flow within the vessel, and it may be heard with narrowing of the external or internal carotid artery. However, a bruit is absent when flow is undisturbed or when carotid occlusion is complete. Investigation for atrial fibrillation involves echocardiography, electrocardiography (ECG), and Holter monitoring. It is crucial to identify and treat atrial fibrillation because it is a leading cause of cardiac emboli. If there is a visible embolus, a workup for GCA is generally not necessary.

In patients older than 50 years, once GCA is ruled out, an immediate workup for the source of the emboli must be initiated (see Chapter 15 for detailed discussion of GCA, including diagnosis). Because monocular TVL may herald a devastating cerebral stroke,



**Figure 6-4** Magnetic resonance angiogram shows high-grade stenosis (*arrow*) at the bifurcation point of the cervical internal carotid artery. (Courtesy of Aki Kawasaki, MD.)

all patients with acute vascular TVL should undergo a thorough vascular workup at once. It is best to immediately refer these patients to the nearest emergency department (preferably one affiliated with a stroke center). Sending a patient away for outpatient workup or to a primary care physician delays appropriate management.

**Imaging** It is important to obtain noninvasive vascular imaging of patients with monocular TVL urgently. The carotid arteries (in patients with monocular TVL) and the aortic arch can reliably be evaluated by duplex carotid ultrasonography, magnetic resonance angiography (MRA), or computed tomography angiography (CTA). Although ultrasonography is a sensitive method for detecting cervical ulcerated plaques, it has varying reliability. MRA and CTA enable visualization and characterization of the plaque in question and the surrounding arterial wall; these imaging techniques are also extremely useful for detecting internal carotid artery dissection.

For all patients with acute retinal ischemia, diffusion-weighted magnetic resonance imaging (DW-MRI, also called DWI) should be obtained. Results of studies have shown that up to 1 of every 4 patients will show acute brain infarctions on DWI (often silent infarctions in neurologically asymptomatic patients). The probability of abnormal MRI findings is higher in patients with embolic retinal ischemia (compared with patients with nonembolic retinal ischemia) and in patients with permanent visual loss (compared with patients with TVL).

Powers WJ, Rabinstein AA, Ackerson T, et al. Guidelines for the early management of patients with acute ischemic stroke: 2019 update to the 2018 guidelines for the early management of acute ischemic stroke: a guideline for healthcare professionals from the American Heart Association/American Stroke Association. *Stroke*. 2019;50(12):e344–e418.

Echocardiography is useful for detecting valvular and cardiac wall defects, intracardiac tumors, and large thrombi. Transthoracic echocardiography is appropriate for initial screening for the aforementioned conditions. Although transesophageal echocardiography is more invasive, it is also more sensitive than transthoracic echocardiography and allows better visualization of the cardiac valves and evaluation of the aortic arch. It is important to note that a normal-appearing echocardiogram does not exclude the possibility of emboli. Prolonged inpatient cardiac monitoring or ambulatory Holter monitoring may document previously undetected cardiac arrhythmias.

If a cardiac or carotid source of embolus formation is not found, other systemic processes that could contribute to the stroke need to be considered. Major risk factors for stroke include advanced age, hypertension, ischemic heart disease, diabetes, hypercholesterolemia, smoking, and sleep apnea. Laboratory studies should be obtained to evaluate for these conditions and any others under clinical suspicion, such as hypercoagulable states, collagen vascular diseases, or vasculitis, depending on presenting signs and symptoms.

Bioussé V, Nahab F, Newman NJ. Management of acute retinal ischemia: follow the guidelines! *Ophthalmology*. 2018;125(10):1597–1607.

Bioussé V, Trobe JD. Transient monocular visual loss. *Am J Ophthalmol*. 2005;140(4):717–721.

Jauch EC, Saver JL, Adams HP Jr, et al; American Heart Association; American Stroke Association Stroke Council; Council on Cardiovascular Surgery and Anesthesia; Council on Cardiovascular Radiology and Intervention; Council on Cardiovascular Nursing; Interdisciplinary Council on Peripheral Vascular Disease. Guidelines for the early management of patients with acute ischemic stroke: a guideline for healthcare professionals from the American Heart Association/American Stroke Association. *Stroke*. 2013;44(3):870–947.

Lee J, Kim SW, Lee SC, Kwon OW, Kim YD, Byeon SH. Co-occurrence of acute retinal artery occlusion and acute ischemic stroke: diffusion-weighted magnetic resonance imaging study. *Am J Ophthalmol*. 2014;157(6):1231–1238.

Mac Grory B, Schrag M, Bioussé V, et al; American Heart Association Stroke Council; Council on Arteriosclerosis, Thrombosis and Vascular Biology; Council on Hypertension; Council on Peripheral Vascular Disease. Management of central retinal artery occlusion: a scientific statement from the American Heart Association. *Stroke*. 2021;52(6):e282–e294. Published correction appears in *Stroke*. 2021;52(6):e309.

**Prognosis** Significant carotid artery stenosis or occlusion is present in over 50% of TVL cases. Retinal TIA is a medical emergency associated with a high risk of early ischemic cerebral stroke and other cardiovascular events. Of patients with TIA (retinal or cerebral), 10%–15% have a cerebral stroke within 90 days, and approximately 50% of these strokes occur within 48 hours. For individuals with TIA who survive the initial high-risk period, the 10-year stroke risk is about 19%, and the combined 10-year risk of stroke, myocardial infarction, and vascular death is approximately 40% (or about 4% per year).

Benavente O, Eliasziw M, Streifler JY, Fox AJ, Barnett HJ, Meldrum H; North American Symptomatic Carotid Endarterectomy Trial Collaborators. Prognosis after transient monocular blindness associated with carotid-artery stenosis. *N Engl J Med*. 2001;345(15):1084–1090.

Helenius J, Arsava EM, Goldstein JN, et al. Concurrent acute brain infarcts in patients with monocular visual loss. *Ann Neurol*. 2012;72(2):286–293.

**Risk stratification** Several factors have been used to stratify the stroke risk in patients with retinal TIA, including male sex, age 75 years or older, history of cerebral TIA or cerebral stroke, intermittent leg claudication, carotid artery stenosis of 80%–94%, and absence of collateral vessels on cerebral angiography. Patients with none or only 1 of these risk factors have a 3-year ipsilateral stroke risk of 1.8%. However, for patients with 2 risk factors, the 3-year stroke risk is 12.3%, and for patients with 3 or more risk factors, the 3-year stroke risk increases to 24.2%.

**Guidelines for TIA management** According to the American Heart Association guidelines, a patient who has had either a retinal or cerebral TIA requires immediate assessment for an acute stroke. An acute stroke is diagnosed in patients whose neuroimaging findings (ie, DWI results) are abnormal. These patients are then admitted to the hospital and managed accordingly regardless of whether they presented with a retinal or cerebral TIA. Patients with normal MRI results usually are evaluated within 24 hours in a stroke clinic or an emergency department observation unit affiliated with a stroke center. Although the risk of stroke after a retinal TIA related to carotid atherosclerosis is lower than the risk of stroke after a cerebral TIA, the management of retinal TIAs is similar to that of cerebral TIAs.

Easton JD, Saver JL, Albers GW, et al; American Heart Association; American Stroke Association Stroke Council; Council on Cardiovascular Surgery and Anesthesia; Council on Cardiovascular Radiology and Intervention; Council on Cardiovascular Nursing; Interdisciplinary Council on Peripheral Vascular Disease. Definition and evaluation of transient ischemic attack: a scientific statement for healthcare professionals from the American Heart Association/American Stroke Association Stroke Council; Council on Cardiovascular Surgery and Anesthesia; Council on Cardiovascular Radiology and Intervention; Council on Cardiovascular Nursing; and the Interdisciplinary Council on Peripheral Vascular Disease. The American Academy of Neurology affirms the value of this statement as an educational tool for neurologists. *Stroke*. 2009;40(6):2276–2293.

**Treatment** Medical treatment of retinal TIA due to carotid artery stenosis begins with antiplatelet agents (aspirin, aspirin and dipyridamole, or clopidogrel). Treating the vascular risk factors and employing other secondary prevention measures (eg, carotid endarterectomy, treatment of arrhythmia, treatment of cardiac sources of emboli) are essential. Treatment should be initiated as soon as possible by a stroke neurologist.

Anticoagulant therapy with direct oral anticoagulants (DOACs) is used to prevent recurrent ischemic stroke in patients with atrial fibrillation. There are 2 groups of DOACs: factor Xa inhibitors (eg, apixaban, edoxaban, and rivaroxaban) and direct thrombin inhibitors (eg, dabigatran). Along with warfarin, DOACs are now the mainstay of anticoagulant therapy in outpatient settings and often preferred over warfarin in the prevention and treatment of thromboembolic disorders, primarily because of their proven efficacy, superior safety records, and more predictable and reliable pharmacokinetic and pharmacodynamic profiles. In addition, DOACs do not require routine coagulation monitoring. Although DOACs have many favorable characteristics, they have limitations. Apart from the cost, bleeding risk is still a major concern. However, idarucizumab is effective and specifically indicated for dabigatran-related life-threatening or uncontrollable bleeding as well as for the reversal of dabigatran in the event of an emergency surgery. Also, andexanet



alfa was recently approved by the US Food and Drug Administration to reverse bleeding in individuals taking apixaban, edoxaban, or rivaroxaban. Although the role of DOACs in acute ischemic stroke has been established, the timing of their administration during treatment of stroke remains unclear. See BCSC Section 1, *Update on General Medicine*, for additional discussion.

The decision regarding whether a patient requires surgical management of carotid atheromatous disease (eg, carotid endarterectomy) should be made in consultation with a stroke neurologist.

Kustos SA, Fasinu PS. Direct-acting oral anticoagulants and their reversal agents—an update. *Medicines (Basel)*. 2019;6(4):103.

Seiffge DJ, Werring DJ, Paciaroni M, et al. Timing of anticoagulation after recent ischaemic stroke in patients with atrial fibrillation. *Lancet Neurol*. 2019;18(1):117–126.

### **Additional systemic causes**

Other possible systemic causes of vascular monocular TVL include vasculitis (eg, GCA, Takayasu arteritis), ocular hypoperfusion, ophthalmic artery disease, central retinal artery vasospasm, hyperviscosity syndrome, and antiphospholipid antibody syndrome.

**Vasculitis** As mentioned earlier, monocular TVL in patients older than 50 years can be caused by GCA and may signal impending acute and permanent visual loss in 1 or both eyes. Therefore, a directed history of older patients with monocular or binocular TVL should include inquiries about the following signs and symptoms of GCA:

- headache
- scalp tenderness
- jaw claudication
- weight loss
- proximal muscle aches
- malaise
- fever

However, as stated earlier, systemic signs and symptoms are absent in up to 20% of patients with GCA who have visual symptoms (so-called occult GCA).

Erythrocyte sedimentation rate (ESR), C-reactive protein (CRP) level, and complete blood count (CBC) should be assessed in all patients older than 50 years who present with TVL. If GCA is the suspected cause of TVL, immediate treatment with high-dose corticosteroids is begun, as it is the only way to prevent progression to permanent visual loss and contralateral eye involvement. See Chapter 15 for in-depth discussion of GCA, including diagnosis and treatment.

Hayreh SS, Podhajsky PA, Zimmerman B. Occult giant cell arteritis: ocular manifestations. *Am J Ophthalmol*. 1998;125(4):521–526.

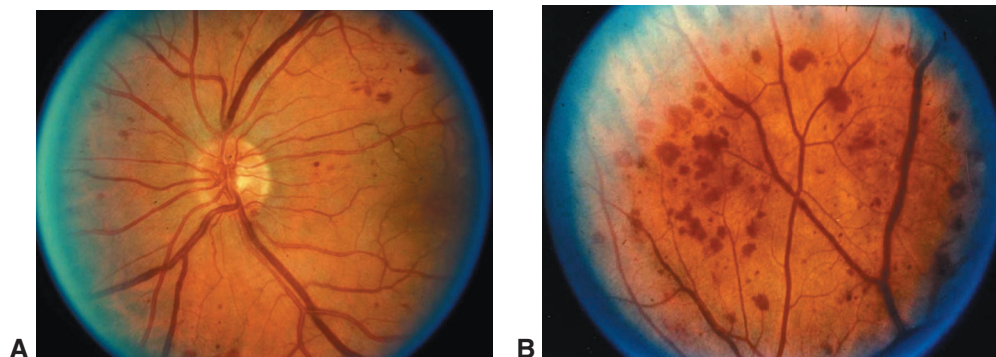
**Ocular hypoperfusion** Ocular hypoperfusion may lead to monocular TVL in 3 classic scenarios: central retinal vein occlusion (CRVO), change in posture from a sitting to a standing position, and ocular ischemic syndrome.

**CENTRAL RETINAL VEIN OCCLUSION** Patients with CRVO may report TVL that lasts seconds to minutes, with full recovery to normal vision afterward. Such symptoms may predate more lasting visual loss by days or weeks, or the symptoms may cease when collateral vessels develop.

**CHANGE IN POSTURE FROM A SITTING TO A STANDING POSITION** The monocular TVL is usually related to severe stenosis of the great vessels, or GCA. The patient may note progressive constriction of vision in the periphery (“diaphragm pattern”) that lasts from seconds to 1–2 minutes.

**OCULAR ISCHEMIC SYNDROME** This syndrome is characterized in part by a hypotensive, ischemic retinopathy with low retinal artery pressure, poor perfusion, midperipheral dot-and-blot retinal hemorrhages, and dilated (nontortuous) retinal veins (*venous stasis retinopathy*). Recurrent orbital pain that improves when the patient lies down is highly suggestive of carotid occlusive disease. In the early stages, patients may experience transient or persistent blurred vision or TVL on exposure to bright light. Severe ocular ischemia causes anterior segment changes that may be confused with chronic intraocular inflammation. The patient may have decreased vision; a red, painful eye with episcleral vascular hyperemia; and aqueous flare (ischemic uveitis). IOP may be high, normal, or low even though neovascularization of the anterior chamber angle and iris is common. In this instance, low or normal IOP is the result of impaired ciliary body perfusion. Fundus changes include dilated retinal veins, narrowed retinal arteries with microaneurysms, and midperipheral dot-and-blot hemorrhages (Fig 6-5).

Treatment of ocular ischemic syndrome is challenging and includes ocular reperfusion (via carotid endarterectomy, or carotid stenting when possible), use of IOP-lowering drugs, and treatment for neovascularization, including panretinal photocoagulation and/or intravitreal anti-vascular endothelial growth factor. If the preoperative IOP is low, restoration of blood flow may precipitate dangerously high IOP. Once signs of chronic hypoperfusion develop, however, the patient is unlikely to improve with surgery. In other



**Figure 6-5** Ocular ischemic syndrome. **A**, The fundus demonstrates retinal venous dilation and scattered hemorrhages. **B**, Midperipheral dot-and-blot hemorrhages. (Reprinted from Carter JE. Panretinal photocoagulation for progressive ocular neovascularization secondary to occlusion of the common carotid artery. *Ann Ophthalmol.* 1984;16(6):572–576.)

patients, carotid occlusion may be too advanced for surgical correction. Thus, early detection is crucial because neovascularization and progressive ocular ischemia result from prolonged hypoperfusion (see also BCSC Section 12, *Retina and Vitreous*).

Mendrinis E, Machinis TG, Pournaras CJ. Ocular ischemic syndrome. *Surv Ophthalmol*. 2010;55(1):2–34.

**Vasospasm, hyperviscosity, and hypercoagulability** Monocular TVL can result from vasospasm of the central retinal artery. Affected patients are generally young and experience stereotypic episodes of painless, severe monocular TVL. The vision returns to normal in between episodes, and the prognosis is usually good. The ocular examination findings are usually normal, but occasionally, when the patient is seen during the episode of visual loss, ophthalmoscopic examination reveals constriction of the retinal arteries. The diagnosis of vasospastic monocular TVL is one of exclusion. Before this diagnosis is made, the workup should rule out all causes of embolic retinal TIA. If the patient is older than 50 years, tests for ESR and CRP level should be obtained to rule out GCA.

In younger patients with monocular TVL, hyperviscosity syndrome and hypercoagulable states should be considered. *Hyperviscosity syndrome*, an uncommon cause of TVL, is the term used for any of several syndromes associated with excessive blood viscosity. One type is due to increased serum viscosity, which may result from elevated paraprotein levels, as seen with multiple myeloma. Another type is due to increased red or white blood cells (as in polycythemia vera, leukemia, and a myeloproliferative disorder). Approximately 10% of patients with polycythemia vera report episodes of monocular TVL. First-line laboratory studies for hyperviscosity include serum viscosity (although there is no specific cutoff for diagnosis), CBC, albumin, and total protein.

Hypercoagulable states may result from acquired and hereditary conditions. The most common conditions to consider in patients with monocular TVL include antiphospholipid syndrome, thrombocytosis, and other thrombophilia disorders. The screening panel for investigating for hypercoagulable states is outlined in Table 6-2.

Winterkorn JMS, Burde RM. Vasospasm—not migraine—in the anterior visual pathway. *Ophthalmol Clin North Am*. 1996;9:393–405.

**Table 6-2 Laboratory Tests for Hypercoagulable States and Relevant Conditions**

Condition	Tests
Antiphospholipid syndrome	Lupus anticoagulant, activated partial thromboplastin time (aPTT), dilute Russell viper venom time (dRVVT), prothrombin time
Deficiency of natural anticoagulant	Protein C, protein S, antithrombin, protein C deficiency type II
Thromboinflammation	C-reactive protein, fibrinogen, factor VIII
Genetic predisposition	Factor V Leiden, homocysteine, methylenetetrahydrofolate reductase mutation

## Binocular Transient Visual Loss

Common causes of binocular TVL include

- migraine
- occipital lobe lesions: tumor, arteriovenous malformation
- occipital lobe or posterior visual pathway ischemia: embolic, vasculitic, hypoperfusion

### Migraine

The most common cause of binocular TVL is the homonymous hemianopic defect caused by migrainous visual aura. Typically, the patient notes a small homonymous scotoma bounded by a zigzag, shimmering, colorful, or silvery image. The scotoma enlarges over several minutes, sometimes to a complete homonymous hemianopia, then gradually disappears. Vision typically returns to normal within 5–60 minutes. The visual aura is usually followed by a headache, although some patients may experience the typical aura without headache (previously called acephalgic migraine). The patient's vision is completely normal between episodes, and the visual phenomena typically change sides. Evaluation of migraine is discussed in Chapter 13.

Retinal migraine is a diagnosis that is sometimes given to patients with monocular TVL for which no other explanation is identified. True retinal migraine is very rare, and the underlying mechanism is unclear. Most, if not all, cases of retinal migraine are either migraine with aura, vasospasm, or functional visual loss. The International Headache Society has a strict set of diagnostic criteria for retinal migraine (see sidebar on p. 212).

### Occipital Mass Lesions

A structural lesion, such as an occipital arteriovenous malformation or tumor, may cause episodic binocular TVL, which may be associated with headaches. Symptoms that always occur on the same side are highly suggestive of a structural abnormality. Patients with these symptoms require contrast-enhanced brain MRI and/or MRA.

### Occipital Ischemia

Episodes of complete binocular TVL may represent a TIA involving the occipital lobes, either in the distribution of the basilar artery or the posterior cerebral arteries (see Chapter 1). These episodes are particularly common in older patients with vascular risk factors or cardiac anomalies. As opposed to migraine, hemianopic events of ischemic origin are typically sudden in onset and last only a few minutes. There may be an associated headache, especially in the brow contralateral to the hemianopia, but the pain occurs at the time of TVL. Nonophthalmic symptoms of TIAs in the vertebrobasilar system are discussed in Chapter 15.

Patients with suspected occipital TIA must be referred immediately to an emergency department and evaluated by a neurologist.

Lawlor M, Perry R, Hunt BJ, Plant GT. Strokes and vision: the management of ischemic arterial disease affecting the retina and occipital lobe. *Surv Ophthalmol.* 2015;60(4):296–309.

### **Diagnostic Criteria for Retinal Migraine From the Third Edition of the International Classification of Headache Disorders**

**Description:** Repeated attacks of monocular visual disturbance, including scintillations, scotomata, or blindness, associated with migraine headache.

#### **Criteria**

- A. Aura characterized by both of the following:
  - 1. Fully reversible, monocular, positive and/or negative visual phenomena (eg, scintillations, scotomata, or blindness) confirmed during an attack by either or both of the following:
    - a. Clinical visual field examination
    - b. The patient's drawing of a monocular field defect (made after clear instruction)
  - 2. At least 2 of the following:
    - a. Spreading gradually over  $\geq 5$  minutes
    - b. Symptoms last 5–60 minutes
    - c. Accompanied, or followed within 60 minutes, by headache
- B. Not better accounted for by another International Headache Society-3 diagnosis, and other causes of amaurosis fugax have been excluded

Adapted with permission from the International Headache Society. Headache Classification Committee of the International Headache Society International Classification of Headache Disorders. 3rd ed. *Cephalalgia*. 2018;38(1):23–24.

### **Occipital Seizures**

A very uncommon cause of TVL, occipital seizures typically produce unformed positive visual phenomena, such as colored or swirling lights. However, some patients experience negative visual symptoms, typically described as a blacking out of vision. These episodes usually last a few seconds to minutes. Most adults with occipital seizures harbor a structural lesion (eg, tumor, arteriovenous malformation, or structural abnormality due to trauma); in children, such seizures are more often benign. A normal electroencephalogram does not rule out seizures; prolonged electroencephalographic monitoring may be required. The visual symptoms resolve with anticonvulsant therapy.

Kun Lee S, Young Lee S, Kim DW, Soo Lee D, Chung CK. Occipital lobe epilepsy: clinical characteristics, surgical outcome, and role of diagnostic modalities. *Epilepsia*. 2005;46(5):688–695.



# The Patient With Illusions, Hallucinations, and Disorders of Higher Cortical Function



This chapter includes a related video. Go to [www.aaao.org/bcscvideo\\_section05](http://www.aaao.org/bcscvideo_section05) or scan the QR code in the text to access this content.

## Highlights

---

- Illusions are false perceptions of visual stimuli and can occur because of dysfunction anywhere along the pathway from the cornea to the visual cortex.
- Hallucinations are perceptions of an object or event that occur without visual stimuli; they can arise from dysfunction along the pathway from the retina to the visual cortex.
- Hallucinations in patients with visual impairment are often “release” hallucinations and do not reflect neurologic or psychiatric disease.
- Difficulty with visual interpretation in the setting of preserved visual acuity and visual fields often reflects higher cortical dysfunction.

## Introduction

---

Patients are often reluctant to report “seeing things” because of concerns that it may reflect mental illness; however, many visual hallucinations or illusions are not harbingers of psychiatric disease but are instead indicators of brain, ocular, or optic nerve pathology. Therefore, the ophthalmologist should make sure to ask patients about these symptoms. Understanding the difference between illusions, hallucinations, and other disorders of higher cortical function is key; these can be described as follows:

- An *illusion* is a false perception of visual stimuli and disappears with eye closure. For example, a person looking at stationary high-contrast borders may perceive an illusion of movement.
- A *hallucination* is the subjective perception of an object or event when no visual stimulus is present and usually does not disappear with eye closure. Patients with

dementia or altered sensorium (eg, delirium, hypnosis) are prone to hallucinations, as are patients with vision loss.

- *Disorders of higher cortical function* can affect interpretation of visual input and cause difficulty with visual tasks despite intact visual acuity and visual fields.

When assessing a patient who reports illusions, hallucinations, or difficulty with visual interpretation, the ophthalmologist must first evaluate the function of the patient's afferent visual system by determining the corrected distance and near visual acuity (best-corrected visual acuity) and performing color vision and visual field testing. It is also important to characterize the situational nature of the illusion, hallucination, or visual interpretation difficulty and the patient's mental status, as well as to review the past medical history and medication list for conditions or drugs associated with illusions and hallucinations (Table 7-1). This information can guide anatomical localization of the disorder and enable the ophthalmologist to establish a likely pathophysiology and/or differential diagnosis.

Hallucinations and illusions should be distinguished from perception of entoptic phenomena, which are physical structures in the visual pathway anterior to the photoreceptors, such as vitreous floaters, retinal vessels illuminated obliquely, and white blood cells circulating in retinal vessels.

Celesia GG. The mystery of photopsias, visual hallucinations, and distortions. *Suppl Clin Neurophysiol.* 2006;59:97–103.

**Table 7-1 Nonophthalmic Conditions and Medications Associated With Illusions and Hallucinations**

<b>Neurologic conditions</b>	Alzheimer disease, some brain lesions (eg, stroke, tumor, vascular malformation), epilepsy, Huntington chorea, Lewy body dementia, migraine, narcolepsy, Parkinson disease
<b>Medications and hallucinogens</b>	Anticholinergic and dopaminergic drugs, cephalosporins, psychotropic and antiseizure medications, sulfa drugs, vasoconstrictors, vasodilators Clomiphene, cyclosporine, digoxin, indomethacin, lidocaine, lithium, nefazodone, sildenafil, topiramate, trazodone, zonisamide Amphetamines, cocaine, lysergic acid diethylamide (LSD), mescaline, psilocybin Atropine, homatropine, topical scopolamine
<b>Psychiatric conditions</b>	Affective disorders, conversion disorders, schizophrenia
<b>Toxic conditions and metabolic perturbations</b>	Alcohol withdrawal (delirium tremens) Hepatic disease, infection (fever), uremia
<b>Miscellaneous conditions</b>	Intense emotional experiences Hypnosis, sensory deprivation, sleep deprivation

Fraunfelder FT, Fraunfelder FW, Chambers WA. *Drug-Induced Ocular Side Effects*. 7th ed. Saunders/Elsevier; 2014.

Winterkorn JM, Fraser CE, Nirenberg MJ. Ophthalmic features of neurodegenerative diseases. *Focal Points: Clinical Modules for Ophthalmologists*. American Academy of Ophthalmology; 2010, module 1.

## Visual Distortion and Illusions

---

The alterations of perception that make up the spectrum of illusions can arise at various points in the visual system.

### Ocular Origin

Many illusions have an ocular basis and may be classified as optical or retinal (due to alterations in photochemical transduction).

#### **Optical causes**

Irregularities in the eye's refracting elements can cause visual distortion and resultant illusions, such as ghost images (monocular diplopia), movement, or multiple images. Any alteration in the tear film (eg, dry eye syndrome) or in the corneal surface (eg, keratoconus, corneal edema, or scarring) can distort vision. Peripheral iridectomy or iridotomy may result in dysphotopsia (abnormal visual symptoms related to light rays passing through the iridectomy) and shadowing of images. Early cataract may cause visual distortion rather than decreased visual acuity, especially in eyes with early oil-droplet nuclear sclerotic changes or posterior subcapsular changes. The crystalline lens acts as a filter, changing the transmitted spectrum of light and thereby causing altered perceptions of shape and color. Cataract extraction may also result in changes in brightness and color perception. After intraocular lens implantation, some patients experience visual disturbances in the temporal field such as an arc of light or a dark area, called *positive* or *negative dysphotopsia*, respectively; these disturbances are typically transient and resolve spontaneously (see BCSC Section 11, *Lens and Cataract*, for more information).

Hu J, Sella R, Afshari NA. Dysphotopsia: a multifaceted optic phenomenon. *Curr Opin Ophthalmol*. 2018;29(1):61–68.

#### **Retinal causes**

Any disruption of normal foveal architecture (eg, epiretinal membrane, macular edema, macular hole, or subretinal disease) can result in visual distortion. Changes in the position of the retinal photoreceptors can cause various alterations in vision.

Metamorphopsia (line and shape distortion) is characteristic of macular disorders. Patients with these disorders usually report that linear objects appear curved or discontinuous. In intraretinal edema, the retinal elements are often pushed apart, causing micropsia (perceived image shrinkage). Much rarer than micropsia, macropsia (perceived image enlargement) can occur when the photoreceptors are pushed together. Although these symptoms can be prompted by pathology in any retinal location, patients are most sensitive to those due to macular pathology.

The retina may be the source of changes in color perception (dyschromatopsia) associated with drug side effects (eg, digoxin-induced yellowing of vision, sildenafil-induced blue tinge). Other changes in color perception may be related to vitamin A deficiency and choroidal or retinal ischemia, which can also lead to persistent afterimages or dazzle (brightness that temporarily causes visual confusion).

### Optic Nerve Origin

After an episode of demyelinating optic neuritis, a relative conduction delay within the affected optic nerve may lead to an altered perception of motion. Because of the disparity in neuronal transmission, a pendulum, for example, may appear to trace a 3-dimensional elliptical path instead of its actual single-plane oscillation (*Pulfrich phenomenon*).

### Cortical Origin

Depending on the affected area (primary visual cortex [V1] or the association areas, including V2, V3, and V4), occipital lobe pathology may alter the perceived shape and position of an object, change perception of motion, cause color vision loss, or induce multiplicity of images. Patients with parietal lobe abnormalities commonly experience disorders of visual perception, such as micropsia, macropsia, *teleopsia* (objects appearing more distant than they actually are), *pelopsia* (objects appearing closer than they actually are), and cerebral polyopia (see Disorders of Higher Cortical Dysfunction, later in this chapter; see also Chapter 1 for a discussion of anatomy).

## Hallucinations

---

Hallucinations are perceptions unrelated to visual stimuli. They may originate anywhere along the visual pathway but most commonly within the retina or visual cortex. Hallucinations may be *formed* (eg, real objects such as animals, flowers, cars, or people) or *unformed* (eg, light, spots, dots, or geometric patterns).

### Ocular Origin

Vitreous detachment with persistent vitreoretinal adhesions may produce photopsias (flashing lights) or vertical white flashes (so-called lightning streaks of Moore). Such hallucinations are often apparent in a dark environment and may be induced by saccades. Retinal detachment may produce persistent photopsias and floaters.

Photopsias resulting from outer retinal diseases are often continuous in duration. They may be simple white lights, or they may form geometric webs that can be colored, including silver and gold. Photopsias often herald the onset of autoimmune retinopathy, including cancer-associated retinopathy, a paraneoplastic process. In addition, photopsias may accompany a variety of retinal, retinal pigment epithelium, and choroidal abnormalities (eg, multiple evanescent white dot syndrome, acute zonal occult outer retinopathy, or birdshot chorioretinopathy; see Chapter 4 in this volume and BCSC Section 12, *Retina and Vitreous*, for more information on these conditions).

Gass JD, Agarwal A, Scott IU. Acute zonal occult outer retinopathy: a long-term follow-up study. *Am J Ophthalmol*. 2002;134(3):329–339.

Gordon LK. Paraneoplastic syndromes in neuro-ophthalmology. *J Neuroophthalmol*. 2015;35(3):306–314.

Zaret BS. Lightning streaks of Moore: a cause of recurrent stereotypic visual disturbance. *Neurology*. 1985;35(7):1078–1081.

## Optic Nerve Origin

Optic neuritis often produces phosphenes, which are flashes of light induced by eye movement or a dark setting. Patients with subacute or long-standing optic neuropathy may experience *sound-induced photisms* (sensations of color or light induced by a loud noise). It has been speculated that these photisms occur because of thalamic dysfunction.

Jacobs L, Karpik A, Bozian D, Gøthgen S. Auditory-visual synesthesia: sound-induced photisms. *Arch Neurol*. 1981;38(4):211–216.

## Cortical Origin

### Palinopsia

Unusual cortical phenomena may occur with disorders of both the dominant and (more frequently) the nondominant temporal, parietal, and occipital lobes. Palinopsia, visual perseveration after removal of the original stimulus (multiple afterimages), can be divided into 2 categories: *illusory* and *hallucinatory*. Illusory palinopsia is triggered by contrast and/or motion; the afterimage or visual trails appear in the same location in the visual field as the original stimulus (Fig 7-1). Migraine; use of hallucinogenic drugs such as lysergic acid diethylamide (LSD), even in the distant past; and certain medications (eg, clomiphen, nefazodone, topiramate, trazodone, and zonisamide) can cause illusory palinopsia. In contrast, hallucinatory palinopsia is not affected by environmental conditions, and the perseverated image can occur in a different location in the visual field than the original stimulus. When the afterimages are associated with homonymous hemianopia and appear in the blind hemifield, a posterior cortical lesion is usually present.



**Figure 7-1** Illusory palinopsia. A person with this condition perceives afterimages in the same location in the visual field as the original stimulus. (Reprinted from Gersztenkorn D, Lee AG. *Palinopsia revamped: a systematic review of the literature*. *Surv Ophthalmol*. 2015;60(1):1–35, with permission from Elsevier.)



Gersztenkorn D, Lee AG. Palinopsia revamped: a systematic review of the literature. *Surv Ophthalmol.* 2015;60(1):1–35.

Yun SH, Lavin PJ, Schatz MP, Lesser RL. Topiramate-induced palinopsia: a case series and review of the literature. *J Neuroophthalmol.* 2015;35(2):148–151.

### ***Aura and brief intermittent hallucinations due to migraine***

Abnormal excitatory activity in the cerebral cortex, followed by a wave of depressed neuronal function (*cortical spreading depression*), is believed to cause the visual phenomenon of aura due to migraine (see Chapter 13, Fig 13-1). In addition to the classic fortification spectrum (teichopsia), false sensation of motion (scintillations), and false perception of colors, patients may experience the so-called *Alice in Wonderland effect* (micropsia and/or macropsia), formed or unformed images, or visual distortion. Common patient descriptions of visual phenomena experienced during a migraine with aura include heat waves, cracked glass, kaleidoscopic vision, and fragmented vision.

In migraine with aura, binocular hemifield visual phenomena can last 5–60 minutes and are always followed by a headache (see Chapter 13). Patients may also experience *typical aura without headache*, previously called *acephalgic migraine*. Both phenomena (migraine with aura and typical aura without headache) as well as migraine (headache) without aura can occur in the same patient.

Many patients with migraine experience brief, simple, intermittent hallucinations, such as flashes or shooting stars, that are not associated with headache.

### ***Persistent positive visual phenomena***

These visual phenomena are often described as snow, television static, dots (black-and-white or colored), colored pixelated images, or a rainlike pattern affecting the entire visual field (Video 7-1). Such visual phenomena usually persist for months to years and, while bothersome, rarely interfere with visual function. They are commonly, but not exclusively, noted in patients with a personal or family history of migraine. Persistent positive visual phenomena are distinct from migraine aura and cannot be attributed to another disorder. Isolated visual snow (with no other neurologic or visual symptoms) may be a normal phenomenon.



**VIDEO 7-1** Visual snow.

Animation developed by Heather E. Moss, MD, PhD.



Schankin CJ, Maniyan FH, Digre KB, Goadsby PJ. “Visual snow”—a disorder distinct from persistent migraine aura. *Brain.* 2014;137(5):1419–1428.

### ***Sleep-associated visual hallucinations***

*Hypnagogic* hallucinations are vivid perceptual experiences that occur at sleep onset, whereas *hypnopompic* hallucinations are similar experiences that occur during awakening. Both phenomena are frequently associated with sleep disorders (eg, insomnia and excessive daytime sleepiness) and may be suggestive of narcolepsy.

***Hallucinations associated with vision loss***

Visually impaired patients with preserved cognitive status may experience visual hallucinations that are due to “release” of visual information by deafferented cortex (Charles Bonnet syndrome). *Release hallucinations* is a more general term that does not require intact cognitive status. The hallucinations may be

- formed or unformed
- persistent or abruptly intermittent
- simple or highly organized and complex

Patients with Charles Bonnet syndrome have a clear sensorium and realize that the hallucinations are not real, in contrast to individuals with Anton syndrome (discussed later in this chapter).

If the cause of the vision loss is known and there is no homonymous visual field defect, neuroimaging is unnecessary. Common underlying conditions include age-related macular degeneration, glaucoma, diabetic retinopathy, and cerebral infarction. Medical treatment is often unsuccessful in suppressing the hallucinations. Reassurance that the hallucinations are not indicative of psychiatric disease is important.

Hamedani AG. Vision loss and hallucinations: perspectives from neurology and ophthalmology. *Curr Opin Neurol*. 2021;34(1):84–88.

***Hallucinations associated with brain lesions***

Disruption of central nervous system function can cause hallucinations. Often, these hallucinations are associated with lesions visible on neuroimaging (eg, those due to stroke, tumor, congenital malformation). However, the dysfunctional region is not always apparent on imaging. Seizures are the most common cause of intermittent hallucinations in this setting.

In rare cases, lesions involving the midbrain, pons, or thalamus may cause formed hallucinations (*peduncular hallucinosis*) that can be constant or intermittent and are usually associated with an inverted sleep-wake cycle. Associated symptoms may occur when adjacent structures are involved.

Temporal lobe lesions usually produce olfactory and gustatory hallucinations. However, they can also cause complex, formed hallucinations in either the ipsilateral or contralateral visual field.

Parietal lobe disorders can cause formed or unformed hallucinations, whereas occipital lobe disorders commonly cause unformed hallucinations. Patients with occipital lobe lesions may describe white or colored flashes of light, kaleidoscopic colors, moving discs, flickering, or a hexagonal array (eg, chicken-wire or honeycomb patterns). A complete whiteout of vision suggests bilateral occipital lobe ischemia.

Celesia GG. Positive spontaneous visual phenomena. In: Celesia GG, ed. *Disorders of Visual Processing*. Elsevier; 2005:353–370. *Handbook of Clinical Neurophysiology*; vol 5.

***Hallucinations associated with neurodegenerative disease***

Patients with Parkinson disease or Lewy body dementia often experience formed hallucinations attributable to disease pathology and levodopa therapy. A minority of patients

with Alzheimer disease also experience complex hallucinations. In all three of these conditions, hallucinations are associated with functional and cognitive decline.

## Treatment of Illusions and Hallucinations

---

The approach to management of aura due to migraine is the same as that for migraine and consists of avoidance of triggers and daily medication as prophylaxis against episodes (for more detailed discussion, see Chapter 13). Similar approaches can be trialed for nonmigraine illusions and hallucinations with retrogeniculate origin, although success is often limited.

Education and reassurance regarding the basis of illusion and hallucination symptoms are important. In addition to treating the underlying ophthalmic or neurologic cause, ophthalmologists should be alert for impairment in activities of daily living associated with the visual symptoms. Low vision techniques can be helpful in such cases.

Difficulty coping with visual symptoms may lead to or exacerbate depressed mood or anxiety, treatment of which can improve quality of life. Patients with excessive thoughts, feelings, or behaviors related to their visual symptoms, even when the underlying cause is established, may have *somatic symptom disorder*, which can be treated with psychotherapy and psychotropic medications.

Morabito G, Barbi E, Giorgio C. The unaware physician's role in perpetuating somatic symptom disorder. *JAMA Pediatr.* 2020;174(1):9–10.

## Disorders of Higher Cortical Function

---

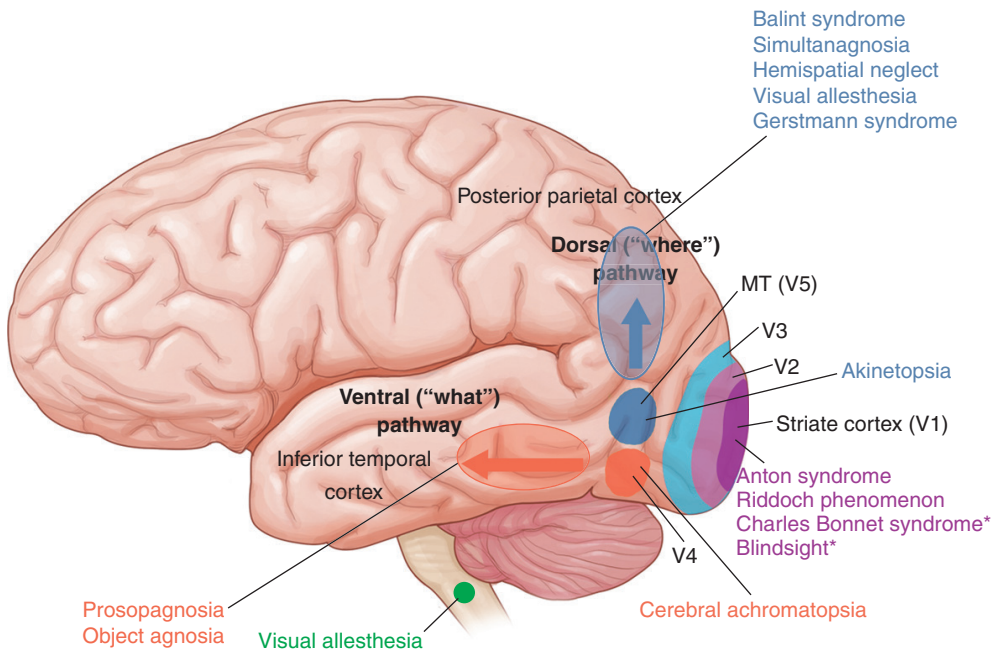
The process of seeing begins when visual information reaches the primary visual cortex (striate cortex, V1). For visual awareness to occur, this information must be processed by the associative cortical areas (see Chapter 1). Visual information is then projected through a ventral occipitotemporal pathway and a dorsal occipitoparietal pathway (see Chapter 1, Fig 1-27). The ventral pathway helps process the physical attributes of an image (the *what*), such as color, shape, and pattern. The dorsal pathway is responsible for visual-spatial analysis (the *where*) and for guiding movements toward items of interest. In addition, interconnecting pathways are crucial for transferring information from the primary visual cortex to visual association areas, including V2–V5.

In general, *syndromes* due to abnormal visual processing result either from damage to the cortical areas responsible for processing information or from interruption of information flow between cortical areas (*disconnection syndromes*). Disorders of higher cortical visual function may be further subdivided into disorders of recognition, of visual-spatial relationships, and of awareness of vision or visual deficit (Table 7-2, Fig 7-2).

Common causes of higher cortical visual dysfunction are focal lesions from strokes and tumors. Posterior cortical atrophy due to neurodegenerative conditions such as Alzheimer disease, corticobasal degeneration, or Creutzfeldt-Jakob disease is an important diagnostic consideration when patients demonstrate symptoms of disorders of higher cortical function and have normal neuroimaging findings.

**Table 7-2 Disorders of Higher Cortical Function**

Disorders of Recognition	Disorders of Visual–Spatial Relationships	Disorders of Awareness of Vision or Visual Deficit
Akinetopsia	Acquired ocular motor apraxia	Anton syndrome
Alexia without agraphia	Optic ataxia	Blindsight
Cerebral achromatopsia	Simultanagnosia	Hemispacial neglect
Object agnosia	Visual allesthesia	Riddoch phenomenon
Prosopagnosia		(staticokinetic dissociation)



**Figure 7-2** Sites of dysfunction leading to disorders of higher cortical function. Conditions marked with an asterisk can also be associated with vision loss caused by a lesion of the visual pathway anterior to this point. MT = middle temporal area.

Girkin CA, Miller NR. Central disorders of vision in humans. *Surv Ophthalmol.* 2001; 45(5):379–405.

Holden SK, Bettcher BM, Pelak VS. Update on posterior cortical atrophy. *Curr Opin Neurol.* 2020;33(1):68–73.

## Disorders of Recognition

### Object agnosia

Interruption of signal flow from the occipital lobe to the area of the temporal lobe involved in object identification results in an inability to recognize objects and is called

*object agnosia*. The condition, which is a form of visual–visual disconnection, often results from bilateral ventral pathway dysfunction that affects occipitotemporal projections. Patients with object agnosia can identify objects by touch or description but not by sight.

### **Prosopagnosia**

Prosopagnosia, the inability to recognize familiar faces, is a more specific form of agnosia. Affected patients also usually have difficulty performing other visual memory tasks. Prosopagnosia is often congenital; acquired cases result predominantly from stroke. The condition usually occurs with bilateral inferior occipitotemporal lobe damage but may also occur with right inferior occipital lobe damage. Accompanying superior homonymous visual field defects are common.

Schmidt D. Neuro-ophthalmological findings in patients with acquired prosopagnosia.

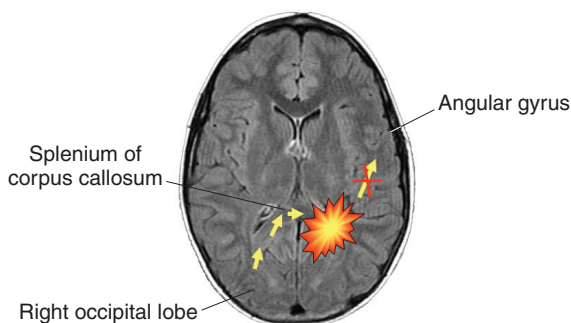
*Graefes Arch Clin Exp Ophthalmol.* 2015;253:333–334.

### **Akinetopsia**

Patients with pathology affecting the dorsal pathway to area V5 (also known as the middle temporal area) may experience akinetopsia, which is the loss of the perception of visual motion. However, these patients may still retain perception of form, texture, and color.

### **Alexia without agraphia**

During the act of reading, the right occipital lobe receives visual information from the left visual field. This information is transferred to the left side of the brain through the splenium of the corpus callosum and then relayed anteriorly to the angular gyrus of the parietal lobe for comprehension. When the splenium of the corpus callosum is damaged (usually due to infarction), the information from the left visual field (right occipital lobe) cannot cross to the opposite hemisphere (Fig 7-3). Typically, the left occipital lobe is also damaged and no visual input reaches the angular gyrus, resulting in alexia (ie, inability to read), a form of visual–verbal disconnection. However, because the structures anterior to the splenium are intact, the patient can produce language and write (alexia without agraphia). These patients cannot read what they have just written. When the left angular



**Figure 7-3** Alexia without agraphia. The diagram depicts the flow of information (*arrows*) from the right occipital lobe through the splenium of the corpus callosum to the angular gyrus of the parietal lobe. A lesion (*bright-colored polygon*) in the left occipital lobe obstructs this flow. (Courtesy of Eric Eggenberger, DO.)



gyrus is damaged, both reading and writing are affected (*alexia with agraphia*); in this setting, patients also often have acalculia, right–left confusion, and finger agnosia (*Gerstmann syndrome*).

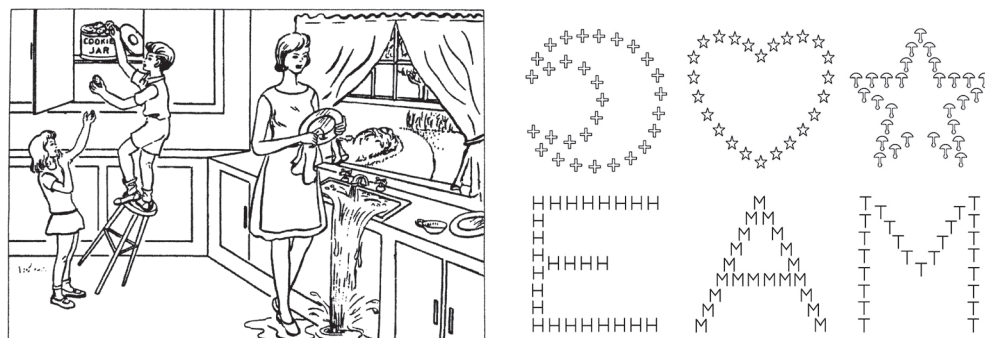
### **Cerebral achromatopsia**

In patients with bilateral inferior occipitotemporal lobe lesions (lingual and fusiform gyri; see Chapter 1), color discrimination may be abnormal. These patients cannot match colors or order them according to hue. Bilateral occipital ventromedial cortex damage may cause complete achromatopsia. Unilateral damage may cause hemiachromatopsia, which is often accompanied by superior homonymous visual field defects.

## **Disorders of Visual–Spatial Relationships**

### **Simultanagnosia**

Simultanagnosia, the failure to integrate multiple elements of a scene to form the total picture, suggests parietal lobe dysfunction. It can be assessed by asking patients to describe a complex scene (traditionally the “cookie theft picture” [Fig 7-4, left] is used), or a shape comprising smaller figures (Fig 7-4, right). A patient with simultanagnosia will describe only parts of the scene or the small figures and will not identify the larger scene or shape that they form. The cookie theft picture, developed in 1972, is included in the National Institutes of Health Stroke Scale, which is the gold standard for measuring clinical stroke severity. Modernized versions have been created for simultanagnosia assessment but are not in widespread use. Testing color vision with Ishihara pseudoisochromatic color plates may reveal simultanagnosia if the patient can identify the colors but not the shapes of numbers (ie, the patient does not see the whole picture as the sum of its parts).



**Figure 7-4** Bedside testing for simultanagnosia. (*Left panel*) The “cookie theft picture,” modified from the Boston Diagnostic Aphasia Examination and first published in 1972. (*Right panel*) Examples of Navon figures. When patients with simultanagnosia are asked to describe what they see in either panel, they will describe one part of the scene or the component characters without appreciating the larger scene or figure. (*Left image used with permission from Kline LB, Bajandas FJ. Neuro-Ophthalmology Review Manual. Rev. 5th ed. Slack; 2004:227. Right image from Kéita L, Bedoin N, Burack JA, Lepore F. Switching between global and local levels: the level repetition effect and its hemispheric asymmetry. Front Psychol. 2014;5:252.*)

Berube S, Nonnemacher J, Demsky C, et al. Stealing cookies in the twenty-first century: measures of spoken narrative in healthy versus speakers with aphasia. *Am J Speech Lang Pathol*. 2019;28(1 Suppl):321–329.

### **Balint syndrome**

Balint syndrome is a rare phenomenon resulting from bilateral occipitoparietal lesions. It consists of the triad of

- simultanagnosia
- optic ataxia, which is a disconnection between visual input and the motor system such that a visually guided task (eg, reaching for a silent object) cannot be completed, but an auditory task (eg, reaching toward a sound) can be
- acquired ocular motor apraxia, which is loss of voluntary movement of the eyes to fixate on a target (ie, psychic paralysis of gaze)

Clinically, these 3 findings rarely occur together.

### **Visual allesthesia**

Patients with visual allesthesia see their environment as rotated, flipped, or inverted, sometimes with objects displaced into opposite visual fields. These symptoms localize the lesion to either the lateral medullary region (*Wallenberg syndrome*) or the occipitoparietal area.

## **Disorders of Awareness of Vision or Visual Deficit**

### **Anton syndrome**

Patients with Anton syndrome characteristically have cortical visual impairment but deny having vision problems. These patients have no demonstrable visual behavior, but they hallucinate and confabulate visual images, leading them to conclude they can see. Directed questions about the visual environment are helpful to establish the diagnosis. Anton syndrome is most common in patients with bilateral occipital infarctions but has been described in persons with blindness from bilateral optic nerve lesions.

### **Riddoch phenomenon**

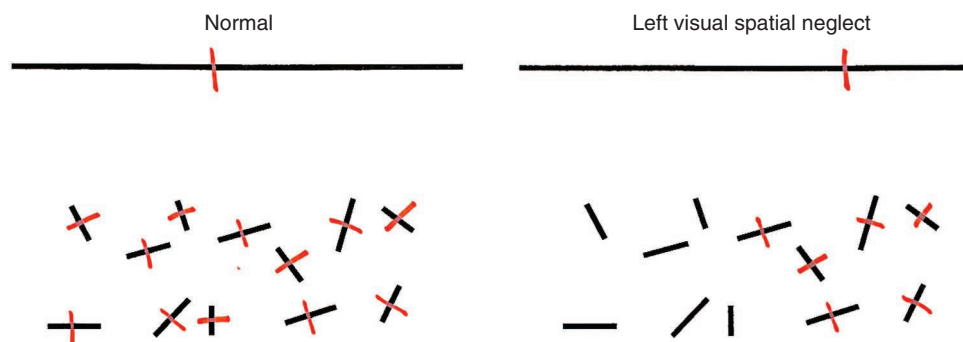
Preservation of the perception of motion in a blind hemifield is called *staticokinetic dissociation*, or the Riddoch phenomenon. When present in an otherwise complete homonymous hemianopia, this phenomenon is thought to portend a better visual prognosis.

### **Blindsight**

Cortically blind patients may have an unconscious rudimentary visual perception (blindsight). This condition can occur after severe damage to the retrogeniculate visual pathway and has been speculated to result from spared visual inputs to the superior colliculus, processing in the lateral geniculate nucleus, or incomplete injury to the primary visual cortex.

### **Hemispatial neglect**

Patients with hemispatial neglect (ie, hemineglect) will not acknowledge seeing objects in 1 hemifield (usually the left). On examination, when presented with *simultaneous* stimuli in both hemifields, patients with hemispatial neglect will perceive only the stimulus in



**Figure 7-5** Examination results demonstrating normal vision (*left*) and left hemispatial neglect (*right*). In the top task, each patient is asked to divide the line in half. The patient without neglect performs the task as instructed, and the patient with left hemispatial neglect performs this task to the right of midline. In the bottom task, each patient is asked to bisect each line. The patient without neglect performs this task as instructed, and the patient with left hemispatial neglect performs this task only on lines in the nonneglected field. (Courtesy of Heather E. Moss, MD, PhD.)

the nonneglected field; however, they will see the stimulus when it is presented in the neglected hemifield *alone* (extinction) (see Chapter 3). Other examination techniques include asking the patient to draw a clock face or to bisect a horizontal line. Patients with hemispatial neglect will label only half the clock and will not bisect the line in the middle (Fig 7-5). Hemispatial neglect usually results from damage in the right hemisphere (eg, the posterior parietal cortex, frontal eye fields, cingulate gyrus), which mediates attention in both hemifields.



# The Patient With Abnormal Ocular Motility or Diplopia



This chapter includes related videos. Go to [www.aao.org/bcscvideo\\_section05](http://www.aao.org/bcscvideo_section05) or scan the QR codes in the text to access this content.



This chapter also includes a related activity. Go to [www.aao.org/bcscactivity\\_section05](http://www.aao.org/bcscactivity_section05) or scan the QR code in the text to access this content.

## Highlights

---

- Diplopia is typically caused by disruption of the infranuclear or internuclear pathways of the efferent visual system.
- Cranial nerve (CN) III, IV, and VI palsies cause diplopia with distinct strabismus patterns that can be differentiated on the basis of a detailed ocular motility examination.
- CN III palsy with or without pupillary involvement is due to an intracranial aneurysm until proven otherwise.
- When diplopia does not follow a specific CN pattern, other causes, such as myasthenia gravis, thyroid eye disease, and carotid-cavernous fistula, should be considered.

## Introduction

---

The *efferent visual system*, introduced in Chapter 1, controls ocular movements. Like all efferent nervous systems, the ocular motor system consists of supranuclear and infranuclear pathways. The supranuclear pathways originate from multiple locations and innervate the CN nuclei. *Prenuclear* is a more accurate term than *supranuclear* because some of these pathways (eg, the vestibular pathways) originate inferior to the CN nuclei. However, the term *supranuclear* is used throughout the literature and will be used in this chapter and Chapter 9 as well.

The infranuclear pathways originate in the CN nuclei and innervate the extraocular muscles (EOMs). The distinction between the supranuclear and infranuclear pathways is clinically important because supranuclear disorders almost always affect both eyes similarly, whereas infranuclear disorders affect each eye differently. The patterns of symmetric dysfunction that occur with supranuclear disorders typically do not produce diplopia, although exceptions such as skew deviation exist. Conversely, infranuclear lesions usually produce



diplopia. The main internuclear pathway of the efferent system is the medial longitudinal fasciculus (MLF), which connects the CN VI nucleus to the contralateral CN III nucleus.

Supranuclear pathways include the

- premotor and motor regions of the frontal and parietal cortices
- cerebellum
- basal ganglia
- superior colliculi
- thalamus (dorsal lateral geniculate nucleus and pulvinar nuclei)
- brainstem centers (paramedian pontine reticular formation [PPRF], neural integrators, and vestibular nuclei)

The internuclear pathway is the

- MLF

Infranuclear pathways include the

- ocular motor CN nuclei
- intramedullary segments of the ocular motor CNs
- peripheral segments of the ocular motor CNs (coursing through the subarachnoid space, cavernous sinus, superior orbital fissure, and orbit)
- neuromuscular junction
- EOMs

Most patients with acquired ocular motility disorders will have diplopia unless the motility limitation is symmetric. Depending on their motility limitation, some patients without diplopia in primary gaze will have diplopia in horizontal or vertical gaze. Diplopia can also occur in patients with full ocular motility.

For a review of strabismus terminology and for additional information on many of the topics covered in this chapter, see BCSC Section 6, *Pediatric Ophthalmology and Strabismus*.

## History

---

Answers to the following questions offer important insights into the nature of a patient's diplopia:

- Does the diplopia resolve when either eye is covered (monocular vs binocular diplopia)?
- Is the diplopia horizontal, vertical, oblique, or torsional?
- Is the diplopia the same in all fields of gaze (comitant) or does it vary with gaze direction (incomitant)?
- Is the diplopia constant, intermittent, or variable?

Patients with an ocular misalignment may report double vision or simply “blurred vision.” If closing either eye eliminates the visual disturbance, the blurred vision can be attributed to ocular misalignment (“binocular blur”). If binocular diplopia resolves when the patient closes either eye, the diplopia results from misalignment of the visual axes. It is helpful to determine whether the double vision is more bothersome with far or near fixation or in a specific gaze

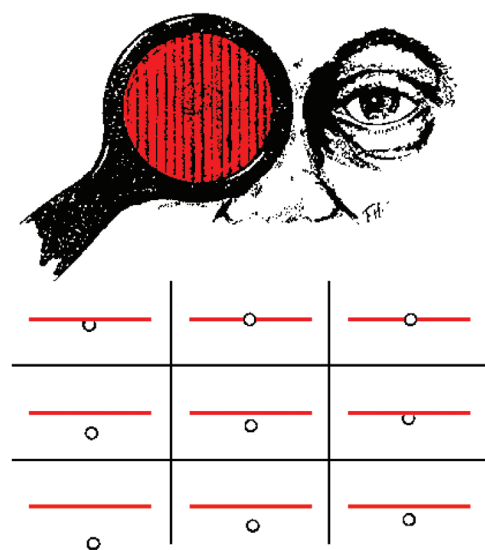
position. Ascertaining whether the patient has a history of head or eye pain, eye or eyelid swelling or redness, numbness, or other neurologic symptoms provides clues about possible orbital, cavernous sinus, or central nervous system causes of diplopia. The time of onset, duration, and modifying factors should also be documented. When a differential diagnosis for binocular diplopia is formulated, it is also important to establish whether there is any history of malignancy, trauma, prior strabismus surgery, thyroid disease, or generalized weakness.

## Physical Examination

Maintaining alignment of the visual axes depends on coordinating the movement of both eyes. External examination may reveal obvious clues to the origin of the patient's diplopia, especially if proptosis or ocular redness is present. The movement of the eyes should be assessed in all positions of gaze, both individually (*ductions*) and together (*versions*).

Establishing whether ocular misalignment is comitant or incomitant is important. In general, comitant misalignment is more commonly present in congenital strabismus, whereas incomitant misalignment suggests an acquired disorder. Abnormal ductions can often be recognized by gross observation, but formal measurement of the amount of misalignment with a prism and alternate cover test (PACT) is used to determine (quantitate) whether an ocular misalignment is comitant or incomitant.

The Maddox rod test, a sensitive method of obtaining information about the degree and pattern of ocular misalignment (Fig 8-1), can help reveal subtle cases of strabismus, especially vertical deviations. When viewing a light source through a red Maddox rod, which contains a series of parallel cylinders, the patient sees a line perpendicular to the orientation of the cylinders. Typically, a red Maddox rod is placed in front of the right eye, producing a red line, while the left eye views the fixation light. Viewing such disparate



**Figure 8-1** Maddox rod shown with the ridges held vertically, which causes the patient to see a horizontal red line. In this example, the light seen by the left eye is under the red line, indicating a left hyperdeviation, which increases on down right gaze. This finding is compatible with left superior oblique dysfunction.

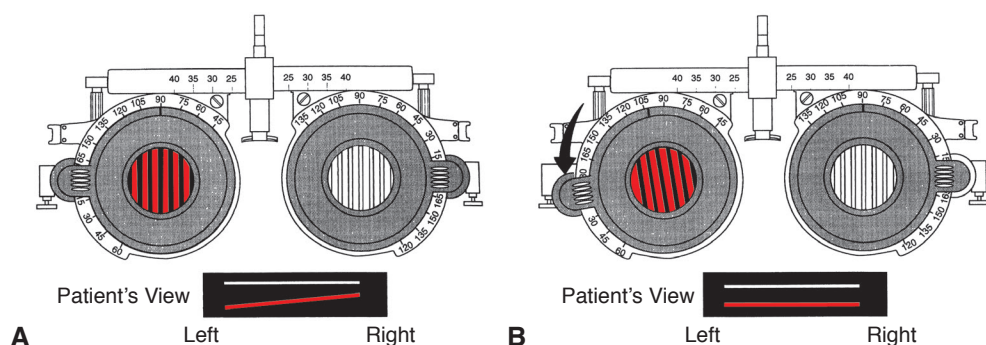
images often makes it easier for patients to appreciate the misalignment of the visual axes. Because this test dissociates the 2 eyes, patients who have a phoria will also report diplopia. Therefore, it is often useful to combine the subjective results of Maddox rod tests with the more objective results of the cover-uncover test. PACT is used to determine the total deviation, which is the manifest deviation (measured with the simultaneous prism and cover test) plus the phoria (see BCSC Section 6, *Pediatric Ophthalmology and Strabismus*). It is important to pay attention to the pattern of misalignment in all 9 positions of gaze (and, in some cases, to head tilt).

The double Maddox rod test helps identify and quantify torsional misalignment. Traditionally, a red Maddox rod is placed in front of the right eye and a white Maddox rod in front of the left eye (Fig 8-2). Because patients may assume that the white line is oriented correctly and falsely localize the abnormal torsion to the red line (right eye), this test can be performed with a red lens in front of each eye to minimize this issue.

A qualitative method for detecting relative cyclotropia uses a horizontal line. A base-down prism is placed over 1 eye to dissociate the images such that 2 vertically displaced lines are visible. The patient is asked whether both lines are parallel or if they converge to 1 side. A CN IV palsy is typically associated with convergence of the lines toward the side of the palsy. A CN IV palsy may also be suspected if indirect ophthalmoscopy reveals appreciable extorsion of the ipsilateral fundus (ie, anatomically, the fovea is below the inferior optic nerve head [ONH] margin, but on indirect ophthalmoscopy, the fovea appears above the superior margin of the ONH).

The presence of ocular deviation may be signaled by a consistent head tilt or head turn on examination. Old photographs (eg, a driver's license photograph) may provide evidence of chronicity.

Simons K, Arnoldi K, Brown MH. Color dissociation artifacts in double Maddox rod cyclodeviation testing. *Ophthalmology*. 1994;101(12):1897–1901.



**Figure 8-2** Double Maddox rod test for extorsion. **A**, A patient with vertical diplopia sees the red line below the white line, indicating a right hypertropia. With cyclotropia, the 2 lines do not appear parallel. **B**, The red Maddox rod is then rotated (arrow) until the 2 lines appear parallel. The degree of rotation required to make the lines appear parallel (in this case about 12°) quantitates the amount of extorsion. (Reproduced with permission from Kline LB, Bajandas FJ. *Neuro-Ophthalmology Review Manual*. Rev. 5th ed. Slack; 2004. Originally modified from Van Noorden GK. *Atlas of Strabismus*. 4th ed. Mosby; 1983.)

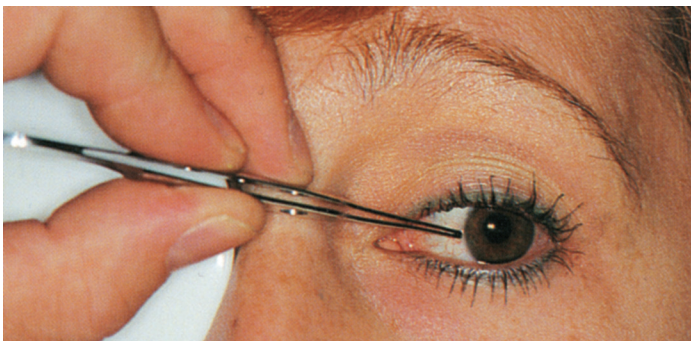
## Monocular Diplopia

Patients may describe optical aberrations as distorted or double vision. Monocular diplopia usually results from abnormalities of the refractive media (eg, uncorrected astigmatism, corneal irregularities such as keratoconus, tear film issues, and cataract). The characteristics of optical causes are seeing ghost images, haloes, or more than 2 images. Monocular diplopia that resolves with use of a pinhole proves the disorder has an optical origin. Less commonly, monocular diplopia can arise from retinal pathology (eg, maculopathy with retinal distortion by fluid, hemorrhage, or fibrosis). However, more commonly retinal pathology can result in binocular diplopia (see the section Foveal Displacement Syndrome later in this chapter). Cerebral monocular diplopia or polyopia is always bilateral and extremely rare.

## Differentiating Paretic From Restrictive Causes of Diplopia

In patients with proptosis, enophthalmos, or a history of orbital trauma or eye surgery, restriction of eye movements should be strongly suspected as the cause of diplopia. The most common causes of restrictive strabismus are thyroid eye disease (TED) and orbital trauma; these conditions are typically associated with orbital signs and symptoms. Diplopia in patients with orbital trauma may have both neural and restrictive components.

Paretic and restrictive syndromes can be distinguished by assessing saccadic speed. Paretic conditions reduce saccadic velocity, whereas restrictive conditions do not. If this method does not provide an answer, the examiner may perform a *forced duction test* (Fig 8-3, Video 8-1). A restrictive process produces a mechanical limitation of the range of eye movements that can often be felt by the examiner when forceps or a cotton swab is used to advance the limited eye movement. Long-standing, chronic neural lesions may also cause mechanical limitation from gradual shortening of the unopposed antagonist muscle; therefore, a “tight” muscle may not always represent a primary restrictive process.



**Figure 8-3** Forced duction testing. Before the eye is grasped with forceps, topical proparacaine drops are applied to the eye and held over the limbal region with a cotton tip for 1–2 minutes. This patient has an esotropia and limited abduction of the left eye. The conjunctiva is grasped with toothed forceps and the globe passively rotated in the direction of limited abduction to assess for restriction of the eye movement. (Reproduced with permission from Yanoff M, Duker JS, eds. *Ophthalmology*. 2nd ed. Mosby; 2004:569.)

Computed tomography (CT) or magnetic resonance imaging (MRI) of the orbits can be useful in confirming most restrictive sources of diplopia.



#### VIDEO 8-1 Forced duction testing.

Courtesy of Sasha Mansukhani, MBBS. Narrated by John J. Chen, MD, PhD.



## Comitant and Incomitant Deviations

As previously mentioned, comitant misalignment is characteristically observed in patients with congenital or early-onset strabismus. Patients with this condition typically do not report diplopia because of *suppression*, an adaptation that reduces the responsiveness of the visual neurons in the occipital cortex to the input from 1 eye (see BCSC Section 6, *Pediatric Ophthalmology and Strabismus*, Chapter 4, Fig 4-6). Patients with a history of childhood strabismus may experience diplopia later in life if their ocular misalignment changes. For example, in patients with a long-standing exophoria, horizontal diplopia may develop in the fifth decade of life, when accommodation and convergence amplitudes wane.

Conversely, an incomitant deviation may become comitant with the passage of time. This spread of comitance may occur with either a restrictive or paretic incomitant deviation and is especially likely with a CN IV palsy.

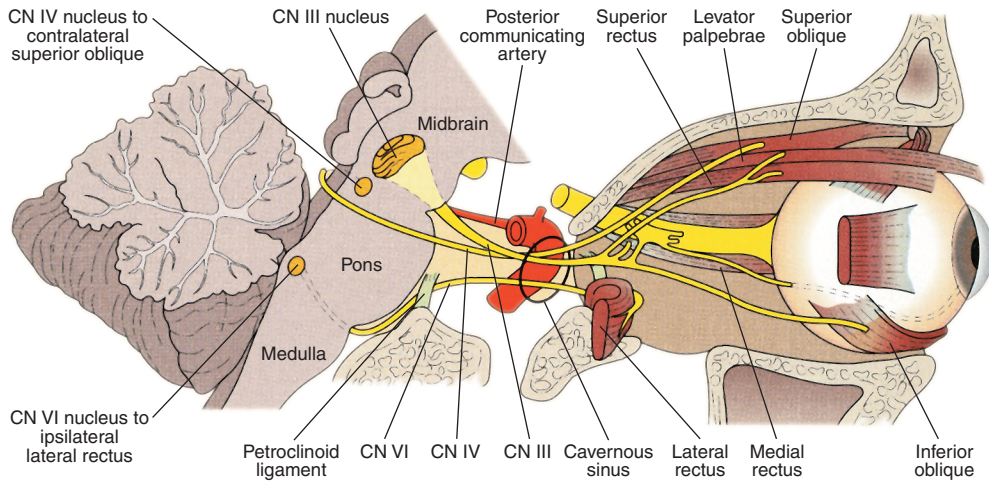
In general, incomitant strabismus is most frequently acquired and usually causes diplopia. If the deviation is very small, fusion may align the eyes and eliminate diplopia. Relatively small misalignments may produce blurred vision rather than an obvious perception of 2 images. Patients with subnormal vision may not recognize diplopia or may have difficulty articulating how their visual perception changes in various positions of gaze. Congenital incomitant deviations, such as those caused by overaction of the inferior oblique muscles, typically do not produce diplopia, even when the strabismus is obvious.

## Localization of Potential Lesions

Because many eye movement disorders have a neural basis, localizing a potential lesion that might be producing the patient's eye movement disorder is important. Anatomical localization will dictate patient evaluation, including imaging modality and differential diagnosis. Also, it is useful to conceptualize the anatomical pathway of the ocular motor system (ie, EOMs, neuromuscular junction, orbit, CNs, brainstem, premotor input, and cerebrum) that is assumed to be involved (Fig 8-4). Adopting this kind of "wiring diagram" approach takes into account the supranuclear, internuclear, nuclear, and fascicular pathways within the brainstem, which then traverse the subarachnoid space, cavernous sinus, superior orbital fissure, and orbit, ending in the neuromuscular junctions of the EOMs. In general, a lesion involving the CN nucleus or fascicle will cause neurologic deficits in addition to ophthalmoparesis (discussed later in the chapter). Brainstem lesions can produce a clinically isolated CN III, IV, or VI palsy, but such isolated cranial neuropathies are the exception.

Attempts at neural localization may fail or give false results in the presence of diffuse disease (eg, meningeal inflammation, as in sarcoidosis). In addition, this approach is not





**Figure 8-4** Anatomical framework for localizing lesions of the infranuclear ocular motor pathways. This schematic provides a lateral view of cranial nerves (CNs) III, IV, and VI from the brainstem nuclei to the orbit. The CN segments within the brainstem are referred to as being “intramedullary” or “fascicular.” The subarachnoid space lies between the brainstem and cavernous sinus. CN III exits the midbrain anteriorly, crosses near the junction of the internal carotid and posterior communicating arteries in the subarachnoid space, and enters the cavernous sinus, where it runs in the lateral wall. CN IV exits the midbrain posteriorly and crosses to the opposite side. It then courses through the subarachnoid space and into the cavernous sinus. CN VI exits the pons anteriorly, ascends along the clivus, crosses the petrous apex, and passes below the petroclinoid ligament to enter the cavernous sinus, where it runs between the lateral wall and the carotid artery. (Reproduced with permission from Yanoff M, Duker JS, eds. *Ophthalmology*. 2nd ed. Mosby; 2004:1324.)

helpful in a clinical syndrome, such as Wernicke encephalopathy, in which imaging may not show characteristic structural disturbances in areas expected to cause the motility abnormalities but rather changes in the mamillary bodies.

## Supranuclear Causes of Abnormal Ocular Motility

Most supranuclear disorders affect both eyes equally and therefore do not cause diplopia. However, certain supranuclear lesions do not result in a symmetric effect and thus may produce ocular misalignment and diplopia (Table 8-1). Supranuclear disorders are discussed in Chapter 9.

**Table 8-1 Supranuclear Ocular Motor Lesions That Produce Strabismus and Diplopia**

Convergence insufficiency or spasm
Divergence insufficiency
Ocular tilt reaction
Skew/alternating skew deviation
Thalamic esodeviation

## Nuclear Causes of Diplopia

The ocular motor nuclei are the start of the infranuclear motor pathways. Nuclear CN lesions are rare but cause localizable ocular motor abnormalities owing to the distinct anatomy of the nuclei. These abnormalities are important to identify because their presence indicates a structural lesion, such as stroke, tumor, or inflammation.

The CN III nucleus is actually a nuclear complex that contains subnuclei for 4 EOMs (superior, inferior, and medial recti; and inferior oblique), a single subnucleus (central caudal nucleus) for the levator palpebrae muscles, and paired subnuclei (Edinger-Westphal nuclei) for the pupillary constrictor muscles (see Chapter 1, Fig 1-36). Because the single central caudal nucleus controls both levator palpebrae superioris muscles, and the superior rectus fascicles decussate just after emerging from their subnuclei, lesions of the CN III nuclear complex either equally affect or spare both upper eyelids. These lesions may also affect the contralateral superior rectus muscle or potentially affect both superior rectus muscles because the axons from 1 superior rectus subnucleus pass adjacent to the opposite superior rectus subnucleus. Injury to the CN III nuclear complex, while uncommon, may occur secondary to reduced vascular perfusion through a small, paramedian-penetrating blood vessel, causing unilateral damage to 1 nuclear complex. Such lesions are often asymmetric and may affect the CN III fascicle on 1 side in addition to the nucleus.

A CN IV nuclear lesion causes contralateral superior oblique weakness because CN IV decussates as it exits the midbrain. Microvascular, inflammatory, neoplastic, or demyelinating lesions may involve the central course of CN IV. Occasionally, a CN IV palsy is accompanied by a contralateral Horner syndrome (first-order neuron lesion), because of the proximity of the descending sympathetic pathway to the caudal portion of the nucleus. A CN IV nuclear lesion may also be associated with a relative afferent pupillary defect, because of the pupillary fibers running in the nearby brachium of the superior colliculus.

A selective lesion of the CN VI nucleus causes a horizontal gaze palsy and not only an isolated abduction paresis in 1 eye (Activity 8-1); therefore, patients with this lesion may not experience diplopia. This occurs because the CN VI nucleus contains 2 populations of motoneurons: (1) those that innervate the ipsilateral lateral rectus muscle; and (2) those that travel via the MLF to innervate the contralateral medial rectus subnucleus of the CN III nuclear complex. Often, ipsilateral upper and lower facial weakness is also present with a nuclear CN VI palsy due to involvement of the adjacent facial nerve fascicle (eg, facial colliculus syndrome).



### ACTIVITY 8-1 The effect of brainstem lesions on horizontal eye movements.

Developed by John J. Chen, MD, PhD, and Paul H. Phillips, MD.



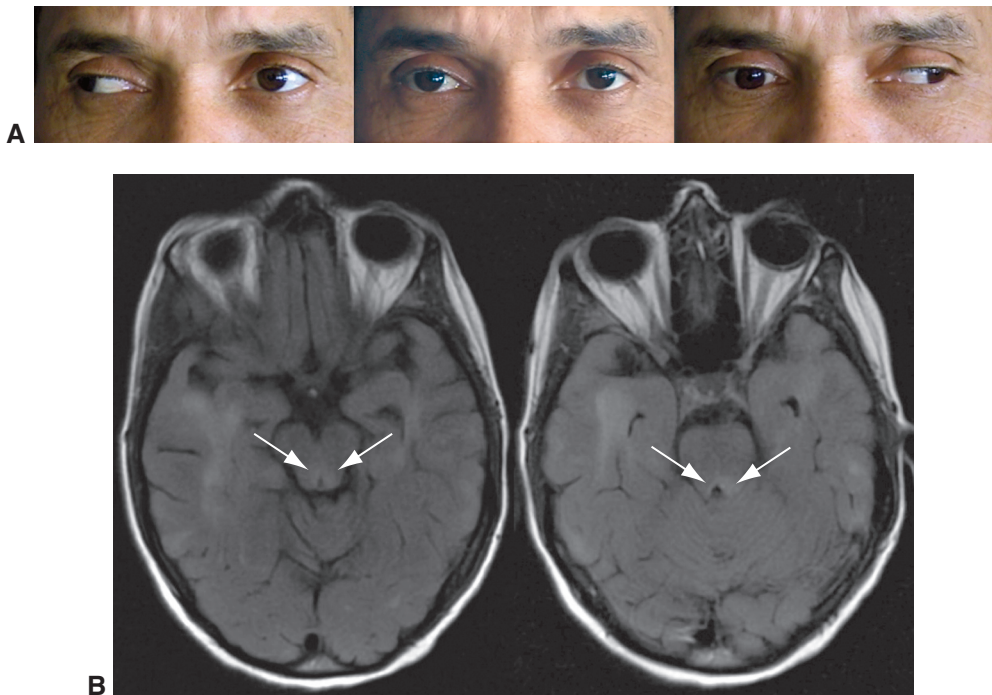
Elliott D, Cunningham ET Jr, Miller NR. Fourth nerve paresis and ipsilateral relative afferent pupillary defect without visual sensory disturbance. A sign of contralateral dorsal midbrain disease. *J Clin Neuroophthalmol*. 1991;11(3):169–172; discussion 173–174.

## Internuclear Causes of Diplopia

In the context of eye movement control, an “internuclear” lesion is one that disrupts the MLF, a bundle of fibers that connects the CN VI nucleus on one side of the pons to the medial rectus subnucleus (of CN III) on the contralateral side of the midbrain (see Chapter 1, Fig 1-33). This type of lesion produces an *internuclear ophthalmoplegia (INO)*.

### Internuclear Ophthalmoplegia

The cardinal sign of a unilateral INO is slowed adducting saccadic velocity in 1 eye, usually associated with abducting nystagmus of the fellow eye. The INO is named for the side with limited or slowed adduction (ie, a right INO refers to limited or slowed adduction of the right eye secondary to an MLF lesion on the right side of the brainstem). The eye with the slowed adduction may have a full or limited range of adduction (Fig 8-5, Videos 8-2, 8-3; see also Activity 8-1). Convergence may be spared or disrupted. Patients with INO may report horizontal diplopia; they may also experience vertical-oblique diplopia owing to an associated skew deviation (see Chapter 9 for more details), episodic diplopia related



**Figure 8-5** Bilateral internuclear ophthalmoplegia in a 53-year-old man with diplopia on lateral gazes. **A**, Horizontal gaze in either direction results in full abduction of the ipsilateral eye but virtually no adduction of the contralateral eye. Alignment in primary gaze (*center panel*) is nearly orthotropic. **B**, Axial fluid-attenuated inversion recovery (FLAIR) magnetic resonance imaging (MRI) brain scan shows edema (bright signal indicated by *arrows*) in the area of the medial longitudinal fasciculus bilaterally at the level of the upper midbrain (*left*) and pons (*right*). (Courtesy of Prem S. Subramanian, MD, PhD.)

to head–eye movements if the lesion is partial, or difficulty tracking fast-moving objects (eg, when playing sports) because of the mismatch in saccadic velocity between the eyes.



**VIDEO 8-2** Left internuclear ophthalmoplegia.

Courtesy of M. Tariq Bhatti, MD. Narration by Zoë R. Williams, MD.



**VIDEO 8-3** Bilateral internuclear ophthalmoplegia.

Courtesy of John J. Chen, MD, PhD.



A bilateral INO produces bilateral adduction lag and bilateral abducting nystagmus and can be associated with *vertical gaze-evoked nystagmus* that is most noticeable in up-gaze. This nystagmus is due to disruption of vertical vestibular and gaze-holding pathways, which ascend from the vestibular nuclei through the MLF. A large-angle exotropia may occur in bilateral INO (ie, “wall-eyed” bilateral INO, or *WEBINO*, syndrome) and is often caused by a midbrain lesion near the CN III nuclei.

The 2 most common causes of INO, whether unilateral or bilateral, are demyelination and stroke. In adolescents and younger adults, INO is typically caused by demyelination. In older adults, stroke is the most common cause. Other causes include infection, neoplasm, trauma, and progressive supranuclear palsy. Myasthenia gravis can produce pseudo-INO, which usually lacks the vertical gaze-evoked nystagmus of a true INO and is often accompanied by myasthenic eyelid signs. The adduction paresis of myasthenic pseudo-INO usually resolves transiently after intravenous administration of edrophonium and typically responds to appropriate systemic therapy (see Chapter 15).

Amezcuca L, Morrow MJ, Jirawuthiworavong GV. Multiple sclerosis: review of eye movement disorders and update of disease-modifying therapies. *Curr Opin Ophthalmol*. 2015;26(6):534–539.

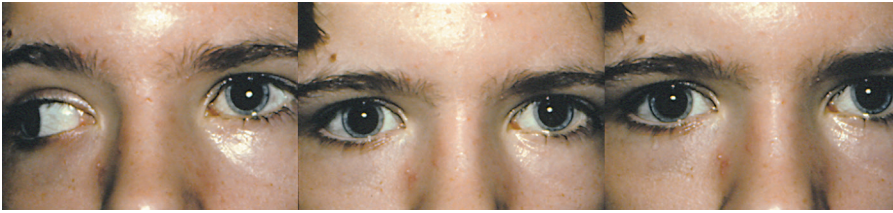
Frohman TC, Galetta S, Fox R, et al. Pearls & Oy-sters: the medial longitudinal fasciculus in ocular motor physiology. *Neurology*. 2008;70(17):e57–e67.

McGettrick P, Eustace P. The W.E.B.I.N.O. syndrome. *Neuroophthalmology*. 1985;5(2):109–115.

Mills DA, Frohman TC, Davis SL, et al. Break in binocular fusion during head turning in MS patients with INO. *Neurology*. 2008;71(6):458–460.

## One-and-a-Half Syndrome

One-and-a-half syndrome, which combines a horizontal gaze palsy and ipsilateral INO (Fig 8-6; see also Activity 8-1), is caused by a pontine abnormality that is large enough to involve the MLF and the PPRF or the CN VI nucleus on the same side of the brainstem. The only horizontal eye movement remaining unaffected is abduction of the eye contralateral to the lesion (ie, horizontal eye movements are lost in 1 eye, whereas they are “half” lost in the fellow eye, hence the name). Vertical gaze is preserved. A lesion that produces one-and-a-half syndrome but also involves the intra-axial portion of CN VII is called *eight-and-a-half syndrome* ( $7 + 1.5 = 8.5$ ). Stroke is the most common cause of this disorder in older adults, and demyelination the most common cause in young patients.



**Figure 8-6** One-and-a-half syndrome. This 15-year-old patient had a brainstem glioma that caused a gaze palsy to the left (*right photograph*) and a left internuclear ophthalmoplegia (evident here as incomplete adduction of the left eye on gaze to the right; *left photograph*). The only intact horizontal eye movement was abduction of the right eye. (Courtesy of Steven A. Newman, MD.)

Espinosa PS. Teaching NeuroImage: one-and-a-half syndrome. *Neurology*. 2008;70(5):e20.

Johkura K, Kudo Y, Amano Y, et al. Gaze palsy and exotropia in internuclear ophthalmoplegia.

*J Neurol Sci*. 2015;353(1–2):158–160.

## Ocular Motor Cranial Nerve Palsies

Many isolated CN palsies in older adults result from microvascular disease. It is believed that most ischemic CN palsies occur within the subarachnoid segment of the ocular motor CNs, which extends from the brainstem to the cavernous sinus, where the nerves exit the dura. Ischemic cranial mononeuropathies typically occur in isolation in older patients, with maximal deficit at presentation, but the loss of function occasionally progresses over 7–10 days. Although these disorders are typically painless, pain can be present and may be severe in some patients. Therefore, pain does not distinguish ischemia from aneurysmal compression or other causes of CN palsy.

Ocular misalignment due to ischemic ocular motor CN palsy almost always improves over time, and the diplopia usually resolves within 6 months. Patients require medical evaluation for ischemic risk factors, including diabetes mellitus, hypertensive vascular disease, and elevated serum lipid levels. Progression of ocular misalignment beyond 2 weeks or failure to improve within 3 months is not typical for an ischemic cause of a cranial neuropathy and warrants prompt, thorough evaluation for another cause. Multiple simultaneous CN palsies also prompt a workup for an alternative cause. An isolated mononeuropathy of CN III warrants special attention and typically requires neuroimaging because of the nerve's anatomical proximity to the cerebral vasculature (especially the posterior communicating artery [PCoA]) and the potential for aneurysmal compression (discussed later in this chapter).

Myasthenia gravis may mimic any pattern of painless, pupil-sparing EOM dysfunction and belongs in the differential diagnosis of such cases. Up to 15% of patients with giant cell arteritis (GCA) present with diplopia (which may be transient) that results from a skew deviation, ischemic cranial neuropathy, or EOM ischemia; thus, GCA should be considered in older adults with new-onset diplopia, especially if they have systemic symptoms of GCA (see Chapter 15). Any patient with a history of cancer and an ocular motor cranial neuropathy should undergo neuroimaging to rule out a compressive or infiltrative lesion.



## Intra-axial Ocular Motor Cranial Nerve Palsies

Intra-axial (*fascicular*) ocular motor CN palsies are due to lesions of the nerve that are distal to its nucleus but within the confines of the brainstem. A brainstem lesion tends to affect many structures and therefore produces numerous deficits, allowing accurate topographic localization of the lesion. It is important to recognize a brainstem lesion because its presence requires neuroimaging to determine the etiology. In the midbrain, intra-axial lesions can damage either CN III or CN IV. Intra-axial involvement of the CN III fascicle can produce 1 of 4 syndromes, each of which includes an ipsilateral CN III palsy:

- Damage to the ventral midbrain and the cerebral peduncle can cause a contralateral hemiparesis (*Weber syndrome*, or *alternating oculomotor hemiplegia*).
- Involvement of the red nucleus and substantia nigra may produce contralateral ataxia or tremor (*Benedikt syndrome*, or *tegmental mesencephalic paralysis*).
- Damage to the dorsal midbrain may involve the superior cerebellar peduncle and produce contralateral ataxia (*Claude syndrome*, or *rubrospinal cerebellar peduncle syndrome*).
- A dorsal lesion with a slightly different configuration can produce the same type of ataxia as in Claude syndrome plus a CN III nuclear lesion and features of supra-nuclear eye movement dysfunction (*Nothnagel syndrome*).

The localization, direct anatomical correlations, and physical findings of these lesions are more important than the eponyms, especially because the use and definitions of these eponyms have varied in the literature.

Fascicular lesions of CN IV are rare, given the relatively short course of the nerve within the brainstem. A lesion of the CN IV fascicle is clinically identical to a nuclear lesion (both cause contralateral superior oblique weakness). Other brainstem symptoms can be present, including hemisensory loss, hemiparesis, an ipsilesional Horner syndrome, or other brainstem cranial neuropathies. Pineal tumors may compromise the proximal course of both CNs IV by compressing the tectum of the midbrain. Such lesions may also obstruct the aqueduct of Sylvius, leading to elevated intracranial pressure and hydrocephalus as well as dorsal midbrain syndrome (see Chapter 9).

Intra-axial lesions of the CN VI fascicle within the pons may also injure CN VII, whose fibers curve around the CN VI nucleus at the *facial genu* (see Chapter 1, Fig 1-44). Intra-axial lesions that involve the CN VI fascicle may also damage the tractus solitarius and the descending tract of CN V, resulting in an ipsilateral abduction palsy, facial weakness, loss of taste over the anterior two-thirds of the tongue, and facial hypoesthesia (*Foville syndrome*). Lesions of the ventral pons can damage CN VI and CN VII along with the corticospinal tract, producing contralateral hemiplegia, ipsilateral facial weakness, and abduction deficit (*Millard-Gubler syndrome*), or they may spare CN VII but still affect the corticospinal tract, causing contralateral hemiplegia and ipsilateral abduction deficit (*Raymond syndrome*).

Liu GT, Crenner CW, Logigian EL, Charness ME, Samuels MA. Midbrain syndromes of Benedikt, Claude, and Nothnagel: setting the record straight. *Neurology*. 1992; 42(9):1820–1822.

### Third Cranial Nerve Palsy

Cranial nerve III palsies can cause dysfunction of the somatic muscles (superior, inferior, and medial recti; inferior oblique; and levator palpebrae superioris) and the autonomic muscles (pupillary sphincter and ciliary) (Video 8-4). A complete CN III palsy presents with downward and outward deviation of the eye; complete ptosis; and the inability to adduct, infraduct, or supraduct the eye. The pupil may or may not be involved in a complete CN III palsy. Pupillary involvement, discussed in the next sections, is a critical distinction in a CN III palsy. Partial CN III palsies are more common than complete CN III palsies; patients present with different amounts of limitation of supraduction, infraduction, adduction, and different degrees of ptosis with or without pupillary dysfunction (Fig 8-7).



#### VIDEO 8-4 Right CN III palsy.

Courtesy of M. Tariq Bhatti, MD. Narration by Zoë R. Williams, MD.



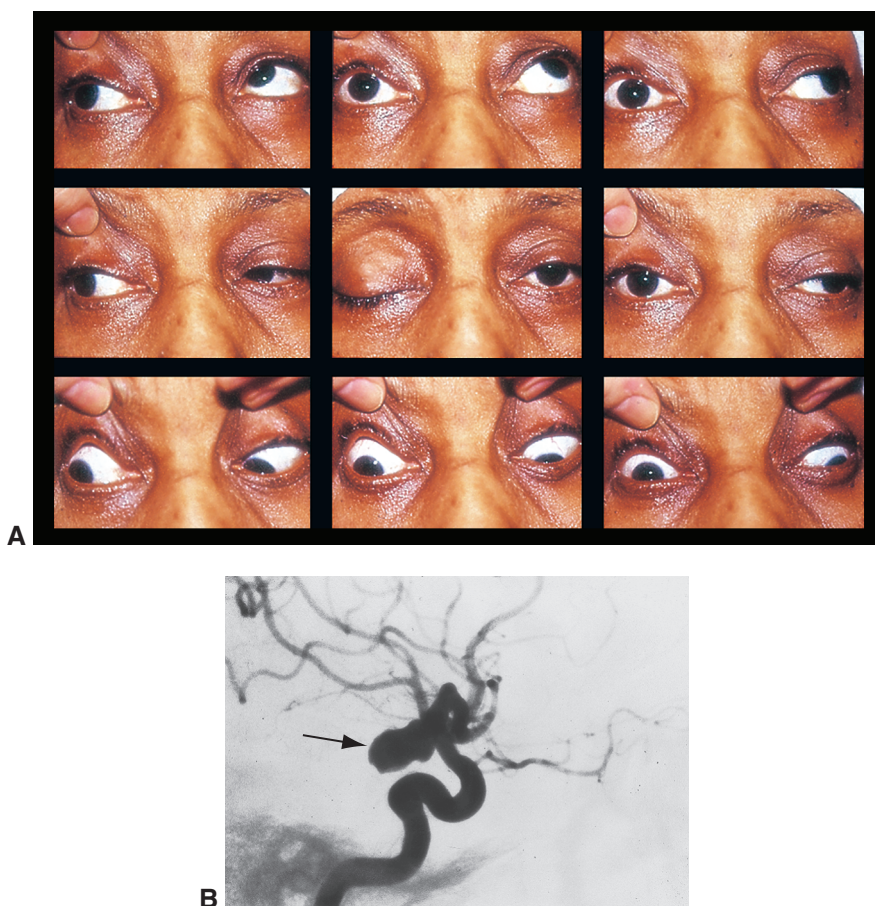
Most isolated unilateral CN III palsies result from (presumed) microvascular injury in the subarachnoid space or cavernous sinus. Less common causes include aneurysmal compression, tumor, inflammation (eg, sarcoidosis), vasculitis, infection (eg, meningitis), infiltration (eg, lymphoma, carcinoma), and trauma.

Fang C, Leavitt JA, Hodge DO, Holmes JM, Mohnney BG, Chen JJ. Incidence and etiologies of acquired third nerve palsy using a population-based method. *JAMA Ophthalmol.* 2017;135(1):23–28.

### Pupil-involving third cranial nerve palsy

Pupillary dysfunction with CN III palsy results from loss of parasympathetic input and produces a mid-dilated pupil that responds poorly to light. Patients may present with various levels of levator palpebrae superioris or EOM dysfunction. Aneurysms that arise at the junction of the PCoA and internal carotid artery (ICA) are juxtaposed to CN III and are, therefore, in a position to produce a CN III palsy as the initial manifestation of aneurysmal expansion or rupture. Pupillary involvement occurs because the pupillomotor fibers reside superficially in the medial aspect of the nerve adjacent to the PCoA (see Chapter 1, Fig 1-39).

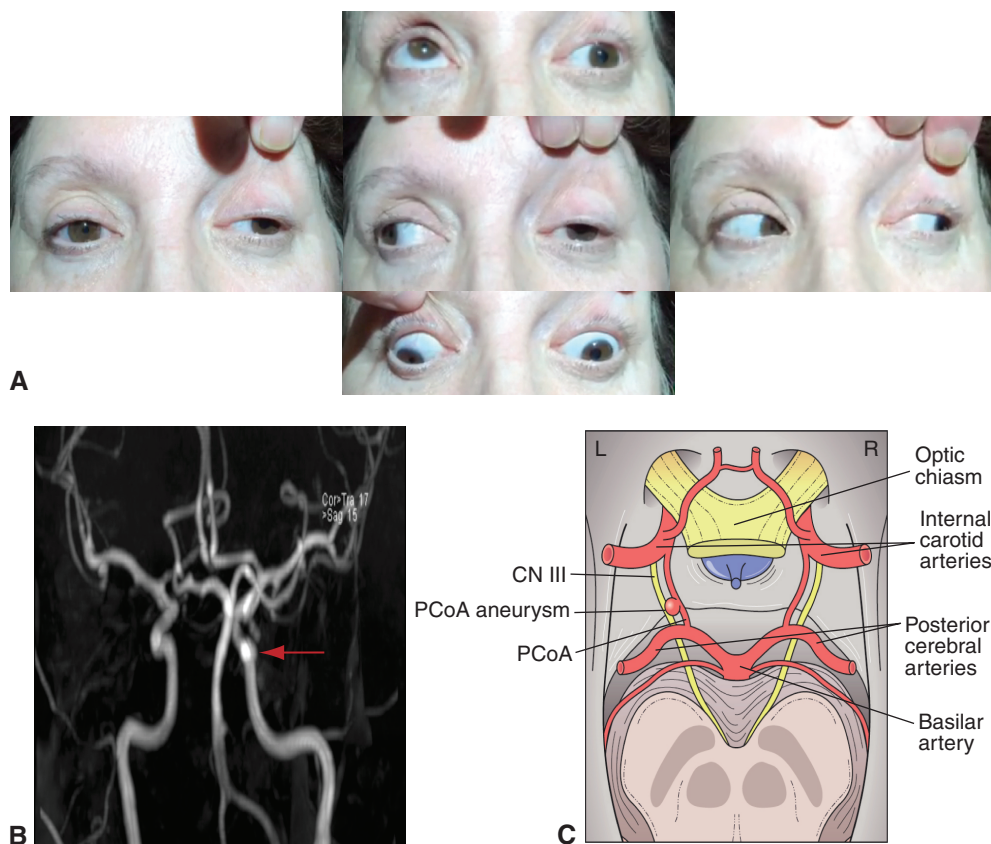
Because there is a 50% risk of mortality associated with aneurysmal rupture, the clinician must assume that a nontraumatic CN III palsy with pupillary involvement or evidence of progression to pupillary involvement is secondary to an aneurysm until proven otherwise and proceed accordingly. Immediate cerebrovascular imaging (eg, computed tomography angiography [CTA], magnetic resonance angiography [MRA], or catheter angiography, depending on the clinical scenario and neuroradiologic consultation) should be undertaken (Fig 8-8). These angiographic methods can detect almost all aneurysms at this location that produce a CN III palsy. Modern CTA and MRA techniques can reliably detect aneurysms as small as 3 mm in diameter. Of these 2 methods, CTA is faster, provides images with slightly greater resolution, and may show evidence of a subarachnoid hemorrhage. MRI acquired with MRA is more likely to show nonaneurysmal lesions. Catheter angiography is



**Figure 8-7** Partial cranial nerve (CN) III palsy. This 62-year-old woman reported experiencing “the worst headache of my life.” **A**, Examination revealed complete ptosis on the right; a non-reactive, dilated pupil; and severely limited extraocular movement except for abduction. **B**, Lateral view of a cerebral angiogram demonstrates a posterior communicating artery aneurysm (arrow). (Part A courtesy of Steven A. Newman, MD; part B courtesy of Leo Hochhauser, MD.)

often used for diagnostic confirmation and definitive treatment of the aneurysm but is occasionally used when there is high clinical suspicion of aneurysm and CTA/MRA are unclear. Although aneurysms are uncommon in patients younger than 20 years, in rare cases they present as early as the first decade of life. Patients with a compressive partial CN III palsy tend to have better recovery of function than patients with a compressive complete CN III palsy after undergoing the same neurosurgical intervention.

A patient who presents only with efferent pupillary dysfunction (ie, the pupil is dilated and responds poorly to light) but exhibits normal eyelid and EOM function almost always has a benign disorder. Such isolated pupillary involvement is not a form of CN III palsy but rather represents a pupil that is either tonic (Adie), pharmacologically dilated, or mechanically damaged (see Chapter 11). Of note, two-thirds of pupil-involving CN III palsies will develop supersensitivity denervation and will constrict with administration of



**Figure 8-8** Pupil-involving cranial nerve (CN) III palsy from a posterior communicating artery (PCoA) aneurysm. **A and B**, The patient had acute-onset pupillary dilation, ptosis, and limitation of supraduction, adduction, and infraduction resulting from a PCoA aneurysm (arrow in **B**). **C**, The close relationship between the PCoA aneurysm and CN III is depicted. A pupil-involving CN III palsy is due to a compressive lesion until proven otherwise. (Reproduced with permission from Chen JJ, Kardon RH. Pupillary signs of neuro-ophthalmic disease. In: Yanoff M, Duker JS. Ophthalmology. 5th ed. Elsevier; 2018:969.)

dilute pilocarpine; therefore, this finding is not specific to an Adie pupil. More important, in the setting of a dilated pupil, the clinician must exclude minor degrees of incomitant strabismus (via careful PACT or Maddox rod testing) in order to exclude a subtle CN III palsy. Tentorial herniation is not a plausible explanation for an isolated, fixed, and dilated pupil in the absence of altered mental status or other neurologic abnormalities.

Pupillary dysfunction, or a progressive loss of function, does not always indicate the presence of an aneurysm or other serious problem. The vasculopathic form of a CN III palsy may produce some efferent pupillary defect in up to 20% of cases, although the pupillary involvement is generally mild (typically  $\leq 1$  mm anisocoria). Elevated blood pressure or levels of fasting blood glucose, hemoglobin A<sub>1c</sub>, or serum lipids indicates an increased probability that microvascular ischemia is the cause of the CN III palsy; however, patients

with these risk factors may also harbor aneurysms. Thus, pupillary involvement should prompt immediate neuroimaging in search of an aneurysm.

### ***Pupil-sparing third cranial nerve palsy***

The term *pupil-sparing partial CN III palsy* refers to cases in which the pupil reacts normally but the impairment of levator palpebrae superioris and/or EOM function is incomplete. Although the pupil is normal, this finding does not have the same benign implication as in pupil-sparing but otherwise complete oculomotor paresis, given that many other fibers within CN III are also “spared.” This distinction is crucial because some partial CN III palsies with normal pupillary function are due to compressive lesions, including aneurysm, and may later progress to involve the pupil. Imaging with MRA or CTA is therefore indicated to exclude an aneurysm. If the MRA or CTA finding is negative and the CN III palsy has progressed on follow-up, MRI of the brain and orbits using a gadolinium contrast agent is needed to search for an anatomical lesion.

The term *pupil-sparing complete CN III palsy* refers to cases in which pupillary function is normal (ie, equal pupil size and reactivity), but there is total loss of eyelid and ocular motor functions of CN III. A pupil-sparing complete CN III palsy is almost always benign and secondary to microvascular disease (diabetes mellitus, hypertension, or hyperlipidemia). An acute, isolated, pupil-sparing (but otherwise complete) CN III palsy in a patient older than 50 years with known vascular risk factors and without history of cancer does not necessarily require neuroimaging. However, because it is often difficult to establish with certainty that a patient with CN III palsy has complete external ophthalmoplegia and because the risk of missing an aneurysm can have devastating consequences, many clinicians obtain CTA and MRA studies for any acute CN III palsy. The presence of head and periorbital pain is not helpful in establishing the cause of the CN III palsy. Although most CN III palsies caused by aneurysms present with pain, many vasculopathic palsies also produce pain that, in some cases, may be intense.

Before assuming that a CN III palsy is microvascular, the clinician should ensure that it is isolated (ie, that there are no other CN palsies), which also involves assessing facial sensation. Intact CN IV function can be confirmed in the setting of a complete CN III palsy by documenting intorsion in attempted downgaze (Video 8-5).



**VIDEO 8-5** Complete CN III palsy with intact CN IV function.

Courtesy of M. Tariq Bhatti, MD. Narrated by John J. Chen, MD, PhD.



In a patient suspected to have a microvascular CN palsy, a general medical evaluation is indicated to assess the patient's serum glucose levels, systemic blood pressure, and serum lipid levels. In older adults, screening for vasculitis (eg, GCA) through testing for Westergren erythrocyte sedimentation rate (ESR), C-reactive protein (CRP) level, and platelet count must also be considered. If progression occurs, other cranial neuropathies develop, or the expected improvement does not ensue within 3 months, neuroimaging should be undertaken to search for a mass or infiltrative lesion at the base of the skull or within the cavernous sinus. Occasionally, neuroimaging studies need to be repeated to discover a mass, especially if it is within the cavernous sinus. Lumbar puncture may be necessary to detect carcinomatous meningitis, inflammation, or infection.



- Gu DQ, Luo B, Zhang X, Long XA, Duan CZ. Recovery of posterior communicating artery aneurysm-induced oculomotor nerve paresis after endovascular treatment. *Clin Neurol Neurosurg.* 2012;114(9):1238–1242.
- Jacobson DM. Relative pupil-sparing third nerve palsy: etiology and clinical variables predictive of a mass. *Neurology.* 2001;56(6):797–798.
- Jacobson DM, Broste SK. Early progression of ophthalmoplegia in patients with ischemic oculomotor nerve palsies. *Arch Ophthalmol.* 1995;113(12):1535–1537.
- O'Connor PS, Tredici TJ, Green RP. Pupil-sparing third nerve palsies caused by aneurysm. *Am J Ophthalmol.* 1983;95(3):395–397.
- Trobe JD. Searching for brain aneurysm in third cranial nerve palsy. *J Neuroophthalmol.* 2009;29(3):171–173.

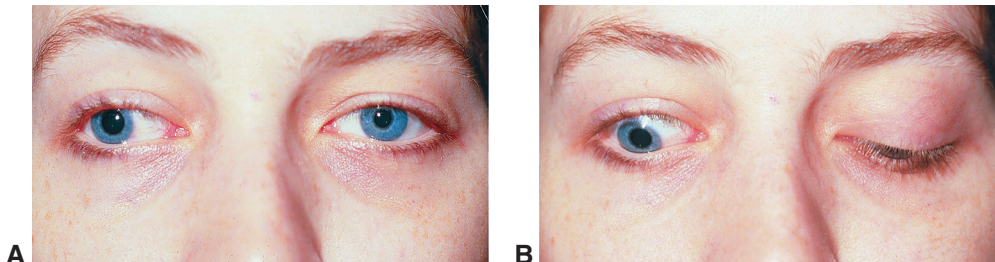
### **Divisional third cranial nerve palsy**

Cranial nerve III branches into superior and inferior divisions within the cavernous sinus and superior orbital fissure. Isolated involvement of either division usually indicates a lesion of the anterior cavernous sinus or posterior orbit. The initial diagnostic study of choice is cranial and orbital MRI with contrast material and fat suppression in addition to MRA. If neuroimaging results are normal, medical evaluation is warranted, including assessment of blood pressure, of blood glucose and serum lipid levels, and of ESR as well as CRP level in the appropriate clinical scenario. In rare cases, a divisional CN III palsy may be secondary to brainstem disease, usually from small-vessel stroke (lacunae) or demyelination, because there is a functional division that occurs proximally within the fascicular portion of CN III. Aneurysms are a much less common but potentially lethal cause of divisional CN III palsy. Rare causes include tumors, inflammatory disorders (eg, sarcoidosis, vasculitis), infection (eg, meningitis), infiltration (eg, carcinomatous meningitis or lymphoma), and trauma.

Bhatti MT, Eisenschenk S, Roper SN, Guy JR. Superior divisional third cranial nerve paresis: clinical and anatomical observations of 2 unique cases. *Arch Neurol.* 2006;63(5):771–776.

### **Aberrant regeneration of the third cranial nerve**

After nerve axons are damaged, the nerve fibers may regrow to innervate muscles other than those they originally innervated (Fig 8-9). This fiber misrouting produces several synkinetic phenomena (ie, co-contraction of muscles that normally are not activated



**Figure 8-9** Aberrant regeneration of right CN III. **A**, In primary gaze, there is mild ptosis, pupillary mydriasis, and exotropia. **B**, With attempted downward gaze, the right upper eyelid retracts as fibers of the right CN III supplying the inferior rectus now also innervate the levator palpebrae superioris muscle. (Courtesy of Rod Foroozan, MD.)

together). Classic findings include eyelid retraction with adduction or pupillary miosis with elevation, adduction, or depression (Video 8-6).



**VIDEO 8-6** Aberrant regeneration of CN III.  
Courtesy of John J. Chen, MD, PhD.



Aberrant regeneration is common after trauma or compression by an aneurysm or tumor but does not occur with microvascular ischemia. Signs of aberrant regeneration without a history of CN III palsy—*primary aberrant regeneration*—are presumptive evidence of a slowly expanding parasellar lesion, most commonly a meningioma or carotid aneurysm within the cavernous sinus, which requires appropriate neuroimaging.

Ling JD, Chao D, Al Zubidi N, Lee AG. Big red flags in neuro-ophthalmology. *Can J Ophthalmol.* 2013;48(1):3–7.

### Fourth Cranial Nerve Palsy

An acute CN IV palsy typically causes diplopia that is worse in contralateral gaze, ipsilateral head tilt, and downgaze; hence, patients almost always report diplopia (or a tendency to close 1 eye) while reading. In some cases, examination of the affected eye reveals limited downgaze in the adducted position, but in most cases ocular motility appears grossly normal. Accordingly, it is essential to perform PACT or Maddox rod testing to demonstrate a hypertropia that worsens on contralateral gaze and ipsilateral head tilt. Ipsilateral head tilting usually increases the vertical strabismus; thus, patients typically (subconsciously) tilt their head to the opposite side to avoid diplopia.

The *Parks-Bielschowsky 3-step test* is an algorithmic approach to identifying ocular motility patterns that conform to dysfunction of a specific vertically acting EOM. The 3 steps are as follows:

1. Find the side of the hypertropia in primary gaze.
2. Determine whether the hypertropia is greater on left or right gaze.
3. Determine whether the hypertropia is greater on left or right head tilt.

Excyclotropia of the affected eye can be assessed by double Maddox rod testing and indirect ophthalmoscopy. The 3-step test is most helpful in determining whether a vertical strabismus conforms to the pattern of a CN IV palsy. For example, a right CN IV palsy shows right hyperdeviation that worsens on left gaze and right head tilt (equaling a positive 3-step test result) and causes excyclotropia of the right eye. (For more on the 3-step test, see BCSC Section 6, *Pediatric Ophthalmology and Strabismus*.)

Occasionally, a skew deviation mimics a CN IV palsy on the 3-step test. However, in a skew deviation, the hypertropic eye will often be intorted as opposed to extorted, as it is in a CN IV paresis. In addition, moving the patient from sitting to a supine position (by reclining the examination chair) often reduces the magnitude of the hypertropia in skew deviation but has little or no effect on a CN IV palsy. Practically speaking, acquired vertical strabismus not from a CN IV palsy is often the result of the dysfunction of more than 1 muscle and will not generate a positive result on a 3-step test. TED, myasthenia


gravis, or simultaneous dysfunction of multiple CNs can produce a variety of nonspecific patterns of ocular misalignment. The reliability of the 3-step test in identifying patterns of vertical strabismus (including CN IV palsy) lessens somewhat over time because of the phenomenon called “spread of comitance” (see the earlier section Comitant and Incomitant Deviations).

*Bilateral CN IV palsy* can be considered whenever a unilateral palsy is diagnosed, especially after head trauma. Patients with bilateral CN IV palsy present with

- crossed hypertropia (ie, the right eye is higher on left gaze, and the left eye is higher on right gaze)
- extorsion of  $\geq 10^\circ$  (best measured with double Maddox rod testing)
- large ( $\geq 25$  prism diopters [ $\Delta$ ]) V-pattern esotropia
- habitual chin down posture

CN IV palsies are often congenital. Recognized causes of congenital CN IV palsies include an anomalous superior oblique tendon, an anomalous site of its insertion, or a defect in the trochlea. Some cases of presumed congenital CN IV palsy are secondary to a benign tumor (eg, schwannoma) of the nerve. Patients may be asymptomatic until adulthood, when their vertical fusional amplitudes diminish and diplopia develops. Most patients maintain a chronic head tilt. The long-standing nature of the head tilt may cause facial asymmetry and can often be confirmed by reviewing old photographs (Fig 8-10). Patients with a long-standing CN IV palsy have relatively large vertical fusional amplitudes ( $>3\Delta$ ). MRI often reveals diminished size of the superior oblique muscle on the affected side. However, comparing superior oblique size on MRI between the affected and unaffected sides does not reliably distinguish long-standing acquired from congenital palsies.

In patients older than 50 years, an isolated CN IV palsy is typically caused by microvascular ischemia. Function usually improves and typically recovers within 6 months. CN IV is particularly vulnerable to closed head trauma because of its unique dorsal midbrain–crossing anatomy. In addition, CN IV can be damaged by disease within the subarachnoid space or cavernous sinus.



**Figure 8-10** Congenital left cranial nerve (CN) IV palsy. **A**, Note the left hypertropia and right head tilt when the patient was a child. **B**, The right head tilt is still present 40 years later, but the patient describes more difficulty maintaining single, binocular vision. **C**, After eye muscle surgery, the diplopia and head tilt have resolved. (Courtesy of Lanning B. Kline, MD.)

Diagnostic evaluation for an isolated, nontraumatic CN IV palsy usually yields little information because most cases have congenital, ischemic, or idiopathic causes. In older patients, who are at increased risk for vasculopathy, a full medical evaluation is appropriate to assess for vascular risk factors (eg, diabetes mellitus, hyperlipidemia, and hypertension). Occasionally GCA can cause a CN IV palsy. Follow-up evaluations in older patients are performed to confirm whether recovery has occurred; a lack of improvement after 3 months necessitates neuroimaging directed toward the skull base to search for a mass lesion. Other possible causes of an acquired vertical strabismus include orbital restrictive syndromes (eg, TED or previous trauma), skew deviation, partial CN III palsy, myasthenia gravis, and Brown syndrome.

Dosunmu EO, Hatt SR, Leske DA, Hodge DO, Holmes JM. Incidence and etiology of presumed fourth cranial nerve palsy: a population-based study. *Am J Ophthalmol.* 2018;185:110–114.

Engel JM. Treatment and diagnosis of congenital fourth nerve palsies: an update. *Curr Opin Ophthalmol.* 2015;26(5):353–356.

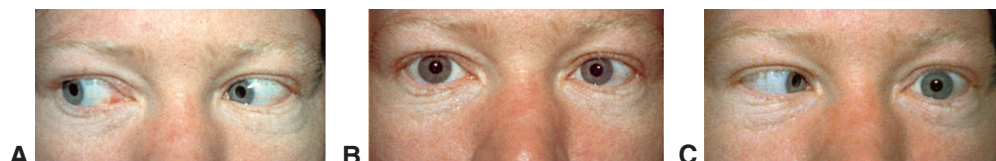Uchiyama E, Matsuo T, Imai S, Itoshima E. Paretic side/normal side ratios of cross-sectional areas of the superior oblique muscle vary largely in idiopathic superior oblique palsy. *Am J Ophthalmol.* 2010;149(3):508–512.

Wong AM, Colpa L, Chandrakumar M. Ability of an upright-supine test to differentiate skew deviation from other vertical strabismus causes. *Arch Ophthalmol.* 2011;129(12):1570–1575.

## Sixth Cranial Nerve Palsy

Cranial nerve VI is the most frequently affected nerve in an isolated ocular motor CN palsy. CN VI palsy presents as horizontal diplopia that worsens on ipsilateral gaze, correlating with an abduction deficit and esodeviation that increases with gaze to the affected side (Fig 8-11). A pattern of divergence insufficiency or paralysis may occur during the evolving or resolving phase of a CN VI palsy (see Chapter 9).

An ischemic mononeuropathy is the most common cause of an isolated CN VI palsy. Lesions of the *cerebellopontine angle* (especially acoustic neuroma or meningioma) may involve CN VI and other contiguous CNs, causing decreased facial and corneal sensation (CN V), facial paralysis (CN VII), and decreased hearing with vestibular signs (CN VIII). Chronic inflammation of the petrous bone may cause an ipsilateral abducens palsy and



**Figure 8-11** Left cranial nerve (CN) VI palsy. **A**, In right gaze, the eyes are aligned. **B**, In straight-ahead gaze, the left eye is inwardly deviated. **C**, In left gaze, the left eye does not abduct, causing a marked misalignment of the eyes. (From Trobe JD. *The Physician's Guide to Eye Care*. 3rd ed. American Academy of Ophthalmology; 2006:118. Image courtesy of Kellogg Eye Center, University of Michigan.)

facial pain (*Gradenigo syndrome*), especially in children with recurrent middle ear infections. After exiting the prepontine space, CN VI is vulnerable to meningeal or skull-based processes, such as meningioma, nasopharyngeal carcinoma, chordoma, or chondrosarcoma. Clivus lesions can cause unilateral or bilateral CN VI palsies. In addition, CN VI is susceptible to injury from shearing forces of head trauma or elevated intracranial pressure. In such cases, injury occurs where CN VI enters the cavernous sinus through the *Dorello canal* (the opening inferior to the petroclinoid ligament). The appearance of a CN VI palsy after seemingly minor head trauma raises concern for a preexisting pathology, such as tumor compression, that makes the nerve more susceptible to injury.

Isolated CN VI palsies in adults older than 50 years are usually ischemic. Ocular motility in such cases usually improves over time and typically resolves within 6 months. Whether or not neuroimaging is required at the time of initial diagnosis is controversial. Some experts recommend neuroimaging at initial presentation. As with other isolated ocular motor CN palsies, medical evaluation is appropriate. However, a cranial MRI is mandatory if obvious improvement has not occurred after 3 months or if additional CN deficits occur. Other diagnostic studies that may be necessary include lumbar puncture, chest imaging, and hematologic studies to identify an underlying systemic process such as syphilis, sarcoidosis, collagen vascular disease, or GCA. Recovery does not necessarily indicate a benign cause. Occasionally, a CN VI palsy will resolve spontaneously and then recur as a manifestation of an intracranial tumor or ocular myasthenia gravis.

Impaired abduction in patients younger than 50 years necessitates close evaluation because few such cases are caused by ischemic cranial neuropathy. Younger patients should undergo cranial and orbital MRI with gadolinium. A CN VI palsy may be the only presenting ocular sign of a posteriorly draining carotid-cavernous fistula (eg, white eye shunt syndrome; see the later section “Carotid-cavernous sinus fistula”). If imaging results are negative, further consideration includes evaluations for

- neuromuscular junction disease, by obtaining acetylcholine receptor antibody titers or performing edrophonium testing
- mechanical pathophysiologies, such as TED with medial rectus muscle involvement
- meningeal-based disease, by obtaining a lumbar puncture

Leukemia and brainstem glioma are important considerations in children. In adolescents and young adults, demyelination may be the cause, in which case MRI with fluid-attenuated inversion recovery (FLAIR) imaging typically reveals T2 hyperintensities consistent with multiple sclerosis. (See Chapter 2 for a discussion of neuroimaging and Chapter 15 for a discussion of multiple sclerosis.) Other potential mimics of CN VI palsy include type 1 Duane syndrome (see BCSC Section 6, *Pediatric Ophthalmology and Strabismus*), spasm of the near reflex, myasthenia gravis, TED, and medial orbital wall fracture with entrapment.

Tamhankar MA, Biousse V, Ying GS, et al. Isolated third, fourth, and sixth cranial nerve palsies from presumed microvascular versus other causes: a prospective study. *Ophthalmology*. 2013;120(11):2264–2269.



## Recurrent Painful Ophthalmoplegic Neuropathy

In 2018, the third edition of the *International Classification of Headache Disorders (ICHD-3)* introduced *recurrent painful ophthalmoplegic neuropathy (RPON)* as the new classification for recurrent headaches with subsequent unilateral ophthalmoplegia, replacing the previous term *ophthalmoplegic migraine*. RPON usually involves CN III but in rare instances can also affect CNs IV or VI. RPON is more common in childhood and early adulthood. Head pain usually precedes the ocular motor paresis and can develop up to 14 days before the onset of diplopia. Episodes of RPON typically resolve spontaneously over days to a few months. Recurrent episodes can sometimes lead to permanent, residual deficits. Treatment with corticosteroids may be helpful in some patients. MRI may demonstrate reversible thickening and enhancement at the root exit zone of the CNs. CN schwannoma may mimic the fluctuating nature of this condition; however, CN enhancement will persist after resolution of the CN palsy. As noted, vascular imaging to rule out an aneurysm is necessary in a CN III palsy.

Ambrosetto P, Nicolini F, Zoli M, Cirillo L, Feraco P, Bacci A. Ophthalmoplegic migraine: from questions to answers. *Cephalalgia*. 2014;34(11):914–919.

Förderreuther S, Ruscheweyh R. From ophthalmoplegic migraine to cranial neuropathy. *Curr Pain Headache Rep*. 2015;19(6):21.

## Paresis of More Than One Cranial Nerve

The framework for managing isolated ocular motor CN palsies presented earlier in this chapter assumes that no other neurologic abnormalities are present. Benign microvascular ischemic disease rarely causes simultaneous involvement of more than 1 ocular motor CN. Simultaneous involvement of unilateral CNs III, IV, V, and VI, and sympathetic nerves strongly suggests a lesion of the cavernous sinus (see the following section). Bilateral involvement of the CNs suggests a diffuse process such as infiltrative disease (eg, carcinoma, leukemia, or lymphoma), a midline mass lesion that extends bilaterally (eg, chordoma, chondrosarcoma, or nasopharyngeal carcinoma), a meningeal-based process, an inflammatory polyneuropathy (eg, Guillain-Barré syndrome or its variant, the Miller Fisher syndrome, or sarcoidosis), or myasthenia gravis.

If symptoms or signs indicate that more than 1 CN is involved, a neurologic evaluation should be undertaken. If neuroimaging appears normal, a lumbar puncture with cytopathologic examination may be necessary. Testing for cancer-associated protein markers may be helpful in uncovering an elusive diagnosis. In suspected neoplastic meningeal involvement (ie, meningeal carcinomatosis), combined CT–positron emission tomography (CT–PET) scans are often the studies of choice to demonstrate accessible biopsy sites. Repeated studies may be needed to obtain a definitive diagnosis. *Idiopathic multiple cranial neuropathy syndrome* should be considered only after neuroimaging, cerebrospinal fluid analysis, other tests, and extended observation have excluded neoplastic, inflammatory, or infectious causes.

## Cavernous Sinus and Orbital Apex Involvement

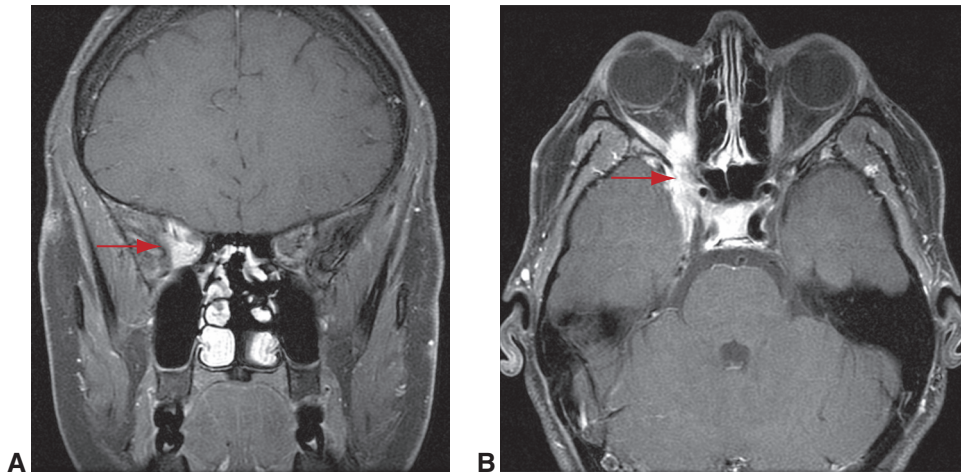
Ipsilateral CN dysfunction involving a combination of CNs III, IV, V, and VI, and sympathetic fibers is the hallmark of ophthalmoplegia that is secondary to a cavernous sinus

lesion (see illustrations in Chapter 1). The presence of CN V involvement with facial hypoesthesia, a third-order (postganglionic) Horner syndrome, or both is helpful for localizing the lesion to the cavernous sinus. If only 1 CN is involved, it is usually CN VI, which is the only CN not protected within the lateral dural wall of the cavernous sinus. Aggressive lesions of the cavernous sinus, especially infectious or inflammatory processes, may compromise venous outflow and produce engorgement of ocular surface vessels, orbital venous congestion, increased intraocular pressure, and increased ocular pulse pressure.

It is often very difficult to distinguish cavernous sinus lesions clinically from lesions involving the superior orbital fissure. The CNs pass through this fissure from the cavernous sinus into the orbit, and lesions often cross this anatomical boundary. In recognition of this difficulty, the more general designation of *sphenocavernous syndrome* or *parasellar syndrome* may be used. The offending lesion may extend toward the optic canal or into the orbital apex, in which case optic nerve function can be compromised. The designation *orbital apex syndrome* is then applied (Fig 8-12).

### **Tolosa-Hunt syndrome**

Tolosa-Hunt syndrome is an idiopathic, sterile inflammation that primarily affects the cavernous sinus. Severe, “boring” pain is almost always present. Neuroimaging may show an enhancing mass within the cavernous sinus. The pain typically responds rapidly and dramatically to corticosteroid therapy, but a positive therapeutic response may also occur with neoplastic mass lesions, especially lymphoma. Frequently, the cause of a painful ophthalmoplegia in patients initially diagnosed with Tolosa-Hunt syndrome is later



**Figure 8-12** Orbital apex syndrome due to immunoglobulin G4-related disease (IgG4-RD). The patient has right, partial, pupil-involving cranial nerve (CN) III and VI palsies, a right optic neuropathy with a central scotoma, and visual acuity of 20/200. Involvement of the optic nerve and multiple CNs localizes the lesion to the orbital apex. Coronal (**A**) and axial (**B**) T1-weighted, fat-suppressed MRI of the orbits with contrast demonstrates an enhancing lesion involving the right orbital apex (arrows) and cavernous sinus. (Courtesy of John J. Chen, MD, PhD.)

discovered to be neoplastic. Therefore, Tolosa-Hunt syndrome is a diagnosis of exclusion. Other causes of cavernous sinus lesions include aneurysm, fungal infection, meningioma, lymphoma, immunoglobulin G4 (IgG4)-related ophthalmic disease, schwannoma, pituitary adenoma (with or without apoplexy), carotid-cavernous fistula, metastasis, sarcoidosis, and cavernous sinus thrombosis.

Hao R, He Y, Zhang H, Zhang W, Li X, Ke Y. The evaluation of ICHD-3 beta diagnostic criteria for Tolosa-Hunt syndrome: a study of 22 cases of Tolosa-Hunt syndrome. *Neurol Sci.* 2015;36(6):899–905.

Hung CH, Chang KH, Chen YL, et al. Clinical and radiological findings suggesting disorders other than Tolosa-Hunt syndrome among ophthalmoplegic patients: a retrospective analysis. *Headache.* 2015;55(2):252–264.

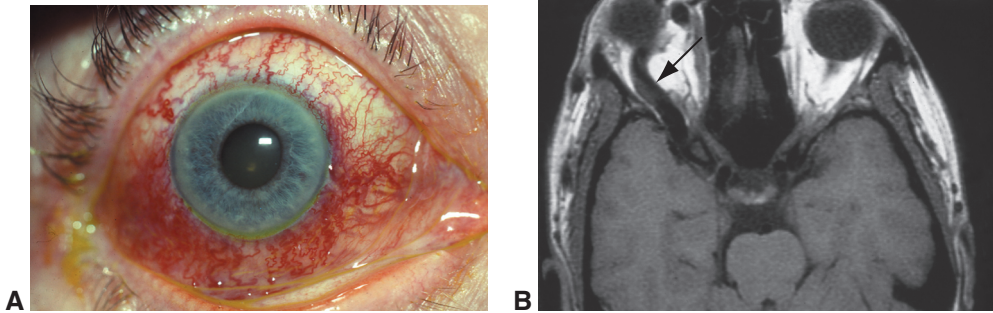
### **Carotid-cavernous sinus fistula**

Abnormal connections between the cavernous sinus and the carotid artery or its branches introduce high arterial pressure into the normally low-pressure venous circulation of the cavernous sinus. Such a high-pressure connection may reverse blood flow within the superior ophthalmic vein and produce venous congestion within the orbit. Arterialization of conjunctival vessels is a classic sign of this fistula (Fig 8-13). Patients with this condition may have either direct, high-flow connections between the internal carotid artery and the cavernous sinus or indirect, “dural,” low-flow connections mediated by small arterial feeders off the internal or external carotids (Fig 8-14). High-flow, direct fistulas most commonly occur after severe head trauma and produce a cranial bruit, whereas low-flow, indirect fistulas most often occur spontaneously, particularly in older women. The sequence of events leading to indirect fistula formation is not known. Physical examination cannot reliably distinguish between high-flow and low-flow fistulas, aside from a cranial bruit that indicates high flow. Imaging may show an enlargement of the superior ophthalmic vein. MRA, CTA, or cerebral angiography is often necessary to make the correct diagnosis.

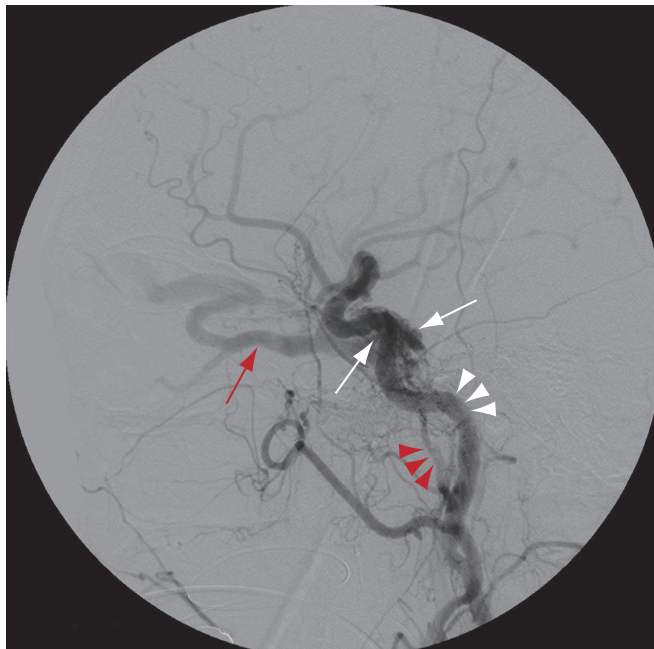
Direct and indirect carotid-cavernous sinus fistulas often produce elevated intraocular pressure and proptosis but may also cause the following signs or symptoms:

- diplopia resulting from either CN palsy or orbital congestion
- arterial or venous compromise to the retina and eye
- ischemic optic neuropathy
- choroidal effusions
- ocular pain (which may partly result from ocular surface drying if proptosis is significant) or ipsilateral headache
- cerebral venous infarction (rare) resulting from venous hypertension

Diplopia can occur from congestion of the EOMs or involvement of any of the CNs in the cavernous sinus, most commonly CN VI. In rare cases, a posteriorly draining fistula can cause an isolated CN palsy with a quiet-appearing eye. Pulsatile tinnitus is often present. Some indirect fistulas remain stable or close spontaneously; however, both types of fistulas may be successfully treated with interventional radiologic techniques or radiosurgery. Angiographic studies are required in order to determine the location and configuration of the



**Figure 8-13** Right carotid-cavernous sinus fistula. **A**, The elevated orbital venous pressure produces enlarged, corkscrew, arterialized episcleral and conjunctival blood vessels that extend to the limbus. **B**, Axial T1-weighted magnetic resonance imaging reveals an enlarged, dilated superior ophthalmic vein (arrow). (Courtesy of Karl C. Golnik, MD.)



**Figure 8-14** Carotid-cavernous sinus fistula. Lateral cerebral angiogram with right common carotid artery injection. Note the cavernous sinus (ill-defined area, white arrows) filling from both the external carotid artery branches (red arrowheads) and internal carotid artery branches (white arrowheads). The superior ophthalmic vein (red arrow) is markedly enlarged and fills inappropriately during the early arterial phase of this study. (Courtesy of Prem S. Subramanian, MD, PhD.)

fistula, and a variety of thrombogenic materials (eg, coils, beads, or balloons) may be used to eliminate the abnormal vascular flow.

Williams ZR. Carotid-cavernous fistulae: a review of clinical presentation, therapeutic options, and visual prognosis. *Int Ophthalmol Clin*. 2018;58(2):271–294.

## Myopathic, Restrictive, Orbital, Neuromuscular, and Other Causes of Diplopia

---

Eye movements may be impaired or restricted by congenital or acquired mechanical factors. Congenitally deficient neural innervation to EOMs can cause limited eye movements with a restrictive component. Neuromuscular junction deficits can cause variable diplopia.

### Thyroid Eye Disease

The most common cause of restrictive strabismus in adults is TED. Any of the EOMs may be involved, but the most commonly affected muscles are the inferior and medial recti. When the inferior rectus muscle is involved, an ipsilateral hypotropia typically occurs in primary position that increases in upgaze—the restrictive process pulls the eye down and limits supraduction. When the medial rectus is the affected muscle, an esodeviation typically occurs that increases on lateral gaze to the same side (the enlarged, “tight” medial rectus restricts abduction). The diagnosis of TED is straightforward if associated with proptosis, chemosis, eyelid retraction, and eyelid lag; however, restrictive strabismus may be the only sign. Forced duction testing (see Fig 8-3) may provide information to support this diagnosis. Neuroimaging in patients with TED typically reveals enlargement of the EOM bellies with sparing of the tendons (see BCSC Section 7, *Oculofacial Plastic and Orbital Surgery*, Chapter 4).

### Orbital Myositis

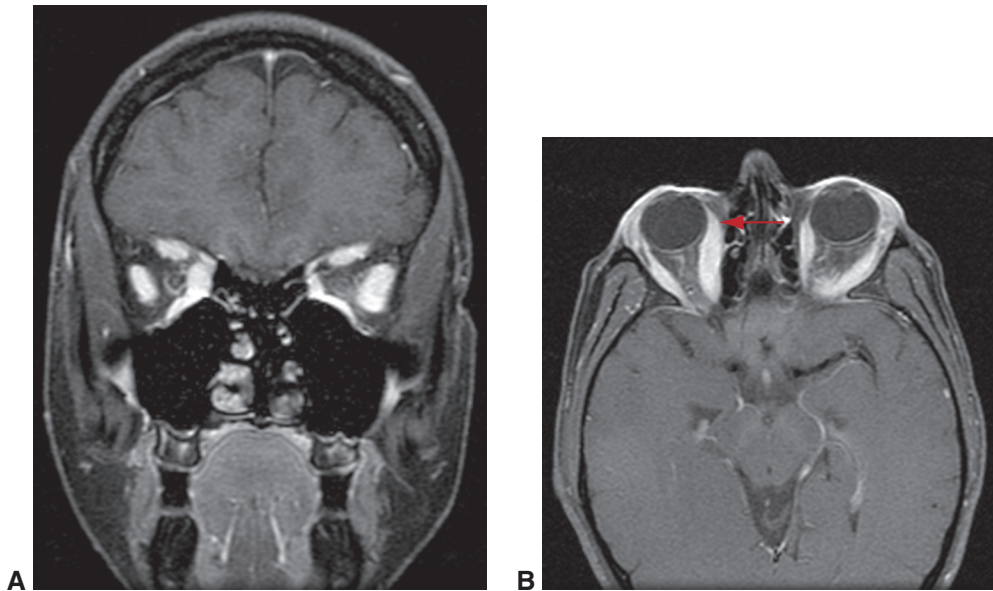
Idiopathic inflammation of 1 or more EOMs typically produces ophthalmoplegia and pain, often with conjunctival hyperemia and chemosis, and sometimes with proptosis. The pain may be quite intense and is exacerbated by eye movements. If the inflammation is confined to the posterior orbit, the eye may appear white and quiet. CT or MRI typically shows enlargement of 1 or more of the EOMs with tendon involvement, and the inflammation often extends into the orbital fat (Fig 8-15). Orbital myositis–related pain usually responds to systemic corticosteroid therapy within 24 hours, whereas diplopia may take longer to resolve. Orbital myositis is usually an isolated phenomenon within the spectrum of nonspecific orbital inflammation (NSOI) but also may be part of a systemic disease such as granulomatosis with polyangiitis (formerly, Wegener granulomatosis), systemic lupus erythematosus, sarcoidosis, IgG4-related ophthalmic disease, lymphoma, or, in rare cases, metastatic disease, or as an adverse effect of medication (such as bisphosphonate). EOM biopsy can be considered in cases of recurrent orbital myositis with corticosteroid taper. See also BCSC Section 7, *Oculofacial Plastic and Orbital Surgery*.

Yamamoto M, Hashimoto M, Takahashi H, Shinomura Y. IgG4 disease. *J Neuroophthalmol*. 2014;34(4):393–399.

### Posttraumatic Restriction

Blowout fractures of the orbit often cause diplopia. The most typical presentation involves fracture of the orbital floor with entrapment of the inferior rectus muscle or its fascial





**Figure 8-15** Orbital myositis. **A**, Coronal, T1-weighted, fat-suppressed magnetic resonance image with contrast shows enlargement and enhancement of the lateral, medial, and superior recti muscles of both eyes. **B**, Axial view shows involvement of the tendons (arrow). (Courtesy of James A. Garrity, MD.)

attachments. This entrapment, best illustrated with coronal CT of the orbit, mimics the pattern of vertical strabismus often present in TED. Less commonly, the medial rectus muscle becomes entrapped (see Chapter 2, Fig 2-11). Paretic strabismus from swelling also may occur in the acute phase. In this case, as the swelling resolves, so may the diplopia. Hence, decisions about the need for surgery for orbital blowout fractures must be made judiciously. See also BCSC Section 7, *Oculofacial Plastic and Orbital Surgery*.

### Postsurgical Restriction

Binocular diplopia can result from injury to or inflammation within the inferior rectus or other muscles after retrobulbar or peribulbar injection for cataract or other ocular surgery. The onset of vertical diplopia immediately following surgery initially suggests nerve damage or myotoxicity from the local anesthetic. Over time, the initial parietic or myotoxic effect can evolve into EOM fibrosis, leading to an overaction or a restricted eye movement pattern. For example, if the inferior rectus muscle is affected, the involved eye may transition from hypertropic (paretic) to hypotropic (restricted) status. In addition, restrictive diplopia may be caused by pterygium excision, scleral buckle placement, episcleral plaque brachytherapy, or tube shunt procedures.

Abdelaziz A, Capó H, Banitt MR, et al. Diplopia after glaucoma drainage device implantation. *J AAPOS*. 2013;17(2):192–196.

Gunton KB, Armstrong B. Diplopia in adult patients following cataract extraction and refractive surgery. *Curr Opin Ophthalmol*. 2010;21(5):341–344.

Sener EC, Kiratli H, Gedik S, Sanac AS. Ocular motility disturbances after episcleral plaque brachytherapy for uveal melanoma. *J AAPOS*. 2004;8(1):38–45.

## Chronic Progressive External Ophthalmoplegia

See Chapter 15 for a discussion of this condition.

## Neoplastic Involvement

If cancer infiltrates the orbit, especially cancer from the surrounding paranasal sinuses, eye movements may be impaired, because of either EOM infiltration or involvement of the ocular motor CNs. Ptosis, relative enophthalmos, or associated eyelid “hang-up” on downgaze may accompany the diplopia. Occasionally, EOMs may be metastatic tumor sites.

## Brown Syndrome

Brown syndrome is a restrictive ocular motor disorder that produces limited upgaze when the affected eye is in the adducted position. It is usually congenital but can be acquired. Acquired Brown syndrome typically occurs in patients with rheumatoid arthritis, NSOI, or trauma, including iatrogenic trauma. In rare cases, it may be a manifestation of a focal neoplastic metastasis to the superior oblique muscle (see BCSC Section 6, *Pediatric Ophthalmology and Strabismus*).

## Heavy Eye Syndrome

“Heavy eye syndrome,” also called *strabismus fixus*, may result in progressive esotropia and hypotropia in patients with high myopia. The esotropia and hypotropia are associated with limited abduction and supraduction of the eye resulting from the superotemporal shift of the staphylomatous globe posteriorly, with medial displacement of the superior rectus muscle and inferior displacement of the lateral rectus muscle. The intervening connective tissue band also degenerates. Neuroimaging is done to exclude other causes and often confirms the muscle slippage.

## Sagging Eye Syndrome

Sagging eye syndrome can occur in older patients without the prerequisite of myopia. It presents with a mild- to moderate-angle esotropia greater at distance than at near fixation (ie, divergence insufficiency), full lateral gaze, and minimal hypotropia with limited supraduction. The lateral rectus–superior rectus band degenerates, with inferior displacement of the lateral rectus muscle, in conjunction with the prolapse of connective tissue superotemporally, but there is no globe prolapse. In addition, patients often experience degenerative changes that can cause deep superior sulci, high eyelid creases, and ptosis resulting from levator aponeurosis dehiscence. Sagging eye syndrome is the mechanism underlying divergence insufficiency in older adults.

Tan RJ, Demer JL. Heavy eye syndrome versus sagging eye syndrome in high myopia. *J AAPOS*. 2015;19(6):500–506.

## Ocular Neuromyotonia

Ocular neuromyotonia, a rare but important cause of episodic diplopia, is thought to be neurogenic in origin. Prior skull-based radiation therapy, typically for neoplasm (eg, meningioma), is the most common historical feature. Months to years postradiation, patients experience episodic diplopia lasting typically 30–60 seconds (Video 8-7). Ocular neuromyotonia may affect any of the ocular motor nerves or their divisions. Diplopia is often triggered by activation of the affected nerve in eccentric gaze with resultant sustained muscle contraction producing ocular misalignment (eg, CN VI neuromyotonia produces sustained lateral rectus muscle spasm of the involved eye and attendant exotropia). If the cause is unrecognized, patients often undergo extensive and largely unnecessary workup in the search for a recurrent neoplasm. The disorder generally responds well to medical therapy. Carbamazepine and its derivatives constitute first-line treatment.



### VIDEO 8-7 Ocular neuromyotonia.

Courtesy of M. Tariq Bhatti, MD. Narrated by John J. Chen, MD, PhD.



Roper-Hall G, Chung SM, Cruz OA. Ocular neuromyotonia: differential diagnosis and treatment. *Strabismus*. 2013;21(2):131–136.

## Neuromuscular Junction Causes of Diplopia

The prototypical disease of the neuromuscular junction is myasthenia gravis. It typically produces variable diplopia and ptosis with any pattern of pupil-sparing, painless ocular misalignment. Conversely, it never produces sensory symptoms, pain, or pupillary dysfunction. Accordingly, myasthenia gravis belongs in the differential diagnosis of any such case of diplopia (see Chapter 15).

## Refractive Procedure–Induced Diplopia

In patients with childhood strabismus, diplopia may be induced by refractive procedures that cause a change in fixation preference to the nondominant eye (eg, monovision correction, cataract surgery on an amblyopic eye before the dominant eye, or noncycloplegic refraction leading to undercorrected hyperopia in the preferred eye with a shift of fixation to the amblyopic eye). “Fixation switch diplopia” resolves with appropriate optical correction to reestablish fixation with the dominant eye. Anisometropia or aniseikonia can also cause diplopia or contribute to the unmasking of a preexisting strabismus.

Pineles SL. Fixation switch diplopia. *J Neuroophthalmol*. 2016;36(2):118–119.

## Foveal Displacement Syndrome

Foveal displacement syndrome, also called central-peripheral rivalry–type diplopia, results from macular disease, most commonly epiretinal membrane, that distorts or displaces the fovea. Affected patients experience diplopia because the central and peripheral retina cannot be simultaneously fused owing to the retinal misregistration. Prisms may transiently resolve the diplopia for seconds to minutes. However, the stronger peripheral-fusion drive

subsequently overcomes the central fusion, which leads to small degrees of variable central binocular diplopia that usually cannot be permanently corrected with use of a prism or strabismus surgery. Epiretinal membrane peeling can be helpful in some patients, but the success of this treatment is unpredictable.

- De Pool ME, Campbell JP, Broome SO, Guyton DL. The dragged-fovea diplopia syndrome: clinical characteristics, diagnosis, and treatment. *Ophthalmology*. 2005;112(8):1455–1462.
- Hatt SR, Leske DA, Klaehn LD, Kramer AM, Iezzi R Jr, Holmes JM. Treatment for central-peripheral rivalry-type diplopia (“dragged-fovea diplopia syndrome”). *Am J Ophthalmol*. 2019;208:41–46.

# The Patient With Supranuclear Disorders of Ocular Motility



This chapter includes related videos. Go to [www.aao.org/bcscvideo\\_section05](http://www.aao.org/bcscvideo_section05) or scan the QR codes in the text to access this content.

### Highlights

---

- The supranuclear pathways are more accurately called *prenuclear* because some of these pathways (eg, the vestibular pathways) originate inferior to the cranial nerve (CN) nuclei. However, the term *supranuclear* is used throughout the literature and is used in this book as well.
- Six major supranuclear ocular motor systems—ocular fixation, vestibular-ocular, optokinetic, saccadic, smooth-pursuit, and vergence systems—have evolved to detect motion and direct or maintain foveal alignment with objects of interest.
- The supranuclear ocular motor systems are neural networks that encompass multiple regions of the central nervous system, including premotor and motor regions of the frontal and parietal cortices, the cerebellum, the superior colliculi, the thalamus, the basal ganglia, and the brainstem.
- The 6 supranuclear system pathways converge at the level of the brainstem to innervate the ocular motor CN nuclei.

### Fundamental Principles of Ocular Motor Control

---

In primates, the afferent visual system is broadly designed to achieve 2 fundamental goals: (1) to detect objects and motion in the environment; and (2) to provide a high level of spatial resolution for objects that command attention. The entire retina outside the fovea is essentially devoted to the detection of objects. Only the fovea, which occupies a tiny fraction of the total retinal area, provides the fine-quality resolution that allows us to read or to perform highly precise visual motor tasks. Therefore, if one is to discern the fine details of an object, the image of that object must be precisely located on the fovea.

The ocular motor system consists of supranuclear and infranuclear pathways that direct and hold foveal alignment with objects of interest. The supranuclear pathways are more accurately termed *prenuclear* as some of them (eg, the vestibular pathways) originate



**Table 9-1 Supranuclear Ocular Motor Systems**

Type	Speed of Eye Movement	Main Function
Ocular fixation system	Fast	Holds image of stationary object steady on fovea when head is immobile by correcting for ocular drift; “refreshes” image on retina to avoid photoreceptor fatigue
Vestibular-ocular system	Slow	Holds retinal image steady during brief head rotation or translation
Optokinetic system	Slow	Holds retinal image steady during sustained head movements
Saccadic system	Fast	Rapidly brings image of object of interest onto the fovea
Smooth-pursuit system	Slow	Holds image of a moving object steady on fovea
Vergence system	Slow	Moves eyes in opposite directions so an image of an object of interest is simultaneously held on each fovea

inferior to the cranial nerve (CN) nuclei. However, the term *supranuclear* is used throughout the literature and is used in this book as well.

Six major supranuclear ocular motor systems have evolved to direct and hold foveal alignment with objects of interest (Table 9-1):

- *Ocular fixation system.* Holds the image of a stationary object on the fovea when the head is not moving
- *Vestibular-ocular system.* Holds the image steady on the fovea during brief head movements
- *Optokinetic system.* Holds the image on the fovea during sustained head movements
- *Saccadic system.* Rapidly brings the image of an object of interest onto the fovea
- *Smooth-pursuit system.* Holds the image of a moving object on the fovea
- *Vergence system.* Moves the eyes in opposite directions so that an image of an object of interest is simultaneously held on each fovea

The supranuclear ocular motor systems are neural networks that encompass multiple regions of the central nervous system (CNS), including premotor and motor regions of the frontal and parietal cortices, the cerebellum, the superior colliculi, the thalamus, the basal ganglia, and the brainstem. These supranuclear systems include different anatomical pathways that converge at the level of the brainstem to innervate the ocular motor CN nuclei. Their separate origins allow selective disruption of these ocular motor systems by disease processes. Therefore, a targeted clinical examination of these systems allows the clinician to identify the affected system and determine the responsible disease process.

Leigh RJ, Zee DS. *The Neurology of Eye Movements*. 5th ed. Contemporary Neurology Series. Oxford University Press; 2015.

Wong AMF. *Eye Movement Disorders*. Oxford University Press; 2008.

## Supranuclear Ocular Motor Systems: Function, Anatomy, Clinical Testing, and Disorders of Eye Movements

---

Clinical examination of the supranuclear systems includes assessment of ocular fixation, vestibular-ocular reflex (VOR), optokinetic nystagmus, saccadic and pursuit eye movements, and convergence (see Table 9-1). Each of these movements is controlled by dedicated anatomical pathways, the collective goals of which are to direct the image of a target of interest onto the fovea and maintain this image on the fovea. Methods of assessing each subsystem and signs of malfunction are described in the following sections. A thorough assessment of ocular motility also requires a search for nystagmus. For additional discussion of many of the topics covered in this chapter, see Chapter 10.

### Ocular Fixation System

The ocular fixation system holds the image of a stationary object on the fovea when the head is immobile. Eye movement recordings show that the eye is not completely still during ocular fixation; subclinical eye movements prevent attenuation of neuronal responses in the retina. A basic principle of all sensory systems is that any persistent, unchanging stimulus gradually produces an attenuated neural response. This phenomenon explains, for instance, why one does not attend to the constant tactile stimulus of wearing clothing or a wristwatch.

The degradation of image quality that would result if the eye were completely still is countered by *microsaccadic refixation movements*, which are very small-amplitude ( $0.1^{\circ}$ – $0.2^{\circ}$  of visual angle) to-and-fro saccades. As is true for most saccadic movements, there is a slight pause (180–200 milliseconds) between movements, known as an *intersaccadic interval*. These eye movements, which are of equal amplitude and speed to the left and right with a brief intersaccadic interval, produce tracings in the shape of square waves; hence the term *square waves*. The normal microsaccadic refixation to-and-fro movements are small enough that the image is maintained within the field of the fovea but large enough to provide a changing image to photoreceptors, thereby preventing attenuation of the neural response and enhancing perceptual quality. *Slow drift eye movements* also occur during fixation and counter the image degradation that would occur if the eyes were completely still. Microsaccadic and slow drift eye movements are too small to be observed on clinical examination.

The anatomical pathways that control ocular fixation include the dorsolateral prefrontal cortex, the supplementary eye field, the parietal eye field, regions V5 and V5a, the basal ganglia, and the superior colliculi. Clinical evaluation of ocular stability involves observing the patient's ability to fixate on a target when the head and body are held stationary.

### Ocular fixation dysfunction

Malfunction of other supranuclear ocular motor systems may disrupt steady fixation. Saccadic, rapid eye movements that disrupt fixation are referred to as *saccadic intrusions*. The most common intrusions are *square-wave jerks* (SWJs), which lead the eyes off and then back onto the target with symmetric movements (amplitude of  $0.5^{\circ}$ – $3.0^{\circ}$  of visual angle).

These SWJs may be observed on clinical examination, as they have a much greater amplitude than the normal microsaccadic refixation movements described previously. Infrequent SWJs (4–6 per minute) may be observed in older patients with normal fixation. Frequent SWJs (>15 per minute) are pathologic and occur in patients with *progressive supranuclear palsy (PSP)*, *Parkinson disease*, and certain cerebellar diseases. They may also be seen in patients who smoke cigarettes. Other examples of saccadic intrusions include macrosquare-wave jerks, macrosaccadic oscillations, ocular flutter, and opsoclonus (see Chapter 10).

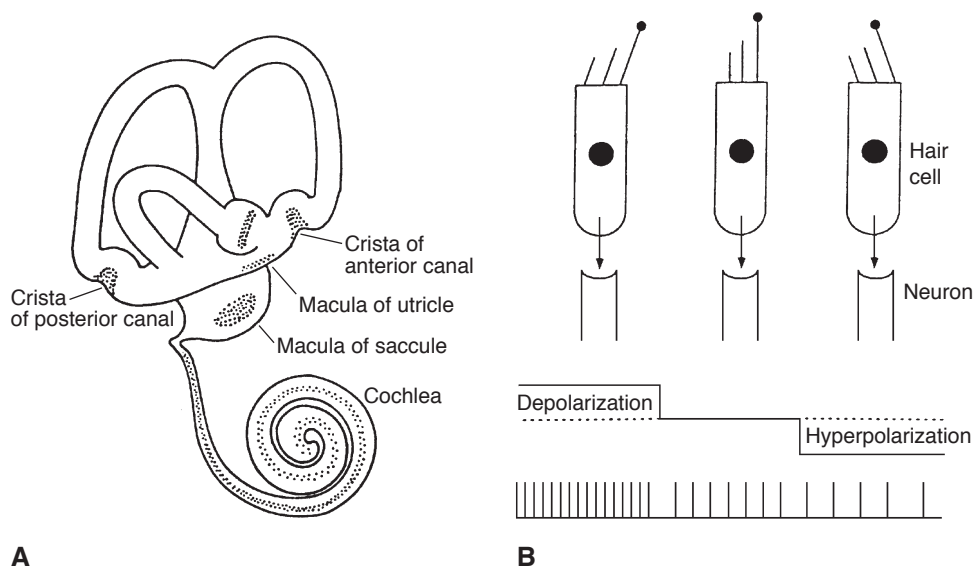
Sustained slow eye movements that disrupt fixation characterize nystagmus, which may be caused by supranuclear dysfunction such as an imbalance of vestibular input to the ocular motor nuclei. A continuous slow eye movement that displaces the eye off fixation, followed by a corrective saccade, is referred to as a *jerk nystagmus*. A continuous slow, oscillating eye movement without a corrective saccade is referred to as a *pendular nystagmus*.

### **Vestibular-Ocular System (Vestibular-Ocular Reflex)**

The VOR holds foveal alignment on a target of interest during brief, high-frequency head movements by generating ocular rotations of equal speed, and in the opposite direction, as that of the head movements. VOR responses are driven by the labyrinth, which is composed of 3 semicircular canals and the otoliths (the utricle and saccule). The labyrinth contains hair cells with cilia that project into the endolymph fluid. Head movement causes endolymph flow that deflects cilia on the hair cells, subsequently altering the neurologic activity of CN VIII (Fig 9-1). The semicircular canals respond to head rotation, and the otoliths respond to linear head movements and static head tilt. Neural activity (excitatory and inhibitory) from these structures passes along the vestibular nerves to synapses in the CN VIII nuclei in the medulla of the brainstem; from there, the activity projects to the ocular motor nuclei (ie, the VOR pathway; see Chapter 1) (Fig 9-2). CN VIII nuclei have interconnections with the cerebellum that “fine-tune” the VOR.

Each semicircular canal responds to head movements and governs ocular rotations within the same plane as the canal. In addition, each semicircular canal responds in opposite ways to head movements in each direction within the plane of the canal. Thus, the right horizontal semicircular canal stimulates right CN VIII discharge in response to rightward head rotation and inhibits right CN VIII discharge in response to leftward head rotation. Conversely, the left horizontal semicircular canal excites the left CN VIII in response to leftward head rotation and inhibits the left CN VIII in response to rightward head rotation. This arrangement results in a “push–pull” relationship between the paired canals in which stimulation from 1 canal occurs with inhibition from the contralateral, paired canal.

Stimulation from the horizontal semicircular canal projects via the CN VIII medial vestibular nucleus to the contralateral CN VI nucleus, resulting in horizontal ocular rotations away from the side of the canal (see Fig 9-2). For example, stimulating the right horizontal semicircular canal generates left gaze. Together, the horizontal canals generate horizontal ocular rotations that are equal in speed and opposite in direction to horizontal head rotation. For example, rightward head rotation stimulates the right horizontal semicircular canal (and inhibits the left horizontal semicircular canal) to generate leftward ocular rotations.

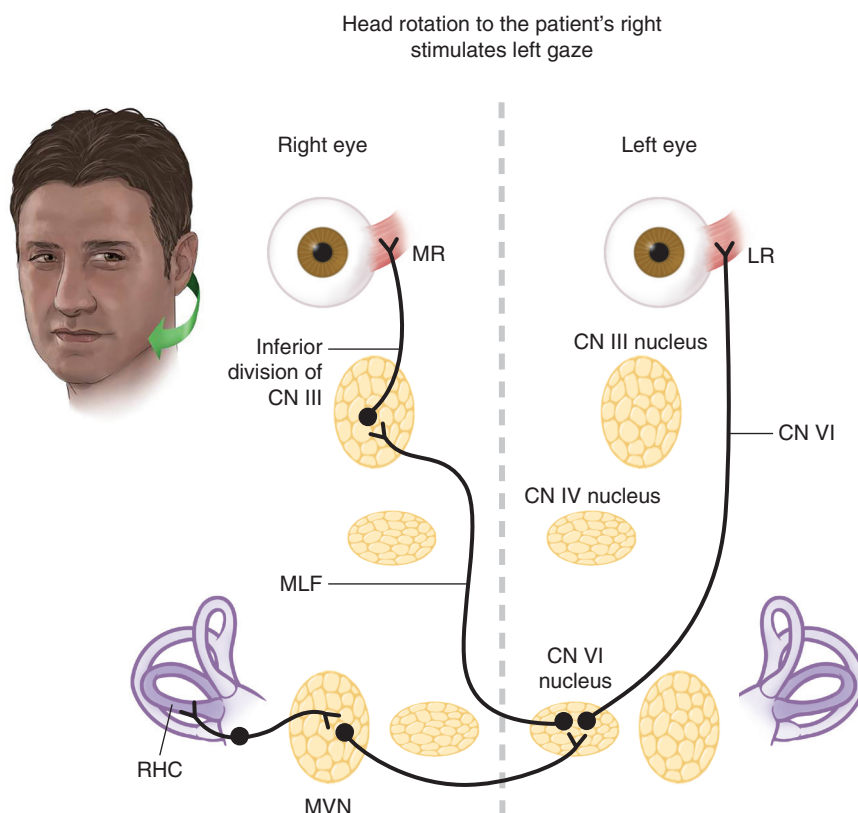


**Figure 9-1** Vestibular system. **A**, Schematic of the mammalian labyrinth. The crista of the lateral semicircular canal is shown but not labeled (with the canal projecting forward). **B**, *Top*: Motion transduction by the vestibular hair cells. At rest, there is a resting rate of action potential discharge in the primary vestibular afferents (center hair cell). Depolarization occurs when the stereocilia are deflected toward the kinocilium (represented by the longest cilium, with a beaded end). Hyperpolarization occurs when the stereocilia are deflected away from the kinocilium. This movement of the stereocilia modulates the discharge rate in the vestibular nerve neuron. *Bottom*: The action potential generated by the shearing forces on the hair cell. Depolarization (*left side of graph*) causes an increase in the frequency of the action potential. Hyperpolarization causes a decrease in the frequency of action potential. (Reproduced with permission from Leigh RJ, Zee DS. *The Neurology of Eye Movements*. 4th ed. Oxford University Press; 2006.)

The anterior semicircular canals stimulate upgaze (in response to downward head rotation), and the posterior canals stimulate downgaze (in response to upward head rotation). The anterior and posterior canals also stimulate contralateral torsion in response to dynamic ipsilateral head tilt.

Sustained head rotation stimulates the VOR to generate slow-phase ocular movements that are *opposite the direction* of head rotation (to maintain fixation); these slow-phase ocular movements alternate with fast-phase, reflexive refixation saccades *in the direction* of head rotation (VOR nystagmus). For example, sustained rightward head rotation stimulates the vestibular system to generate a slow leftward ocular movement followed by a rightward saccade. The VOR response to sustained head rotation attenuates fairly quickly as the cilia on the hair cells resume their normal position. However, a “velocity storage” mechanism prolongs the VOR for several seconds during sustained head movements. This velocity storage mechanism is generated by interconnections within the CN VIII nuclei (the vestibular commissure) and is fine-tuned and stabilized by connections with the cerebellum.

The otoliths (saccule and utricle) respond to linear head movement and static head tilt. Head tilt stimulates a response that partially aligns ocular orientation closer to the horizontal plane. Thus, rightward head tilt stimulates the right utricle to generate compensatory



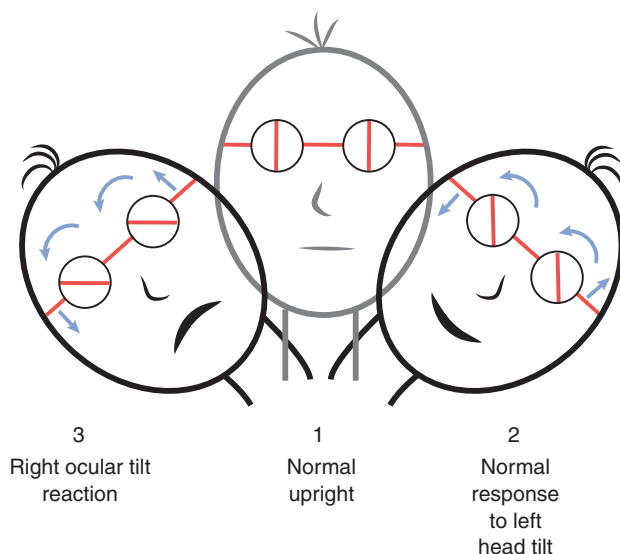
**Figure 9-2** Vestibular ocular pathway for horizontal head turn. Rightward head rotation activates the right horizontal semicircular canal (RHC). Afferent neurons from the RHC project to second-order neurons in the cranial nerve (CN) VIII medial vestibular nucleus (MVN). Axons from the MVN project to the contralateral left CN VI nucleus, which in turn stimulates leftward horizontal ocular rotations. LR=lateral rectus muscle; MLF=medial longitudinal fasciculus; MR=medial rectus muscle. (Adapted from Agnes M. F. Wong, 2008. Illustration by Wendy Hiller Gee; patient image by Rob Flewell, CMI.)

elevation and intorsion of the right eye and depression and extorsion of the left eye. Conversely, leftward head tilt stimulates the left utricle to generate compensatory elevation and intorsion of the left eye and depression and extorsion of the right eye (Fig 9-3).

### **Assessment of vestibular-ocular function**

Examination can readily elicit evidence of VOR dysfunction. Spontaneous nystagmus may be a sign of imbalanced vestibular input, resulting in a slow-phase gaze deviation that disrupts fixation, followed by a fast-phase corrective saccade. The nystagmus amplitude increases with gaze in the direction of the fast-phase saccade (Alexander's law). Nystagmus can be detected by observation of the eyes as the patient fixates on a distant target with the head stationary. Subtle small-amplitude nystagmus can be detected by viewing the fundus with a direct ophthalmoscope while looking for repetitive shifts in the position of the optic nerve head. Note that the optic nerve head is behind the center of ocular rotation and therefore will beat in a direction opposite to that of the nystagmus. This test is first





**Figure 9-3** Right ocular tilt reaction (Skew deviation + Ocular torsion + Head tilt). Tilting the head to the left stimulates the left utricle (2). This results in normal small compensatory eye movements that partially align the eyes closer to the horizontal plane as a *response* to the head tilt; the left eye elevates and intorts, and the right eye depresses and extorts (2). A lesion of the right utricular pathway results in a relative predominance of left utricular pathway stimulation. The relative overaction of the left utricle *drives* a pathologic right ocular tilt reaction (3). This creates the false impression that the head is tilted to the left and the environment is tilted to the right. The head tilts to the right, the right eye depresses and extorts, and the left eye elevates and intorts (3). To achieve the illusion of normal upright orientation (1), a right ocular tilt reaction (3) compensates for the apparent rightward tilt of the environment. With the ocular tilt reaction, the upper poles of each eye rotate toward the lower ear. (Adapted with permission from Kline LB, Bajandas FJ. *Neuro-Ophthalmology Review Manual*. 6th ed. Slack; 2008:71. Modified from Brandt T, Dieterich M. Pathological eye-hand coordination in roll: tonic ocular tilt reaction in mesencephalic and medullary lesions. *Brain*. 1987;110(Pt 3):649–666. Illustration by Wendy Hiller Gee.)

performed while the fellow eye is allowed to fixate on a target. Next, the effect of removing visual fixation (achieved by covering the fixating eye) is assessed. Fixation suppresses nystagmus from peripheral vestibular disorders; thus, the onset of nystagmus after removal of visual fixation suggests the presence of an imbalance of the peripheral vestibular system. In contrast, nystagmus that is not suppressed by fixation suggests a CNS vestibular disorder.

The VOR gain (ie, the ratio of the amplitude of eye rotation to the amplitude of head rotation) can be assessed clinically with the *head impulse test*, which requires the clinician to turn the patient's head briskly (approximately 20°) while the patient fixates on a target. Normally, when the head is rotated 20°, the eyes rotate exactly 20° in the opposite direction, with equal speed, to maintain foveation of a stationary target (Video 9-1). Any imbalance in the VOR gain results in the eyes being “dragged off” target at the end of the head turn, followed by a refixation saccade to recapture the target (Video 9-2). The horizontal semicircular canals are evaluated by horizontal head rotation. When a lesion is present and the head is rotated toward the side of the lesion, a defective response is observed. For example, rightward head rotation should stimulate the right horizontal semicircular canal to generate leftward ocular rotations of equal speed and amplitude. When a lesion is

present in the right horizontal semicircular canal pathway, the eyes will be dragged off target, followed by a leftward, compensatory refixation saccade. The anterior and posterior semicircular canals can be assessed by vertical head rotations.



**VIDEO 9-1** Head impulse, nystagmus, testing for skew (HINTS) test: normal findings.

Courtesy of Daniel Ross Gold, DO, and NANOS/NOVEL. <https://novel.utah.edu>



**VIDEO 9-2** Head impulse, nystagmus, testing for skew (HINTS) test: abnormal findings.

Courtesy of Daniel Ross Gold, DO, and NANOS/NOVEL. <https://novel.utah.edu>



VOR gain can also be tested by measuring visual acuity during head rotations (*dynamic visual acuity*). Relatively small horizontal or vertical head rotations at approximately 2 Hz are performed while the patient reads the Snellen chart. In a patient with normal VOR gain, foveal fixation will be maintained and visual acuity will decrease by 1 or 2 lines at most (Video 9-3). Abnormal VOR gain will produce a mismatch between the amplitude of the eye and head movements, causing the intended target to drift off the fovea; this results in a decrease in visual acuity by several lines. Patients with unilateral vestibular loss will have a decrease in visual acuity of 2–3 lines during horizontal headshaking and will have better visual acuity with vertical headshaking because unilateral vestibular loss impairs horizontal semicircular canal function more than vertical semicircular canal function. Patients with bilateral vestibular loss often have a decrease in visual acuity of 4 or more lines with both horizontal and vertical headshaking.



**VIDEO 9-3** Dynamic visual acuity testing—normal response.

Courtesy of Daniel Ross Gold, DO, and NANOS/NOVEL. <https://novel.utah.edu>



### ***Vestibular-ocular dysfunction***

Eye movement abnormalities can develop from either peripheral or central disruptions of vestibular activity, although peripheral end-organ disease of the semicircular canals is the most common cause of such abnormalities. Patients with vestibular disease often have nystagmus and abnormal VOR gain. Mixed horizontal-torsional nystagmus that is suppressed by fixation suggests peripheral vestibular disease. Purely vertical or torsional nystagmus that is not suppressed by fixation suggests central vestibular disease (see Chapter 10). Abnormal VOR gain is detected with the head impulse test and by measuring dynamic visual acuity as described previously (see Videos 9-1, 9-2, 9-3).

Otolith pathway dysfunction may produce skew deviation or an ocular tilt reaction. *Skew deviation* is a vertical misalignment of the eyes caused by asymmetric otolith pathway input to the ocular motor nuclei (Video 9-4). The vertical misalignment, which may be comitant or incomitant, may simulate a CN IV palsy, including a positive 3-step test result. However, skew deviation typically occurs with intorsion of the hypertropic eye. In contrast, CN IV palsy causes extorsion of the hypertropic eye. In addition,

the vertical deviation in skew deviation typically improves when the patient lies down, whereas it does not change in CN IV palsy. An alternating skew deviation manifests as hypertropia of the abducting eye (ie, right hypertropia on right gaze and left hypertropia on left gaze).



#### VIDEO 9-4 Skew deviation.

Courtesy of Helmut Wilhelm, MD, and NANOS/NOVEL. <https://novel.utah.edu>



The *ocular tilt reaction*, which occurs with otolithic pathway imbalance, consists of a head tilt, skew deviation, and cyclotorsional rotation of the eyes. As described earlier, normally, the otoliths *respond* to head tilt to improve ocular orientation with the horizontal plane (eg, a left head tilt stimulates the left otolith, resulting in elevation and intorsion of the left eye, and depression and extorsion of the right eye). However, a lesion that decreases innervation from the right otolithic pathway (resulting in a pathologic relative increase in innervation from the left otolithic pathway) will *drive* a pathologic right ocular tilt reaction. The increased activity of the left otolithic pathway generates a right head tilt, elevation and intorsion of the left eye, and depression and extorsion of the right eye (right ocular tilt reaction) (see Fig 9-3). The subjective visual vertical may be tilted in the direction of the ocular rotation, although the patient may not recognize that such a shift has occurred.

Skew deviation and the ocular tilt reaction are caused by peripheral or CNS lesions that result in asymmetric otolithic pathway input. A peripheral nerve or caudal CNS lesion will generally be ipsilateral to the hypotropic eye (eg, a right otolith lesion is associated with right hypotropic skew deviation or right ocular tilt reaction driven by the intact left otolithic input) (see Fig 9-3). However, otolithic innervation crosses within the pons and projects to multiple ocular motor nuclei, the interstitial nucleus of Cajal, and the cerebellum. Therefore, a left-sided lesion rostral to this decussation in the pons will be contralateral to the hypotropic eye (eg, a left brainstem lesion above the decussation in the pons is associated with a right hypotropic skew deviation or right ocular tilt reaction). Lesions in the cerebellum can cause either an ipsilateral or contralateral ocular tilt reaction. Despite these generalities regarding localization, skew deviation and the ocular tilt reaction do not reliably localize dysfunction to a specific region of the CNS and may be caused by lesions anywhere in the brainstem or cerebellum (eg, the posterior fossa) that result in asymmetric otolithic input to the ocular motor nuclei. The most common etiologies are stroke, multiple sclerosis, tumor, trauma, abscess, syringobulbia, Arnold-Chiari malformation, and iatrogenic injury from neurosurgical procedures. Acute unilateral peripheral nervous system vestibular lesions can also cause skew deviation. However, these skew deviations are typically small and transient as CNS adaptations equalize otolithic input to the ocular motor CNs.

Evaluation of nystagmus, head impulse testing, and assessment for skew deviation is referred to as the *HINTS* (*head impulse, nystagmus, testing for skew*) test. In a patient with dizziness, this test enables the examiner to distinguish a serious CNS lesion (ie, stroke) from a peripheral vestibular lesion, which is often benign (ie, vestibular neuritis).

A patient with a CNS lesion in the brainstem or cerebellum that disrupts the vestibular pathways may have a vertical nystagmus and a skew deviation. In contrast, a peripheral vestibular lesion will cause a unidirectional horizontal-torsional nystagmus that increases in the direction of the fast phase; an abnormal head impulse test with head rotation to the affected side, and no skew deviation (after CNS adaptations have eliminated the initial transient skew deviation). For example, a patient with a right peripheral vestibular nerve lesion will have a left-beating, horizontal-torsional nystagmus; an abnormal head impulse test with rightward head rotation; and no skew deviation after CNS adaptations have occurred. Each finding alone is not sufficiently reliable to distinguish peripheral from CNS lesions. However, a patient with all 3 of the typical findings for a peripheral nerve lesion on HINTS testing is unlikely to have a CNS lesion, and if the neurologic examination findings are otherwise normal, does not require evaluation for a stroke.

Vestibular imbalance is common with lesions of the caudal brainstem (lower pons and medulla) because of disruption to the CN VIII nuclei or their interconnections. One of the better-known stroke syndromes involving this area is the *lateral medullary syndrome* (or *Wallenberg syndrome*). In general, damage to a lateral region of the brainstem disrupts the sensory pathways; therefore, lateral medullary syndrome is a type of “stroke without paralysis” (see Chapter 2, Fig 2-6). Patients may present with the following signs and symptoms:

- ipsilateral loss of facial pain and temperature sensation (involvement of the descending tract of CN V)
- contralateral loss of hemibody pain and temperature sensation (involvement of the lateral spinothalamic tract)
- ipsilateral cerebellar ataxia (damage to spinocerebellar tracts)
- ipsilateral first-order Horner syndrome
- ipsilateral ocular tilt reaction (head tilt toward the side of the lesion)
- nystagmus (horizontal, torsional, and upbeating vertical)

In addition, patients may have dysarthria, dysphagia, vertigo, or persistent hiccups; there is no extremity weakness.

Although the lateral medulla is in the distribution of the posterior inferior cerebellar artery (PICA), lateral medullary syndrome usually results from occlusion of the more proximal vertebral artery. Consequently, patients may experience *lateropulsion*, the sensation of being pulled toward the side of the lesion, which results from damage to the CN VIII nuclei. Patients may also manifest *ocular lateropulsion*; this effect can be tested by examination of horizontal pursuit and saccadic movements, which will reveal a bias that produces hypermetric movements toward the side of the lesion and hypometric movements away from the side of the lesion. Vertical saccades may follow an elliptical path as the eyes deviate toward the side of the lesion during the vertical movement. Finally, this directional bias also can be observed by noting that the eyes turn toward the side of the lesion after visual fixation is removed for a few seconds (Video 9-5).



#### VIDEO 9-5 Ocular lateropulsion.

Courtesy of M. Tariq Bhatti, MD.



- Brodsky MC, Donahue SP, Vaphiades M, Brandt T. Skew deviation revisited. *Surv Ophthalmol*. 2006;51(2):105–128.
- Donahue SP, Lavin PJ, Hamed LM. Tonic ocular tilt reaction simulating a superior oblique palsy: diagnostic confusion with the 3-step test. *Arch Ophthalmol*. 1999;117(3):347–352.
- Kung NH, Van Stavern GP, Gold DR. HINTS in the acute vestibular syndrome: pearls and pitfalls. *J Neuroophthalmol*. 2018;38(2):244–250.
- Saber Tehrani AS, Kattah JC, Kerber KA, et al. Diagnosing stroke in acute dizziness and vertigo: pitfalls and pearls. *Stroke*. 2018;49(3):788–795.
- Wong AM, Colpa L, Chandrakumar M. Ability of an upright-supine test to differentiate skew deviation from other vertical strabismus causes. *Arch Ophthalmol*. 2011;129(12):1570–1575.

### Optokinetic System (Optokinetic Nystagmus)

The *optokinetic system* maintains steady alignment of images on the retina during *sustained* rotation of the head (or environment). Optokinetic nystagmus (OKN) is induced when a large visual image sweeps across the retina. The initial response is a slow-phase, pursuit-like movement that follows the visual scene, followed by a contraversive, involuntary, reflexive saccade. The VOR generates similar reflexive eye movements. However, the vestibular response is generated by brief head rotations that stimulate the semicircular canals and is attenuated after approximately 30 seconds as the cilia on the hair cells resume their normal position. In contrast, the optokinetic system response is a sustained response that is generated by continuous visual image motion over a large area of retina.

The vestibular and optokinetic systems act synergistically to hold the visual scene steady on the retina during sustained head rotations. For example, when a patient is rotated in the examination chair, the VOR, responding to *input from the semicircular canals*, initially stimulates the slow-phase ocular rotations in the opposite direction that hold the visual image steady on the retina. However, after approximately 30 seconds, the rotation-induced VOR is attenuated. Thereafter, the optokinetic system responds to the *visual scene sweeping across the retina* by providing a sustained output, which generates continuous slow-phase ocular movements that hold the visual image steady on the retina. Throughout, the slow-phase ocular movements alternate with fast-phase refixation saccades, resulting in initial vestibular ocular nystagmus (slow-phase generated by vestibular system alternating with refixation saccades) that is followed after about 30 seconds by OKN (slow-phase generated by optokinetic system alternating with refixation saccades).

The smooth-pursuit system and the optokinetic system are similar but distinct. The smooth-pursuit system is voluntarily activated; its function is to maintain the image of a small moving object on the fovea. In contrast, the optokinetic system is involuntary and is reflexively activated when a large visual image sweeps across a large area of retina.

### Assessment of the optokinetic system

The optokinetic system cannot be isolated for testing in the clinical setting. In order to do so, the moving stimulus would have to fill the complete visual environment. The rotating OKN drum with vertical black-and-white stripes that clinicians use in the office, while



practical, subtends only a portion of the visual field and primarily tests the pursuit and saccade systems, not the optokinetic system.

### ***Optokinetic nystagmus dysfunction***

Isolating the optokinetic system response from the pursuit response to a moving target requires specialized testing equipment not typically used in the clinical setting. As noted previously, the OKN drum subtends a small portion of the visual field and therefore primarily tests smooth-pursuit movements in the direction of drum rotation and saccadic eye movements opposite the direction of drum rotation (eg, drum rotation toward the patient's left side generates a leftward ocular pursuit movement followed by a rightward saccade) (Video 9-6).



**VIDEO 9-6** Optokinetic nystagmus—normal response.

*Courtesy of John J. Chen, MD, PhD.*



Asymmetry of the OKN drum-induced responses can be caused by a unilateral lesion of the cerebral pathways that descend from the ipsilateral parietal, middle temporal, or medial superior temporal areas to the brainstem ocular motor centers. These regions control ipsilateral smooth pursuit. Therefore, abnormal, jerky pursuits (ie, saccadic pursuits) will occur when the OKN drum is rotated toward the side of the lesion. Asymmetry of OKN responses, with normal smooth-pursuit movements produced by drum rotation toward the patient's left and abnormal saccadic pursuit movements produced by drum rotation toward the patient's right, suggests a lesion in the right cerebrum. Typically, lesions of the parietal or parieto-occipital cortex must be relatively large to produce drum-induced asymmetries; these lesions are usually accompanied by a homonymous hemianopia. A lesion confined to the occipital lobe (eg, as usually occurs secondary to a stroke within the distribution of the posterior cerebral artery) also produces a homonymous hemianopia but not OKN asymmetry. Thus, the clinician can use the OKN drum to gain insight into the location and extent of a cerebral lesion that produces a homonymous hemianopia.

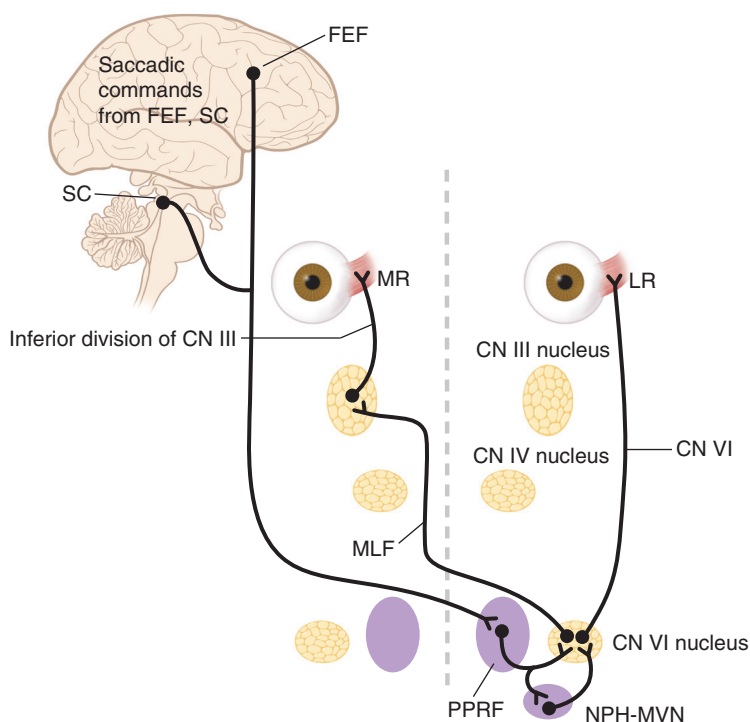
## **Saccadic System**

The saccadic system rapidly shifts the image of a target of interest onto the fovea. Saccades are ballistic, rapid movements that generally cannot be altered once initiated. The speed of saccades correlates with the extent of eye movement; larger-amplitude saccades are faster than smaller-amplitude saccades. This relationship is referred to as the *main sequence*. Saccadic velocity may exceed 500° per second, a speed that allows the eyes to move from primary position to the farthest extent of the temporal visual field in only 0.2 seconds. Saccadic latency (the interval between appearance of a target and onset of a saccade) is approximately 200 milliseconds, and saccadic duration is generally less than 100 milliseconds.

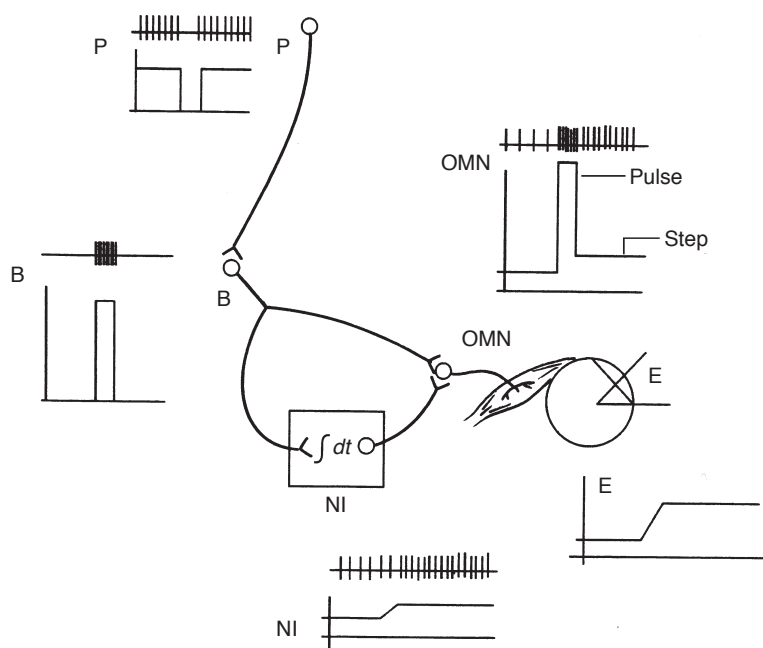
Saccades may be volitional or reflexive (as in the reflexive quick phases of optokinetic and vestibular nystagmus). Volitional saccades are controlled by several areas of the cerebral cortex, including premotor zones that project to the *frontal eye fields (FEFs)* (see Chapter 1). Descending pathways from the FEFs also communicate with several intermediate structures, including the basal ganglia and superior colliculi. Reflexive saccades

are controlled primarily by the superior colliculi. Activation of these pathways generates conjugate, contralateral saccades by innervating the contralateral paramedian pontine reticular formation (PPRF). The PPRF contains 2 populations of neurons: (1) *burst cells* that activate the neighboring CN VI nucleus; and (2) *omnipause cells* that inhibit the burst cells. The FEFs and superior colliculi generate a saccade by stimulating the burst cells and inhibiting the omnipause cells within the contralateral PPRF. The PPRF burst cells project to the adjacent CN VI nucleus, which innervates the ipsilateral lateral rectus muscle and, via the medial longitudinal fasciculus (MLF), the contralateral medial rectus muscle (Fig 9-4).

The PPRF generates saccades via 2 innervational components: (1) a pulse; and (2) a step (Fig 9-5). The *pulse* initiates the saccade with a burst of high-frequency, phasic innervational activity that enables the globe to overcome inertia and the viscous drag of the orbit (gaze initiation). The *step* consists of tonic innervational activity that continues after the saccadic eye movement is complete in order to hold the eye in its new eccentric



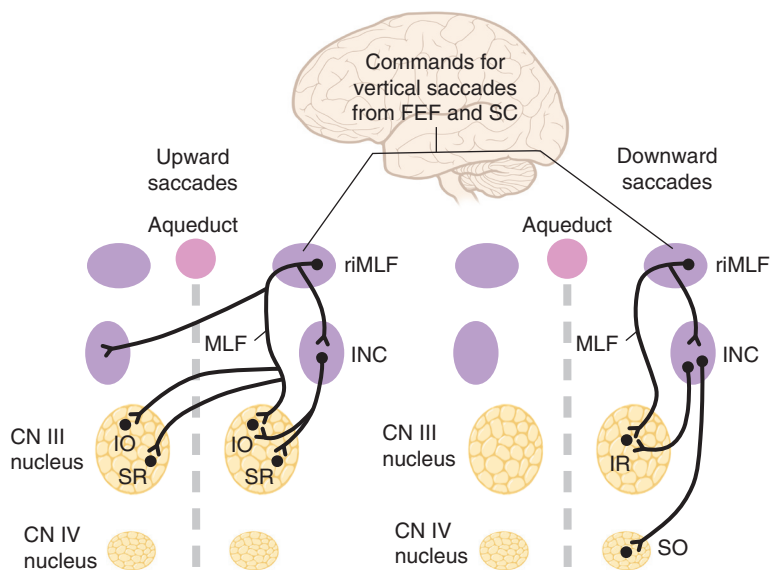
**Figure 9-4** Saccadic system pathway for horizontal saccades. Saccadic commands from the frontal eye field (FEF) and the superior colliculus (SC) project to the contralateral paramedian pontine reticular formation (PPRF). These projections inhibit omnipause cells in the PPRF, resulting in increased discharge from burst cells in the PPRF. Burst cells in the PPRF project to the ipsilateral cranial nerve (CN) VI nucleus. A subpopulation of burst cells in the PPRF projects to the nucleus prepositus hypoglossi–medial vestibular nucleus (NPH-MVN) complex, which in turn projects to the CN VI nucleus. The NPH-MVN complex performs the function of neural integration for horizontal saccades. LR=lateral rectus muscle; MLF=medial longitudinal fasciculus; MR=medial rectus muscle. (Adapted from Agnes M. F. Wong, 2008. Illustration by Wendy Hiller Gee.)



**Figure 9-5** Generation of a saccadic eye movement. Omnipause cells (P) cease their discharge just before the onset of a saccade, allowing burst cells (B) to create the pulse that initiates the saccade. The pulse is received by the neural integrator (NI), which determines the appropriate step ( $dt$ ) needed to maintain the eccentric position of the eyes and modulates the signal to the ocular motoneuron (OMN). The lower-right trace (E) depicts the shift in eye position from baseline to a sustained eccentric position. Vertical lines represent individual discharges of neurons. Underneath each schematized neural (spike) discharge is a plot of discharge rate versus time. (Reproduced with permission from Leigh RJ, Zee DS. *The Neurology of Eye Movements*. 3rd ed. Contemporary Neurology Series. Oxford University Press; 1999.)

position against elastic forces in the orbit (gaze holding). The pulse determines saccade velocity, and the step maintains the position of the eye after the saccade. In order for the saccade to be accurate, the velocity of the saccade (pulse innervation) must match the final ocular position maintained after the saccade is complete (step innervation). The process of matching the pulse and step components of a saccade is referred to as *neural integration*. For horizontal movements, the neural integrator consists of the accessory nucleus of CN XII, also known as the *nucleus prepositus hypoglossi*, in the medulla and the medial vestibular nucleus (NPH-MVN). The PPRF contains neurons that project directly to the CN VI nucleus as well as neurons that project to the neural integrator prior to innervating the CN VI nucleus, enabling pulse–step integration of horizontal saccades (see Fig 9-4). Activation of the CN VI nucleus generates conjugate horizontal eye movements ipsilateral to the PPRF and the CN VI nucleus (see Chapter 1).

The FEFs and the superior colliculi generate volitional and reflexive vertical saccades, respectively, via bilateral descending pathways that project to the *rostral interstitial nucleus of the MLF (riMLF)* (Fig 9-6). The riMLF, which is located in the midbrain, is the supranuclear brainstem center for control of conjugate vertical saccadic eye movements. Neural



**Figure 9-6** Saccadic system pathway for vertical saccades. Commands from the frontal eye field (FEF) and the superior colliculus (SC) project to the rostral interstitial nucleus of the medial longitudinal fasciculus (riMLF). Burst cells in the riMLF project to cranial nerve (CN) III and CN IV nuclei, which in turn project to the vertical extraocular muscles and stimulate vertical saccades. A subpopulation of cells within the riMLF project to the interstitial nucleus of Cajal (INC), which in turn projects to the CN III and CN IV nuclei performing the function of neural integration for vertical eye movements. The INC is the neural integrator for vertical saccades, analogous to the nucleus prepositus hypoglossi–medial vestibular nucleus (NPH-MVN) complex for horizontal saccades. IO = CN III inferior oblique subnucleus; IR = CN III inferior rectus subnucleus; SO = CN III superior oblique subnucleus; SR = CN III superior rectus subnucleus. (Adapted from Agnes M. F. Wong, 2008. Illustration by Wendy Hiller Gee.)

integration of vertical saccades occurs in the nearby *interstitial nucleus of Cajal (INC)*, which matches phasic pulse innervation (gaze initiation) with tonic step innervation (gaze holding) in order to hold the eyes in the proper vertical eccentric position after completion of the saccade; note that this structure is the homologue of the NPH-MVN, which performs the neural integration for control of horizontal eye movements. Thus, the riMLF contains burst-cell neurons that project directly to the CN III and CN IV nuclei as well as neurons that project to the INC prior to innervating these nuclei, enabling pulse–step integration of vertical saccades.

Saccadic eye movements are fine-tuned by the cerebellum, which receives neural input from the pons and supplies innervation to the PPRF and riMLF. The cerebellum influences saccadic speed and accuracy and assists in neural integration (pulse–step matching).

### **Assessment of saccades**

Volitional saccades can be tested by having the patient rapidly shift gaze between 2 targets, such as the extended index fingers of the clinician's outstretched hands, which are held to the left and right of the patient. Reflexive saccades are tested by observing the quick phases of OKN (elicited by patient fixation on a rotating OKN drum) and vestibular nystagmus

(elicited by patient rotation in an examination chair). The *latency* (duration from stimulus to movement), *accuracy* (arrival of the eyes on the target), *velocity*, and *conjugacy* (degree to which the 2 eyes move together) of the movements should be monitored. A *hypometric saccade* falls short of the intended target; 1–2 small catch-up saccades may be within normal limits. A *hypermetric saccade* overshoots the target and is usually pathologic.

### **Saccadic dysfunction**

Saccadic disorders may produce involuntary saccades, reduced speed of saccades, poor accuracy of saccades (ie, hypometria or hypermetria), delayed latency to initiate saccades, or the inability to maintain eccentric gaze after completion of a saccade. The specific saccadic disorder relates to the pattern of neural activity delivered to the ocular motor nuclei. Excessive involuntary firing of burst cells (or excessive inhibition of omnipause cells) in the PPRF causes unwanted, involuntary saccadic intrusions that disrupt fixation (see the section “Ocular fixation dysfunction” earlier in this chapter, and Saccadic Intrusions in Chapter 10).

When a patient appears unable to initiate saccades, the doll’s head maneuver can determine whether this inability is the result of a supranuclear or nuclear/infranuclear lesion. In a patient with a supranuclear lesion that causes a horizontal saccadic gaze deficit, the doll’s head maneuver will activate the intact vestibular-ocular system, bypassing the PPRF and directly stimulating the CN VI nucleus to induce horizontal gaze. Conversely, a CN VI nuclear/infranuclear lesion will impair horizontal gaze in response to the doll’s head maneuver as well as attempted volitional saccades.

Slow saccades can result from central or peripheral lesions (including nuclear and infranuclear lesions). Peripheral lesions almost always result in slowed saccadic movements that are hypometric. In contrast, slow saccades with normal amplitude are typically due to CNS lesions, especially lesions of the cerebral hemispheres or basal ganglia. Irrespective of the location of a CNS lesion, slowed saccades ultimately result from *decreased discharge frequency* of burst-cell neurons, which causes a deficit in phasic innervation (the pulse component) of the saccade. Saccadic slowness confined to the horizontal plane suggests dysfunction of the PPRF in the pons, whereas saccadic slowness confined to the vertical plane suggests dysfunction of the riMLF in the midbrain. Patients with PSP have slow volitional saccades, especially in the vertical plane, but their reflexive saccades (the fast phases of OKN) often are initially normal. Other CNS disorders that cause slow saccades include cerebellar degeneration, Huntington disease, Wilson disease (hepatolenticular degeneration), and Whipple disease. Most of these cases typically include a prolonged latency to initiate saccades. Myasthenia gravis may produce faster-than-normal (“lightning-like”) saccades that suddenly stop short of the intended target (reduced saccadic amplitude/hypometric saccades).

Dysmetric saccades result from peripheral lesions or from *abnormal discharge duration* of the burst-cell neurons responsible for the pulse component of the saccade. Hypometric saccades can be observed with peripheral or central lesions, whereas hypermetric saccades are usually the result of disease of the cerebellum or its interconnections. The accuracy of saccadic eye movements can be difficult to assess in patients with significant bilateral vision loss, especially those with large visual field defects (eg, homonymous



hemianopia and bitemporal hemianopia). Thus, the clinician should exercise caution in describing the presence of inaccurate saccades in these patients.

In other cases, saccades are initiated only after prolonged latency, which is a characteristic feature of ocular motor apraxia (discussed in the following section). Assessment of saccadic latency must take into account the patient's age; a gradual increase in latency may occur with advancing age.

The inability to maintain eccentric gaze after completion of a saccade is a result of decreased tonic innervation (the step component of a saccade). Insufficient tonic innervation arises from infranuclear lesions, cerebellar disease, or malfunction of the neural integrator, often referred to as a leaky integrator (the neural integrator consists of the NPH-MVN for horizontal saccades, the INC for vertical saccades, and the cerebellum for horizontal and vertical saccades). After the saccade is completed, the deficient tonic innervation causes the eyes to drift slowly off the target back to the central position, followed by a corrective saccade toward the target. This combination of eye movements is known as *gaze-evoked nystagmus*.

The most common saccadic dysfunction—the conjugate limitation of upgaze characterized by eye movements that have reduced range but normal velocity—is part of normal aging. Abnormalities of saccadic function are relatively nonspecific with regard to etiology and site of the lesion. However, there are some notable exceptions; saccadic abnormalities that provide important clues to the diagnosis include

- slowed saccades in a patient with extrapyramidal (ie, Parkinson-like) syndrome with imbalance and impaired cognition, which suggest a diagnosis of PSP
- hypermetric saccades, which usually indicate disease of the cerebellum or its outflow pathways
- unidirectional hypermetric saccades, ocular lateropulsion, and hypermetric pursuit movements, which are generally present as part of the lateral medullary syndrome

### **Ocular motor apraxia**

An extreme instance of saccadic dysfunction is ocular motor apraxia, which can be congenital or acquired. An *apraxia* is an inability to voluntarily initiate a movement that can be initiated by another means, which reveals absence of paralysis.

**Congenital ocular motor apraxia (infantile-onset saccade initiation delay)** Ocular motor apraxia in children is characterized by increased latency or failure of saccadic initiation. Volitional and reflexive saccades (in response to OKN and VOR) are affected. Horizontal OKN drum rotation induces lateral gaze in the direction of drum rotation, as slow-phase pursuit movements are relatively intact. However, the failure to generate saccades consistently results in the eyes becoming “locked up” in lateral gaze. Saccades, once generated, are often hypometric. Ocular motor apraxia and its characteristic features in children may be better described as a syndrome and referred to as *infantile-onset saccade initiation delay* or *intermittent saccade failure*.

Congenital ocular motor apraxia (as described by Cogan) is idiopathic and is characterized by increased latency and intermittent failure of horizontal saccadic initiation (Videos 9-7, 9-8). Vertical eye movements are normal. Children with congenital ocular

motor apraxia characteristically use horizontal head thrusts to shift fixation. The rapid horizontal head thrust stimulates the VOR to move the eyes into extreme contraversion. Therefore, the head thrust must be continued past the target of interest until foveation on the target is achieved; this maneuver is followed by slower head rotation in the opposite direction to primary position while the eyes maintain target fixation. Older patients use subtle head movements and blinking to generate saccades. Infants with congenital ocular motor apraxia may be misperceived as having poor vision because they cannot initiate saccades to fixate on objects, and they do not yet have the head control to utilize head thrusts.



**VIDEO 9-7** Cogan congenital ocular motor apraxia.

Used with permission from Oxford University Press. From Leigh RJ, Zee DS. *The Neurology of Eye Movements*. 3rd ed. Contemporary Neurology Series. Oxford University Press; 1999.



**VIDEO 9-8** Cogan congenital ocular motor apraxia: patient reading.

Used with permission from Oxford University Press. From Leigh RJ, Zee DS. *The Neurology of Eye Movements*. 3rd ed. Contemporary Neurology Series. Oxford University Press; 1999.



The location of the lesion that causes congenital ocular motor apraxia is not known. Saccades, once initiated, are of normal velocity and are often hypometric; however, normal-velocity, large-amplitude saccades are occasionally generated, indicating that the burst-cell neurons are intact and that the lesion is therefore proximal to the PPRF. Patients with this condition may have other neurologic abnormalities, including mild developmental delay. Neuroimaging findings may be normal, although multiple abnormalities of uncertain significance, most commonly cerebellar vermis hypoplasia, have been described. Most cases are sporadic, although familial inheritance (autosomal dominant and recessive) has been reported.

Congenital ocular motor apraxia (intermittent saccade failure) in children is associated with several diseases, including ataxia-telangiectasia, Joubert syndrome, Pelizaeus-Merzbacher disease, Niemann-Pick disease type C, Gaucher disease, Tay-Sachs disease, abetalipoproteinemia (which causes vitamin E deficiency), and Wilson disease (Table 9-2). In these cases, both vertical and horizontal saccades are affected. Head thrusting is present in approximately half of these cases. Other signs that should prompt a search for an associated disease include nystagmus, skew deviation, retinal pigment epithelium changes, ataxia, seizures, and progressive developmental delay. If these signs are present, a workup that includes neuroimaging, electroretinography, and genetic evaluation should be considered.

Cogan DG. Congenital ocular motor apraxia. *Can J Ophthalmol*. 1966;1(4):253–260.

Harris CM, Shawkat F, Russell-Eggitt I, Wilson J, Taylor D. Intermittent horizontal saccade failure ('ocular motor apraxia') in children. *Br J Ophthalmol*. 1996;80:151–158.

**Acquired ocular motor apraxia** Acquired ocular motor apraxia results from bilateral lesions of the supranuclear gaze pathways of the frontal and parietal lobes, usually caused by bilateral strokes, often as part of an anoxic encephalopathy following either cardiac arrest, coronary artery bypass grafting, or thoracic aortic aneurysm repair. Patients are unable to

**Table 9-2 Ocular Motor Apraxia****Congenital (infantile-onset saccade initiation delay)**

Cogan idiopathic ocular motor apraxia  
 Joubert syndrome  
 Ataxia-telangiectasia  
 Ataxia-oculomotor apraxia types 1 and 2  
 Abetalipoproteinemia  
 Bardet-Biedl syndrome  
 Cornelia de Lange syndrome  
 Gaucher disease  
 GM gangliosidosis  
 Krabbe leukodystrophy  
 Lesch-Nyhan syndrome  
 Niemann-Pick disease type C  
 Pelizaeus-Merzbacher disease  
 Peroxisomal assembly disorder  
 Propionic acidemia  
 Tay-Sachs disease  
 Wilson disease

**Acquired**

Alzheimer disease  
 Demyelination  
 Frontoparietal lobe infarction or hemorrhage (often from cardiac arrest or cardiac or aortic surgery)

initiate voluntary eye movements, including horizontal and vertical saccades and pursuits. They often blink to break fixation and then turn their head toward a new point of interest. Vestibular reflexive saccades are intact. Bilateral lesions at the parieto-occipital junction may also impair the guidance of volitional saccades. Such inaccurate saccades, together with *optic ataxia* (inaccurate visually guided arm movements to a silent object; eg, when a patient misdirects his or her hand when attempting to shake yours, despite being able to see your hand) and *simultanagnosia* (disordered visual attention that makes it difficult for a patient to perceive all the major features of a scene at once), are known as *Balint syndrome*. This syndrome is often associated with cognitive dysfunction or homonymous visual field defects (see Chapter 7). Etiologies of Balint syndrome include watershed or embolic infarcts, demyelination, and Alzheimer disease.

**Acquired saccadic palsy**

An acquired saccadic palsy can occur from dysfunction of burst cells within the PPRF in the brainstem. The lesions may be too subtle to be seen on magnetic resonance imaging. Common etiologies include heart surgery such as aortic valve replacement and aortic dissection repair. In these cases, there is a palsy of volitional and reflexive (vestibular and OKN) saccades with sparing of all other eye movements. This condition is distinct from acquired ocular motor apraxia, which affects all voluntary eye movements and spares vestibular reflexive saccades.

Eggers SD, Moster ML, Cranmer K. Selective saccadic palsy after cardiac surgery. *Neurology*. 2008;70(4):318–320.

## Smooth-Pursuit System

The smooth-pursuit system generates smooth conjugate eye movements that maintain the image of a moving target on the fovea. Pursuit eye movements can track a moving target both when the head is immobile and when it is in motion. In order to perform the latter function, the pursuit system must override the VOR. For example, rightward head rotation stimulates the VOR to move the eyes in the opposite direction, toward the left. Thus, in order to track a rightward-moving object with simultaneous rightward head rotation, the pursuit system (which tracks the object by moving the eyes toward the right) must cancel the VOR (which drives the eyes in the opposite direction, toward the left).

Pursuit movements cannot be generated without a moving target; attempts to pursue an imaginary target will result in a series of saccades. When a patient tracks an object, the moving target generates signals from the M ganglion cells in the retina that are relayed through the magnocellular layers of the lateral geniculate nucleus to the striate cortex (V1), and from there to the extrastriate cortex. These signals are subsequently relayed to the middle temporal (MT) area (where neurons preferentially respond to the speed and direction of moving stimuli), the medial superior temporal (MST) area, the posterior parietal cortex, and the FEF. The MT and MST areas are part of the *dorsal visual processing stream*, which plays an important role in detecting moving visual stimuli (see Chapter 1, Fig 1-28). The descending cortical pathways of the temporal, parietal, and frontal lobes converge and pass through the posterior limb of the internal capsule to innervate the ipsilateral dorsolateral pontine nucleus (DLPN). The pathway that follows the DLPN comprises 2 decussations (Fig 9-7; see also Chapter 1, Fig 1-30). First, the neurons in the DLPN decussate and project to the contralateral cerebellar lobe (the first decussation), which in turn innervates the medial CN VIII nucleus. Thereafter, neurons in the medial vestibular nucleus decussate and project to the contralateral CN VI nucleus (the second decussation). The CN VI nucleus initiates conjugate horizontal eye movements by innervating the ipsilateral lateral rectus muscle and, via internuclear neurons that travel in the MLF, the contralateral medial rectus muscle. Thus, the cortical regions control ipsilateral pursuit movements as a result of the double decussation pathway. Vertical pursuit movements are generated by similar pathways that ultimately stimulate CN III and CN IV.

### Assessment of the smooth-pursuit system

Clinicians test pursuit eye movements by having the patient's eyes follow a predictably slow-moving target horizontally and then vertically while the head and body are held in position (Video 9-9). Two main types of pursuit dysfunction occur: (1) abnormal gain; and (2) delayed initiation. The gain of pursuit eye movements should be 1—that is, the eyes should accurately follow the slow-moving stimulus. A low gain results in eye movements that trail the target (ie, the motor output is not commensurate with the speed of the moving target), which prompts initiation of catch-up saccades to maintain visual fixation. This combination of too-slow pursuit movements with interposed saccades is called *cogwheel*, or *saccadic pursuit* (see Video 9-9). Conversely, a high gain causes the eyes to pursue ahead of the target, which prompts backup saccades.





**VIDEO 9-9** Normal and defective pursuit.

Courtesy of Heather E. Moss, MD, PhD.

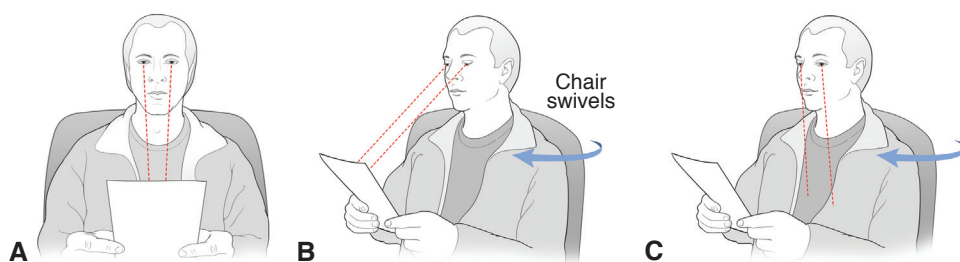


The OKN drum can be used to evaluate smooth pursuit (see Video 9-6). The smooth-pursuit system generates the eye movements that follow the rotating lines on the OKN drum. Pursuit movements toward the side of drum rotation should be accurate without saccadic interruptions. The OKN drum should be rotated to each side to evaluate the symmetry of the pursuit response.

The smooth-pursuit system can also be evaluated by testing VOR cancellation (Fig 9-8). In this test, the patient fixates on a target (the patient's thumb or a near card) held at arm's length while being rotated from side to side in the examination chair (Video 9-10). The patient's head, the target, and the chair rotate in the same direction as a unit. If the smooth-pursuit system cancels the VOR, the patient will maintain fixation on the target during chair rotation. If the smooth-pursuit system does not cancel the VOR because of deficits in VOR cancellation, the VOR will drive the eyes off target in the direction opposite that of the chair rotation, followed by a corrective saccade. For example, a patient with intact VOR cancellation will maintain fixation on his or her thumb during rightward chair rotation. If there is inadequate VOR cancellation, the VOR will drive the eyes away from the thumb and to the left in response to rightward rotation. This will be followed by a rightward corrective saccade, which indicates low pursuit gain to the right (see Fig 9-8). It is normal in such assessments for the patient to exhibit catch-up saccades during the first 4 or 5 rotations but not thereafter.

**VIDEO 9-10** Vestibular ocular reflex cancellation—normal response.

Courtesy of Daniel Ross Gold, DO, and NANOS/NOVEL. <https://novel.utah.edu>



**Figure 9-8** Clinical assessment of vestibular ocular reflex (VOR) cancellation by the pursuit system. **A**, The patient is seated in a swivel chair, fixating on the letters of a near card held at arm's length. **B**, If VOR cancellation is normal (intact), the eyes maintain fixation on the target as the chair, the patient's head and arms, and the card rotate together as a unit. **C**, Conversely, if VOR cancellation is impaired, the eyes are dragged off target during rotation by the VOR. In this example, the chair is rotated to the patient's right, and the VOR moves the eyes to the patient's left, prompting a rightward saccade to regain the target; this result probably indicates cerebellar system pathology. (Illustration by Christine Galapp.)

### ***Smooth-pursuit system dysfunction***

Smooth-pursuit system dysfunction is of poor localizing value. Accompanying neurologic abnormalities are often required in order to determine the location and etiology of the causative lesion.

Abnormal gain is typically observed in older patients without other definable neurologic problems or secondary to use of a wide range of medications. With age, reduced gain decreases the smoothness of pursuit eye movements, although obvious saccadic pursuit is pathologic.

Large cerebral lesions that involve the frontal, parietal, or temporal lobe or the underlying white matter may cause decreased pursuit gain (saccadic pursuits) when the patient fixates on an object moving toward the side of the lesion. These lesions may cause an asymmetric OKN response, with abnormal saccadic pursuits in response to drum rotation toward the side of the lesion and normal smooth pursuits when the drum is rotated away from the side of the lesion. As discussed previously, occipital lobe lesions do not cause OKN asymmetry.

Cerebellar disease of any etiology may cause saccadic pursuits and an inability to cancel the VOR, demonstrated by the chair rotation fixation test (see Fig 9-8 and Videos 9-9, 9-10). Accompanying signs of cerebellar disease are often present.

Smooth-pursuit deficits are usually present in both horizontal and vertical planes, although the vertical plane may be involved selectively in patients with bilateral internuclear ophthalmoplegia, dorsal midbrain syndrome, or PSP.

### **Vergence System**

Vergence eye movements slowly drive the eyes in opposite directions to maintain the image of an object on the fovea of both eyes as the object moves toward or away from the observer. Vergence stimuli include tonic vergence, fusional vergence, accommodative vergence, and voluntary vergence. Without innervation, the anatomy of the orbits creates a divergent misalignment of the eyes (as occurs during sleep or anesthesia). Thus, a baseline amount of *tonic vergence* is required to align the eyes in alert humans. *Fusional vergence* is driven by a disparity in the relative location of images on the retinas and realigns the lines of sight to achieve single binocular vision. *Accommodative vergence* is driven by retinal blur. As an object approaches the eye, retinal blur stimulates the near triad, which consists of accommodation, convergence, and pupillary constriction. Humans are also able to voluntarily stimulate the near triad (*voluntary vergence*). Clinically, the most important stimuli for vergence consist of retinal disparity (fusional vergence) and retinal blur (accommodative convergence, as part of the near triad).

The cerebral structures controlling vergence movements in primates are not well understood. Binocularly driven cortical cells in the occipital lobe as well as regions of the frontal, parietal, and temporal lobes innervate brainstem neurons located in the mesencephalic reticular formation just dorsal to the CN III nuclei (both directly and via the cerebellum). The mesencephalic reticular formation in turn innervates the medial rectus subnucleus of each CN III nucleus, resulting in convergence.

### **Assessment of convergence**

Convergence is tested with an accommodative target that has enough detail to require an effort to see it clearly (a penlight or finger is not adequate). Fusional and accommodative convergences are simultaneously evaluated by determining the near point of convergence (NPC). The patient fixates on a small accommodative target that is slowly brought toward the nose. The NPC is the distance at which fusion is not maintained and a divergent movement occurs. A normal NPC is approximately 3–5 cm from the nose.

Fusional convergence is measured by placing a *base-out prism* in front of 1 eye while the patient fixates on a target, either near or at a distance. The prism strength is increased until diplopia occurs (ie, until fusion is broken). The strength of the prism at which diplopia occurs is the convergence amplitude. Divergence amplitudes are measured in a similar manner with *base-in prisms*. Normal convergence amplitudes are 25 prism diopters ( $\Delta$ ) for distance fixation and 35 $\Delta$  for near fixation. Normal divergence amplitudes are 7 $\Delta$  for distance fixation and 15 $\Delta$  for near fixation.

Accommodative convergence is measured by the accommodative convergence/accommodation ratio (AC/A ratio), using the lens gradient method or the heterophoria method. The *lens gradient method* entails performing the prism and alternate cover test to measure the ocular deviation with distance fixation. The test is repeated with a –2.00 D lens placed in front of each eye. The change in the ocular deviation after lens placement (in prism diopters) is divided by 2 to determine the AC/A ratio. A normal AC/A ratio is 3–5 $\Delta$ /D. The *heterophoria method* determines the AC/A ratio by the following formula:

$$\frac{AC}{A} = \frac{\text{Interpupillary Distance (in centimeters)} + \frac{\text{Deviation Near (30 cm)} - \text{Deviation Distance}}{3}}$$

See BCSC Section 6, *Pediatric Ophthalmology and Strabismus*, for further discussion of accommodation and strabismus.

### **Vergence dysfunction**

Although vergence disorders are common, they can be challenging to diagnose because convergence depends strongly on patient effort. These disorders are frequently classified as convergence insufficiency, accommodative esotropia, spasm of the near reflex, or divergence insufficiency. Unlike other supranuclear disorders, vergence disorders usually result in diplopic symptoms.

**Convergence insufficiency** Convergence insufficiency (CI) is typically a small exodeviation that is greater at near fixation than at distance fixation. It is a common cause of eye strain, headache, blurred vision, and intermittent diplopia during near-point tasks. Patients with CI have decreased fusional convergence amplitudes and a remote NPC, often greater than 10 cm. This condition often occurs as an isolated finding; in the absence of other neurologic symptoms, further workup is not needed. Nonetheless, many neurologic conditions are associated with CI, most notably closed head trauma and extrapyramidal disorders such as Parkinson disease and PSP. Lesions of the pretectal area may also be associated with CI; however, such lesions are typically accompanied by other features of dorsal midbrain syndrome

(see the section Gaze Preference, Gaze Palsy, and Tonic Deviations). In rare instances, lesions of the midbrain (within the mesencephalic reticular formation and just dorsal to the CN III nuclei) may cause CI with normal CN III function. Treatment options include monocular occlusion, convergence exercises, prism glasses (often with separate reading and distance glasses), and, in some cases, strabismus surgery.

**Accommodative esotropia** Excessive convergence tone is typically noted in younger patients who have an inborn convergence abnormality that manifests as an early-onset esotropia—that is, a high AC/A ratio, which produces an excessive amount of convergence for a given amount of accommodation. See BCSC Section 6, *Pediatric Ophthalmology and Strabismus*, for assessment and treatment of accommodative esotropia.

**Spasm of the near reflex (convergence spasm)** Spasm of the near reflex consists of intermittent episodes of excess convergence, increased accommodation, and pupillary constriction. Isolated spasm of the near reflex is almost never related to organic disease. However, when convergence spasm is associated with other abnormalities, especially convergence-retraction nystagmus and reduced conjugate upgaze (as in dorsal midbrain syndrome), organic neurologic impairment is present. Acquired convergence spasm may also be noted in patients with lesions at the junction of the diencephalon and mesencephalon, thalamus, lower brainstem, and cerebellum, in association with other signs and symptoms related to lesion location (eg, thalamic esotropia due to thalamic hemorrhage, Wernicke encephalopathy, Arnold-Chiari malformation, multiple sclerosis, midbrain stroke, and phenytoin intoxication).

**Divergence insufficiency** Divergence insufficiency (DI) is an acquired ocular misalignment defined by an esodeviation that is greater at distance than at near fixation, without lateral incomitance and without abduction deficits. This disorder is usually benign and not related to neurologic dysfunction. In older patients, DI often results from involution of the connective tissue band between the superior rectus and lateral rectus muscles, causing inferior displacement of the lateral rectus muscles (ie, sagging eye syndrome, or age-related distance esotropia). The malpositioned lateral rectus muscles have reduced abduction force, resulting in DI pattern esotropia. Associated findings often include a deep superior sulcus and upper eyelid ptosis from levator dehiscence. In rare cases, DI may be caused by neurologic disorders such as increased intracranial pressure, midbrain tumors, Miller Fisher syndrome, head trauma, intracranial hypotension, Arnold-Chiari malformation, and cerebellar degeneration as well as by thyroid-related orbitopathy (often with other signs of these disorders). In addition, DI can be confused with bilateral CN VI palsies, incipient unilateral CN VI palsy, or resolving CN VI palsy. Unlike DI, CN VI palsy is associated with slow abduction saccades and abduction deficits. When present as an isolated neurologic finding, DI does not require further workup, although patients should be observed for development of other neurologic signs. Treatment options include monocular occlusion, prism glasses, and strabismus surgery.

Chaudhuri Z, Demer JL. Sagging eye syndrome: connective tissue involution as a cause of horizontal and vertical strabismus in older patients. *JAMA Ophthalmol.* 2013;131(5):619–625.

Jacobson DM. Divergence insufficiency revisited: natural history of idiopathic cases and neurologic associations. *Arch Ophthalmol.* 2000;118(9):1237–1241.

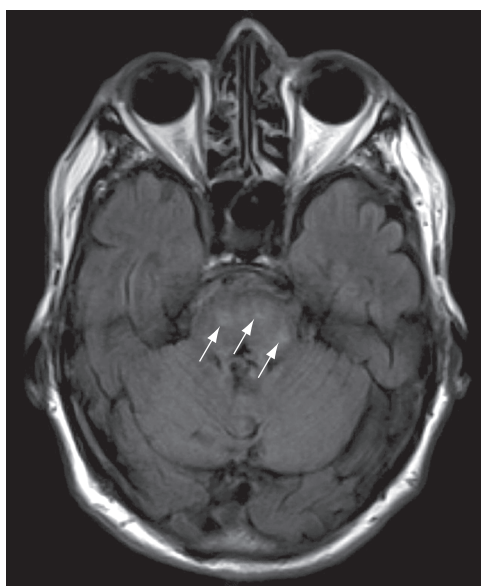
## Gaze Preference, Gaze Palsy, and Tonic Deviations

Gaze preference is an inability to produce volitional gaze contralateral to the side of a cerebral (supranuclear) lesion to the FEF; it is accompanied by a tendency for tonic deviation of the eyes toward the side of the lesion. In such cases, the doll's head maneuver generates a full range of horizontal eye movements because the vestibular-ocular pathways are intact. Stroke is the most common etiology for this type of cerebral injury. The eye movement dysfunction is generally temporary, lasting only days or weeks. Presumably, alternative cerebral-bulbar pathways (perhaps from the parietal lobe) become increasingly capable of generating the saccades and maintaining central gaze.

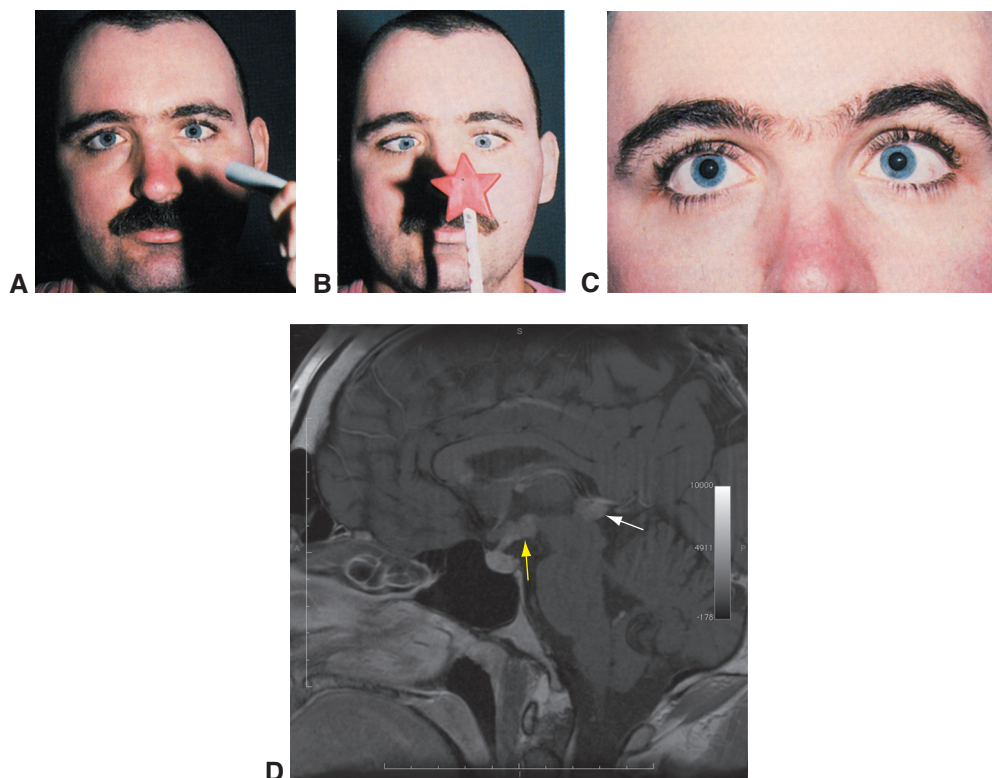
Gaze palsy is a symmetric limitation of the movements of both eyes in the same direction (ie, a conjugate ophthalmoplegia). Brainstem lesions that produce a horizontal gaze palsy disrupt eye movements toward the side of the lesion (opposite to the pattern observed with lesions of the FEF). With CN VI nuclear lesions, a gaze palsy occurs because the CN VI nucleus also contains internuclear neurons destined for the contralateral CN III subnucleus via the MLF. CN VI nuclear lesions damage the final common site for supranuclear innervation of horizontal eye movements; thus, the doll's head maneuver is ineffective in driving the paretic eyes toward the side of the lesion. A PPRF lesion will also cause a gaze palsy that can often be overcome with the doll's head maneuver as the vestibular system projections bypass the PPRF and directly innervate the CN VI nucleus. Bilateral pontine injury can abolish all horizontal eye movements (Fig 9-9). This devastating injury still allows vertical eye movements, which often occur spontaneously (ie, ocular bobbing). Congenital horizontal gaze palsy can occur as part of Möbius syndrome, in which aplasia of the CN VI nuclei is accompanied by bilateral facial paresis.

Vertical gaze palsies can manifest as selective limitation of upgaze or downgaze. In either case, the lesion is usually in the midbrain. Limitation of conjugate upgaze occurs

**Figure 9-9** Bilateral horizontal gaze palsy due to pontine ischemia. The patient had "trouble moving my eyes" but no other neurologic deficits. Axial magnetic resonance imaging (MRI) scan of a brain. The T1-weighted image without contrast shows signal hyperintensity (arrows) in the bilateral pons involving the paramedian pontine reticular formations. (Courtesy of Prem S. Subramanian, MD, PhD.)







**Figure 9-10** Dorsal midbrain syndrome. **A**, A patient with a germinoma pressing on the pretectum shows a poor pupillary light reaction. **B**, The near reaction of the pupils is good. **C**, Attempted upgaze is poorly done. **D**, MRI (T1-weighted with contrast) shows pineal (white arrow) and chiasmal (yellow arrow) germinoma with involvement of the dorsal midbrain, located beneath the pineal lesion. (Parts A–C used with permission from Albert DM, Jakobiec FA, eds. *Principles and Practice of Ophthalmology*, vol 2. Saunders; 1994:2476. Part D courtesy of Prem S. Subramanian, MD, PhD.)

with damage to the pretectum, an isthmus between the superior colliculi and the thalamus. Supranuclear fibers that control vertical gaze (upgaze greater than downgaze) decussate through the pretectum (posterior commissure) as they pass to the riMLF, the midbrain structure that functions as the saccadic generator for vertical eye movements (and thus is the homologue of the PPRF for horizontal saccades). Clinical manifestations of *dorsal midbrain syndrome* (also known as *pretectal* or *Parinaud syndrome*) (Fig 9-10; Videos 9-11, 9-12) include

- conjugate limitation of vertical gaze (usually upgaze) (greater in saccades than in pursuits)
- co-contraction of extraocular muscles with attempted upgaze (convergence-retraction nystagmus)
- mid-dilated pupils with light–near dissociation
- retraction of the eyelids in primary position (*Collier sign*)
- skew deviation

- disruption of convergence (convergence spasm or convergence palsy)
- increased SWJs

Patients with dorsal midbrain syndrome often present with only a subset of these signs, although the limitation of conjugate upgaze is the most common feature. Common etiologies of this syndrome include hydrocephalus, ventriculoperitoneal shunt malfunction, mass lesions (especially pineal-based tumors), multiple sclerosis, stroke, and Whipple disease. The workup includes neuroimaging. Treatment consists of addressing the underlying etiology. Residual diplopia can be treated with prisms, and upgaze deficits can be improved with strabismus surgery.



**VIDEO 9-11** Convergence-retraction nystagmus with upgaze saccade.

*Courtesy of M. Tariq Bhatti, MD.*



**VIDEO 9-12** Convergence-retraction nystagmus demonstrated with optokinetic nystagmus drum rotating down.

*Courtesy of M. Tariq Bhatti, MD.*



The pretectum is the terminal structure supplied by the artery of Percheron (small penetrating arteries that arise from the area around the top of the basilar artery; see Chapter 1). Stenosis at the origin of these vessels, disease of the more proximal basilar artery, or entrapment of emboli that lodge at the top of the basilar artery can cause infarction of the riMLF, resulting in vertical saccadic gaze deficits with relative sparing of vertical pursuit and vestibular-ocular movements.

Deviation of the eyes may occur with seizures involving any cerebral lobe. Most notably, a lesion of the FEF that causes excess neural activity, such as a focal seizure, will drive the eyes contralaterally during the period of the seizure. The head also may turn contralateral to the seizure focus during the ictus. In the postictal state, when there may be lingering hypoactivity of the FEF neurons, the eyes may deviate ipsilateral to the side of the lesion because of a relative increase in input from the unaffected FEF on the opposite side of the brain.

Transient and conjugate downward or upward ocular deviation may occur in healthy newborns. In these cases, the vertical doll's head maneuver can move the eyes out of their tonically held position. Tonic downgaze in premature newborns, however, may be associated with serious neurologic disease, especially when intraventricular hemorrhage expands the third ventricle that presses on the pretectum. Tonic downward deviation of the eyes combined with retraction of the eyelids, referred to as the *setting sun sign*, is primarily observed in children as part of dorsal midbrain syndrome. Conjugate paresis of upgaze is an associated finding, and in these cases, the doll's head maneuver cannot induce upward movements of the eyes.

*Oculogyric crisis* is a tonic upward ocular deviation, sometimes directed toward the right or left. Patients find it difficult to direct their eyes downward. This disorder often arises from an idiosyncratic reaction to neuroleptic antipsychotic drugs such as haloperidol and fluphenazine, as well as antiemetic drugs such as metoclopramide, which are strong dopaminergic blockers. These drugs alter supranuclear input received by the

ocular motor nuclei. The crisis may persist for hours. Patients with Wilson disease may have an oculogyric crisis. Administration of anticholinergic drugs (eg, prochlorperazine) promptly stops the crisis.

Buckley EG, Holgado S. Surgical treatment of upgaze palsy in Parinaud's syndrome. *J AAPOS*. 2004;8(3):249–253.

Caplan LR. "Top of the basilar" syndrome. *Neurology*. 1980;30(1):72–79.

Corbett JJ. Neuro-ophthalmic complications of hydrocephalus and shunting procedures. *Semin Neurol*. 1986;6:111–123.

Keane JR. The pretectal syndrome: 206 patients. *Neurology*. 1990;40(4):684–690.



# The Patient With Nystagmus or Spontaneous Eye Movement Disorders



This chapter includes related videos. Go to [www.aao.org/bcscvideo\\_section05](http://www.aao.org/bcscvideo_section05) or scan the QR codes in the text to access this content.

## Highlights

---

- Sustained, slow eye movements that disrupt fixation characterize nystagmus.
- Sustained, slow eye movements that disrupt fixation, followed by a corrective saccade are referred to as *jerk nystagmus*.
- Continuous back-and-forth, slow eye movements without a corrective saccade are referred to as *pendular nystagmus*.
- Saccadic eye movements that disrupt fixation are referred to as *saccadic intrusions*.

## Introduction and Terminology

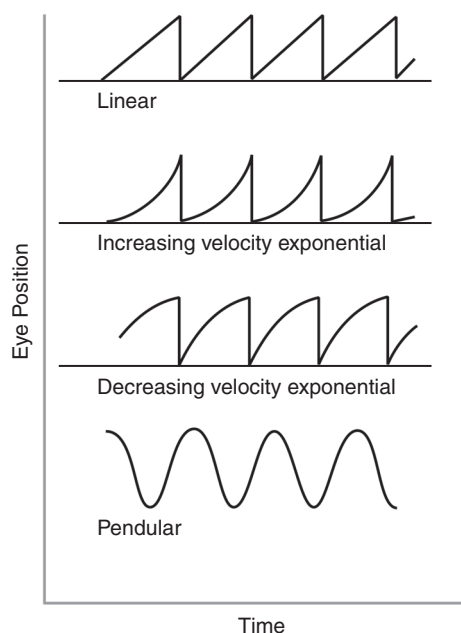
---

A variety of diseases, drugs, or other factors may disrupt the systems that provide ocular stability. Abnormal eye movements may occur because of inability to maintain fixation, loss of the normal inhibitory influences on eye movement control, or loss of the normally symmetric input from one of the vestibular pathways to the ocular motor nuclei. *Nystagmus* refers to one form of excessive eye movements; this term should be reserved for rhythmic, to-and-fro (eg, horizontal, vertical, torsional, or mixed) eye movements that incorporate a slow phase. *Jerk nystagmus* has 2 phases: (1) a slow-phase drift from the visual target, followed by (2) a corrective saccade (fast phase) back to the target. *Pendular nystagmus* describes back-and-forth slow-phase movements that occur without a fast phase (Fig 10-1). Abnormal saccadic movements may also drive the eyes off fixation. Collectively, these pathologic eye movements are called *saccadic intrusions* or *saccadic oscillations*; because they have no slow phase, they do not conform to the definition of nystagmus.

In 2001, a National Eye Institute (NEI)–sponsored committee published “The classification of eye movement abnormalities and strabismus (CEMAS),” which provides a



**Figure 10-1** Nystagmus waveforms are named for their slow-phase velocity profile. *From top to bottom:* Linear velocity is typical of vestibular nystagmus; increasing velocity exponential typifies infantile nystagmus syndrome; decreasing velocity exponential typifies fusion maldevelopment nystagmus syndrome and gaze-evoked nystagmus; and pendular waveform typifies infantile nystagmus syndrome and acquired pendular nystagmus. (Modified with permission from Kline LB, Bajandas FJ. *Neuro-Ophthalmology Review Manual*. 6th ed. Slack; 2008.)



systematic classification of primary eye movement abnormalities and strabismus conditions. Formal definitions of the entities discussed in this chapter can be found in this document. In general, this chapter uses the CEMAS terms recommended by the NEI-sponsored committee; the traditional designations are given within parentheses in headings except where noted. For further discussion of many of the topics covered in this chapter, see Chapter 9.

CEMAS Working Group. A National Eye Institute sponsored workshop and publication on the classification of eye movement abnormalities and strabismus (CEMAS). In: Hertle RW, ed. *The National Eye Institute Publications*. National Eye Institute, National Institutes of Health; 2001.

## Assessment of Eye Movement Abnormalities

Nystagmus in children and adults may degrade vision. Patients with acquired nystagmus often report *oscillopsia*, in which there appears to be back-and-forth environmental movement. Children with early-onset nystagmus typically do not have oscillopsia but often have reduced visual acuity. During the examination, patients should be asked about any associated neurologic symptoms (eg, vertigo, ataxia, motor weakness, or sensory weakness) and any family history of abnormal eye movements or strabismus.

An examination of ocular motility begins with an assessment of ocular stability in primary gaze. Any abnormal eye movements in the cardinal positions should be examined to determine whether they are

- monocular or binocular
- conjugate (ie, the eyes behave similarly)

- horizontal, vertical, torsional, or mixed in pattern
- continuous or induced by a particular eye position
- characterized by slow phases only (ie, pendular nystagmus), fast and slow phases (ie, jerk nystagmus), or fast phases only (ie, saccadic intrusion)
- reduced at a null point (ie, the field of gaze at which the nystagmus is minimal)

By convention, the direction of jerk nystagmus is reported as the direction of its fast-phase component; however, it is the slow-phase component that indicates the pathology. In *dissociated* or *disconjugate nystagmus*, the amplitude of oscillations differs in each eye; in *disjunctive nystagmus*, the direction of the oscillations differs between the 2 eyes.

The amplitude of nystagmus often changes with gaze position. A few beats of nystagmus are normally present at the extremes of horizontal gaze (beyond 45°), especially in older patients. This finding should not be considered pathologic unless the nystagmus is persistent, asymmetric (eg, present to the left but not the right), or accompanied by other features. Assessment for nystagmus can be complemented by strategies that search for subtler, smaller-amplitude eye movements. Illuminated Frenzel (high-magnification) goggles are extremely useful for detecting eye movements, but a 20 diopter (D) lens, slit lamp, or direct ophthalmoscope can also be used to block the patient's fixation and magnify abnormal eye movements. Ocular motor recordings (eg, via electro- or video-oculography, infrared tracking, or electromagnetic scleral search-coil techniques) provide objective and highly sensitive measurements of eye movements but are often unavailable in standard clinical practice. The characteristics of eye movements can be recorded and communicated effectively via drawings and video recordings.

Leigh RJ, Zee DS. *The Neurology of Eye Movements*. 5th ed. Contemporary Neurology Series. Oxford University Press; 2015.

Serra A, Leigh RJ. Diagnostic value of nystagmus: spontaneous and induced ocular oscillations. *J Neurol Neurosurg Psychiatry*. 2002;73(6):615–618.

## Early-Onset (Childhood) Nystagmus

---

See BCSC Section 6, *Pediatric Ophthalmology and Strabismus*, for additional discussion of early-onset nystagmus.

### Infantile Nystagmus Syndrome (Congenital Nystagmus)

Infantile nystagmus syndrome (INS), or congenital nystagmus, is often recognized in the first few months of life but may not become evident until several months later. There may be a family history of the disorder.

INS is almost always conjugate and horizontal on clinical examination, even in up-gaze and downgaze (Video 10-1). The nystagmus may be continuous or intermittent and can appear as jerk or pendular movements in different positions of gaze. The jerk movement, when present, is typically right beating in right gaze and left beating in left gaze. Eye movement recordings show that these movements are often punctuated by *foveation periods* (brief periods in which the eyes are still and aimed at the object of regard). There is frequently a *null point*, the field of gaze in which nystagmus intensity is minimal and

the foveation period is increased, thereby maximizing visual function. If the null point is not in primary position, patients often adopt a horizontal or vertical head turn or head tilt that places the eyes in the null position in order to improve vision. Visual attention and fixation usually amplify INS (in contrast to peripheral vestibular nystagmus, discussed later in this chapter), whereas convergence on a near target damps the amplitude of the nystagmus. INS is abolished during sleep.



**VIDEO 10-1** Infantile nystagmus syndrome.  
Courtesy of Paul H. Phillips, MD.



There are 2 characteristic signs of INS:

- *Reversal of the normal pattern of optokinetic nystagmus (OKN).* Patients with INS respond to OKN drum rotation with slow-phase eye movements in the direction opposite to that of the rotating drum.
- *A unique pattern in which the velocity of the slow-phase movement increases exponentially.* This increasing-velocity waveform is punctuated by foveation periods. Determining this pattern requires analysis of eye movement recordings (see Fig 10-1).

As mentioned previously, children with INS usually do not have oscillopsia. Visual acuity is determined by the length of the foveation period as well as the accompanying afferent pathway disease, if present. Visual acuity is often reduced, although some patients achieve normal visual acuity. Strabismus occurs in approximately 30% of patients.

INS is associated with conditions that cause *bilateral, pregeniculate vision loss* before 2 years of age. Therefore, the workup of a patient with early-onset nystagmus should include a search for clinical manifestations of pregeniculate vision loss. In some patients, the etiology may be obvious, such as in children with bilateral dense congenital cataracts. But when the eyes do not have an obvious structural abnormality, the patient should be evaluated for the following conditions, which may be subtle and difficult to detect in uncooperative children:

- *Optic neuropathy.* INS occurs with bilateral optic neuropathies that occur before 2 years of age, most commonly optic nerve hypoplasia. The clinician should consider obtaining neuroimaging to detect hydrocephalus or a compressive lesion. The detection of optic nerve hypoplasia requires an endocrinologic evaluation for associated hypopituitarism.
- *Foveal hypoplasia.* INS occurs with foveal hypoplasia, often in patients with albinism or aniridia. Patients should be assessed for other signs of albinism, such as iris transillumination defects and hypopigmentation of the retinal pigment epithelium, choroid, skin, and hair. Albinism and aniridia may be familial.
- *Retinal dystrophy.* INS may occur with early-onset retinal dystrophies such as achromatopsia and Leber congenital amaurosis. Patients should be assessed for other signs of retinal dystrophy, such as photophobia, nyctalopia, eye pressing, paradoxical pupils, high refractive error, and progressive visual loss. Retinal examination may show

mild pallor of the optic nerve head and vessel attenuation, or the findings may be normal. The clinician should determine whether the patient has a familial history of retinal dystrophies. Ultimately, electrophysiologic testing (eg, electroretinography), genetic testing, or both, may be required for diagnosis. Children with regression of developmental milestones require further workup for neurometabolic disease.

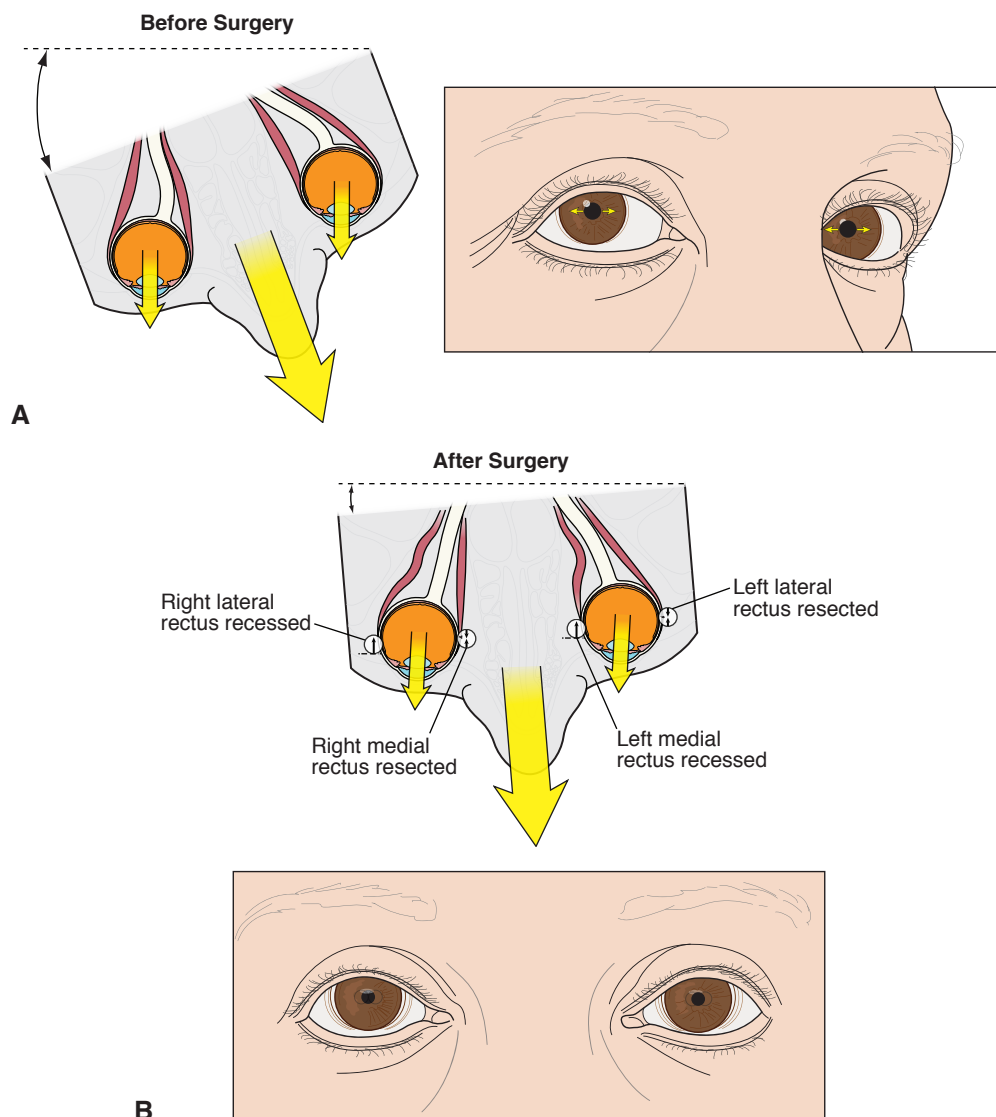
Approximately 40% of children with typical INS will have no detectable afferent pathway abnormality despite an extensive workup that includes electrophysiologic testing.

Off-label (treatments prescribed for an indication other than those that have received approval from the US Food and Drug Administration) use of memantine or gabapentin may reduce the severity of nystagmus and improve visual function in some patients with INS. However, these medications have adverse effects and are not commonly used for childhood nystagmus. Contact lenses may improve visual function in patients with INS, and the use of base-out prisms to induce convergence may improve visual function in those whose nystagmus damps with convergence. Some patients with INS can be treated with extraocular muscle surgery (eg, the Anderson-Kestenbaum procedure) to mechanically shift the null point closer to primary position (Fig 10-2; see also Fig 12-4 in BCSC Section 6, *Pediatric Ophthalmology and Strabismus*). A similar procedure may be performed on the vertical recti of a patient with a vertical null point, although diplopia may occur postoperatively because of limited vertical fusional amplitudes. In certain patients, horizontal rectus muscle tenotomy and reattachment of these muscles to their original insertion site may induce a variable reduction in nystagmus amplitude and improve visual function.

- Bertsch M, Floyd M, Kehoe T, Pfeifer W, Drack AV. The clinical evaluation of infantile nystagmus: what to do first and why. *Ophthalmic Genet.* 2017;38(1):22–33.
- Hertle RW. Nystagmus in infancy and childhood. *Semin Ophthalmol.* 2008;23(5):307–317.
- Hertle RW, Dell’Osso LF. Clinical and ocular motor analysis of congenital nystagmus in infancy. *J AAPOS.* 1999;3(2):70–79.
- Hertle RW, Dell’Osso LF, FitzGibbon EJ, Thompson D, Yang D, Mellow SD. Horizontal rectus tenotomy in patients with congenital nystagmus: results in 10 adults. *Ophthalmology.* 2003;110(11):2097–2105.
- Hertle RW; National Eye Institute Sponsored Classification of Eye Movement Abnormalities and Strabismus (CEMAS) Working Group. A next step in naming and classification of eye movement disorders and strabismus. *J AAPOS.* 2002;6(4):201–202.
- Richards MD, Wong A. Infantile nystagmus syndrome: clinical characteristics, current theories of pathogenesis, diagnosis, and management. *Can J Ophthalmol.* 2015;50(6):400–408.

### **Fusional Maldevelopment Nystagmus Syndrome (Latent Nystagmus)**

Fusional maldevelopment nystagmus syndrome (FMNS), or latent nystagmus, is an early-onset, conjugate, horizontal jerk nystagmus that is accentuated by monocular fixation. The nystagmus intensity in FMNS decreases with fusion (binocular function). However, when 1 eye is occluded (thereby eliminating fusion), the fixating eye slowly drifts toward the nose, and a corrective abducting saccade follows. The eye under the occluder is moving in the same direction and with the same amplitude as the fixating eye (ie, the nystagmus is conjugate). Thus, the direction of the fast phase component of both eyes beats toward the



**Figure 10-2** Surgical treatment of infantile nystagmus syndrome. **A**, The nystagmus null point is in right gaze (patient maintains left head turn). **B**, The Anderson-Kestenbaum procedure shifts the null point centrally and reduces the head turn. The right lateral rectus and left medial rectus muscles are recessed. The right medial rectus and left lateral rectus muscles are resected. (Illustration by Mark Miller.)

viewing eye and away from the occluded eye. The direction of the fast phase immediately reverses upon occlusion of the fixating eye as the fellow eye takes up fixation (Video 10-2). Consequently, when a standard occluder is used to measure visual acuity in patients with FMNS, acuity is often degraded by the induced nystagmus. Partial optical blurring of 1 eye (with a high-plus lens or filter) may not exacerbate the nystagmus of FMNS (compared with occlusion), and thus may permit better visual acuity measurements in the fellow eye.



Eye movement recordings show that the nystagmus in FMNS typically has a constant-velocity or decelerating slow phase, in contrast to the increasing exponential waveform of INS. FMNS and INS may coexist (see Fig 10-1).



**VIDEO 10-2** Fusion maldevelopment nystagmus syndrome.

*Courtesy of Robert W. Hered, MD.*



FMNS may occur when both eyes are open if 1 eye is suppressed, a condition called *manifest latent nystagmus (MLN)*. In other words, the nystagmus is damped with fusion but develops spontaneously whenever suppression of 1 eye occurs; therefore, the clinician may not need to occlude an eye to induce this form of nystagmus.

FMNS occurs with any condition that disrupts binocularity in the first 6 months of life, most commonly infantile esotropia. Other associated conditions include severe anisometropia, constant infantile exotropia, monocular cataract, corneal opacities, and unilateral microphthalmos. If 1 eye has severe structural damage and poor vision (as occurs in unilateral microphthalmos), the fellow eye with normal vision will always be the fixating eye and the nystagmus in FMNS will always beat toward that eye (because the abnormal eye with poor vision is unable to take up fixation). Patients may maintain a head turn toward the fixating eye. This head position places the fixating eye in adduction, thereby damping the nystagmus in order to improve vision.

Patients with FMNS often have other associated signs of abnormal binocular development, such as dissociated vertical deviation, oblique overaction, and smooth-pursuit asymmetry (in which the fixating eye is able to pursue a target moving toward the nose but has difficulty pursuing a target moving away from the nose).

Treatment consists of measures that improve fusion when possible, such as glasses, strabismus surgery, or both.

Dell'Osso LF, Schmidt D, Daroff RB. Latent, manifest latent, and congenital nystagmus.

*Arch Ophthalmol.* 1979;97(10):1877–1885.

## Heimann-Bielschowsky Phenomenon

Monocular nystagmus in an eye with long-standing poor vision is often referred to as the Heimann-Bielschowsky phenomenon. This phenomenon may occur in patients with poor vision from a variety of underlying etiologies, including optic neuropathy and amblyopia. Onset may occur in adulthood with highly asymmetric vision loss, and the phenomenon may not remit even if the visual problem (eg, dense cataract) is corrected. The nystagmus is characterized by intermittent, monocular, vertical, slow, pendular eye movements of low frequency and variable amplitude (Video 10-3). The workup is directed toward determining the etiology of the vision loss. The cause may be obvious on ophthalmologic examination, requiring no additional diagnostic testing (eg, in an infant with unilateral microphthalmos). However, monocular vertical nystagmus in an infant with a relative afferent pupillary defect and optic nerve head atrophy suggests an optic nerve or chiasmal tumor (glioma) and therefore warrants neuroimaging. Symptomatic oscillopsia is uncommon and can be treated with gabapentin. Strabismus surgery can improve appearance.

**VIDEO 10-3** Heimann-Bielschowsky phenomenon.

*Courtesy of Paul H. Phillips, MD.*



## Spasmus Nutans Syndrome

Spasmus nutans syndrome is a childhood nystagmus characterized by asymmetric, small-amplitude, high-frequency, “shimmering” eye movements, often accompanied by head nodding and an abnormal head position (*torticollis*). The nystagmus may be dissociated (sometimes even monocular), and the amplitude and phase relationships of the eye movements may vary between the eyes over the course of a few seconds. The shimmering eye movements are often variable or intermittent; may occur in the horizontal, vertical, or oblique plane; and may increase in the abducted eye during lateral gaze (Video 10-4). Head nodding, torticollis, or both occur in approximately 60% of patients and appear to damp the nystagmus and improve vision.

**VIDEO 10-4** Spasmus nutans.

*Used with permission from Oxford University Press. From Leigh RJ, Zee DS. The Neurology of Eye Movements. 5th ed. Contemporary Neurology Series. Oxford University Press; 2015.*



Spasmus nutans syndrome is typically acquired at 6–24 months of age, although onset may range from 2 weeks to 3 years. Clinically, spasmus nutans spontaneously improves usually within 3–4 years, but in rare cases persists for up to 8 years. Secondary amblyopia and strabismus may occur in the more involved eye. The syndrome is sometimes familial and is associated with African-American ethnicity, Hispanic ethnicity, and low socioeconomic status.

In general, spasmus nutans syndrome is distinguished from INS by the asymmetric or monocular high-frequency, small-amplitude, shimmering, multiplanar, variable nature of the nystagmus. In contrast, INS consists of larger-amplitude, lower-frequency bilateral conjugate, symmetric, horizontal, constant ocular movements.

The etiology of spasmus nutans syndrome is unknown. Chiasmal/suprachiasmal tumors (eg, optic pathway gliomas), retinal dystrophies (eg, congenital stationary night blindness), and neurodegenerative disorders (eg, Pelizaeus-Merzbacher disease or Leigh disease [also known as subacute necrotizing encephalopathy]) may result in an identical nystagmus. Therefore, neuroimaging is indicated for patients with presumed spasmus nutans syndrome to exclude a glioma of the anterior visual pathway or other parasellar or hypothalamic tumors. If the patient shows signs of a retinal dystrophy (eg, progressive visual loss, photophobia, nyctalopia, eye pressing, paradoxical pupils, or high refractive error), an electroretinogram and/or genetic testing for retinal dystrophies should be considered. Progressive developmental delay requires an evaluation for neurodegenerative disease.

Patients with spasmus nutans syndrome should be monitored and treated for any associated amblyopia and strabismus. As noted earlier, the abnormal eye and head movements typically diminish after several years (usually by the end of the first decade of life). Lack of resolution or development of other neurologic problems should prompt appropriate evaluation, including neuroimaging.

Kiblinger GD, Wallace BS, Hines M, Siatkowski RM. Spasmus nutans-like nystagmus is often associated with underlying ocular, intracranial, or systemic abnormalities. *J Neuroophthalmol.* 2007;27(2):118–122.

Lambert SR, Newman NJ. Retinal disease masquerading as spasmus nutans. *Neurology.* 1993;43(8):1607–1609.

## Gaze-Evoked Nystagmus

Gaze-evoked nystagmus develops because of an inability to maintain fixation in eccentric gaze. The eyes drift back to the midline as a result of the elastic properties of the orbit, and a corrective saccade is generated to reposition the eyes on the eccentric target (Video 10-5). Therefore, the fast phase is always in the direction of gaze. The amplitude of the nystagmus increases as the eyes are moved in the direction of the fast phase. This pattern is in accordance with Alexander's law, which states that nystagmus increases in intensity (amplitude and frequency) as the eyes are moved in the direction of the fast phase.



### VIDEO 10-5 Gaze-evoked nystagmus and rebound nystagmus.

Used with permission from Oxford University Press, USA. From Wong AMF. Eye Movement Disorders. Oxford University Press; 2008.



Gaze-evoked nystagmus is most commonly caused by dysfunction of the *neural integrator* (see Chapters 1 and 9). For horizontal gaze, the neural integrator consists of the nucleus prepositus hypoglossi and medial vestibular nucleus (NPH-MVN). For vertical gaze, the interstitial nucleus of Cajal (INC) serves as the neural integrator. The cerebellum also participates in neural integration of both horizontal and vertical eye movements.

When eccentric gaze is initiated, the neural integrator receives a velocity signal (the *pulse*) from the appropriate gaze center and, through the mathematical process of integration, generates tonic innervation (a *step* signal) to maintain the eccentric position of the eyes after the ocular movements have been completed (see Chapter 9, Fig 9-5). Thus, the neural integrator ensures a level of neural activity adequate to maintain the eyes in an eccentric position of gaze against the elastic forces of the orbit. When the neural integrator fails to function properly (ie, becomes “leaky”), the tonic innervation (step signal) that holds the eyes in eccentric gaze is deficient. Consequently, after completion of eccentric gaze, the eyes slowly drift off the target back to the central position, and a corrective saccade toward the target follows—hence the term *gaze-evoked nystagmus*.

Pathologic gaze-evoked nystagmus is caused by dysfunction of the structures in the brainstem (NPH-MVN and INC) and/or cerebellum that participate in neural integration. A medullary lesion that affects the NPH-MVN causes horizontal gaze-evoked nystagmus (ie, Wallenberg syndrome; see Chapter 9); a midbrain lesion that affects the INC may cause vertical gaze-evoked nystagmus. Because the cerebellum participates in neural integration of both horizontal and vertical eye movements, cerebellar disease may cause horizontal and vertical gaze-evoked nystagmus. A few beats of symmetric, low-frequency, small-amplitude jerk nystagmus at the extremes of far horizontal gaze without other ocular motility dysfunction (eg, rebound nystagmus or saccadic dysmetria) constitute physiologic endpoint nystagmus and are not clinically significant. However, sustained, large-amplitude,

or asymmetric gaze-evoked nystagmus is pathologic and should prompt further evaluation. The 2 most common etiologies are (1) toxic effects from drugs and medications (eg, alcohol, sedatives, anticonvulsants, and antidepressants); and (2) cerebellar disease. Whenever gaze-evoked nystagmus is asymmetric, an ipsilateral lesion of the brainstem or cerebellum—typically stroke, demyelination, or tumor—is presumably present. Such a finding should prompt appropriate patient evaluation, including targeted neuroimaging. End-organ disease, such as cranial nerve (CN) palsy, myasthenia gravis, and extraocular myopathies, can also cause gaze-evoked nystagmus, with a pattern similar to that observed with lesions of the central nervous system (CNS).

## Rebound Nystagmus

In some patients with gaze-evoked nystagmus, prolonged eccentric gaze (>30 seconds) reduces the amplitude of the nystagmus. However, when these patients resume central gaze position, a jerk nystagmus develops in the opposite direction of the initial gaze-evoked nystagmus, a condition referred to as *rebound nystagmus* (see Video 10-5). Prolonged eccentric viewing likely induces brainstem/cerebellar compensatory mechanisms that gradually increase tonic innervation toward eccentric gaze, thereby reducing the gaze-evoked nystagmus. When the patient resumes central gaze, residual tonic innervation continues to drive the eyes toward the prior eccentric gaze position, and a corrective saccade in the opposite direction (rebound nystagmus) follows. For example, a patient with gaze-evoked nystagmus may have a gradual reduction of the amplitude of a rightward-beating nystagmus with prolonged right gaze because brainstem/cerebellar compensatory mechanisms gradually increase tonic right-gaze innervation. However, when the patient resumes central gaze, the residual tonic right-gaze innervation continues, inducing a slow-phase ocular rotation toward the right, followed by a corrective, leftward-beating saccade (ie, rightward-beating gaze-evoked nystagmus in right gaze followed by leftward-beating rebound nystagmus upon the patient's resumption of central gaze). Gaze-evoked nystagmus accompanied by rebound nystagmus is often a manifestation of cerebellar disease.

## Vestibular Nystagmus

---

### Peripheral Vestibular Nystagmus

Patients with peripheral vestibular nystagmus typically present with a sudden, sometimes dramatic, onset of disequilibrium with vertigo, nausea, and vomiting (Table 10-1). Often, they recognize that their symptoms are worsened by particular head movements or positions. Oscillopsia, tinnitus, and hearing loss may also occur. After the acute phase of peripheral vestibular loss, which typically lasts days, patients experience a slow period (lasting weeks to months) of gradually waning symptoms. Even patients who become asymptomatic may experience discomfort months to years later when their vestibular system is challenged, for example, when riding in a fast-moving car or boat.

Peripheral vestibular nystagmus results from dysfunction of the end-organs (eg, semicircular canals, otolithic structures, or vestibular nerve). End-organ damage is usually

**Table 10-1 Clinical Characteristics of Peripheral Vestibular Nystagmus**


---

Severe vertigo
Tinnitus or hearing loss (may occur)
Horizontal nystagmus with torsion
Horizontal nystagmus without torsion (rare)
Pure vertical or torsional nystagmus (extremely rare)
Symptoms lasting days to months, improving over time (may be recurrent)
Nystagmus damped by visual fixation
Commonly caused by labyrinthitis, Ménière disease, trauma, toxicity

---

unilateral or asymmetric (except in cases of toxicity) and disrupts the normally symmetric vestibular afferent input to the ocular motor nuclei. Asymmetric afferent input from the semicircular canals generates vestibular nystagmus. The characteristics of peripheral vestibular nystagmus reflect the combined effects of decreased afferent input from all 3 semicircular canals.

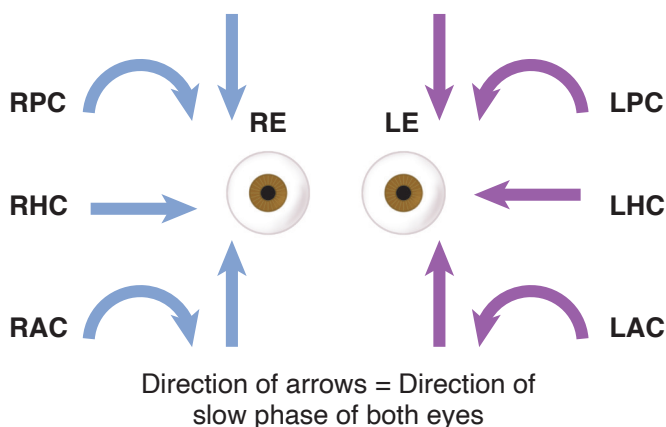
Input from the horizontal semicircular canal is routed to the contralateral abducens nucleus (see Chapters 1 and 9). Therefore, stimulating the horizontal canal generates contralateral horizontal gaze (see Chapter 9, Fig 9-2). Conversely, a lesion of the horizontal canal results in ipsilateral gaze. Therefore, a lesion of the horizontal canal results in a tonic gaze deviation toward the side of the lesion, followed by a corrective saccade away from the side of the lesion (ie, nystagmus beats away from the lesion). For example, a left-sided vestibular lesion reduces input from the left horizontal semicircular canal, resulting in a leftward tonic gaze deviation, followed by a corrective saccade away from the side of the lesion. Thus, a left-sided lesion produces leftward slow phases and right jerk nystagmus.

The anterior semicircular canals generate upgaze, and the posterior semicircular canals generate downgaze. Therefore, a unilateral vestibular lesion that affects the anterior and posterior canals on 1 side has no net effect on vertical gaze. However, the anterior and posterior canals generate contralateral torsion. Therefore, a unilateral vestibular lesion causes tonic ipsilateral torsion, followed by a corrective torsional saccade away from the side of the lesion (Fig 10-3).

Combining the effects of decreased afferent input from all 3 semicircular canals on 1 side, a unilateral peripheral vestibular lesion generates a combined horizontal–torsional nystagmus with jerk phases directed away from the side of the lesion (see Fig 10-3). The nystagmus follows Alexander’s law, which states that the nystagmus is more pronounced when gaze is directed toward the side of the fast-beating component. Depending on the severity of the lesion, the nystagmus may be evident in primary position. Asymmetric otolithic input may result in a skew deviation or an ocular tilt reaction (see Chapter 9).

A characteristic feature of peripheral vestibular nystagmus is the ability of visual fixation to damp the nystagmus. The clinician can evaluate the effect of visual fixation on nystagmus during direct ophthalmoscopy by temporarily covering the contralateral fixating eye. Other methods for enhancing vestibular nystagmus include vigorous headshaking, hyperventilation, mastoid vibration, and the Valsalva maneuver.





**Figure 10-3** The horizontal semicircular canals (HCs) stimulate contralateral horizontal gaze (ie, stimulation of the right horizontal canal [RHC] causes left gaze, and stimulation of the left HC [LHC] causes right gaze). The anterior semicircular canals (ACs) stimulate upgaze and contralateral torsion, and the posterior semicircular canals (PCs) stimulate downgaze and contralateral torsion. Unilateral peripheral vestibular lesions cause contralateral horizontal–torsional nystagmus, as illustrated by the following example: A unilateral right peripheral vestibular lesion inhibits all of the ipsilateral canals. Innervation from the right AC (RAC) and right PC (RPC) is decreased, and the vertical components cancel each other. However, the intact left AC (LAC) and left PC (LPC) generate slow-phase torsional movements toward the patient's right. In addition, the intact LHC generates slow-phase right horizontal gaze. A fast-phase corrective, leftward torsional–horizontal saccade occurs (ie, leftward horizontal–torsional nystagmus contralateral to the right vestibular lesion).

Central nervous system lesions often have a predominant effect on either the bilateral AC pathways or the bilateral PC pathways. When the bilateral PC pathways are dysfunctional, the intact AC pathways stimulate tonic upgaze combined with a corrective downgaze saccade (downgaze nystagmus). Conversely, when bilateral AC pathways are dysfunctional, the intact PC pathways stimulate tonic downgaze combined with a corrective upgaze saccade (upgaze nystagmus). (Adapted with permission from Wong AMF. *Eye Movement Disorders*. Oxford University Press; 2008:37 and from Leigh RJ, Zee DS. *The Neurology of Eye Movements*. 3rd ed. Contemporary Neurology Series. Oxford University Press; 1999. Illustration by Wendy Hiller Gee.)

### Peripheral vestibular dysfunction

Peripheral vestibular dysfunction, often accompanied by nystagmus, usually occurs in 1 of 4 clinical patterns:

- Acute monophasic disorder secondary to a (presumed viral) vestibular neuronitis.
- Recurrent vestibular dysfunction, usually associated with auditory symptoms (eg, tinnitus and hearing loss). This disorder, exemplified by *Ménière disease*, is usually progressive, although there may be long symptom-free intervals.
- Paroxysmal dysfunction of the vestibular system that produces vertigo in response to certain head positions. This disorder, known as *benign paroxysmal positional vertigo (BPPV)*, develops because of free movement of otoconia particles (calcium carbonate crystals normally contained within the utricle and saccule), which act as foreign debris within a semicircular canal. The Dix-Hallpike maneuver, during which the patient's head is turned 45° to the right or left and lowered below the horizontal plane of an examination table to induce symptoms, can be used to determine on which side the semicircular canals are dysfunctional. Once the side is

identified, repositioning treatments such as the Epley maneuver can remove the otoconia particles from that semicircular canal and provide lasting remission, although recurrence is not unusual.

- Toxic vestibular dysfunction, primarily caused by the use of aminoglycosides (but also other medications such as chemotherapeutics). Systemic ototoxins typically produce head movement–related oscillopsia and decreased vestibular ocular reflex (VOR) gain bilaterally with little or no nystagmus (ie, bilateral vestibular hypofunction without asymmetry).

A very large cerebellopontine angle tumor (eg, vestibular schwannoma or meningioma) may produce *Bruns nystagmus*, a combination of gaze-evoked and peripheral vestibular nystagmus. Initially, because the vestibular nerve is affected, the eyes drift toward the side of the lesion, with a corrective fast phase in the opposite direction. As the lesion enlarges, the ipsilateral brainstem is compressed, causing problems in maintaining ipsilateral eccentric gaze; thus, as the patient looks to the side of the lesion, a large-amplitude, low-frequency, ipsilesional gaze-evoked nystagmus is noted, whereas in contralateral gaze (away from the side of the lesion), a small-amplitude, high-frequency, contralesional vestibular nystagmus is observed.

Baloh RW. Clinical practice. Vestibular neuritis. *N Engl J Med*. 2003;348(11):1027–1032.

Fife TD, Tusa RJ, Furman JM, et al. Assessment: vestibular testing techniques in adults and children: report of the Therapeutics and Technology Assessment Subcommittee of the American Academy of Neurology. *Neurology*. 2000;55(10):1431–1441.

## Central Vestibular Nystagmus

Because the central vestibular structures of the brainstem and the cerebellum are extensively interconnected, it can be difficult, if not impossible, to determine by clinical examination alone the precise location of lesions that produce central nystagmus, although features of some supranuclear ocular motility disorders allow lesion localization (Table 10-2). It is often more useful to think of the central vestibular pathways as a single system within the brainstem and cerebellum. When more specific information about the location of a lesion is desired, neuroimaging is often required. Central vestibular nystagmus often involves pathways governed by the anterior semicircular canals, posterior semicircular canals, or both (see Fig 10-3). Therefore, isolated vertical or torsional nystagmus is common (in contrast to

**Table 10-2 Selected Forms of Nystagmus or Oscillatory Movements and Their Most Common Lesion Locations**

Abnormal Eye Movement	Probable Location of Lesion
Downbeat nystagmus	Cervicomedullary junction or vestibulocerebellum
Upbeat nystagmus	Posterior cranial fossa (medulla oblongata most common)
Periodic alternating nystagmus	Cerebellar nodulus
See-saw nystagmus	Parasellar region/diencephalon
Ocular flutter, opsoclonus	Pons (omnipause cells), cerebellum (connections to pons)
Convergence-retraction nystagmus	Preectum (dorsal midbrain)

peripheral vestibular nystagmus, which is characterized by horizontal movements combined with torsional movements). If central vestibular nystagmus is of small amplitude and present only when the eyes are not in primary position, patients may have no visual symptoms.

There are several forms of central vestibular nystagmus:

- downbeat nystagmus
- upbeat nystagmus
- torsional nystagmus
- central vestibular instability nystagmus (periodic alternating nystagmus)

These are discussed in the following subsections.

### **Downbeat nystagmus**

Downbeat nystagmus is the most common form of central vestibular nystagmus and results from lesions that produce defective vertical gaze holding characterized by an upward drift of the eyes, which is then corrected with a downward saccade (Video 10-6). The vertical vestibular pathways are biased toward anterior canal input to the vestibular nuclei (that mediate upgaze). The vestibulocerebellum (ie, the nodulus, uvula, flocculus, and paraflocculus) balances this bias by inhibiting anterior canal projections to the vestibular nuclei. Lesions within the vestibulocerebellum unleash the anterior canal bias, resulting in a slow upgaze movement, followed by a corrective downbeat saccade (ie, downbeat nystagmus) (see Fig 10-3). Downbeat nystagmus may be present in primary position, but in accordance with Alexander's law, the downbeating movements are usually accentuated in downgaze (especially to either side). Patients usually report oscillopsia, which can be debilitating.



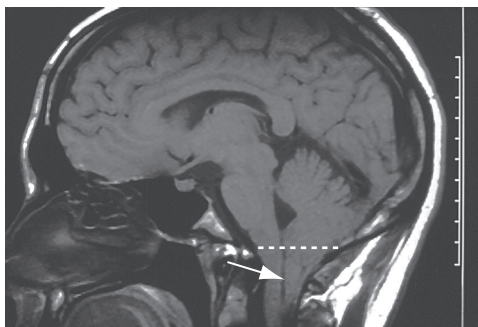
**VIDEO 10-6** Downbeat nystagmus.

*Courtesy of Janet C. Rucker, MD.*



A structural lesion may be associated with downbeat nystagmus, in which case the lesion may involve the vestibulocerebellum or the cervicomedullary junction. The most common structural lesion is a Chiari type I malformation, a developmental abnormality characterized by posterior fossa crowding and cerebellar tonsillar protrusion into the foramen magnum (Fig 10-4). Lesions at the foramen magnum are best assessed with sagittal

**Figure 10-4** Chiari type I malformation in a 26-year-old patient who reported a sense of movement of his environment. Downbeat nystagmus was identified as the explanation for his oscillopsia. This T1-weighted sagittal magnetic resonance imaging scan shows herniation of the cerebellar tonsils (*arrow*) through the foramen magnum. The level of the foramen magnum is shown by the *dashed line*.



magnetic resonance imaging (MRI). In some cases of unexplained downbeat nystagmus, antibodies to glutamic acid decarboxylase (GAD) have been identified in the blood of affected patients.

The differential diagnosis of downbeat nystagmus includes the following:

- Chiari type I malformation
- syrinx of the brainstem or upper cervical spinal cord
- platybasia
- tumors of the foramen magnum (eg, meningioma, cerebellar hemangioma)
- demyelination
- stroke
- cranial trauma
- basilar artery impression
- spinocerebellar degenerations
- brainstem encephalitis
- paraneoplastic syndrome
- GAD antibodies
- drug toxicity (eg, lithium, anticonvulsants)
- impaired nutrition (ie, thiamine deficiency resulting in Wernicke encephalopathy, magnesium deficiency, or parenteral feeding)
- idiopathic

Common off-label treatments for downbeat nystagmus and other central vestibular forms of nystagmus include clonazepam (a gamma-aminobutyric acid [GABA] receptor agonist), baclofen, gabapentin, memantine, 4-aminopyridine, and 3,4-diaminopyridine (amifampridine). Unfortunately, medical treatment often provides little to no improvement of symptoms. Dalfampridine has been used to treat downbeat nystagmus and may be more efficacious than the similar drug 3,4-diaminopyridine. Base-out prisms (used to induce convergence) can sometimes improve the oscillopsia associated with downbeat nystagmus.

### ***Upbeat nystagmus***

Upbeat nystagmus is characterized by a downward drifting of the eyes, followed by corrective, upward saccades (Video 10-7). This nystagmus can be caused by lesions in the brainstem (often medulla) or the anterior cerebellar vermis; thus, the lesions may exist at various locations within the posterior fossa. These lesions predominantly affect the CNS anterior canal vestibular pathways. The intact posterior canal pathways provide the predominant input, resulting in tonic downgaze and a corrective upgaze saccade (upgaze nystagmus) (see Fig 10-3). Common causes of lesions resulting in upbeat nystagmus include demyelination, stroke, cerebellar degeneration, and tobacco smoking.



**VIDEO 10-7** Upbeat nystagmus.  
Courtesy of Agnes M. F. Wong, MD, PhD.



### ***Torsional nystagmus***

Although peripheral vestibular nystagmus may have a torsional component, purely torsional nystagmus indicates a central lesion. Torsional nystagmus is usually associated with a medullary lesion (eg, syringobulbia, lateral medullary infarction) and may be part of an ocular tilt reaction.

### ***Periodic alternating nystagmus***

Periodic alternating nystagmus (PAN) (CEMAS term: central vestibular instability nystagmus) is a strictly horizontal nystagmus that oscillates predictably in direction, amplitude, and frequency. For instance, a rightward-beating nystagmus develops progressively larger amplitudes and higher frequencies up to a certain point, then wanes, eventually leading to a short period of downbeat or no nystagmus. Then the nystagmus reverses direction, with a crescendo–decrescendo pattern that again leads to a short period without nystagmus, completing the cycle (Video 10-8). PAN may be congenital or acquired. The acquired form has a characteristic oscillation cycle of 2–4 minutes. A cursory examination may lead to the erroneous conclusion that the nystagmus is directed toward one side only. For this reason, any presentation of nystagmus that is purely horizontal and occurs in primary position should be observed for at least 2 minutes to be certain that the condition is not PAN. A patient with PAN may also demonstrate a periodic alternating head turn (in the direction of the nystagmus) to minimize the nystagmus, in accordance with Alexander’s law. For example, during the left-beating phase of PAN, the patient’s head turns to the left to place the eyes in right gaze in order to minimize the nystagmus.



**VIDEO 10-8** Periodic alternating nystagmus.

Courtesy of Edward G. Buckley, MD.



Acquired PAN is caused by unstable “velocity storage,” typically secondary to cerebellar disease. The vestibular-ocular system’s response to sustained head rotation attenuates fairly quickly as the cilia on the hair cells within the semicircular canals resume their normal position (see Chapter 9). However, a velocity storage mechanism prolongs the vestibular-ocular response for several seconds during sustained head movements. This mechanism is generated by interconnections within the vestibular nuclei (the vestibular commissure) and is stabilized by cerebellar GABA-ergic innervation. Cerebellar disease may cause unstable velocity storage that results in a horizontal nystagmus with an oscillating null point, namely PAN. Common causes of PAN include Chiari type I malformation, cerebellar degeneration, multiple sclerosis (MS), cerebellar tumors, stroke, use of anticonvulsant medication, and bilateral loss of vision. If the bilateral vision loss is reversed (eg, if a vitreous hemorrhage is cleared), PAN may be abolished. Baclofen, a GABA receptor agonist, used off-label, can eliminate the acquired form of PAN.

### **HINTS Test**

Evaluation of nystagmus, head impulse testing, and assessment for skew deviation is referred to as the *HINTS* (*head impulse, nystagmus, testing for skew*) test (see Chapter 9). In a patient with dizziness, this test enables the examiner to distinguish a serious CNS

lesion (ie, stroke) from a peripheral vestibular lesion, which is often benign (ie, vestibular neuritis). In order for HINTS testing to be valid, it is essential that the patient be examined during symptomatic periods with nystagmus.

## Acquired Pendular Nystagmus

Acquired pendular nystagmus includes pendular, slow-phase eye movements in the horizontal, vertical, and torsional planes (often forming elliptical waveforms) (Video 10-9). In contrast, congenital pendular nystagmus usually manifests with only horizontal movements on clinical examination. Pendular nystagmus with both vertical and horizontal components produces oblique nystagmus (if the components are in phase) or circular or elliptical nystagmus (if the components are out of phase). The eye movements may be conjugate or disconjugate and are often dissociated.



**VIDEO 10-9** Acquired pendular nystagmus.  
Courtesy of William A. Fletcher, MD.



The localizing value of acquired pendular nystagmus is poor. It is most commonly noted in patients with MS, who may exhibit asymmetric or monocular forms. This form of nystagmus can also develop after blindness occurs secondary to optic nerve disease, including optic neuropathy due to MS. When vision is reduced in both eyes, the nystagmus is typically larger in the eye with poorer vision.

Memantine or gabapentin (each used off-label) may reduce the severity of nystagmus and improve vision in patients with acquired pendular nystagmus. Unilateral retrolbulbar injection of botulinum toxin type A reduces the amplitude of nystagmus and may improve vision for patients who are willing to view monocularly. However, total cessation of eye movements has its own consequences; for example, some patients report blurred vision when walking because of the loss of the normal VOR, which adjusts eye position as the head moves.

Shery T, Proudlock FA, Sarvananthan N, McLean RJ, Gottlob I. The effects of gabapentin and memantine in acquired and congenital nystagmus: a retrospective study. *Br J Ophthalmol*. 2006;90(7):839–843.

Thurtell MJ. Treatment of nystagmus. *Semin Neurol*. 2015;35(5):522–526.

## Oculopalatal Myoclonus or Tremor

Acquired pendular nystagmus may accompany *palatal myoclonus*, an acquired oscillation of the palate. The eye movements are continuous and rhythmic, occur at a frequency of approximately 1 Hz, are typically conjugate in the vertical plane, and persist during sleep (Video 10-10). This eye movement disorder may also be associated with synchronous movements of the facial muscles, pharynx, tongue, larynx, diaphragm, trunk, and extremities. The condition usually arises several months (up to years in rare cases) after occurrence of a lesion that involves the Guillain-Mollaret triangle—a triangular pathway connecting the red nucleus, the inferior olivary nucleus, and the contralateral cerebellar



dentate nucleus. Lesions of this pathway produce inferior olivary hypertrophy, which is visualized with MRI as a T2 hyperintensity within 1 or both inferior olives.

Common etiologies include stroke, demyelination, and trauma. Treatment consists of gabapentin, memantine, or trihexyphenidyl (all off-label uses).



#### VIDEO 10-10 Oculopalatal myoclonus.

Courtesy of Agnes M. F. Wong, MD, PhD.



Tilikete C, Desestret V. Hypertrophic olivary degeneration and palatal or oculopalatal tremor. *Front Neurol.* 2017;8:302.

## See-Saw Nystagmus

See-saw nystagmus is a form of disjunctive nystagmus in which 1 eye elevates and intorts while the other eye depresses and extorts, a movement reminiscent of that of a see-saw (Video 10-11). The eye movements are typically pendular, slow, low frequency, and similar in amplitude between the eyes. See-saw nystagmus may be congenital or acquired and may be caused by lesions that affect the chiasm, midbrain, or both. Trauma and parasellar-diencephalic tumors, in particular craniopharyngioma, are frequent causes; hydrocephalus and congenital achiasma are rare causes. There may be associated vision loss, often a bitemporal hemianopia. See-saw nystagmus may also occur in patients with vision loss due to retinitis pigmentosa, albinism, or optic nerve hypoplasia. Asymmetric vision loss may influence the amplitude of the eye movements (ie, the amplitude may be larger in the eye with poorer vision).



#### VIDEO 10-11 See-saw nystagmus.

Courtesy of Agnes M. F. Wong, MD, PhD.



## Dissociated Nystagmus With Internuclear Ophthalmoplegia

Lesions of the medial longitudinal fasciculus (MLF) produce an *internuclear ophthalmoplegia* (INO) (see Chapter 8). Isolated slowed adduction saccadic velocity of the eye ipsilateral to an MLF lesion is the primary feature required to establish a diagnosis of INO. In addition, nystagmus of the abducting eye often occurs when gaze is directed to the side opposite the lesion (Video 10-12). One explanation for this pattern of dissociated nystagmus is the development of increased neural pulsing in an attempt to overcome the adduction weakness. According to Hering's law, the increased neural signaling is also delivered to the contralateral yoke muscle, causing excessive saccadic movements in the contralateral lateral rectus muscle, resulting in a dissociated abducting nystagmus.



#### VIDEO 10-12 Bilateral internuclear ophthalmoplegia.

Used with permission from Oxford University Press, USA. From Wong AMF. *Eye Movement Disorders.* Oxford University Press; 2008.

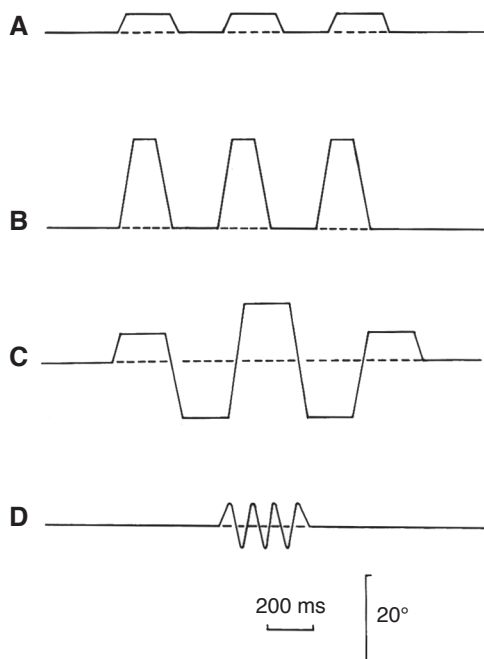


## Saccadic Intrusions

Eye movement recordings have helped identify several forms of saccadic intrusions (Fig 10-5). Two classes of saccadic intrusions are distinguished by either the presence or the absence of an intersaccadic interval—the temporal separation between sequential saccades that lasts 180–200 milliseconds.

### Saccadic Intrusions With Normal Intersaccadic Intervals

The most common saccadic intrusions are *square-wave jerks*, which have a normal intersaccadic interval (amplitude, typically  $<3^\circ$  of visual angle; latency to refixation, 200 milliseconds) and may occur normally at low frequencies (4–6 per minute) in older patients. Pathologic square-wave jerks occur at a rate greater than 15 per minute. *Macrosquare-wave jerks*, which are much less common, also include an intersaccadic interval (amplitude,  $5^\circ$ – $15^\circ$ ; latency to refixation, 70–150 milliseconds). The larger-amplitude macrosquare-wave jerks tend to have a slightly higher frequency and are always pathologic. They are observed most frequently in patients with cerebellar disease, spinocerebellar ataxia, progressive supranuclear palsy, or MS. Lesions of the cerebellum, brainstem, or their interconnecting fibers may alter the discharge of omnipause cells and burst cells in the paramedian pontine reticular formation (for horizontal saccades). The inhibition of omnipause cells and the stimulation of burst cells lower the threshold for saccadic initiation, resulting in inappropriate saccadic intrusions that drive the eyes off of fixation.



**Figure 10-5** Schematic representation of saccadic intrusions and oscillations. The baseline of each graph represents on-target fixation. **A**, Square-wave jerks: small, intrusive saccades away from and back to the target position. **B**, Macrosquare-wave jerks. **C**, Macrosaccadic oscillations: hypermetric saccades to either side of the target position. **D**, Ocular flutter: back-to-back, to-and-fro saccades without an intersaccadic interval. (Modified with permission from Leigh RJ, Zee DS. *The Neurology of Eye Movements*. 3rd ed. Contemporary Neurology Series. Oxford University Press; 1999.)

*Macrosaccadic oscillation* is another saccadic intrusion that breaks fixation. Macrosaccadic oscillations differ from square-wave jerks in that they consist of large saccades that straddle and overshoot fixation without foveation of the target. The saccades are separated by an intersaccadic interval. The oscillations occur in bursts in which the saccadic amplitude increases and then decreases; eye movement recordings show a characteristic spindle shape. Macrosaccadic oscillations occur as a result of cerebellar dysfunction (eg, tumors, MS, stroke, paraneoplastic syndromes) that alter the calibration of saccadic size, resulting in hypermetric primary and corrective saccades that oscillate around the desired eye position.

### Saccadic Intrusions Without Normal Intersaccadic Intervals

Two types of eye movement abnormalities lack the intersaccadic interval that normally occurs with sequential saccades: (1) ocular flutter; and (2) opsoclonus. *Ocular flutter* is characterized by bursts of involuntary, small-amplitude, very high-frequency (10–15 Hz), to-and-fro *horizontal* eye movements (see Fig 10-5D). *Opsoclonus* (also known as *saccadomania*) consists of involuntary, sustained, *multidirectional* eye movements with a similarly high frequency but often larger amplitude (Video 10-13). A patient may have ocular flutter and opsoclonus during the course of a disease. Both conditions can occur with other signs of cerebellar dysfunction, such as ocular dysmetria, myoclonus, and ataxia (dancing eyes and feet syndrome). Ocular flutter and opsoclonus can be diagnosed with reasonable confidence through clinical examination, although a definitive demonstration of the lack of an intersaccadic interval requires eye movement recordings. The pathophysiology is unknown but may relate to cerebellar/brainstem dysfunction that inhibits omnipause neurons (located in the paramedian pontine reticular formation) and activates burst neurons (located in the paramedian pontine reticular formation and rostral interstitial nucleus of the MLF), resulting in uncontrolled, involuntary horizontal and vertical saccadic intrusions.



**VIDEO 10-13** Opsoclonus.  
Courtesy of Agnes M. F. Wong, MD, PhD.



Etiologies of ocular flutter and opsoclonus include paraneoplastic syndromes, encephalitis, drug intoxication, MS, environmental toxins, and hyperosmolar coma. Ocular flutter and opsoclonus may also occur in some patients without explanation in the absence of associated systemic abnormalities. Opsoclonus may be a transient finding that resolves by 6 months of age in otherwise-healthy infants.

Diagnostic workup for ocular flutter and opsoclonus includes searching for a tumor and an associated paraneoplastic syndrome. In children, neuroblastoma (or another tumor of neural crest origin) is the primary consideration, whereas in adults, small-cell carcinoma of the lung or cancer of the breast or ovaries is of prime concern. Evaluation consists of a complete physical examination and may include MRI or computed tomography (CT) of the head, chest, and abdomen; a whole-body positron emission tomography (PET) scan; lumbar puncture; and a test of urine catecholamine levels (to detect elevated homovanillic acid and vanillylmandelic acid, associated with neuroblastoma). Abnormal paraneoplastic

antibodies may be found in the serum or cerebrospinal fluid (CSF) of some patients with paraneoplastic syndrome–induced ocular flutter/opsoclonus. A serologic or CSF assay for the anti–neuronal nuclear antibody type 2 (ANNA-2, or anti-Ri) can help confirm the diagnosis in cases that are secondary to cancer of the breast or ovary. In children, serologic or CSF assay for anti–neuronal nuclear antibody type 1 (ANNA-1, or anti-Hu) may help confirm the diagnosis in cases secondary to neuroblastoma. However, many patients with paraneoplastic syndromes do not have detectable anti–neuronal nuclear antibodies. Therefore, the absence of these antibodies does not exclude a paraneoplastic syndrome.

Treatment of ocular flutter and opsoclonus is directed at the underlying etiology. Regardless of etiology, immunomodulation with corticosteroids, plasmapheresis, intravenous immunoglobulin, or azathioprine may reduce the saccadic oscillations and associated oscillopsia. Other medications that may reduce symptoms include propranolol, verapamil, gabapentin, and thiamine.

Gordon LK. Paraneoplastic syndromes in neuro-ophthalmology. *J Neuroophthalmol.* 2015;35(3):306–314.

Hoyt CS, Mousel DK, Weber AA. Transient supranuclear disturbances of gaze in healthy neonates. *Am J Ophthalmol.* 1980;89(5):708–713.

### Voluntary Flutter (Voluntary “Nystagmus”)

Voluntary “nystagmus” consists of rapidly oscillating eye movements (almost always horizontal) that can be induced volitionally. These movements, which are not a form of nystagmus (because they lack slow phases), appear as high-frequency, conjugate, back-to-back saccades without an intersaccadic interval. They are associated with convergence, facial grimacing, and eyelid fluttering. Episodes are unsustained, rarely lasting longer than 30 seconds (Video 10-14). Voluntary nystagmus occurs in 8% of the normal population, may be familial, and is not associated with other neurologic findings. At times, voluntary nystagmus can be difficult to distinguish from ocular flutter. But unlike voluntary nystagmus, ocular flutter may be sustained; is typically associated with other neurological signs (such as ocular dysmetria, ataxia, and myoclonus); and does not have the convergence, facial grimacing, and eyelid fluttering of voluntary nystagmus.



**VIDEO 10-14** Voluntary nystagmus.  
Courtesy of M. Tariq Bhatti, MD.



## Additional Eye Movement Disorders

### Convergence-Retraction Nystagmus

Convergence-retraction nystagmus (CEMAS term: induced convergence-retraction) does not meet the true definition of nystagmus because it lacks slow phases. This condition results from co-contraction of the horizontal rectus extraocular muscles on attempted up-gaze. The medial rectus muscles are the most powerful of the extraocular muscles, and their contraction produces convergent movements even when all other extraocular muscles are

contracting. The co-contraction of the horizontal rectus muscles causes retraction of the globe into the orbit (see Chapter 9, Video 9-11). Convergence-retraction nystagmus localizes the disease process to the dorsal midbrain and is part of *dorsal midbrain syndrome* (see Chapter 9, Fig 9-10), which is also associated with paresis of upgaze, pupillary light–near dissociation, skew deviation, and bilateral eyelid retraction (Collier sign). Convergence-retraction nystagmus is best demonstrated by having the patient attempt an upward saccade elicited on command or by following a downward-rotating OKN drum (see Chapter 9, Video 9-12).

### Superior Oblique Myokymia

Superior oblique myokymia (SOM) is characterized by monocular, paroxysmal, high-frequency bursts of superior oblique muscle contraction. These bursts typically last for seconds, occur numerous times per day, and produce vertical and torsional eye movements. The movements are of very small amplitude and usually require magnification (obtained, for instance, with a slit lamp or 20 D lens) to observe them. Using the slit lamp to focus on a conjunctival vessel can help identify these movements (Video 10-15). The abnormal movements may occur either spontaneously or immediately after a downward eye movement or blinking. Patients may experience a combination of oscillopsia, vertical/torsional diplopia, blurry vision, and tremulous ocular sensations.



**VIDEO 10-15** Superior oblique myokymia.  
Courtesy of Paul H. Phillips, MD.



The etiology of SOM is unknown. Some clinical and neuroimaging findings suggest that this disorder may occur when the superior cerebellar or posterior cerebral artery compresses the CN IV root exit zone, similar to the neurovascular compression that occurs with hemifacial spasm and trigeminal neuralgia. In rare cases, SOM may occur before or after a CN IV palsy. Thus, CN IV compression, aberrant regeneration, and ephaptic transmission are implicated in the pathophysiology of this disorder.

Although most patients with SOM are otherwise healthy, in rare cases, SOM may be associated with MS, posterior fossa tumor, stroke, or trauma. Neuroimaging should be considered for identifying any associated conditions.

The clinical course of SOM is variable. Some patients recover spontaneously or experience only brief spells of symptoms. Other patients experience chronic oscillopsia or intermittent diplopia. Off-label treatment with  $\beta$ -blockers (topical or systemic), carbamazepine, phenytoin, baclofen, oxcarbazepine, or gabapentin may be helpful for some patients. For patients with more severe symptoms, a superior oblique tenectomy (to alleviate the oscillopsia) combined with an ipsilateral inferior oblique myectomy (to treat the iatrogenic superior oblique weakness) may help. In patients with neurovascular compression, intracranial surgery to decompress CN IV may alleviate symptoms. However, most patients choose a less invasive treatment option.

Brazis PW, Miller NR, Henderer JD, Lee AG. The natural history and results of treatment of superior oblique myokymia. *Arch Ophthalmol.* 1994;112(8):1063–1067.

Hashimoto M, Ohtsuka K, Suzuki Y, Minamida Y, Houkin K. Superior oblique myokymia caused by vascular compression. *J Neuroophthalmol*. 2004;24(3):237–239.

Zhang M, Gilbert A, Hunter DG. Superior oblique myokymia. *Surv Ophthalmol*. 2018;63(4):507–517.

### **Oculomasticatory Myorhythmia**

Vertical saccadic palsy may be an early neurologic finding in Whipple disease. In addition, pendular vergence oscillations that occur with contractions of the masticatory muscles may develop. This combination of abnormal movements is known as *oculomasticatory myorhythmia*. Patients may have only the neurologic manifestations, but more commonly, they also have unexplained fever, diarrhea, cognitive dysfunction, weight loss, and lymphadenopathy. Whipple disease can be diagnosed through duodenal biopsy (using periodic acid–Schiff [PAS] staining) to document infection with *Tropheryma whipplei* or by serologic polymerase chain reaction (PCR) testing. Although Whipple disease is progressive and potentially life-threatening, it is curable with antibiotic therapy.

Schwartz MA, Selhorst JB, Ochs AL, et al. Oculomasticatory myorhythmia: a unique movement disorder occurring in Whipple's disease. *Ann Neurol*. 1986;20(6):677–683.





# The Patient With Pupillary Abnormalities



*This chapter includes related videos. Go to [www.aaopt.org/bcscvideo\\_section05](http://www.aaopt.org/bcscvideo_section05) or scan the QR codes in the text to access this content.*

### Highlights

---

- Anisocoria is not a result of isolated loss of vision, even when such loss is unilateral.
- Topical apraclonidine is an alternative to cocaine to confirm a Horner pupil, but false-negative results can occur.
- A chronic Adie pupil can show anisocoria that is greater in dim light than in bright light, the opposite of other pupil disturbances resulting from parasympathetic denervation.
- An isolated dilated pupil is almost never the result of a cranial nerve III palsy, but it is critical to ensure that no subtle strabismus is present.

### Introduction

---

Pupillary function is an important objective clinical sign in the assessment of patients with vision loss and neurologic disease. A relative afferent pupillary defect (RAPD) localizes the site of damage to the retina, optic nerve, optic chiasm, or optic tract. However, an RAPD does not produce anisocoria. Anisocoria may result from damage to or interruption of the innervation to the iris sphincter or dilator muscle or from external pharmacologic factors, reflecting asymmetric autonomic nerve input to each iris.

Pupillary anatomy and innervation are discussed in Chapter 1, and the evaluation of an RAPD is described in Chapter 3. This chapter reviews the clinical approach to patients with efferent pupillary disorders, including irregular pupils, anisocoria, and light–near dissociation.

### History

---

Patients with pupillary disturbances, particularly anisocoria, may not be aware of any abnormality. This is especially true in individuals with dark-colored irides. Anisocoria is usually asymptomatic, but patients may report photophobia, difficulty focusing with changes

### KEY OBJECTIVES OF THE PUPILLARY EXAMINATION

- Determine whether each pupil responds to light.
- If the pupils do not respond to light and the patient can see, determine whether each pupil can respond to visualizing at near.
- Establish whether anisocoria is present, and if so, ascertain whether the difference between the 2 eyes is greater in dim or bright light.
- Determine whether there is an RAPD (see Chapter 3 for details).

in illumination or refocusing from near to far and vice versa, or blurring of vision. The clinician should inquire about any new medications (particularly patches or ointments that contain parasympathomimetic drugs), ocular infections, face or neck trauma (including chiropractic manipulation), headache or facial pain, diplopia, or change in eyelid position.

## Pupillary Examination

Examination of the patient should include an assessment of the orbit, eyelid position, and ocular motility, as well as slit-lamp examination. Examination of old photographs (eg, family portraits or social media selfies) may reveal whether the pupillary abnormality was not a new finding.

Clinical examination of the pupils requires a bright, even, handheld light source (such as a muscle light); a pupil-measuring gauge, preferably in half-millimeter increments; and an examination room in which background illumination is easily controlled. Eyedrops such as cocaine, apraclonidine, or pilocarpine may be used to help assess the pupils.

To evaluate pupil size, the clinician shines a handheld light obliquely from below the patient's nose for indirect illumination and a clear view of the pupils, in both darkness and room light. To avoid accommodative miosis, the clinician asks the patient to fixate on a distant target and takes care not to block the patient's fixation.

To check the pupillary light reflex, the examiner briefly shines a bright focal light onto each pupil in turn and notes the speed and amplitude of its constriction. Most clinicians observe only the illuminated pupil (the direct response) because it is difficult to simultaneously assess the contralateral pupil (the consensual response). The direct and consensual pupillary responses are symmetric when the efferent pupillary pathway is intact. Thus, shining a light onto a nonseeing eye results in lack of a pupillary response in both eyes, but shining a light onto the contralateral seeing eye results in both the pupil of the seeing eye and the pupil of the nonseeing eye (consensual response) constricting briskly. In other words, *poor vision in 1 eye is never a cause of anisocoria*.

If the light response is abnormal, the pupillary near response should be examined (Video 11-1). This test should be carried out in moderate room light so that the patient's pupils are midsized. The clinician directs the patient to look at an accommodative target with fine detail. Although the near response is usually triggered by blurred or disparate imagery, it has a large volitional component, and the patient may need encouragement. Sometimes a better response is obtained when auditory input, such as a ticking watch, is added to the visual stimulus or when a proprioceptive target, such as the patient's own

thumb, is used. A lack of a near response usually indicates that the patient is not trying hard enough. Light–near dissociation should be diagnosed only when the near response exceeds the best constriction that bright light can produce.



#### VIDEO 11-1 Light–near dissociation.

*Courtesy of John J. Chen, MD, PhD.*



Slit-lamp examination of the anterior segment is another essential part of the pupillary examination. Diverse ocular pathology can result in miosis, mydriasis, or poor pupillary response. Acute corneal injury or anterior chamber inflammation may explain a small pupil in the presence of ciliary spasm. When a patient has blurred vision, pain, red eye, and a dilated pupil, angle-closure glaucoma should be considered. Transillumination defects of the iris are evidence of iris damage from previous trauma, infection, or inflammation (see BCSC Section 10, *Glaucoma*). Sectoral paralysis of the iris sphincter due to an Adie pupil or aberrant regeneration of cranial nerve (CN) III is best observed by placing a wide beam at an angle to the iris and turning the light off and on while viewing one sector of the sphincter at a time under high magnification (Video 11-2). If the irides are intact, an innervational problem should be suspected.



#### VIDEO 11-2 Segmental palsy of an Adie pupil at the slit lamp.

*Courtesy of Randy H. Kardon, MD, PhD.*



## Factors Affecting Pupil Size

Baseline pupil size is influenced by several factors, including ambient light, retinal adaptation state, patient age, and arousal level. The frequency and amplitude of both pupils oscillate rhythmically and in synchrony; this phenomenon is called *hippus*. Hippus is independent of variations in illumination or in fixation of the eyes. Pupils typically become smaller as a result of aging. Somnolence results in loss of cortical input that inhibits the Edinger-Westphal nucleus, thus causing small pupils. Severely elevated intraocular pressure may result in enlargement of the pupil, possibly due to iris ischemia. Pupils are often dilated after generalized tonic-clonic seizures. Extremely small pupils suggest pontine hemorrhage, opioid intoxication, or pilocarpine use. Extremely large pupils may be normal (especially in young patients) or may suggest parasympathetic pharmacologic blockade from use of topical or systemic drugs, use of stimulants, or significant anxiety.

## Pupil Irregularity

Pupil irregularity can result from many factors that are either congenital or acquired. Congenital iris malformations such as coloboma or aniridia result in abnormal pupil shape and reactivity. Acquired conditions that damage the mechanical compliance of the iris stroma or iris musculature can result in an irregular pupil. For example, blunt trauma to the eye can cause focal tears in the sphincter muscle. An *iridodialysis* occurs when the

outer edge of the iris is torn away from its ciliary attachment. Intraocular inflammation can damage the iris or cause it to adhere to the lens or cornea (*synechiae*). Neovascularization can also distort the iris and impair pupillary reactivity. A surgical procedure in the anterior segment may affect the shape or function of the pupil (known as *Urrets-Zavalía syndrome*); cataract surgery is probably the leading cause of a misshapen pupil in an adult.

Two rare conditions of focal abnormality in iris innervation may cause pupil irregularity:

- *Tadpole pupil*. This disorder is attributed to a focal spasm of the iris dilator muscle, which produces a peaking of the pupil that lasts a few minutes. The phenomenon may occur numerous times over several days or a week and then disappear. It is idiopathic, but a small percentage of patients harbor an underlying sympathetic lesion; thus, pharmacologic testing for Horner pupil is suggested.
- *Midbrain corectopia*. In rare cases, eccentric or oval pupils are present in patients with rostral midbrain disease. The abnormality is presumably caused by incomplete damage of the pupillary fibers, leading to selective inhibition of iris sphincter tone.

Balaggan KS, Hugkustone CE, Bremner FD. Episodic segmental iris dilator muscle spasm: the tadpole-shaped pupil. *Arch Ophthalmol*. 2003;121(5):744–745.

Spierer O, Lazar M. Urrets-Zavalía syndrome (fixed and dilated pupil following penetrating keratoplasty for keratoconus) and its variants. *Surv Ophthalmol*. 2014;59(3):304–310.

## Anisocoria

Asymmetry of efferent signals to the iris muscles produces inequality in the diameters of the 2 pupils. This phenomenon, called *anisocoria*, may be physiologic or pathologic. Figure 11-1 shows an algorithm for evaluating a patient with isolated anisocoria. Specific disorders are discussed in the following sections.

### Normal Pupillary Response to Light

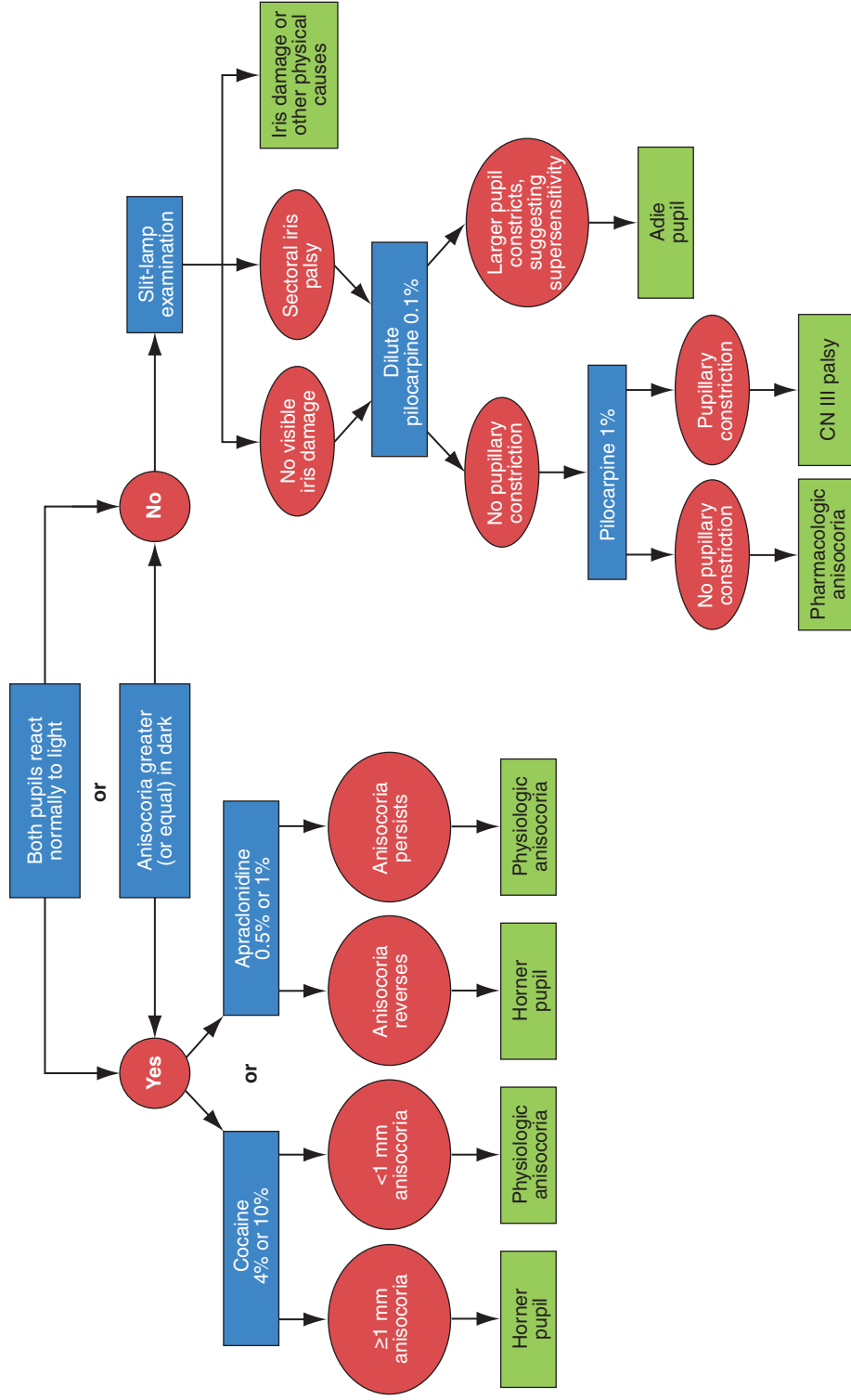
When evaluating the pupils of a patient with anisocoria, the clinician should first check the pupillary light reflex (to determine whether the response to light is normal) and then evaluate whether the anisocoria is greater in dim or bright light or is independent of illumination. If the pupils react normally to light, either there is physiologic anisocoria or the abnormality is of the sympathetic pathway. If 1 of the pupils responds abnormally to light, the next step is to examine the iris sphincter at the slit lamp to determine whether there are secondary causes to explain the anisocoria.

### Anisocoria Equal in Dim and Bright Light

#### *Physiologic anisocoria*

When the magnitude of the anisocoria is equal in dim and bright light, this indicates that the relative function of the iris sphincter and dilator muscles is intact. This scenario is consistent with physiologic anisocoria, and the patient can be reassured about the benign nature of this phenomenon.

Physiologic anisocoria (also known as *simple* or *essential anisocoria*) is the most common cause of a difference in pupil diameter. Approximately 20% of individuals have



**Figure 11-1** Flowchart for evaluation of isolated anisocoria. CN = cranial nerve. (Based on an illustration by Helen Danesh-Meyer, MD, PhD.)



noticeably asymmetric pupils. Usually the difference in pupil diameter is less than 1.0 mm and can vary from day to day.

Sometimes physiologic anisocoria is more apparent in dim light than in bright light. Ptosis occurring on the side of the smaller pupil may create diagnostic confusion with Horner syndrome. Pseudo-Horner and true Horner syndromes are best differentiated through pharmacologic testing (see the section “Pharmacologic testing” later in this chapter).

Lam BL, Thompson HS, Corbett JJ. The prevalence of simple anisocoria. *Am J Ophthalmol*. 1987;104(1):69–73.

**Anisocoria Greater in Dim Light**

Anisocoria that is greater in dim light can be caused by a range of conditions. Identifying some of the causes requires obtaining a thorough patient history (eg, pharmacologic agents); others can be identified by slit-lamp examination (Table 11-1). In general, causes of anisocoria that have a mechanical or inflammatory origin tend to produce a sluggish pupillary response to light, unlike Horner syndrome and physiologic anisocoria. Anisocoria from a chronic Adie pupil is paradoxically greater in dim light than in bright light; see the section “Idiopathic tonic (Adie) pupil” later in the chapter.

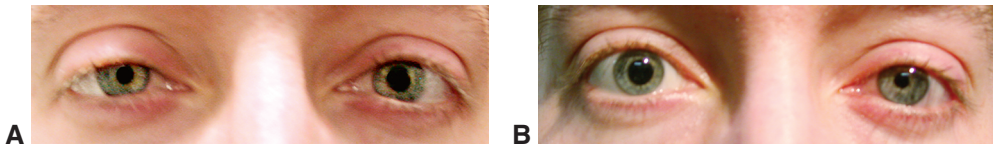
**Horner syndrome**

The presence of a lesion at any point along the oculosympathetic pathway (see Chapter 1, Fig 1-46) results in Horner syndrome, which is characterized clinically by ipsilesional miosis (from unantagonized action of the iris sphincter), facial anhidrosis, ipsilateral upper eyelid ptosis, and mild lower eyelid elevation (reverse, or upside-down, ptosis). The ptosis is due to denervation of the tarsal (Müller) muscle in both the upper and the lower eyelids, producing a noticeably narrower palpebral fissure and the false impression

**Table 11-1 Causes of Anisocoria Greater in Dim Light and Sluggish Response to Light**

Classification of Anisocoria	Examples of Causes
Pharmacologic anisocoria	Topical miotic: pilocarpine Systemic miotics: adrenergic blockers, general anesthesia, phenothiazines, opioids, cannabis Parasympathomimetics: carbachol, methacholine, organophosphate, physostigmine Sympatholytics: $\alpha_1$ -adrenergic antagonists, $\alpha_2$ -adrenergic agonists (brimonidine)
Mechanical anisocoria	Posterior synechiae Trauma or surgery Anterior segment tumors Exfoliation syndrome (atrophy of iris dilator)
Inflammatory anisocoria	Anterior uveitis
Denervation anisocoria	Long-standing Adie pupil Argyll Robertson pupil Aberrant regeneration of CN III

CN = cranial nerve.



**Figure 11-2** Apraclonidine test for Horner syndrome. **A**, A patient with suspected oculosympathetic defect (ptosis and miosis) on the right side. **B**, Following instillation of topical apraclonidine in both eyes, the right pupil has dilated and the anisocoria is now reversed, confirming Horner syndrome on the right side. Note also the resolution of eyelid ptosis, even to the point of retraction on the right side. (Courtesy of Aki Kawasaki, MD.)

of enophthalmos (Fig 11-2). In the acute phase, conjunctival hyperemia, facial flushing, and nasal congestion can also be present.

The distribution of anhidrosis depends on the location of the lesion. Interruption of the central (first-order) or preganglionic (second-order) neuron causes anhidrosis of the ipsilateral head, face, and neck. This may produce a harlequin syndrome, in which one-half of the face is pale and the other half is normal or reddish in color, with the division exactly in the midline. Interestingly, the pale side of the face is the one with the sympathetic deficit because the vessels and perspiratory glands have been denervated, leading to supersensitivity to circulating adrenaline.

Lesions at or distal to the superior cervical ganglion—that is, the postganglionic (third-order) neuron—result in anhidrosis limited to the ipsilateral forehead. When the lesion is congenital or acquired early in life, iris heterochromia develops (the affected iris appears lighter in color) but may not be detected until the age of 9–12 months (see the later section “Congenital Horner syndrome”).

One of the clinical challenges in diagnosing Horner pupil is differentiating it from physiologic anisocoria, because the pupillary reaction to light is normal with both conditions, and physiologic anisocoria may also be greater in dim light. One key difference is that pupillary dilation is intact in physiologic anisocoria, whereas there is dilation lag in Horner pupil. Pupillary dilation in dim light is the result of sphincter relaxation and dilator contraction. Hence, a normal pupil dilates briskly in dim light. When a sympathetic lesion is present, the affected pupil dilates only by sphincter relaxation. In Horner syndrome, the weakened dilator muscle causes the pupil to dilate more slowly, producing an anisocoria that is greatest at 4–5 seconds and less if remeasured at 15 seconds. The presence of dilation lag is sufficient to differentiate Horner pupil from physiologic anisocoria (Video 11-3).



#### VIDEO 11-3 Dilation lag in Horner syndrome.

Courtesy of Randy H. Kardon, MD, PhD.



**Pharmacologic testing** The oculosympathetic dysfunction of the pupil can be confirmed pharmacologically with topical eyedrops of either apraclonidine or cocaine. Topical apraclonidine (0.5% or 1%) is an  $\alpha_2$ -adrenergic agonist and a weak  $\alpha_1$ -adrenergic agonist and is used routinely as a pharmacologic diagnostic test for suspected Horner pupil because it is more accessible than cocaine. In most healthy eyes, apraclonidine has little effect on pupil size. In patients with a Horner pupil, the  $\alpha_1$ -agonist effect dominates because of the

supersensitivity of the  $\alpha_1$ -receptors (due to the paucity of norepinephrine in the synaptic cleft), resulting in relative mydriasis by contraction of the dilator muscle (see Fig 11-2). For this test, 1 drop of apraclonidine is instilled in each eye, and the patient is reassessed 60 minutes later, although a positive result often can be detected before then. Reversal of the anisocoria is considered a positive response and confirms the diagnosis of a Horner pupil. In addition to the pupillary dilation, the upper eyelid ptosis improves; however, this response is not specific to Horner syndrome eyelids.

Apraclonidine has limitations in the diagnosis of a Horner pupil. First, theoretically, only postganglionic lesions should produce denervation supersensitivity. Although apraclonidine has been shown to trigger pupillary dilation with lesions at any level of the sympathetic chain, the degree of sensitivity produced by central and preganglionic lesions is unclear. Second, denervation supersensitivity typically occurs several (2–5) days after injury to the sympathetic pathway, and apraclonidine's role in acute lesions is questionable. In addition, use of apraclonidine is generally avoided in young children because it may cause central nervous system (CNS) depression or acute respiratory arrest. Cocaine is a better choice for this age group, given its lower risk of adverse events. Brimonidine cannot be substituted for apraclonidine in testing for a Horner pupil because it is a highly selective  $\alpha_2$ -adrenergic agonist and has no significant effect on  $\alpha_1$ -receptors of the iris dilator.

### CLINICAL PEARL

Pharmacologic agents can be used to confirm a clinical suspicion of Horner pupil, Adie pupil, or pharmacologic mydriasis. However, pharmacologic pupillary testing is not infallible; false-positive and false-negative test results can occur. Therefore, test results must be interpreted on an individual basis.

Cocaine blocks the reuptake of norepinephrine released at sympathetic nerve terminals in the eye, causing pupillary dilation, eyelid retraction, and conjunctival blanching in the unaffected eye. In a Horner pupil, little or no norepinephrine is released into the synaptic cleft. Therefore, cocaine has no effect, and the miotic pupil remains smaller than the fellow pupil. The test is performed by instilling 2 drops of cocaine (4% or 10%) in each eye 5 minutes apart and measuring the degree of anisocoria after 45 minutes to 1 hour. A postcocaine anisocoria of 1 mm or greater is diagnostic of a Horner pupil on the side of the smaller pupil (see Fig 11-1). Eyes with iris synechiae and a mechanically immobile pupil can cause false-positive cocaine test results, but such findings can be readily distinguished through slit-lamp examination. In addition, after instillation of topical phenylephrine 10% (a strong, direct-acting sympathomimetic drug), a mechanically restricted pupil will remain small, but a Horner pupil will readily dilate.

Dewan MA, Harrison AR, Lee MS. False-negative apraclonidine testing in acute Horner syndrome. *Can J Ophthalmol*. 2009;44(1):109–110.

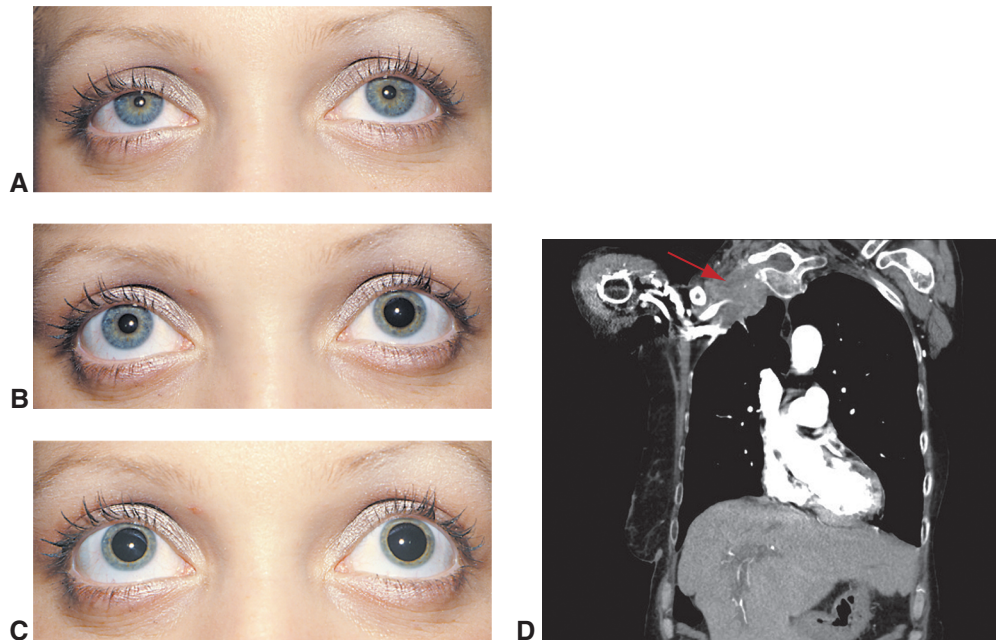
Morales J, Brown SM, Abdul-Rahim AS, Crosson CE. Ocular effects of apraclonidine in Horner syndrome. *Arch Ophthalmol*. 2000;118(7):951–954.

**Lesion localization and evaluation** Once a Horner pupil is confirmed with apraclonidine or cocaine, it is possible to pharmacologically localize the lesion with topical

hydroxyamphetamine (1%). Hydroxyamphetamine enhances the release of presynaptic norepinephrine from an intact postganglionic neuron, causing the pupil to dilate. If the miotic pupil does not dilate, a lesion of the postganglionic neuron is suspected. If both pupils dilate well, the lesion is more proximal, that is, affecting the first- or second-order neuron (Fig 11-3; see also Chapter 1, Fig 1-46). Because cocaine may interfere with the uptake and hence the efficacy of hydroxyamphetamine, 72 hours should elapse between the 2 tests.

Because commercial preparations of topical hydroxyamphetamine have been difficult to obtain and its use is associated with a high rate of false-negative results, hydroxyamphetamine for localization of Horner syndrome is rarely used in clinical practice.

In most instances, the clinical presentation is sufficient to suggest the site of injury and the necessary evaluation (Table 11-2). The presence of neurologic signs such as ataxia, nystagmus, and hemisensory deficit suggests a lesion of the medulla and is an indication for neuroimaging, preferably magnetic resonance imaging (MRI), of the brain and upper cervical cord. Signs and symptoms such as arm pain, cough, hemoptysis, and swelling in the neck suggest a second-order (preganglionic) lesion in the superior sulcus (Pancoast syndrome) or in the mediastinum, requiring cervicothoracic imaging (see Fig 11-3). Symptoms associated with third-order (postganglionic) neuron injury include numbness over the first as well as the second or third divisions of CN V and diplopia resulting from CN VI palsy, owing to the shared location of CN VI and oculosympathetic fibers in the



**Figure 11-3** Horner syndrome involving the second-order neuron. **A**, There is right-sided ptosis and miosis in bright light. **B**, The anisocoria increases in the dark. **C**, Following instillation of hydroxyamphetamine eyedrops (1%), both pupils dilate, indicating that the third-order neuron is intact. **D**, Computed tomography scan demonstrates a right apical lung mass (Pancoast tumor) (arrow). (Parts A–C courtesy of Lanning B. Kline, MD; part D courtesy of M. Tariq Bhatti, MD.)

**Table 11-2 Features Associated With Horner Syndrome, Based on Lesion Location**

Location in the Sympathetic Pathway and Etiology of Lesion	Common Symptoms or Specific Features
<b>Central (first order)</b>	
Lateral medullary syndrome (Wallenberg syndrome)	Anhidrosis of ipsilateral face Ipsilateral impairment of pain and temperature sensation over the face, contralateral pain and temperature impairment over the trunk and limbs, limb ataxia, bulbar disturbance (eg, dysarthria, dysphagia, nystagmus)
Trochlear nucleus/fascicle in brainstem	Contralateral CN IV palsy
Pontine lesion	Ipsilateral CN VI palsy
Spinal cord lesion	Quadriparesis or paraparesis, sensory deficit, bladder or bowel difficulty, hyperreflexia (Horner syndrome may be an isolated finding with cervical spondylosis, brainstem syrinx)
<b>Preganglionic (second order)</b>	
Superior sulcus of lung (Pancoast syndrome), mediastinum, C8–T1 nerve roots	Anhidrosis of ipsilateral face Cough, hemoptysis, and swelling in the neck; ipsilateral shoulder pain; pain and paresthesia along medial arm, forearm, and fourth and fifth digits
Neck lesion	Arm pain, hand weakness, history of neck surgery or trauma
Rowland-Payne syndrome (C6 nerve roots)	Paralysis of the phrenic, vagus, and recurrent laryngeal nerves
Brachial plexus injury	Ipsilateral hypochromia (mostly caused by birth trauma)
Lesion of the internal jugular vein	Central venous catheterization
<b>Postganglionic (third order)</b>	
Internal carotid artery dissection	Acute pain in temple, orbit, throat, neck, arm or behind ear; amaurosis fugax, altered sense of taste (dysgeusia), pulsatile tinnitus, diplopia, tongue or facial numbness
Cavernous sinus lesion	Ipsilateral CN VI palsy, trigeminal neuropathy
Superior cervical ganglion lesion	Anhidrosis of forehead
Trigeminal autonomic cephalgias (eg, cluster headache)	Headache, periocular pain, rhinorrhea, conjunctival tearing and hyperemia
Intraoral trauma or tumor	Ear pain, hearing loss, vertigo

CN=cranial nerve.

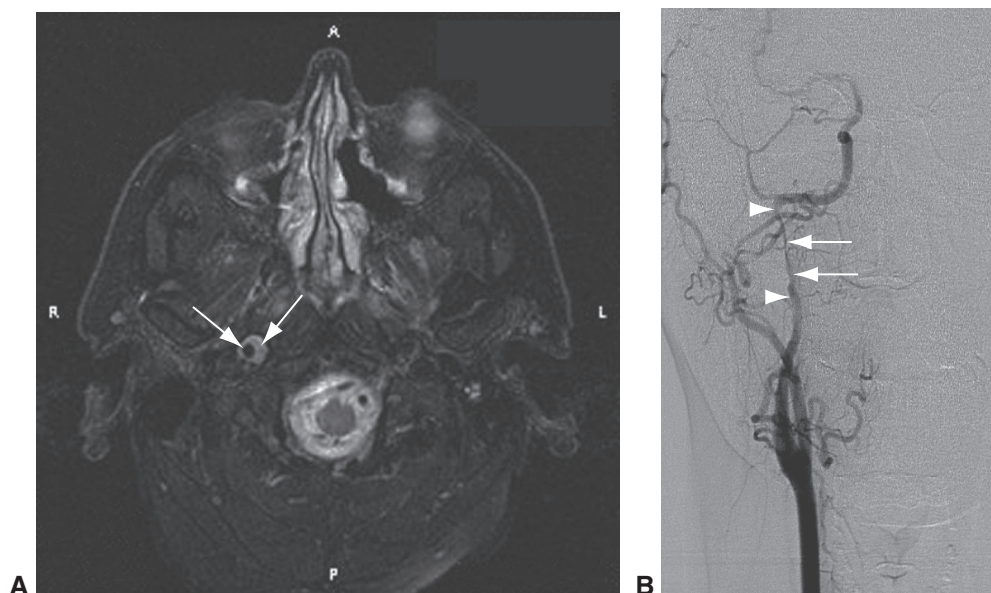
cavernous sinus. Given the extent of the postganglionic fibers, modalities for investigation include the following:

- MRI, with contrast, of the head, neck, and chest; and magnetic resonance angiography (MRA) of the neck; *or*
- computed tomography (CT) of the head, neck, and chest; and computed tomography angiography (CTA) of the neck

If examination of old photographs confirms that a Horner pupil has been present for several years, further investigation will probably be unproductive.

**Painful postganglionic Horner syndrome** Horner syndrome associated with pain deserves special attention. Painful postganglionic Horner syndrome is a distinct clinical





**Figure 11-4** Internal carotid artery dissection. **A**, Axial magnetic resonance imaging (MRI) scan shows blood (arrows) in the wall of the right internal carotid artery (“crescent moon” sign). **B**, String sign (arrows) in the catheter angiogram reflects a narrowed carotid artery compared to the normal caliber (arrowheads), confirming internal carotid artery dissection. A=anterior; L=left; P=posterior; R=right. (Part A courtesy of Karl C. Golnik, MD; part B courtesy of Lanning B. Kline, MD.)

entity associated with several causes, most importantly, an internal carotid artery dissection (Fig 11-4). Pain from dissection is usually located around the temple and orbit and may extend to the throat, neck, forehead, arm, or back of the ear. Patients with painful postganglionic Horner syndrome from dissection may also have amaurosis fugax, altered sense of taste (dysgeusia), and pulsatile tinnitus, and can develop diplopia and tongue or facial numbness. This condition must be recognized promptly because monocular vision loss and stroke are possible complications in the acute stage. MRI typically shows an intramural hemorrhage of the internal carotid artery, but in some cases, MRA, CTA, or, in rare instances, cerebral angiography is needed to detect evidence of the dissection (see Chapter 15).

Trigeminal autonomic cephalgias such as cluster headache may also cause painful Horner syndrome during an acute attack (see Chapter 13). The Horner syndrome often resolves but may become permanent after repeated attacks. Some patients, usually middle-aged men, have Horner syndrome and daily unilateral headaches that are not characteristic of cluster headache (see Chapter 13, Table 13-1). This condition, for which no underlying pathology can be identified, is called *Raeder paratrigeminal syndrome*. This syndrome is a diagnosis of exclusion made only after careful evaluation for underlying pathology in the parasellar and cavernous sinus regions. If the site of the lesion is unknown, imaging of the brain, neck, spine, carotid arteries, chest, and pulmonary apex is indicated, either by MRI and MRA or by CT and CTA.

**Congenital Horner syndrome** Congenital Horner syndrome is usually caused by birth trauma to the brachial plexus. Nontraumatic Horner syndrome in infants and children



raises the possibility of neuroblastoma arising in the sympathetic chain of the chest. In these circumstances, MRI of the head, neck, and chest is indicated. MRI of the abdomen may be considered if clinical suspicion is high. Urinalysis for elevated levels of catecholamines and their metabolites is generally less sensitive than imaging studies in detecting neuroblastoma.

Barrea C, Vigouroux T, Karam J, Milet A, Vaessen S, Misson JP. Horner syndrome in children: a clinical condition with serious underlying disease. *Neuropediatrics*. 2016;47(4):268–272.

Mahoney NR, Liu GT, Menacker SJ, Wilson MC, Hogarty MD, Maris JM. Pediatric Horner syndrome: etiologies and roles of imaging and urine studies to detect neuroblastoma and other responsible mass lesions. *Am J Ophthalmol*. 2006;142(4):651–659.

## **Anisocoria Greater in Bright Light**

### ***Iris damage***

Blunt trauma to the eye can cause either miosis or mydriasis. After injury, the pupil may be relatively miotic because of iris spasm, later becoming midsized or mydriatic, with poor responses to both light and near stimulation. Slit-lamp examination helps differentiate traumatic mydriasis from other types of mydriasis. Notches in the pupillary margin or transillumination defects near the iris sphincter muscle are evidence of sphincter damage. Mydriasis resulting from direct sphincter damage does not respond to topical pilocarpine (1% or 2%) and thus mimics pharmacologic mydriasis (see the following section). When iris injury occurs in patients with head trauma, the dilated pupil may be mistakenly identified as a sign of CN III palsy due to uncal herniation.

Prolonged or recurrent angle closure can also impair pupillary function, as can intra-ocular surgery (Urrets-Zavalía syndrome), as mentioned earlier.

### ***Pharmacologic mydriasis***

When anticholinergic medications are accidentally or intentionally instilled in the eye, the pupil becomes dilated, and its reactivity to light and near stimulation is lost and accommodation is impaired. Drug-induced dilation causes paralysis of the entire iris sphincter, in contrast to a tonic pupil, which causes segmental sphincter paralysis. Slit-lamp examination of the iris can help the clinician distinguish between complete and segmental sphincter paralysis. When mydriasis is induced by an anticholinergic drug such as atropine, instillation of full-strength pilocarpine (1% or more) will not reverse the mydriasis. In contrast, mydriasis caused by neurologic disease such as Adie pupil or CN III palsy is easily overcome with instillation of full-strength or dilute pilocarpine (see the following section). Pharmacologic mydriasis from topical dilating drops usually results in a large pupil, measuring greater than 7 mm. With adrenergic mydriasis, the pupil is large, the palpebral fissure is widened, the conjunctiva may be blanched, and accommodation is not impaired. Pilocarpine 1% will cause some constriction of a pupil that has been dilated with  $\alpha_1$ -adrenergic agonists.

### ***Idiopathic tonic (Adie) pupil***

Idiopathic tonic pupil is known as *Adie pupil*. Approximately 70% of patients are female. Adie pupils are unilateral in 80% of cases, but the second pupil may become involved later

(4% of unilateral cases per year). *Adie syndrome* (also called *Holmes-Adie syndrome*) includes other features, notably diminished deep tendon reflexes and orthostatic hypotension.

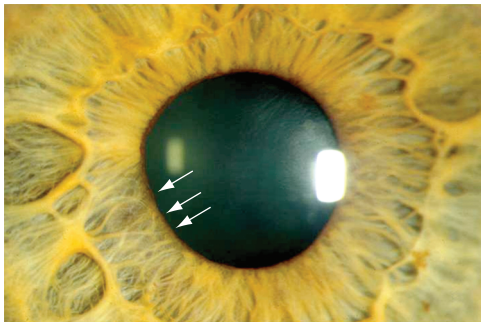
Adie pupil is characterized by a large pupil with poor reaction to light but a strong and tonic pupillary response to near vision (light–near dissociation). Slow tonic redilation of the pupil occurs when the patient switches from near to distance fixation. Other characteristics include sectoral palsy of the iris sphincter (Fig 11-5), accommodative paresis, and cholinergic denervation supersensitivity.

Damage to the ciliary ganglion or short ciliary nerves (postganglionic parasympathetic nerve injury) produces an Adie pupil. Histologic examination of the ciliary ganglion shows a reduction in the number of cells. A tonic pupil can also be caused by local ocular or orbital processes such as surgery, trauma, laser procedure, inflammation, ischemia, or infection (eg, herpes zoster, herpes simplex, syphilis, botulism). In addition to bilateral tonic pupils with mydriasis, botulism may cause bilateral ptosis and ocular motility dysfunction. Tonic pupils can also be a manifestation of widespread autonomic dysfunction consequent to diabetes mellitus, chronic alcoholism, dysautonomia syndromes, neurosyphilis, amyloidosis, sarcoidosis, the Miller Fisher variant of Guillain-Barré syndrome, or Charcot-Marie-Tooth disease.

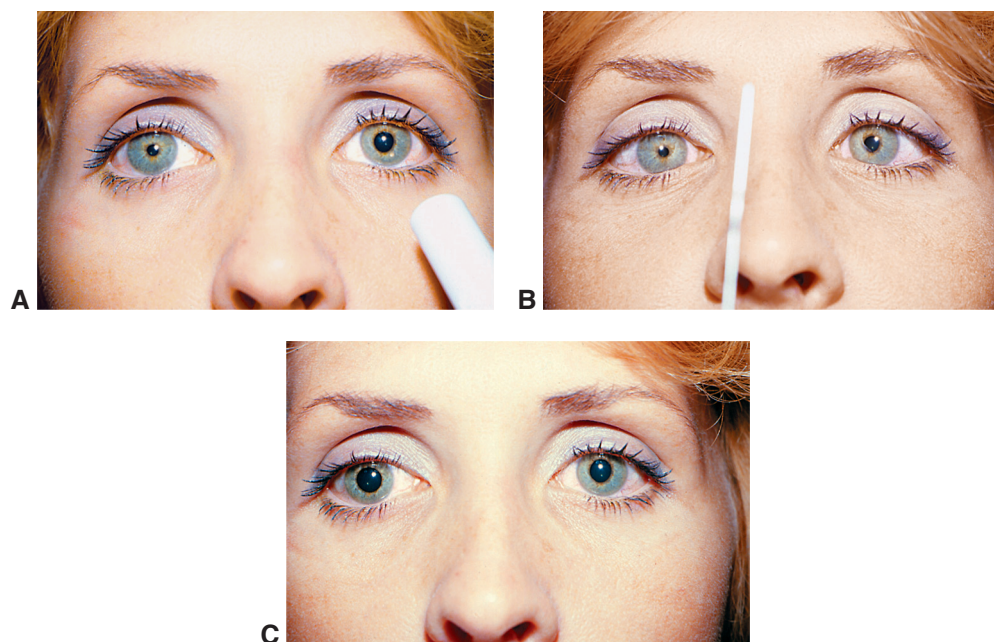
During the acute (lasting approximately 2 months) denervation phase of an Adie pupil, the pupil is dilated and poorly reactive to light stimulation and near fixation. Slit-lamp examination of the iris using high magnification can help the clinician distinguish functional from nonfunctional sphincter segments. Iris crypts stream toward areas of normal sphincter function, and the stroma bunches up along the pupillary border in such areas, producing vermiform movements. Stromal thinning—even atrophy—is observed in areas of sphincter paralysis (see Fig 11-5).

As the damaged short ciliary nerves regenerate, aberrantly guided accommodative fibers sprout onto the iris sphincter, and the pupil recovers its ability to constrict in response to near fixation. However, pupillary movements (both constriction in response to an accommodative stimulus and subsequent redilation) are delayed and slow (ie, tonic; Fig 11-6). This effect may account for patient reports of difficulty refocusing when switching from near to distance vision. The pupillary response to light typically remains severely impaired.

Pharmacologic testing can be used to confirm the diagnosis of Adie pupil. The denervated iris sphincter is supersensitive to weak parasympathomimetic solutions, such as



**Figure 11-5** Sectoral palsy of the iris sphincter in Adie pupil. The pupil is not round. The sphincter contraction is strongest along its superior sector, seen as a puckering or “bunching up” of the iris stroma. The sphincter is paralyzed between the 7 o’clock and 9 o’clock sectors (arrows); the adjacent area of iris stroma appears thinned and flattened. (Courtesy of Rod Foroozan, MD.)



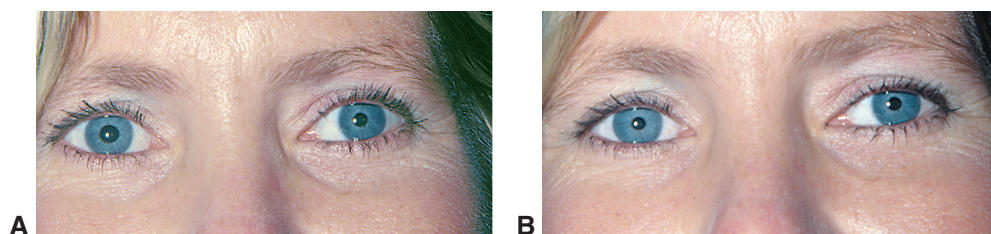
**Figure 11-6** Left Adie pupil. **A**, The left pupil reacts poorly to direct light stimulus, whereas the right pupil demonstrates a strong consensual response. **B**, Both pupils constrict upon fixation on a near target. The response of the left pupil to near effort is better than its response to light (light–near dissociation). **C**, After refixating on a distant target, the right pupil quickly redilates. The left pupil is slow to redilate (it is smaller than the right pupil), a sign of tonicity. (Courtesy of Lanning B. Kline, MD.)

dilute pilocarpine eyedrops (0.1%). This pilocarpine strength can be obtained by diluting commercial 1% solution with balanced salt solution, artificial tears, or sterile saline. The pupils are reexamined 60 minutes after eyedrop instillation. If parasympathetic denervation is present, the affected pupil will have constricted more than the unaffected pupil (Fig 11-7). Approximately 80% of patients with an Adie pupil demonstrate cholinergic supersensitivity, which develops within 5–7 days of denervation.

Patients with Adie pupils may have accommodative paresis symptoms or photophobia, or they may be asymptomatic. The accommodative symptoms are difficult to treat but usually resolve spontaneously within a few months after onset. When photophobia is a problem, topical dilute pilocarpine (0.1%) may be helpful. With time (months to years), an Adie pupil decreases in size but remains poorly reactive to light and tonically miotic in dim conditions, resulting in anisocoria that is greater in the dark than in the light.

### ***Third cranial nerve palsy***

Pupillary involvement in CN III palsy is almost always accompanied by ptosis and limited ocular motility (see Chapter 8). At times, the motility disturbance is subtle, requiring quantitation with prism and alternate cover or Maddox rod testing. Pupillary dysfunction is an important factor in the evaluation of acute CN III palsy. When the pupil is involved, an aneurysm must be excluded (see Chapter 2, Fig 2-15).



**Figure 11-7** Right Adie pupil and its response to pharmacologic testing. **A**, Right Adie pupil at baseline in ambient light. **B**, After instillation of dilute pilocarpine (0.1%), the right pupil becomes miotic, demonstrating supersensitivity. (Courtesy of Lanning B. Kline, MD.)

Aberrant regeneration of CN III axons may cause a synkinetic pupillary reaction. Portions of the iris sphincter contract with attempted movement of the eye, especially medially. Aberrant regeneration can also cause light–near dissociation (discussed in the next section).

## Disorders of Pupillary Reactivity: Light–Near Dissociation

As mentioned previously, light–near dissociation is an abnormality in which the near response exceeds the greatest pupillary constriction that bright light can produce. The physiologic basis for this abnormality is that the near reflex descends from higher cortical centers directly to the Edinger–Westphal nuclei, bypassing the pretectal nuclei in the dorsal midbrain that receive retinal ganglion cell input from the eye. Light–near dissociation may arise from a variety of causes (Table 11-3).

### Afferent Visual Pathway

Optic neuropathy is the most common cause of light–near dissociation (unilateral or bilateral). The reduction in the pupillary light reflex results from loss of retinal ganglion cell input to the pretectal nuclei; the near reflex is unaffected because it bypasses the pretectal nuclei.

### Midbrain

Dorsal midbrain damage can result in midsized pupils with poor light responses but preserved near responses. This occurs when the lesion spares the more ventrally located fibers of the near reflex pathway. Associated findings include bilateral eyelid retraction in primary position (Collier sign), vertical gaze palsy, accommodative paresis, and convergence–retraction nystagmus (dorsal midbrain syndrome [Parinaud syndrome]; see Chapter 9, Fig 9-10 and Video 9-11).

*Argyll Robertson pupils* occur in patients with tertiary syphilis involving the CNS. Affected patients have small pupils (<2 mm in diameter), which are often irregularly shaped. The pupils do not react to light, but the near response and subsequent redilation are normal and brisk. These characteristics distinguish Argyll Robertson pupils from bilateral chronic tonic pupils (which may also result from neurosyphilis). In addition, iris atrophy frequently occurs, portions of the iris transilluminate, and dilation is poor after instillation

**Table 11-3 Causes of Light–Near Pupil Dissociation**

Cause	Location	Mechanism
Severe loss of afferent light input to both eyes	Anterior visual pathway (ie, retina, optic nerves, chiasm)	Damage to or degeneration of the retina or optic nerve pathways
Panretinal photocoagulation, retinal cryotherapy, orbital surgery	Short posterior ciliary nerves	Aberrant regeneration of accommodation neurons
Peripheral neuropathy	Short posterior ciliary nerves	Disproportionate loss of axons to iris sphincter
Adie pupil	Ciliary ganglion or short ciliary nerves	Aberrant regeneration of iris sphincter by accommodation neurons
Aberrant regeneration of CN III	CN III	Aberrant regeneration of axons to the iris sphincter by accommodative or extraocular muscle neurons
Loss of pretectal light input to Edinger-Westphal nucleus	Midbrain tectum	Infection (eg, Argyll Robertson pupils secondary to syphilis), compression (eg, pinealoma), ischemia (eg, stroke)

CN = cranial nerve.

of mydriatic eyedrops. Serologic tests for syphilis should be considered in the evaluation of patients with bilateral pupillary light–near dissociation with miosis.

Argyll Robertson–like pupils are observed in widespread autonomic dysfunction such as bilateral tonic pupils (chronic), diabetes mellitus, and chronic alcoholism, as well as in encephalitis and after panretinal photocoagulation.

### Aberrant Regeneration of Cranial Nerve III

Light–near dissociation can result from aberrant regeneration of damaged nerves that restores the near reflex but not the light reflex. Misdirected regeneration can occur after traumatic injury or chronic compression of CN III. Sometimes aberrant regeneration involves the medial rectus fibers, and pupillary contraction occurs during attempted adduction. This synkinetic pupil movement can resemble light–near dissociation.

## Other Pupillary Disorders

### Benign Episodic Unilateral Mydriasis

Also known as *springing pupil*, benign episodic unilateral mydriasis typically occurs in young, healthy individuals who have a history of headache. Episodic mydriasis may last from minutes to hours and may be accompanied by mild blurring of vision, periocular discomfort, and headache. Each episode is self-limited, and the condition has not been associated with any systemic or neurologic disease beyond migraine.

Jacobson DM. Benign episodic unilateral mydriasis: clinical characteristics. *Ophthalmology*. 1995;102(11):1623–1627.

# The Patient With Eyelid or Facial Abnormalities



*This chapter includes related videos. Go to [www.aao.org/bcscvideo\\_section05](http://www.aao.org/bcscvideo_section05) or scan the QR codes in the text to access this content.*

### Highlights

---

- Localization of eyelid abnormalities and facial movement disorders allows a prioritized differential diagnosis and a focused workup.
- Eyelid abnormalities that are nonneurologic in etiology do not require extensive diagnostic testing.
- Aponeurotic defects are the most common cause of acquired ptosis (also called *blepharoptosis*).
- Facial nerve dysfunction can affect the visual system; thus, it is important that ophthalmologists accurately diagnose and help manage facial nerve palsies, particularly in order to protect the cornea from exposure.
- Facial weakness with intact frontalis muscle action suggests a central (or upper motor neuron) palsy, whereas impaired frontalis muscle contraction suggests a peripheral (or lower motor neuron) cause.
- Hemifacial spasm is investigated with magnetic resonance imaging of the brainstem, often accompanied by magnetic resonance angiography, to exclude a lesion compressing the facial nerve.

### Introduction

---

Eyelid abnormalities and facial movement disorders are frequently encountered in ophthalmology. Many of these conditions are neurologic in origin and therefore require careful evaluation. However, eyelid abnormalities can also be nonneurologic in etiology; such conditions do not require an extensive workup. A thorough history of the presenting complaint is essential, as is documentation of concomitant medical conditions. Although most patients are aware of an abnormality in the position or function of the eyelid, some may present with a chief concern of visual difficulties (eg, vision loss from ptosis) or pain (eg, exposure keratopathy from facial palsy). Occasionally, patients attribute the problem to



the wrong eye, for example mistaking ptosis for contralateral eyelid retraction, or widening of the palpebral fissure for contralateral ptosis. The clinician should ask about the onset and duration of the symptoms, as well as associated symptoms. In addition, the clinician should perform a careful evaluation of eyelid function and facial movements and a thorough ophthalmic examination.

As with other neuro-ophthalmic conditions, accurate anatomical localization provides clues to diagnosis, workup, and management. For eyelid and facial disorders, it is often helpful to determine the level of the neuromuscular system that is involved:

- supranuclear (eg, stroke, tumor)
- brainstem (eg, stroke, demyelination, tumor)
- ocular motor nerve (eg, microvascular condition, compression, infiltration)
- neuromuscular junction (eg, myasthenia gravis, botulism)
- extraocular muscle (eg, ocular myopathies, myositis)

Key clinical features include the presence of ocular motility issues, pupillary abnormalities, and other neurologic deficits (particularly dysfunction of cranial nerves [CNs] V and VII). Diagnosis and management of eyelid disorders (especially levator dehiscence and other nonneurogenic causes of ptosis) are discussed at greater length in BCSC Section 7, *Oculofacial Plastic and Orbital Surgery*.

## Examination Techniques

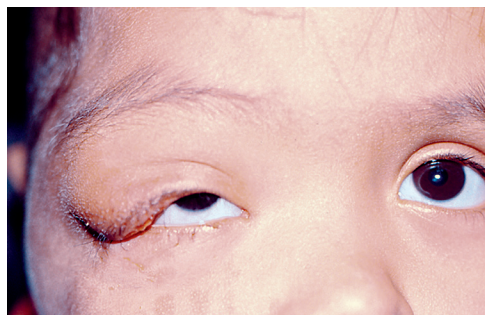
---

An examination of the eyelids begins with observing their general shape and appearance (eg, an S-shaped margin may indicate pathology affecting the lacrimal gland or neurofibromatosis [Fig 12-1; see also Chapter 15]) and blink rate (eg, low in Parkinson disease and high in blepharospasm), and with noting abnormal movements (eg, ocular-facial synkinesis). If the ptosis is unilateral, it may be an artifact of vertical strabismus (eg, hypotropia; Fig 12-2) or contralateral eyelid retraction. The eyelids should be everted for examination to rule out a local cause of ptosis, such as retained contact lens or giant papillary conjunctivitis. If the ptosis is asymmetric, the clinician can manually raise the ptotic eyelid to see whether the higher eyelid drops to a new position (Fig 12-3). This may reveal bilateral ptosis that is masked by increased innervation, as can occur with myasthenia gravis (MG).

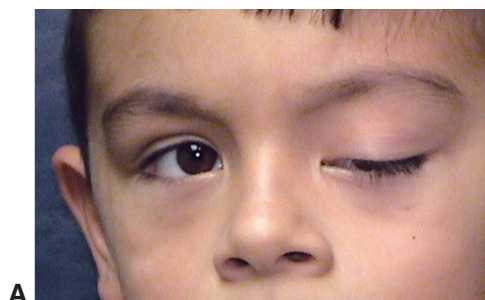
When evaluating a patient with ptosis, the clinician should obtain the following 5 important clinical measurements:

- levator palpebrae superioris muscle function
- margin-reflex distance
- vertical palpebral fissure height
- upper eyelid crease position
- lagophthalmos amount (if present)

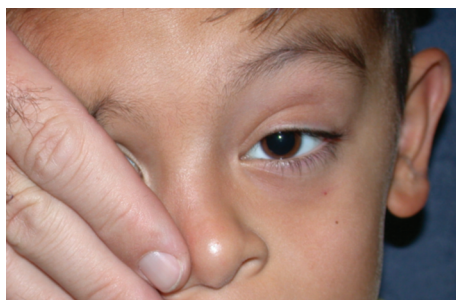Descriptions of these measurements are provided in Chapter 12 of BCSC Section 7, *Oculofacial Plastic and Orbital Surgery*.



**Figure 12-1** Mechanical ptosis. An S-shaped eyelid margin, which is typical of plexiform neurofibroma, is evident in this patient with neurofibromatosis. (Courtesy of Steven A. Newman, MD.)

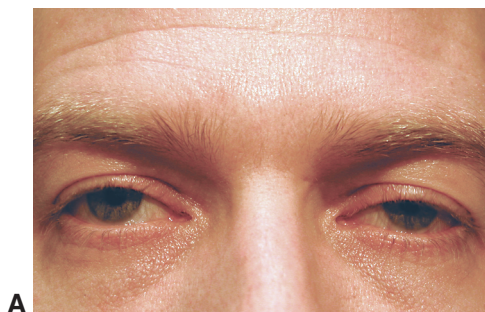

**A**

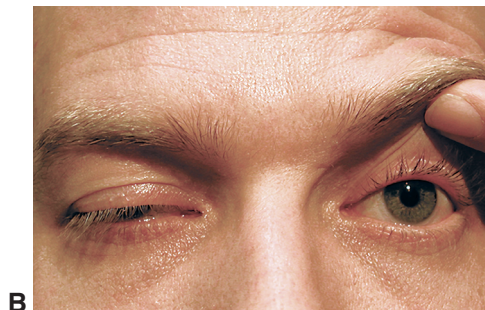

**B**

**Figure 12-2** Pseudoptosis. **A**, Patient with pseudoptosis from a large left hypotropia. **B**, Occlusion of the right eye revealed a markedly improved upper eyelid position. (Courtesy of M. Tariq Bhatti, MD.)



**A**



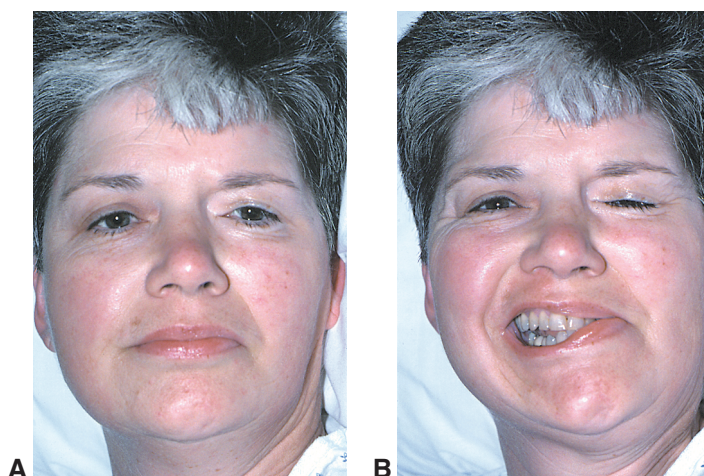**B**

**Figure 12-3** Myasthenia gravis ptosis. **A**, Ptosis that is greater on the left side than on the right. **B**, Manual lifting of the left eyelid results in greater right-sided ptosis (enhanced ptosis). This sign, although often present with myasthenia gravis, is not specific. It can occur with other disorders producing asymmetric ptosis and is a manifestation of Hering's law of equal innervation. (Courtesy of Rod Foroozan, MD.)

In addition, eyelid movement during target pursuit from upgaze to downgaze should be observed. Normally, such movement is smoothly accomplished, but lid lag may occur in patients with thyroid eye disease or as a result of aberrant regeneration of CN III (see Chapter 8, Fig 8-9).

To aid diagnoses of cases of suspected fatigable ptosis caused by MG, the patient can be asked to fixate on the clinician's hand (or a finger), which is elevated to provoke extreme upgaze. The clinician watches for progressive ptosis as the patient attempts to hold this position. A patient without MG can maintain the position without development of ptosis. However, the sensitivity and specificity of this test is unknown, and patients with myasthenia do not always exhibit fatigability. The Cogan lid-twitch sign, a feature of MG, can be identified by having the patient fixate in downgaze for a few seconds and then rapidly refixate straight ahead. The sign appears as an upward overshoot of the eyelid followed by fluttering as the eyelid settles into position. Videos of lid twitch and lid-twitch sign are available at the Neuro-Ophthalmology Virtual Education Library (NOVEL) website (<https://novel.utah.edu>).

Evaluation of facial motor function includes assessing the strength of the orbicularis oculi and other facial muscles. Eyelid closure should be assessed to determine whether it is incomplete (lagophthalmos). Reinnervation phenomena, such as ocular-facial synkinesis (eye closure and facial tic) may be signs of a previous injury to CN VII (Fig 12-4). Exophthalmos (eg, thyroid eye disease) or enophthalmos may also be present. Enophthalmos may result in apparent ptosis and narrowing of the palpebral fissure because the eyelid follows the contour of the globe as the eye retracts into the orbit. Anisocoria (see Chapter 11) may suggest sympathetic nervous system disruption, which will alter eyelid position. Dysfunction of CN III with parasympathetic nervous system involvement may also manifest as ptosis



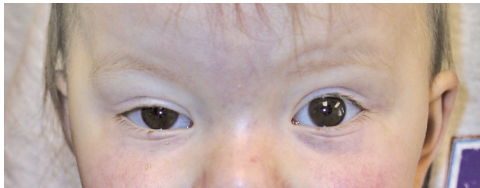**Figure 12-4** Facial nerve synkinesis (ie, aberrant regeneration) after resection of a cerebellopontine angle meningioma. Misdirection may occur with recovery of cranial nerve (CN) VII function. **A**, In the resting state, there is mild asymmetry between the 2 sides of the face. **B**, Note the eye closure when the patient attempted to smile, associated with poor movement of the left side of the face. (Courtesy of Steven A. Newman, MD.)

and anisocoria, as well as an ocular motility deficit. Finally, assessment of “neighboring” CNs is important. If ptosis is caused by CN III weakness, the function of CNs IV, V, and VI should also be evaluated. Ocular motility should be checked for subtle weakness. Similarly, if CN VII dysfunction is noted, facial sensation and hearing need to be evaluated.

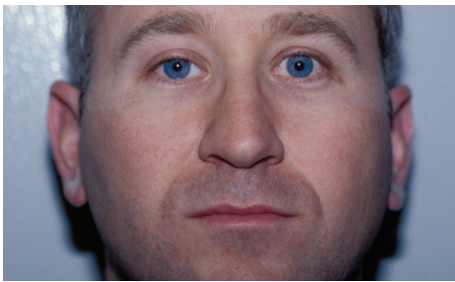## Ptosis

### Congenital Ptosis

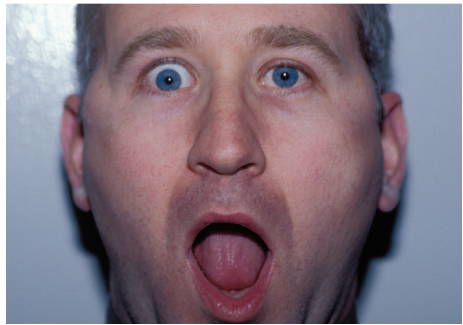
The most common form of congenital ptosis is thought to result from dystrophic development of the levator palpebrae superioris muscle without associated innervational abnormalities. Congenital ptosis is typically associated with decreased levator function, lid lag on downgaze, and poorly formed (or absent) upper eyelid crease. Congenital ptosis (Fig 12-5) can be unilateral or bilateral and may be associated with other congenital ocular or orbital abnormalities, including blepharophimosis syndrome, congenital fibrosis of the extraocular muscles, superior rectus weakness or overaction, and Marcus Gunn jaw-winking syndrome (Fig 12-6). In Marcus Gunn jaw-winking there is unilateral trigeminal–oculomotor nerve synkinesis so that unintentional eyelid movement accompanies volitional jaw movement. In the external pterygoid–levator form of the syndrome, the eyelid elevates with movement of the mandible to the opposite side, protrusion of the jaw, or wide opening of the mouth. With the internal pterygoid–levator form, the eyelid elevates when the teeth are clenched. In some patients with Marcus Gunn jaw-winking syndrome, ptosis may worsen with movement of the jaw, although this finding is not common.



**Figure 12-5** Congenital ptosis, right upper eyelid, in a 2-year-old child. (Courtesy of Rod Foroozan, MD.)



**A**



**B**

**Figure 12-6** Marcus Gunn jaw-winking syndrome (ie, CN V and CN III synkinesis). **A**, Mild right upper eyelid ptosis. **B**, Opening the mouth results in eyelid retraction. (Reproduced with permission from Levin LA, Arnold AC, eds. *Neuro-Ophthalmology: The Practical Guide*. Thieme; 2005.)



Congenital tumors, such as hemangiomas and neurofibromas of the eyelid (see Fig 12-1), may also lead to ptosis. Such tumors are typically associated with a palpable mass. Congenital CN III palsy and congenital Horner syndrome are relatively rare causes of neurogenic ptosis that is present at birth. Whatever the origin of a child's ptosis, the ophthalmologist must be aware of the potential for amblyopia as a result of occlusion or anisometropia.

Acquired Ptosis

Acquired ptosis is commonly classified as follows:

- aponeurotic
- neurogenic
- myogenic
- neuromuscular
- mechanical
- traumatic

Table 12-1 lists the most common causes of acquired ptosis.

Aponeurotic

*Levator aponeurotic defects* are the most frequent cause of acquired ptosis, supplanting the belief that acquired ptosis is the result of aging (“senile” ptosis). This type of ptosis is caused by stretching, dehiscence, or disinsertion of the levator aponeurosis. Aponeurotic ptosis can result from frequent eye rubbing or prolonged contact lens use, particularly rigid lenses. It can also be caused or exacerbated by intraocular surgery, perhaps resulting from use of an eyelid speculum. Because the levator muscle itself is healthy, levator function is usually normal. Patients with aponeurotic defects typically have a higher than normal or absent upper eyelid crease. See BCSC Section 7, *Oculofacial Plastic and Orbital Surgery*, for additional discussion.

Table 12-1 Common Causes of Acquired Ptosis

<b>Aponeurotic</b> Attenuation Dehiscence Disinsertion Stretching	<b>Neurogenic</b> Apraxia of eyelid opening CN III palsy Horner syndrome Miller Fisher syndrome Recurrent painful ophthalmoplegic neuropathy (formerly, ophthalmoplegic migraine)
<b>Mechanical</b> Chalazion Cicatricial	<b>Neuromuscular</b> Botulism or botulinum toxin Myasthenia gravis
<b>Myogenic</b> Chronic progressive external ophthalmoplegia Long-term use of steroid eyedrops Myotonic dystrophy Oculopharyngeal dystrophy	<b>Traumatic</b> Eyelid laceration Foreign body Postsurgical ptosis

CN=cranial nerve.

### **Neurogenic**

*Neurogenic ptosis* requires careful attention to associated abnormalities in pupil size and extraocular movements. The most common causes of neurogenic ptosis are dysfunction of CN III and Horner syndrome. However, isolated unilateral ptosis is rarely, if ever, a manifestation of third nerve palsy.

Bilateral ptosis may be the only manifestation of a nuclear CN III palsy (see Chapter 8), but this is rare, as usually there are accompanying features. Areflexia, ataxia, and ophthalmoplegia characterize the *Miller Fisher syndrome*, a variant of Guillain-Barré syndrome (discussed later in this chapter). In addition to bilateral ptosis, patients with Miller Fisher syndrome may have facial diplegia, as well as respiratory and swallowing difficulties.

*Cerebral ptosis*, a rare form of neurogenic ptosis, occurs in association with a lesion of the cerebral (typically right) hemisphere. The ptosis may be bilateral or unilateral, and in most cases, it is transient, lasting up to several months.

### **Myogenic**

*Myogenic ptosis* is usually bilateral, progressive, and associated with impaired eye movements. The pupil is always normal in terms of function and shape. The patient may not experience diplopia if the eyes are straight in primary position or if there is symmetric or complete ophthalmoplegia. Chronic progressive external ophthalmoplegia is the classic cause of myogenic ptosis. Systemic disorders that can cause this ptosis include *oculopharyngeal dystrophy* and *myotonic dystrophy* (discussed in Chapter 15). Long-term use of steroid eyedrops is thought to lead to ptosis as a localized steroid-induced myopathy of the levator muscle. Posterior sub-Tenon steroid injections have also been associated with ptosis. The levator palpebrae superioris muscle, aponeurosis, or the insertion site of the aponeurosis may be adversely affected by such injections.

### **Neuromuscular**

*Myasthenia gravis* is an autoimmune disease in which immune-mediated damage to the acetylcholine receptor results in abnormal neuromuscular transmission. MG is the most common cause of ptosis resulting from neuromuscular transmission disorder. It can mimic any cause of ptosis and can be unilateral or bilateral. The ptosis can be isolated or associated with ocular motor paresis. The pupils are always normal. Diagnosis of myogenic ptosis or MG requires questions regarding the patient's general strength, fatigability, dysphagia, and family history. See Chapter 15 for detailed discussion of MG.

*Botulism* leads to bilateral ptosis associated with poorly reactive pupils and ophthalmoplegia. Affected patients also have associated facial paralysis and generalized proximal muscle weakness.

### **Traumatic and mechanical**

*Traumatic* and *mechanical* causes of acquired ptosis are generally evident from inspection of the eyelids and require appropriate medical or surgical therapy.

### **Pseudoptosis**

In pseudoptosis, the eyelid appears to droop. Several conditions can cause the eyelid to appear abnormally low, including brow ptosis and laxity and dermatochalasis. Conditions



that result in the eyelids being inadequately supported by the globe also lead to pseudoptosis. Because the perception of eyelid position is related to the position of the eye (see Fig 12-2), hypotropia can cause pseudoptosis. Contralateral eyelid retraction can also give the appearance of ptosis.

### Apraxia of Eyelid Opening

Apraxia of eyelid opening is a rare, transient nonparalytic inability to open the eyes at will in the absence of visible contraction of the orbicularis oculi muscle. Patients often can open their eyes after touching the orbital rim or after sudden command. The main clinical features are frontalis muscle contraction (with elevation of the eyebrows) during attempts to open the eyes and absence of any other signs of neural or myopathic dysfunction. The disorder can mimic unilateral or bilateral ptosis (Video 12-1). The apraxia is thought to be supranuclear in origin, and most patients have extrapyramidal disease such as Parkinson disease, multiple system atrophy, Huntington disease, Wilson disease (also called hepatolenticular degeneration), or progressive supranuclear palsy. Apraxia of eyelid opening may also occur in patients with benign essential blepharospasm (discussed later in the chapter).



**VIDEO 12-1** Apraxia of eyelid opening.

Courtesy of M. Tariq Bhatti, MD. Narration by Adam Rasky, MD.



## Eyelid Retraction

Eyelid retraction is present if the sclera is visible above the superior corneal limbus when the eyes are in primary position. It is usually acquired but may be present at birth. Preterm infants occasionally have a benign, transient conjugate downgaze associated with upper eyelid retraction (ie, setting sun sign). In many healthy infants (80% of children 14–18 weeks of age), bilateral eyelid retraction (eye-popping reflex) occurs when ambient lighting levels are reduced.

Table 12-2 lists the causes of acquired eyelid retraction. In adults, the most common cause of eyelid retraction, whether unilateral or bilateral, is thyroid eye disease (Fig 12-7). *Dorsal midbrain syndrome* (see Chapter 9, Fig 9-10) is a less common cause of eyelid retraction (*Collier sign*) in adults than TED. The appearance of unilateral eyelid retraction can occur because of contralateral ptosis (pseudo-eyelid retraction); this phenomenon results from Hering's law of equal innervation. Unilateral eyelid retraction can also occur from aberrant regeneration of CN III (see Chapter 8), Marcus Gunn jaw-winking syndrome (see Fig 12-6), idiopathic levator palpebrae superioris fibrosis, carcinomatous infiltration, or iatrogenic causes (eg, strabismus surgery on the vertical rectus muscles or ptosis repair). Bilateral eyelid retraction can be associated with thyroid eye disease, familial periodic paralysis, Cushing syndrome, and midbrain disease, or hydrocephalus with vertical nystagmus. Several surgical procedures have been used to reduce the degree of eyelid retraction in patients with thyroid eye disease. See BCSC Section 7, *Oculofacial Plastic and Orbital Surgery*, for a review of eyelid retraction treatment methods.

**Table 12-2 Causes of Acquired Eyelid Retraction****Mechanical**

Buphthalmos  
 High axial myopia  
 Orbital fracture with entrapment  
 Proptosis secondary to orbital mass

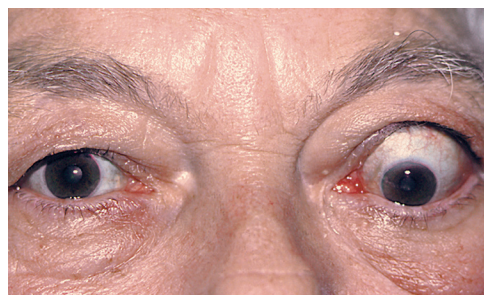
**Myogenic**

Carcinomatous infiltration  
 Idiopathic levator palpebrae superioris muscle fibrosis  
 Iatrogenic (ptosis repair, orbicularis myectomy, strabismus surgery on vertical rectus muscle)  
 Thyroid eye disease

**Neurogenic**

Aberrant regeneration of CN III  
 Dorsal midbrain syndrome  
 Long-term use of sympathomimetic eyedrops (eg, phenylephrine, apraclonidine)  
 Marcus Gunn jaw-winking syndrome  
 Progressive supranuclear palsy

**Pseudo-eyelid retraction** (secondary to contralateral ptosis)

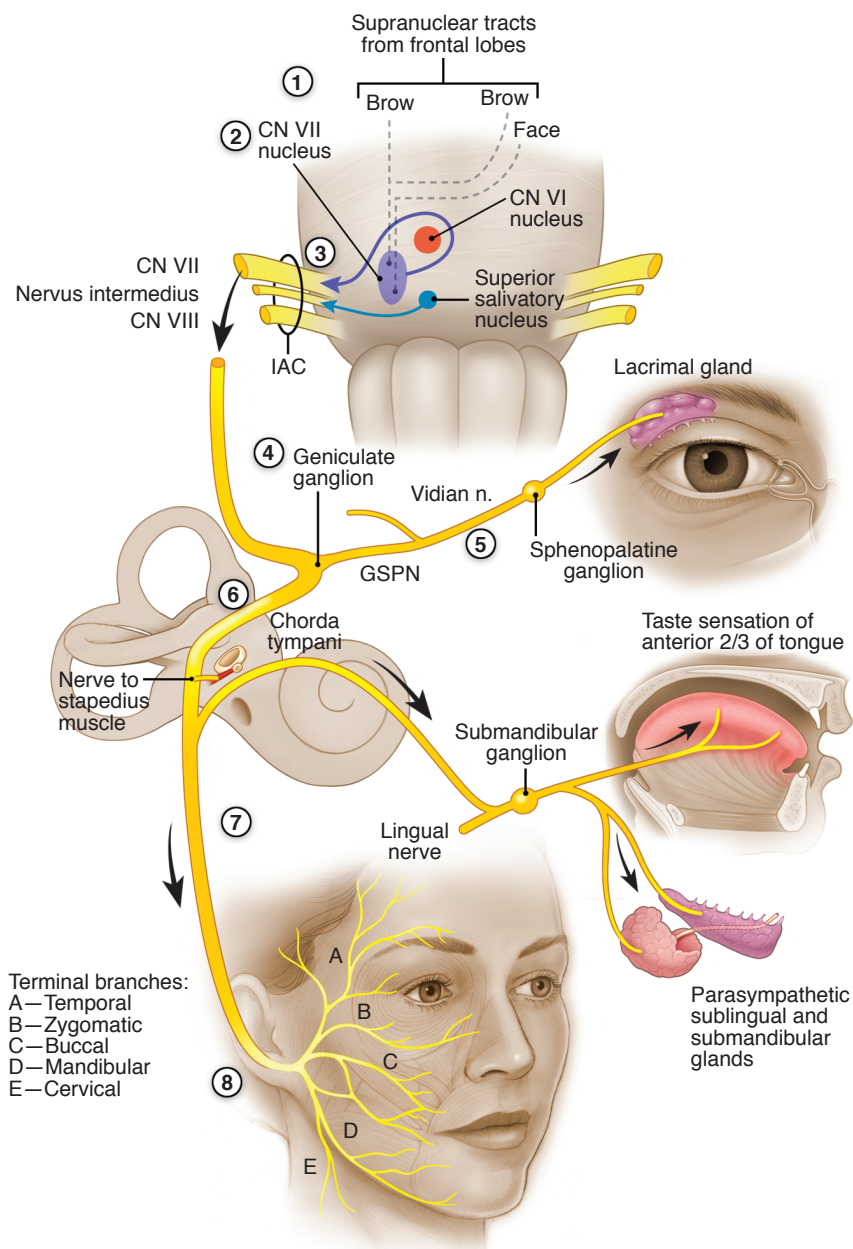


**Figure 12-7** Eyelid retraction from thyroid eye disease. Eyelid retraction on the left side is enhanced by severe left inferior rectus muscle restriction and left hypotropia. (Courtesy of Steven A. Newman, MD.)

## Abnormalities of Facial Movement

The ophthalmologist may be asked to evaluate CN VII weakness, which is frequently seen in clinical settings. Assessment of CN VII includes testing not only motor function, but also sensory and autonomic functions. Motor function can be readily assessed by observation. With the patient at rest, any asymmetry of facial expression or eyelid blink is noted. The palpebral fissure on the side of CN VII paresis will be wider as a result of the relaxed tone of the orbicularis oculi muscles. The clinician can test the various muscle groups by asking the patient to smile, to close the eyes forcibly, and to wrinkle the forehead. The degree to which the eyelashes become buried on each side can reveal subtle orbicularis oculi muscle weakness. The corneal blink reflex provides a functional assessment of CN VII and CN V.

Testing autonomic functions such as salivation and lacrimation as well as testing sensation can help localize CN VII lesions, but this is not commonly done in clinical practice. Cutaneous sensation can be tested along the posterior aspect of the external auditory canal. Lesions of CN VII from the cerebellopontine angle to the geniculate ganglion typically impair all functions of the nerve, whereas lesions distal to the geniculate ganglion affect only certain functions, depending on their location (Fig 12-8).



**Figure 12-8** Distribution and topical diagnosis of CN VII lesions.

1. *Supranuclear facial palsy*: contralateral weakness of lower two-thirds of the face with accompanying weakness of the orbicularis oculi muscle; retained expression
2. *Nuclear facial palsy*: facial monoplegia (congenital) plus CN VI nucleus involvement (ipsilateral gaze palsy) and frequent ataxia; occasional Horner syndrome

(Continued)

**Figure 12-8 (continued) Peripheral lesions result in facial monoplegia, including the orbicularis oculi and frontalis muscles, as well as the following:**

3. *Cerebellopontine angle*: decreased tearing, dysgeusia, loss of salivary secretion, loss of taste from anterior two-thirds of tongue, hearing impairment, nystagmus, vertigo, ataxia, and adjacent CN (V, VI) findings
4. *Geniculate ganglionitis* (Ramsay Hunt syndrome, herpes zoster oticus): findings are the same as in cerebellopontine angle, but the brainstem and other CNs are not involved
5. *Isolated ipsilateral tear deficiency* due to involvement of vidian nerve (vidian n.) or sphenopalatine ganglion (accompanying CN VI palsy with cavernous sinus involvement)
6. *Fallopian canal*: involvement of nerve to stapedius muscle, dysacusis, involvement of chorda tympani, loss of taste to anterior two-thirds of tongue, impaired salivary secretion
7. *Distal to chorda tympani*: isolated paralysis of facial muscles
8. *Distal to branching of CN VII after it leaves stylomastoid foramen*: only certain branches of CN VII are affected (localized facial; bilateral CN VII palsy may result from weakness)

In addition, bilateral CN VII palsy may result from congenital conditions (Möbius syndrome), sarcoidosis, basilar meningitis, Guillain-Barré syndrome, or neurofibromatosis type 2 (bilateral acoustic neuromas). GSPN = greater superficial petrosal nerve; IAC = internal auditory canal.

(Illustration by Christine Gralapp.)

Any aberrant facial movements at rest or during volitional movement should be noted (see Fig 12-4). After any facial neuropathy, but most commonly as a result of Bell palsy (ie, idiopathic), regenerating axons may reinnervate different muscles from those originally served; such aberrant regeneration can cause synkinetic movements. In this situation, the involved facial muscles may remain weak. When axons originally destined for the orbicularis oculi muscle reinnervate the lower facial muscles, each blink may cause a twitch of the corner of the mouth or a dimpling of the chin. Conversely, movements of the lower face—such as pursing the lips, smiling, or chewing with the mouth closed—may produce involuntary eyelid closure.

Other disorders of aberrant facial innervation include lacrimation caused by chewing (ie, *syndrome of crocodile tears*), in which fibers originally supplying mandibular and sublingual glands reinnervate the lacrimal gland by way of the greater superficial petrosal nerve. This syndrome usually develops after severe injury to the proximal CN VII and may be accompanied by decreased reflex tearing and decreased ability to taste from the anterior two-thirds of the tongue.

## Seventh Cranial Nerve Disorders

### Disorders of Underactivity of the Seventh Cranial Nerve

Facial weakness or paralysis may occur with supranuclear, nuclear, or infranuclear lesions (Table 12-3; see also Fig 12-8). Although Bell palsy is the most common cause of facial weakness, it is important to explore other etiologies. The first step in examining a patient with facial weakness is to determine whether the palsy is central (ie, upper motor neuron) or peripheral (ie, lower motor neuron) (Fig 12-9). This can be achieved by asking the patient to look up and raise the eyebrows, testing contraction of the frontalis muscle. If

**Table 12-3 Etiologies of Facial Paralysis****Bell (idiopathic) palsy****Infections**

Acute or chronic otitis media

Herpes zoster (Ramsay Hunt syndrome)

Lyme disease

*Other:* diphtheria, enterovirus, human immunodeficiency virus, infectious mononucleosis, leprosy, meningitis, mumps, rubella, syphilis, tetanus, tuberculosis, varicella, zygomycosis**Miscellaneous causes**

Myasthenia gravis

Diabetes mellitus

Guillain-Barré syndrome

Melkersson-Rosenthal syndrome

Sarcoidosis

Vasculitis

Polyarteritis nodosa

Granulomatosis with polyangiitis

**Neoplasms**

Cerebellopontine angle tumor

Intratemporal bone tumor

Parotid gland tumor

Pontine glioma

*Other:* epidermoids, hemangioma, Langerhans cell histiocytosis (formerly, histiocytosis X), leukemia, lymphoma, sarcoma**Pontine demyelination****Pontine infarct or hemorrhage****Trauma**

Congenital facial paralysis (often due to birth trauma from forceps use)

Facial palsy from head trauma

frontalis muscle function is intact, a central palsy is likely; impaired frontalis contraction suggests a peripheral cause. Also, peripheral facial nerve palsies are frequently accompanied by defective taste, tearing, and hyperacusis.

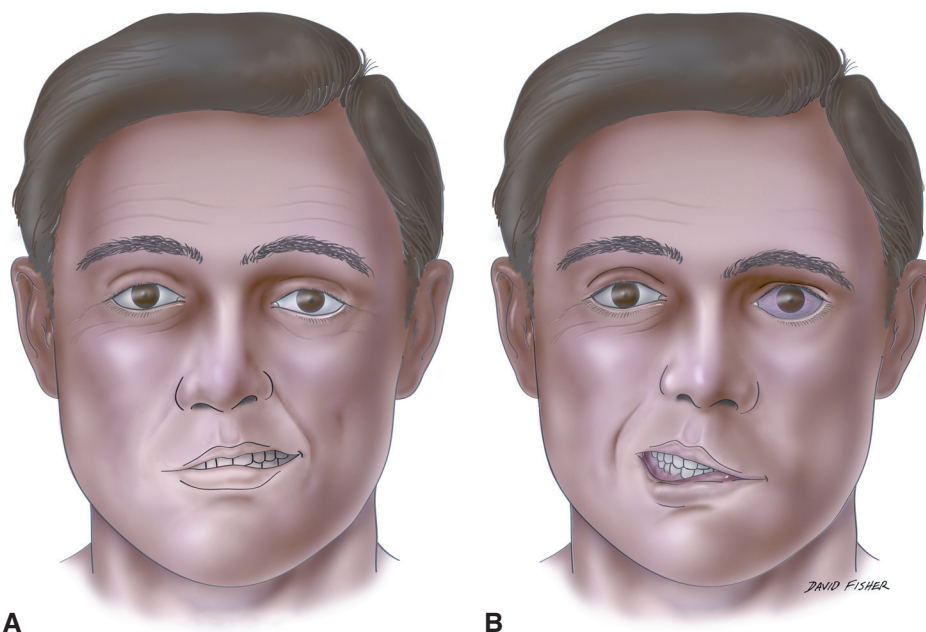
**Supranuclear lesions**

A frontal lobe lesion in the facial portion of the precentral gyrus results in a contralateral paralysis of volitional facial movement, which typically involves the lower face and spares the upper face (upper motor neuron lesion). Emotional and reflex facial movements such as smiling and spontaneous blinking are usually preserved because they are controlled through extrapyramidal pathways.

With extrapyramidal disorders, such as parkinsonism or progressive supranuclear palsy, spontaneous facial expression is minimal, and the spontaneous blink rate is usually reduced. Volitional facial movements generally remain intact.

**Brainstem lesions**

Ipsilateral facial weakness that involves both the upper and lower face may occur with a pontine disorder. Vascular lesions and intraparenchymal tumors are the most common causes. Other evidence of a pontine disturbance is to be expected, such as ipsilateral



**Figure 12-9** Facial nerve palsy. **A**, Right upper motor neuron (central) facial nerve palsy with sparing of the upper portion of the face. **B**, Left lower motor neuron (peripheral) facial nerve injury with upper and lower face involvement. (Reproduced with permission from Bhatti MT, Schmalfuss I. Handbook of Neuroimaging for the Ophthalmologist. JP Medical Ltd; 2014.)

corneal and facial anesthesia, CN VI palsy, lateral gaze palsy, cerebellar ataxia, and contralateral hemiparesis. Dissociations between the autonomic, sensory, and CN VII motor functions may be present. Large lesions of the pons may produce facial diplegia, which also occurs in Möbius syndrome, a congenital disorder involving bilateral CN VI palsies or gaze palsies.

### **Peripheral lesions**

Peripheral or lower motor neuron lesions that result in ipsilateral facial weakness may have numerous causes. Concomitant impairment of CN V, CN VI, or CN VIII or cerebellar signs may indicate cerebellopontine angle tumors. Synkinesis or misdirection phenomenon are late sequelae of peripheral rather than central facial palsies. Table 12-4 compares the key features and treatment of select facial nerve syndromes.

**Bell palsy** As mentioned previously, *Bell palsy* represents the most common type of facial neuropathy; however, it is a diagnosis of exclusion. Bell palsy typically occurs in adults and is characterized by the sudden onset of unilateral facial paresis. Pain may either precede the palsy or occur concurrently. Patients with Bell palsy may report facial numbness, although their cutaneous sensation is usually intact and there may be decreased tearing, diminished taste, and dysacusis.

Although the etiology of Bell palsy is unknown, it is believed to be caused by autoimmune or viral-induced inflammatory or ischemic injury with swelling of the peripheral



**Table 12-4 Comparison of Select Facial Nerve Syndromes**

Condition	Laterality	Associated Neurologic Deficits	Cause	Treatment
Bell palsy	Unilateral	None	Idiopathic	Corticosteroids (+/- antivirals)
Ramsay Hunt syndrome	Unilateral	None	Herpes virus	Antivirals
Guillain-Barré syndrome	Bilateral	Ataxia, areflexia, generalized weakness	Postinfectious	Intravenous immunoglobulin, plasma exchange
Melkersson-Rosenthal syndrome	Unilateral or bilateral	Facial swelling, furrowed tongue	Idiopathic (possibly genetic)	Variable

nerve. The incidence of Bell palsy is higher in pregnant women and in persons with diabetes mellitus or a family history of Bell palsy. If the facial weakness progresses over a period of more than 3 weeks, an alternative etiology should be considered (eg, a neoplastic process, an inflammatory disorder such as sarcoidosis, or an infectious cause).

Approximately 85% of patients with Bell palsy experience a satisfactory recovery, although subtle signs of aberrant regeneration can be detected on examination. In these patients, recovery typically begins within 3 weeks of onset of the deficit and is complete by 2–3 months. In the remaining patients, recovery is incomplete, and significant synkinesis with co-contraction of a variety of facial muscles is common. Complete facial palsy at the time of presentation, impairment of lacrimation, dysacusis, pregnancy, diabetes mellitus, and advanced age are all poor prognostic factors.

Corticosteroids are commonly used to treat Bell palsy, and evidence from meta-analyses and randomized trials supports their efficacy. A 7–10-day course of oral corticosteroids is recommended for patients without systemic contraindications within the first 72 hours of the onset of the palsy. The addition of an antiviral medication (eg, acyclovir, famciclovir, or valacyclovir) is of unclear benefit.

Gronseth GS, Paduga R. Evidence-based guideline update: steroids and antivirals for Bell palsy. Report of the Guideline Development Subcommittee of the American Academy of Neurology. *Neurology*. 2012;79(22):2209–2213.

Schwartz SR, Jones SL, Getchius TS, Gronseth GS. Reconciling the clinical practice guidelines on Bell's palsy from the AAO-HNSF and the AAN. *Neurology*. 2014;82(21):1927–1929.

**Neoplasms** Neoplasms may involve CN VII in the cerebellopontine angle (eg, acoustic neuroma, meningioma), within the fallopian canal, or in the parotid gland. Such lesions may compress CN VII, resulting in facial synkinesis. Most of these lesions are best evaluated through magnetic resonance imaging (MRI) with intravenous contrast material.

**Infections** Various infectious agents can cause CN VII pathology. The nerve may be impaired as a result of infectious meningitis—bacterial, viral, or fungal. Lyme disease, caused by the tick-borne spirochete *Borrelia burgdorferi*, can cause unilateral or bilateral facial

palsies. Classic manifestations include a characteristic rash, arthritis, and meningopolyneuritis (see Chapter 15). The prognosis for CN VII palsy recovery after treatment of Lyme disease is excellent.

Herpes zoster that involves CN VII is called *Ramsay Hunt syndrome* (also called herpes zoster oticus). It is diagnosed through the identification of vesicles along the posterior aspect of the external auditory canal, over the tympanic membrane, or on the pinna. Pain is often severe, and postherpetic neuralgia may result. The prognosis for recovery is less promising for this syndrome than for Bell palsy. An isolated CN VII palsy, as well as other isolated or multiple CN palsies, may be the first sign of human immunodeficiency virus (HIV) seroconversion. Infectious disorders such as otitis media may spread to involve CN VII.

**Miscellaneous causes** CN VII is the most common CN involved in sarcoidosis. The site of involvement is usually the parotid gland, which develops noncaseating granulomatous inflammation. CN VII involvement is frequently bilateral yet asymmetric. For additional discussion of sarcoidosis, see Chapter 15 in this volume and Chapter 10 in BCSC Section 9, *Uveitis and Ocular Inflammation*.

Acquired bilateral facial weakness strongly suggests a cause other than Bell palsy. It may occur in *Guillain-Barré syndrome*, especially in the variant *Miller Fisher syndrome*, in which ophthalmoplegia and ataxia are also present. Cerebrospinal fluid analysis reveals an elevated protein level with a normal cell count. Deep tendon reflexes are usually absent. A high percentage of patients with Miller Fisher syndrome have anti-GQ1b IgG antibodies in their serum. Recovery is generally complete, and the serologic test results improve with clinical improvement. Other causes of acquired bilateral CN VII palsy or facial weakness include meningeal carcinomatosis and MG.

In *Melkersson-Rosenthal syndrome*, recurrent unilateral or bilateral facial paralysis is accompanied by chronic facial swelling and lingua plicata (furling of the tongue). The facial swelling is frequently marked and may be bilateral, even when the facial paresis is unilateral. The etiology of this disorder, which usually begins in childhood or adolescence, is unknown.

**Trauma** CN VII palsy, which can be unilateral or bilateral, can also occur from head trauma. The Battle sign, as manifested by ecchymosis over the mastoid area, may be present and is associated with fractures of the temporal bone. Congenital facial palsy is frequently related to birth trauma from use of forceps and tends to resolve.

### ***Treatment options for seventh cranial nerve underactivity***

In cases of orbicularis oculi muscle involvement, treatment of corneal exposure may be necessary. Artificial tear preparations and lubricants are sufficient in mild cases. Applying lubricating ointment in the eye and then taping the eyelid shut for sleep may be necessary. Moisture chambers have been used at night. Patients should be advised to avoid dusty and windy environments. Breakdown of corneal epithelium indicates the need for punctal plugs, tarsorrhaphy, or injection of botulinum toxin into the levator palpebrae superioris muscle to induce ptosis.

Given the extensive differential diagnosis for CN VII weakness, etiologic considerations in specific clinical situations deserve emphasis:

- *Bilateral* CN VII palsies are most frequently due to sarcoidosis, basilar meningitis (bacterial, viral, spirochetal), or Guillain-Barré syndrome.
- *Recurrent unilateral* CN VII involvement is most commonly idiopathic (ie, Bell palsy) but may be caused by diabetes mellitus, Lyme disease, or Melkersson-Rosenthal syndrome.
- *Progressive* CN VII palsy is highly suggestive of a neoplastic etiology, either from tumor invasion (eg, brainstem, cerebellopontine, or parotid gland) or diffuse infiltration (eg, meningeal carcinomatosis). Further, accompanying CN palsies will aid in topographic localization of the lesion.

In patients with CN VII palsy, it is crucial to determine the status of CN V. Loss of corneal sensation combined with CN VII palsy is a particularly difficult clinical problem. The risk of combined neurotrophic and neuroparalytic keratitis warrants an aggressive approach, possibly including early tarsorrhaphy or an upper eyelid weight implant.

The simplest and most successful surgical treatment for corneal problems associated with chronic CN VII palsies is the implantation of gold or platinum eyelid weights, combined with horizontal eyelid tightening such as a lateral tarsal strip. To avoid implanting too small a weight, the clinician can include trials of various weights taped to the eyelid surface in the preoperative evaluation. The heaviest weight that can be lifted clear of the visual axis is then chosen. Later, if facial nerve function recovers, the weight can be removed.

Sohrab M, Abugo U, Grant M, Merbs S. Management of the eye in facial paralysis. *Facial Plast Surg.* 2015;31(2):140–144.

## Disorders of Overactivity of the Seventh Cranial Nerve

Disorders of CN VII, its nucleus, or the pyramidal or extrapyramidal pathways may produce hyperexcitable states. Benign essential blepharospasm, hemifacial spasm, and facial myokymia are the 3 most common disorders of overactivity (Table 12-5).

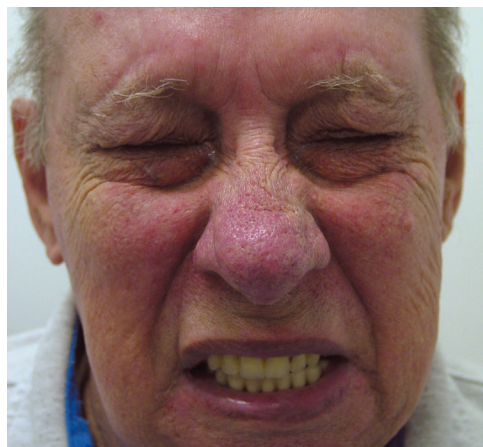### **Benign essential blepharospasm**

Benign essential blepharospasm (BEB) is a bilateral condition that consists of episodic contraction of the orbicularis oculi muscle. Onset usually occurs between the ages of 40 and 60 years. Initially, the spasms are mild and infrequent, but they may progress to the point that the patient's daily activities are severely disrupted. In advanced cases, the patient's eyelids cannot be pried apart during an episode of spasm. Unlike hemifacial spasm, BEB typically abates during sleep. Facial grimacing and other movements may be associated with the blepharospasm (*Meige syndrome*; Fig 12-10), and cogwheeling in the neck and extremities or other extrapyramidal signs may be noted.

**Table 12-5 Comparison of the Common Causes of CN VII Overactivity**

	Laterality	Site of Dysfunction <sup>a</sup>	Etiology	Treatment
BEB	Bilateral	Basal ganglia	Unknown	Botulinum toxin injections (preferred treatment) <i>Medical:</i> Haloperidol, clonazepam, other drugs <i>Surgical:</i> Extirpation of eyelid protractors, selective CN VII section
Hemifacial spasm	Unilateral	CN VII root exit zone in cerebello-pontine angle	Nerve compression by blood vessel or tumor	Botulinum toxin injections (preferred treatment) <i>Medical:</i> Carbamazepine, baclofen, other drugs <i>Surgical:</i> Microsurgical decompression of facial nerve root
Benign eyelid myokymia	Unilateral	Unknown	Unknown	Reassurance Botulinum toxin injections
Facial myokymia	Unilateral	CN VII nucleus or fascicle in pons	Glioma (children), multiple sclerosis (adults)	Treatment of the underlying cause Botulinum toxin injections <i>Medical:</i> Carbamazepine, phenytoin

BEB = benign essential blepharospasm.

<sup>a</sup> Presumed.**Figure 12-10** Benign essential blepharospasm with Meige syndrome. Contraction of the orbicularis oculi muscles occurs in association with facial grimacing. (Courtesy of Eric Eggenberger, DO.)

Although the exact cause of BEB is unknown, increasing evidence acquired through functional neuroimaging suggests that the site of dysfunction is the basal ganglia. The clinician evaluating a patient with blepharospasm should exclude causes of reflex blepharospasm, in particular severe dry eye, intraocular inflammation, and meningeal irritation (usually associated with photophobia). Stress may exacerbate the condition.

Neuroradiologic studies are generally unrevealing and rarely indicated. Functional blepharospasm can occur and can be difficult to distinguish from BEB. In such functional cases, the contractions are much less prominent or subside completely when the patient is distracted.

The effectiveness of medical therapy for BEB is generally limited. Tinted lenses, such as those with an FL-41 tint, may improve blink frequency and light sensitivity. The treatment of choice is injection of botulinum toxin into the orbicularis oculi muscle. The efficacy of the drug relates to its ability to cause muscle weakness. Complications such as ptosis, local ecchymosis, ectropion, diplopia, lagophthalmos, and exposure keratopathy are usually mild and transient. Treatment typically consists of 4–8 injection sites per periorbita. The central portion of the pretarsal orbicularis oculi muscle should be avoided to minimize the chance of inducing ptosis. The treatment effect usually lasts approximately 12 weeks, and repeated injection sessions are needed.

Treatment with surgical myectomy is reserved for cases refractory to botulinum toxin injection. Treatment failure can occur in patients with pure blepharospasm but is more common in patients with blepharospasm associated with apraxia of eyelid opening. See BCSC Section 7, *Oculofacial Plastic and Orbital Surgery*, for additional discussion of surgical myectomy.

BEB may cause psychological distress, with some patients withdrawing socially as the symptoms worsen. Thus, counseling may be as valuable as the medical and surgical management of this condition. The Benign Essential Blepharospasm Research Foundation ([www.blepharospasm.org](http://www.blepharospasm.org)) aids research efforts and provides education and support to patients with BEB.

*Tardive dyskinesia* secondary to neuroleptic and antipsychotic drugs can produce spasms that involve the mouth. Extrapyramidal disorders such as parkinsonism, Huntington disease, and basal ganglia infarction may be accompanied by some degree of blepharospasm.

Ross AH, Elston JS, Marion MH, Malhotra R. Review and update of involuntary facial movement disorders presenting in the ophthalmological setting. *Surv Ophthalmol*. 2011;56(1):54–67.

### **Hemifacial spasm**

Hemifacial spasm is characterized by unilateral episodic spasms that involve the facial musculature and typically last from a few seconds to minutes. The disorder frequently begins as intermittent twitching of the orbicularis oculi muscle but, over the course of several years, spreads to involve all the facial muscles on 1 side (Fig 12-11). Episodes may increase in frequency for weeks to months and then abate for months at a time. CN VII function is usually intact, although over time, subtle ipsilateral facial weakness may develop. Unlike BEB, the spasms can occur during sleep.

The pathogenesis of hemifacial spasm is most commonly compression of the CN VII root exit zone by a dolichoectatic vessel. Abnormal firing in the motor nucleus or ephaptic transmission of nerve impulses causes innervation directed toward a particular muscle group to excite adjacent nerve fibers that are directed to another muscle group. Less commonly, tumors within the cerebellopontine angle, Bell palsy, previous injury to CN VII, or demyelination may lead to the spasms; therefore, MRI of the brainstem, often



**Figure 12-11** Hemifacial spasm. Intermittent contraction of the entire right side of the face. (Courtesy of Rod Foroozan, MD.)

accompanied by magnetic resonance angiography, is typically performed to exclude a compressive lesion or other secondary causes.

Botulinum toxin injection into the periocular and facial muscles has proved very effective and is the treatment of choice for hemifacial spasm in most patients. Reinjection is required, at typical intervals of 3–4 months. Hemifacial spasm responds to lower doses of botulinum toxin than does blepharospasm.

Carbamazepine, clonazepam, or baclofen may provide improvement in some patients. Suboccipital craniectomy with placement of a sponge between CN VII and the offending blood vessel (*microvascular decompression*) may be considered for advanced cases or younger patients. Surgical decompression may be curative but carries higher risks than alternative treatments.

Yaltho TC, Jankovic J. The many faces of hemifacial spasm: differential diagnosis of unilateral facial spasms. *Mov Disord.* 2011;26(9):1582–1592.

### **Spastic paretic hemifacial contracture**

Spastic paretic hemifacial contracture is a rare disorder characterized by unilateral facial contracture with associated facial weakness (Video 12-2). Typically, it begins with myokymia of the orbicularis oculi muscle, which gradually spreads to most of the ipsilateral facial muscles. At the same time, tonic contracture of the affected muscles becomes evident. Over weeks to months, ipsilateral facial weakness develops, and voluntary facial movements of the affected side diminish. Spastic paretic hemifacial contracture is a sign of pontine dysfunction in the region of the CN VII nucleus, often caused by a pontine neoplasm. Damage to the nucleus causes facial weakness, and involvement of supranuclear connections leads to facial spasticity.



#### **VIDEO 12-2** Spastic paretic hemifacial contracture.

Courtesy of M. Tariq Bhatti, MD.



### **Facial myokymia**

Facial myokymia is characterized by continuous unilateral fibrillary or undulating contraction of facial muscle bundles. Occasionally, these rippling movements begin within a portion of the orbicularis oculi muscle and may spread to involve most of the facial muscles.



Facial myokymia typically signifies intramedullary disease of the pons involving the CN VII nucleus or fascicle. It is usually the result of a pontine glioma in children and of multiple sclerosis in adults. In rare instances, myokymia occurs in patients with Guillain-Barré syndrome. Myokymia may be relieved with oral medications such as carbamazepine or phenytoin or with injection of botulinum toxin.

Intermittent fluttering of the orbicularis oculi muscle (*benign eyelid myokymia*) is relatively common. The unilateral phenomenon usually lasts for days or weeks. In rare cases, eyelid myokymia can last for months; these patients may benefit from an injection of botulinum toxin. Caffeine, stress, and sleep deprivation are common contributing factors.

Banik R, Miller NR. Chronic myokymia limited to the eyelid is a benign condition.

*J Neuroophthalmol.* 2004;24(4):290–292.

### **Other conditions**

In rare instances, focal cortical seizures are manifested by gross clonic movements involving only 1 side of the face. The eyes deviate away from the side of the seizure focus during the episode; the patient's ipsilateral hand may also have clonic movements. Frequently, *Todd paralysis*, a transient supranuclear facial paresis, follows the seizure, and the eyes may deviate toward the side of the prior seizure focus.

Oral facial dyskinesias (eg, tardive dyskinesia) are usually noted after long-term use of major tranquilizers and may persist even after the drugs are stopped. *Habit spasm* such as facial tic or nervous twitch is relatively common, particularly in childhood, and is characterized by involuntary, repetitive, reproducible facial movements that can be promptly inhibited on command. These movements tend to disappear in time without treatment. Only in rare cases does Tourette syndrome present with facial twitching alone.

Jung HY, Chung SJ, Hwang JM. Tic disorders in children with frequent blinking. *J AAPOS.*

2004;8(2):171–174.

# The Patient With Head, Ocular, or Facial Pain

## Highlights

---

- Important systemic conditions that should be considered when assessing a patient reporting headache include giant cell arteritis, elevated intracranial pressure, meningitis, internal carotid artery dissection, and arterial hypertension.
- Migraine visual aura is always binocular, although the patient may report an aura as being monocular in the eye in which the visual disturbance appears in the temporal visual field.
- Atypical features for migraine that warrant further investigation include new onset after age 50 years, headache always on the same side, headache preceding the aura, and neurologic deficit.
- MELAS (mitochondrial myopathy, encephalopathy, lactic acidosis, and strokelike episodes) and CADASIL (cerebral autosomal dominant arteriopathy with subcortical infarcts and leukoencephalopathy) are inherited encephalopathies that may resemble migraine in young adults.
- Trigeminal neuralgia with persistent sensory deficits necessitates investigation with neuroimaging, preferably with magnetic resonance imaging.

## Head Pain

---

Headache is a common concern of patients presenting to the ophthalmologist. When pain extends to the orbits, the patient and referring physician may assume that the eyes are in some way responsible for the discomfort. Often the patient may have fears, perhaps unspoken, of a brain tumor. The most important part of an evaluation for headache is the history because the results of the ocular examination are normal in a vast majority of such patients. The International Headache Society (IHS) classification scheme, which was developed in 1988 and most recently revised in 2018, distinguishes *primary* headaches (eg, migraine, tension-type, and trigeminal autonomic cephalgias) from *secondary* headaches (ie, headaches resulting from other causes).

In addition to a complete ophthalmic examination, assessments for a patient reporting headache are needed to identify potential systemic causes. Screening assessments include

- measurement of blood pressure
- inquiries about signs or symptoms of giant cell arteritis (GCA), such as poor appetite, jaw claudication, and night sweats
- physical examination for tenderness or pulselessness of the superficial temporal artery
- neurologic evaluation for meningeal signs (eg, neck stiffness), focal tenderness, and integrity of cranial nerve (CN) function
- formal visual field testing

Table 13-1 summarizes the diagnosis and management of some common headache and related facial pain syndromes.

El-Dairi MA, Bhatti MT. Headaches and facial pain for the ophthalmologist. *Focal Points: Clinical Modules for Ophthalmologists*. American Academy of Ophthalmology; 2011, module 1.

Friedman DI, Digre KB. Headache medicine meets neuro-ophthalmology: exam techniques and challenging cases. *Headache*. 2013;53(4):703–716.

Headache Classification Committee of the International Headache Society. The international classification of headache disorders, 3rd ed. *Cephalalgia*. 2018;38(1):1–211.

## Headache Associated With Systemic Conditions

### ***Giant cell arteritis***

Giant cell arteritis should be suspected in patients older than 50 years with new headaches. Signs and symptoms of this condition also include jaw claudication, fever, weight loss, scalp tenderness, polymyalgia, fatigue, abnormal temporal artery (eg, absence of pulse, tenderness, nodularity), and visual symptoms. Westergren erythrocyte sedimentation rate (ESR) and C-reactive protein (CRP) testing can help screen such patients, although normal laboratory results do not exclude a diagnosis of GCA (see Chapter 15). Tenderness over the temporal artery, particularly if the artery is enlarged or nodular, may support the diagnosis.

### ***Elevated intracranial pressure***

Headache caused by elevated intracranial pressure, as with intracranial mass lesions or idiopathic intracranial hypertension, is typically global, constant, and worse in the morning. Bending over or moving the head often worsens pain, as does Valsalva maneuvers from coughing and straining. Vomiting may occur even without nausea. Other focal, nonlocalizing neurologic signs such as CN VI palsy or papilledema may be present. Pulsatile tinnitus and transient visual loss are common associated symptoms.

### ***Intracranial hemorrhage***

A sudden severe headache accompanied by neck stiffness, change in mentation, or focal neurologic signs suggests intracranial hemorrhage. Neuroimaging is urgently required in such cases. Pituitary apoplexy may also present with a sudden severe headache. It is often accompanied by visual loss and/or CN palsy due to involvement of CNs III, IV, V, or VI.

**Table 13-1 Diagnosis and Management of Select Common Headache and Related Facial Pain Syndromes**

Characteristics	Classic Trigeminal Neuralgia	Secondary Trigeminal Neuralgia	Cluster Headache	Episodic or Chronic Paroxysmal Hemicrania	SUNCT Syndrome	Hemicrania Continua
Age/sex ratio	Middle-aged or later/M:F 1:4	Any/M=W	Any/M:W 9:1	Any/M:W 1:3	Any/M:W 8:1	Any/W > M
Side and location of pain	Unilateral $V_2/V_3 > V_1$	May be bilateral $V_1$ , $V_2$ , or $V_3$	Unilateral periorbital	Unilateral periorbital	Unilateral periorbital	Unilateral hemicrania
Type of pain	Stabbing	Dull, persistent	Boring, very severe	Very severe	Very severe	Sharp
Duration of pain	Seconds to minutes	Chronic	15–180 minutes	2–30 minutes	5–240 seconds	<1 minute
Temporal profile	Few to many attacks per day for weeks or months; pain-free between attacks	Fluctuations, but no remission	1–8 per day Attack phase: 4–16 weeks Remission: 6 months–2 years	5 per day	Numerous in a day; sometimes dull pain between attacks; remissions with irregular pattern	Associated with continuous headache Fluctuating intensity
Associated signs	None; look for trigger	Hypoesthesia $V_1$ , dysesthesia $V_1$ , motor deficit $V_1$ , other cranial nerve palsies	Horner syndrome, eye redness, tearing, rhinorrhea	Horner syndrome, eye redness, tearing, rhinorrhea	Eye redness, tearing	Nausea, vomiting, photophobia ± Horner syndrome
Interictal examination	Normal	Hypoesthesia $V_1$ , motor deficit $V_1$	Normal ± permanent Horner syndrome	Normal ± permanent Horner syndrome	Normal	Normal
Specific treatment	Carbamazepine	Variable response	Acute: oxygen, injectable or intranasal triptans, and DHE Chronic: lithium steroids, calcium channel inhibitors	Indomethacin stops pain	None Variable response	Indomethacin

DHE = dihydroergotamine mesylate; M = men; SUNCT = short-lasting unilateral neuralgiform headache with conjunctival injection and tearing; V = trigeminal nerve; W = women.

Adapted with permission from Biousse V, Newman NJ. *Neuro-Ophthalmology Illustrated*. 2nd ed. Thieme; 2015:545.

**Meningitis**

Headache caused by meningitis may be chronic and not associated with focal neurologic deficits. Neck stiffness and pain on flexion, back pain, pain on eye movement, and photophobia may suggest meningeal inflammation.

**Internal carotid dissection**

An internal carotid dissection may present with facial pain and/or headache. It is often associated with Horner syndrome (see Chapter 11).

**Migraine and Tension-type Headache**

Migraine is a common disabling primary headache disorder consisting of repetitive bouts of headache. Approximately 10% of men and 20% of women experience migraine, with prevalence greatest between the ages of 18 and 44 years. A familial tendency for migraine is strong, and the patient may report having had motion sickness as a child, sleepwalking, and cyclic vomiting.

Onset of migraine may be linked to times of hormonal change, such as during puberty or young adulthood, and migraine episodes may decrease after menopause. Migraine may be exacerbated by menstruation, pregnancy, hunger, stress, certain foods (eg, chocolate or wine), and sleep deprivation. The pain is usually in the frontotemporal region. Diagnosis requires at least 2 of the following pain features:

- unilateral
- pulsating
- moderate to severe
- causing intolerance of physical activity

Associated symptoms include

- environmental sensitivity (ie, photophobia and phonophobia)
- gastrointestinal upset (eg, nausea and/or vomiting)

Characteristic features of migraine are highlighted in Table 13-2.

**Migraine without aura**

Migraine without aura, which comprises 65% of all migraine, has no preceding neurologic symptoms. This type of headache may be global, asymmetric bilateral, or unilateral

**Table 13-2 Clinical Features of Migraine**


Stage	Timing	Characteristics
Prodrome	Occurs up to several days before headache	Mood change, yawning, food cravings, increased urination, fatigue
Aura	Lasts 5–60 minutes	Immediately precedes headache, scintillating scotoma with fortification spectrum
Headache	Lasts 4–72 hours	Severe
Postdrome	Lasts 24–48 hours following headache	Fatigue, cognitive slowing, mood change
Interictal period	Between attacks	Residual hypersensitivity (eg, photophobia)

and can last hours to days. Distinguishing between it and the very common tension-type headache (see the section “Tension-type headache”) may be challenging.

### **Migraine with aura**

Migraine with aura, which comprises 30% of all migraines, is heralded by neurologic symptoms that are most commonly visual. Because visual symptoms in migraine aura originate from the occipital lobes as a result of cortical spreading depression, they are *always* binocular (although the patient may report them as monocular in the eye in which the disturbance appears in the temporal visual field). The aura builds over minutes, with positive visual phenomena that typically have movement. The classic *scintillating scotoma with fortification spectrum* commonly begins with a small scotoma that gradually expands into the peripheral vision (Fig 13-1). The scotoma is bounded by a zigzag, shimmering, colorful, or silvery image that moves temporally into the periphery and then breaks up. Loss of vision may occur, and the presence of both positive and negative phenomena is the hallmark of migraine aura. The aura typically lasts 5–60 minutes and is usually followed by a contralateral throbbing headache. The aura always completely resolves. Most patients experience associated nausea, photophobia, and phonophobia. When untreated, migraine attacks typically last 4–72 hours.

Studies of migraine pathophysiology have found evidence for primary dysfunction involving the afferent sensory neurons of CN V. Activation of the trigeminal nucleus caudalis is thought to cause the release of vasoactive chemokines at the vascular endings of CN V. These neuropeptides are thought to cause dilation of the pial arteries, increase vascular permeability, and induce an inflammatory response that activates trigeminal afferent fibers within the walls of blood vessels.



**Figure 13-1** Visual aura of migraine. **A**, The aura commonly begins with a small scotoma near fixation that gradually expands into the peripheral vision (**B–C**) and then breaks up (**D**). The times shown represent minutes from the onset of the visual aura. (Courtesy of Julie Falardeau, MD.)

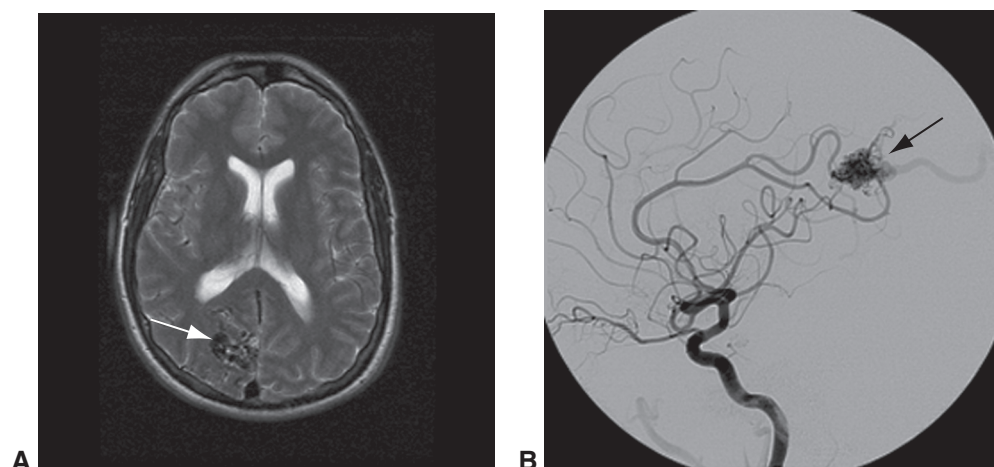


**Typical aura without headache**

Some patients may report only the visual symptoms of migraine aura and no associated headache. This typical aura without headache (formerly, acephalgic migraine) comprises 5% of all migraines and must be differentiated from transient ischemic attacks (TIAs). Typical aura without headache occurs primarily in adults with a history of migraine with aura. The typical manifestation of migraine aura is scintillating scotoma; a less common manifestation is transient homonymous hemianopia without positive visual phenomena or peripheral visual field constriction that progresses to tunnel vision or complete vision loss. Symptoms typically last 5–60 minutes and always resolve completely. Symptoms such as positive visual phenomena and the classic scintillating scotoma with fortification spectrum (see the previous section) or a family history of migraine with aura are helpful for diagnosis. The absence of these features or the presence of residual visual field defects or a bruit should raise suspicion of another underlying process such as cerebrovascular disease or a vascular malformation, and consideration should be given to performing urgent neuroimaging.

**Evaluation of patients with migraine**

If the patient has a typical history of migraine and the results of neurologic and ophthalmic examination are normal, neuroimaging studies are unlikely to show an intracranial abnormality. A history of visual phenomena and hemicranial headaches that change sides suggests a benign etiology. Although symptoms that occur strictly on one side are more worrisome, patients with this clinical presentation are also likely to have migraine. Occasionally, a mass lesion or a large vascular malformation is heralded by typical migraine symptoms, but in such cases, there are often residual visual field defects (Fig 13-2; see also Chapter 15). Such a finding underlines the importance of visual field testing in the evaluation of patients with presumed migrainous visual aura. Referral of patients with suspicious headaches to a neurologist is prudent. Several features suggest the need for additional evaluation of patients



**Figure 13-2** Occipital lobe arteriovenous malformation. **A**, T2-weighted axial magnetic resonance image shows an irregular hypointense mass (arrow) suggestive of a vascular lesion within the right occipital lobe. **B**, Lateral-projection cerebral arteriogram confirms that the lesion is an arteriovenous malformation (arrow). (Courtesy of Rod Foroozan, MD.)

**Table 13-3 Migraine Headache History: “Red-Flag” Features That May Indicate a Secondary Headache Syndrome and Warrant Further Evaluation**

- Is this a new type of headache, or have the patient’s headaches changed in character recently?
- Did the headaches start after age 50 years?
- Are there associated neurologic symptoms such as a change in consciousness, papilledema, or motor weakness?
- Have the symptoms been persistent since onset or steadily progressing in severity over time?
- Are there associated systemic signs and symptoms such as fever, chills, weight loss, and/or neck pain?
- Is there uncontrolled hypertension and/or a history of malignancy or immunosuppression?
- Do position changes or Valsalva-type activities (eg, coughing, sneezing, lifting, bearing down) provoke the headache?
- Is there a visual aura that begins *after* the headache?
- Is it a “thunderclap” headache?

Modified from Smith SV. Neuro-ophthalmic symptoms of primary headache disorders: why the patient with headache may present to neuro-ophthalmology. *J Neuroophthalmol*. 2019;39(2):200–207.

presumed to have migraine. Table 13-3 outlines characteristics of the headache that warrant further investigation.

Frishberg BM, Rosenberg JH, Matchar DB, et al; US Headache Consortium. Evidence-based guidelines in the primary care setting: neuroimaging in patients with nonacute headache. American Academy of Neurology. 2000. Accessed November 15, 2021. <https://www.researchgate.net/publication/237487226>

### ***Ophthalmic features of migraine***

**Visual disturbances** Migraine patients report a wide variety of visual disturbances, which can occur before, during, or even isolated from the headache. Visual aura (discussed in the section “Migraine with aura”) is the only visual complaint included in the diagnostic criteria of migraine. Other perceptual abnormalities associated with migraine include

- palinopsia (discussed in Chapter 7)
- visual phenomena described as dots (black and white or colored), colored pixelated images, and looking through a kaleidoscope or water in a glass
- metamorphopsia, in which objects appear larger (macropsia), smaller (micropsia), closer (pelopsia), or farther (telopsia) than they actually are
- visual snow syndrome: persistent visual disturbance of snowlike or staticlike changes throughout the visual field. Although the disturbance is distinct from migraine aura, most patients have migraine, and migraine can exacerbate the visual snow symptoms.

**Diplopia** Patients report diplopia as a symptom of migraine. If diplopia is monocular (whether unilateral or bilateral) it is most likely related to dry eye. However, patients may also experience cognitive processing difficulty during migraine, and they may perceive this as “double” vision. Binocular diplopia is less common but can reflect brainstem aura. Its presence could also imply a secondary cause of symptoms, such as sixth nerve palsy with increased intracranial pressure. Previously, migraine was thought to be a cause of

episodes of extraocular motor nerve palsy. The disorder formerly called *ophthalmoplegic migraine* is actually a form of inflammatory neuropathy now called *recurrent painful ophthalmoplegic neuropathy*; see Chapter 8 for more on this disorder.

**Photophobia and eye pain** Photophobia is mediated by the trigeminal autonomic system. It can occur at any phase of migraine, and many patients with migraine report chronic photophobia even in the interictal period. Because of the trigeminal innervation of the eye and orbit, migraine headache pain frequently occurs in the orbital, periorbital, and/or retrobulbar areas.

**Dry eye** Dry eye has a high comorbidity in patients with migraine because of the autonomic dysregulation, and pain may be more prominent because of the rich trigeminal innervation of the cornea.

**Anisocoria** The syndrome of benign episodic unilateral mydriasis is closely associated with migraine and most common in young female patients. Unilateral mydriasis can switch eyes during or between attacks, and some patients experience episodic pupil dilatation separate from acute migraine. Mydriasis can also occur bilaterally, but the symmetric dilatation would not result in anisocoria. Miosis is less common but may occur in isolation or in association with the autonomic features (discussed in the section Trigeminal Autonomic Cephalgias and Hemicrania Continua). As anisocoria can also occur in Horner syndrome and third nerve palsy, neuroimaging may be needed to look for a structural lesion.

Digre KB. More than meets the eye: the eye and migraine—what you need to know.  
*J Neuroophthalmol.* 2018;38(2):237–243.

### ***Tension-type headache***

Tension-type headaches are chronic, described as aching or viselike, typically worse at the end of the day, and often precipitated by stress. They are not associated with typical auras. The pathophysiology and treatment of tension-type headaches remain unclear. Such headaches may be associated with depression.

### ***Treatment of migraine and tension-type headache***

The specific type of headache and the needs of the patient should guide treatment. Some patients, for example, need only reassurance that they do not have serious intracranial disease. It is often helpful to involve the primary care physician or a neurologist in the treatment of migraine and tension-type headache.

**Elimination of precipitating or contributing factors** Certain foods provoke headaches in some people, and patients should consider avoiding the potential triggers of chocolate, nitrates, monosodium glutamate, aged cheese, caffeine, wine and other alcoholic beverages, aspartame-based sweeteners, nuts, and shellfish. Other environmental migraine triggers include stress or relief from stress, change in sleep patterns, fumes or strong scents such as perfumes and cigarette smoke, and exercise. The role of estrogens and oral contraceptives is uncertain, but a temporal relationship between initiation of hormone therapy and the development of migraine symptoms suggests a causal relationship.

**Acute migraine** Medications to consider in acute migraine therapy include acetaminophen, dihydroergotamine, serotonin 5-HT<sub>1B/1D</sub>-receptor agonists (ie, triptans such as sumatriptan, rizatriptan, zolmitriptan, frovatriptan, and almotriptan), select nonsteroidal anti-inflammatory drugs (NSAIDs), butorphanol, and combination medications that include caffeine. Note that long-term caffeine intake can worsen headaches.

Also, several US Food and Drug Administration (FDA)–approved devices are available for acute migraine treatment. Options include supraorbital transcutaneous neurostimulation (STNS), noninvasive vagal nerve stimulation (nVNS), single-pulse transcranial magnetic stimulation (sTMS), and remote electrical neuromodulation.

Important caveats and considerations in the treatment of acute migraine include the following:

- The triptans are useful for symptomatic relief of the migraine headache, but to avoid a vasoconstriction-induced infarct, they should be used cautiously in patients with migraine with aura and only after the aura resolves. Also, these drugs are typically not used for patients with suspected or known coronary artery disease because they can cause myocardial infarction in rare instances.
- The new ditan class of medications targets the 5-HT<sub>1F</sub> receptor, which allows these drugs to avoid a vasoconstriction effect yet still act on the trigeminal system. The first agent in this class to receive FDA approval is lasmiditan, for which phase 3 data showed efficacy compared with placebo in treating migraine and that it was well tolerated in patients with cardiovascular risk factors.
- Analgesic medications should be prescribed with caution. The use of analgesic medications for more than 15 days per month can lead to *analgesic rebound headache*, characterized by a constant headache that is relieved only with the continuous use of pain medications. Treatment of analgesic rebound headaches requires the withdrawal of analgesics.
- An antiemetic drug may also be necessary. Certain antiemetics (eg, chlorpromazine, metoclopramide, prochlorperazine) have also been shown to improve headache.
- Photophobia can be managed with use of FL-41 filtered lenses.

**Prophylactic treatment** Prophylactic treatment for migraine headaches is warranted if headaches disrupt activities of daily living beyond what the patient is willing to tolerate. Prophylactic therapy is typically considered for any patient with at least 3–6 headaches per month.

There are several prophylactic treatment options:

- Medications with proven efficacy include several antiepileptics, beta-blockers, and a triptan. The antiepileptic medications include divalproex sodium, sodium valproate, and topiramate. Topiramate, an antiepileptic  $\gamma$ -aminobutyrate (gamma-aminobutyric acid [GABA]) agonist, has been prescribed increasingly for patients with migraine; note that a syndrome characterized by acute myopic shift, ciliochoroidal effusion, and acute bilateral angle-closure glaucoma can occur in some patients using topiramate (see BCSC Section 10, *Glaucoma*).

- The beta-blockers with best evidence for migraine prophylaxis are metoprolol, propranolol, and timolol. Additional studies have demonstrated efficacy of drugs in other classes, including candesartan, memantine, and enalapril, for migraine prevention.
- Anti-calcitonin gene–related peptide (CGRP) monoclonal antibody therapies, such as erenumab, fremanezumab, and galcanezumab, have recently been approved by the FDA for migraine prevention. All are administered by subcutaneous injection once a month, and fremanezumab can also be administered every 3 months.
- Beta-blockers, calcium channel blockers, tricyclic antidepressants, selective serotonin reuptake inhibitors (SSRIs), sodium valproate, and gabapentin may be used as prophylactic drugs, as may NSAIDs, as long as their potential for causing analgesic rebound headaches is kept in mind.
- Oral administration of magnesium and riboflavin can be effective in some patients.
- Pericranial botulinum toxin injections are also successful for some patients.

Tension-type headaches are more likely to respond to prophylactic treatment with tricyclic antidepressants, topiramate, gabapentin, muscle relaxants, or NSAIDs, although the overall rate of success with such drugs is not as high as for migraine. Various forms of biofeedback may also be helpful.

Table 13-4 summarizes drugs with class A evidence for treatment of acute migraine as well as preventive therapy.

**Table 13-4 Medications With Class A Evidence<sup>a</sup> for Acute and Preventive Migraine Treatment**

Strategy	Medications
<b>Abortive</b>	
Analgesics	Acetaminophen
Nonsteroidal anti-inflammatory drugs	Aspirin, diclofenac, ibuprofen, naproxen
Ergot alkaloids	Dihydroergotamine (intranasal or pulmonary inhaler)
Triptans	Almotriptan, eletriptan, frovatriptan, naratriptan, rizatriptan, sumatriptan
Opioids	Butorphanol
Combination	Acetaminophen/aspirin/caffeine; sumatriptan/naproxen
<b>Preventive</b>	
Antiepileptics	Divalproex sodium, sodium valproate, topiramate
Beta-blockers	Metoprolol, propranolol, timolol
Triptans	Frovatriptan
Anti-CGRP monoclonal antibody	Erenumab, fremanezumab, galcanezumab

CGRP = calcitonin gene–related peptide.

<sup>a</sup> Refers to evidence with data derived from multiple randomized clinical trials and/or meta-analyses.

Adapted from Smith SV. Update on migraine: new understanding of pathophysiology and treatments. *Focal Points: Clinical Practice Perspectives*. American Academy of Ophthalmology; 2019, module 2.

- Burstein R, Nosedá R, Borsook D. Migraine: multiple processes, complex pathophysiology. *J Neurosci*. 2015;35(17):6619–6629.
- Digre KB. What's new in the treatment of migraine? *J Neuroophthalmol*. 2019;39(3):352–359.
- Marmura MJ, Silberstein SD, Schwedt TJ. The acute treatment of migraine in adults: the American Headache Society evidence assessment of migraine pharmacotherapies. *Headache*. 2015;55(1):3–20.
- Silberstein SD, Holland S, Freitag F, Dodick DW, Argoff C, Ashman E; Quality Standards Subcommittee of the American Academy of Neurology and the American Headache Society. Evidence-based guideline update: pharmacologic treatment for episodic migraine prevention in adults: report of the Quality Standards Subcommittee of the American Academy of Neurology and the American Headache Society. *Neurology*. 2012;78(17):1337–1345.
- Smith SV. Neuro-ophthalmic symptoms of primary headache disorders: why the patient with headache may present to neuro-ophthalmology. *J Neuroophthalmol*. 2019;39(2):200–207.
- Smith SV. Update on migraine: new understanding of pathophysiology and treatments. *Focal Points: Clinical Practice Perspectives*. American Academy of Ophthalmology; 2019, module 2.

### Trigeminal Autonomic Cephalgias and Hemicrania Continua

The trigeminal autonomic cephalgias (TACs) are primary headache disorders; they include cluster headache, paroxysmal hemicrania, and short-lasting unilateral neuralgiform headache attacks with conjunctival injection and tearing syndrome. They can be difficult to treat and are best managed by neurologists.

#### Cluster headache

Cluster headache is approximately 9 times as common in men as in women. Although the typical age at onset is in the second and third decades of life, this disorder can occur at any age and is typically precipitated by alcohol use. The hypothalamus may play a role in the pathogenesis. Cluster headache is characterized by excruciating bouts of pain that last 15–180 minutes and are localized behind 1 eye in the distribution of the ophthalmic division of CN V ( $V_1$ ). Other characteristics include

- pain that may wake the patient from sleep and cause restlessness
- clusters of episodes that occur over days or weeks
- headache that typically begins like clockwork at the same time of day and then remits for months or years

Associated features include

- ipsilateral tearing
- conjunctival hyperemia
- rhinorrhea
- transient postganglionic Horner syndrome that may become permanent

Cluster headaches can be difficult to treat. Abortive drugs include triptans (subcutaneous or intranasal), oxygen (inhaled), dihydroergotamine (subcutaneous, intramuscular, or intranasal), and lidocaine (intranasal). Drugs useful for prophylaxis include verapamil, lithium, methysergide, corticosteroids, topiramate, and gabapentin.



***Paroxysmal hemicrania***

Paroxysmal hemicrania is characterized by short, severe attacks of pain with cranial autonomic features that occur several times daily. The headache typically lasts 2–30 minutes but may persist for hours. A dramatic resolution of the headache occurs with indomethacin administration.

***SUNCT syndrome***

Short-lasting unilateral neuralgiform headache attacks with conjunctival injection and tearing (SUNCT) syndrome is characterized by unilateral orbital or temporal pain that is severe and throbbing or stabbing. The headache typically occurs more than 20 times per day and lasts 5–240 seconds. It is often associated with conjunctival injection and tearing.

***Hemicrania continua***

Unlike the other TACs, hemicrania continua is characterized by a continuous unilateral headache of variable intensity that waxes and wanes without disappearing completely. The forehead, temple, orbit, and occiput are common sites of pain. Autonomic symptoms are present in most patients. Like paroxysmal hemicrania, this primary headache disorder is responsive to treatment with indomethacin.

**Idiopathic Stabbing Headache**

Also known as “ice pick” headache and “jabs and jolts” syndrome, idiopathic stabbing headache manifests as episodic, momentary, sharp, jabbing pains and occurs more commonly in patients with migraine than in patients with other types of headaches. Patients with cluster headaches also have a high occurrence of idiopathic stabbing headache, typically occurring in the same area as the cluster pain. The most common location for such headaches is in the distribution of  $V_1$ , particularly the orbit, and less commonly the parietal, temporal, facial, occipital, and retroauricular regions. The pain may last less than a second or may occur as a series of stabbing sensations. Idiopathic stabbing headache often responds to indomethacin administration, and many patients improve with standard prophylactic headache drugs.

**Inherited Encephalopathies Resembling Migraine**

The syndrome of mitochondrial encephalopathy, lactic acidosis, and strokelike episodes (MELAS) is a hereditary mitochondrial disorder occurring in children and young adults. Its symptoms (including headache, nausea, vomiting, transient hemianopia, and hemiparesis) suggest migraine; however, permanent neurologic disturbance occurs with spongiform cortical degeneration. Serum and cerebrospinal fluid (CSF) lactate levels and pyruvate levels are elevated, and hyperintense lesions may be observed on T2-weighted magnetic resonance imaging (MRI) of the temporal, parietal, and occipital lobes.

Headache resembling migraine may also occur as the initial symptom of the syndrome of cerebral autosomal dominant arteriopathy with subcortical infarcts and leukoencephalopathy (CADASIL), an autosomal dominant angiopathy that is associated with a mutation in the *NOTCH3* gene on chromosome 19. Headaches occur in 30%–40% of patients with CADASIL and often arise later in life than typical migraine. Recurrent lacunar strokes with

**Table 13-5 Comparison of CADASIL and MELAS**

Characteristic	CADASIL	MELAS
Onset	Presentation at approximately age 30 years	Begins in childhood (age range, 2–15 years), but delayed onset can occur
Pathophysiology	Small-vessel disease due to progressive degeneration of the smooth muscle cells in blood vessels	Deficiency of nitric oxide in small blood vessels of brain leads to strokelike episodes
Genetics	Mutation in the <i>NOTCH3</i> gene on the short arm of chromosome 19	Mutations in mitochondrial DNA
Diagnosis and neuroimaging	Cerebral cortex spared Subcortical lacunar infarcts Abnormal white matter of the anterior temporal poles and superior paramedian bilateral frontal lobes Chronic microangiopathic vascular changes	Elevated lactic acid and pyruvate levels Magnetic resonance spectroscopy shows lactate peak Strokelike lesions Muscle biopsy: common finding of ragged red fibers
Presentation	Migraine with aura Transient weakness Focal neurologic deficit	Seizures Recurrent headaches Loss of appetite Recurrent vomiting Strokelike episodes (hemiparesis) Associated hearing loss Difficulty tolerating exercise
Treatment	Nonspecific Antiplatelet medication	No proven treatment Anticonvulsant L-Arginine Coenzyme Q10

CADASIL = cerebral autosomal dominant arteriopathy with subcortical infarcts and leukoencephalopathy; MELAS = mitochondrial encephalopathy, lactic acidosis, and strokelike episodes.

neurologic deficits and cognitive decline eventually occur. Widespread leukoencephalopathy, particularly within the temporal and frontal lobes, is apparent on MRI. Table 13-5 compares characteristics of MELAS and CADASIL.

Boussier MG, Bioussé V. Small vessel vasculopathies affecting the central nervous system.

*J Neuroophthalmol.* 2004;24(1):56–61.

Ferrante EA, Cudrici CD, Boehm M. CADASIL: new advances in basic science and clinical perspectives. *Curr Opin Hematol.* 2019;26(3):193–198.

## Ocular and Orbital Pain

There is a popular misconception that “eye strain” due to refractive errors and strabismus is a common cause of eye and head pain. The eye is heavily innervated by sensory nerve fibers (see Chapter 1), and inflammatory, ischemic, and even neoplastic involvement of the eye and orbit can produce pain. True ophthalmic causes of eye pain include dry eye and other forms of keratitis, acute angle-closure glaucoma, and intraocular inflammation. These conditions are most commonly diagnosed through examination of the cornea,

anterior segment, and anterior vitreous using a slit lamp. In addition, periocular pain may be referred facial pain (see the section Facial Pain later in this chapter).

Dry eye is a very common cause of ophthalmic discomfort (see BCSC Section 8, *External Disease and Cornea*) and is exacerbated by visual tasks that decrease blink frequency, especially tasks involving long periods of computer use. Pain on awakening may be related to recurrent corneal erosion syndrome.

Acute angle-closure glaucoma can produce ocular pain and is usually associated with halos and decreased vision. Diagnosis is made by slit-lamp examination, gonioscopy, and intraocular pressure measurements. Scleritis is usually accompanied by ocular tenderness. Posterior segment examination with indirect ophthalmoscopy or slit-lamp biomicroscopy may reveal evidence of choroidal or retinal inflammation or posterior scleritis. These causes of ocular pain are discussed in more detail in BCSC Section 7, *Oculofacial Plastic and Orbital Surgery*; Section 9, *Uveitis and Ocular Inflammation*; and Section 10, *Glaucoma*.

Orbital inflammation or infection (orbital cellulitis) usually produces severe eye pain or pain on eye movement, variably accompanied by ocular motility abnormalities, eyelid edema, and proptosis (see BCSC Section 7, *Oculofacial Plastic and Orbital Surgery*). Peri-orbital pain may be the initial manifestation of inflammation or thrombosis within the cavernous sinus. Pain with eye movement commonly accompanies an inflammatory or demyelinating optic neuropathy (see Chapter 4), often in association with decreased vision, visual field changes, and a relative afferent pupillary defect (RAPD). Rapidly expanding tumors of the orbit, orbital apex, and cavernous sinus may also produce eye pain. In these cases, other signs will likely be present, such as a visual field defect, proptosis, ocular motility deficit, resistance to retropulsion of the globe, an RAPD, or an abnormal optic nerve appearance. Microvascular cranial neuropathies (involving CNs III, IV, or VI) can cause retro-orbital pain with associated abnormal ocular motility.

Occipital neuralgia, discussed elsewhere in this chapter, produces pain and tenderness over the greater occipital nerve that radiates to the ipsilateral eye area.

## Trochlear Headache and Trochleitis

Trochleitis is an underdiagnosed orbital cause of headache. At presentation, patients with trochlear headache typically report a history of months to years of chronic orbital pain. Inflammation of the trochlea causes localized pain, swelling, and tenderness, sometimes associated with limitation of eye movement. When there is no obvious orbital inflammation, the diagnosis can be made by eliciting pain with palpation of the involved trochlea. The etiology is usually idiopathic, although trochleitis can be associated with systemic autoimmune diseases. This condition occurs primarily (90%) in women. Treatment includes local injection of corticosteroids in the region of the trochlea or high doses of NSAIDs.

Friedman DI, Gordon LK, Quiros PA. Headache attributable to disorders of the eye. *Curr Pain Headache Rep.* 2010;14(1):62–72.

Harooni H, Golnik KC, Geddie B, Eggenberger ER, Lee AG. Diagnostic yield for neuroimaging in patients with unilateral eye or facial pain. *Can J Ophthalmol.* 2005;40(6):759–763.

Tran TM, McClelland CM, Lee MS. Diagnosis and management of trochleodystonia, trochleitis, and trochlear headache. *Front Neurol.* 2019;10:361.

## Photophobia

Photophobia occurs most frequently as a result of ocular inflammatory disorders, including keratitis and uveitis (particularly iritis), less commonly from chorioretinitis and retinal degenerative disorders, and in rare cases from lesions along the course of the anterior or retrochiasmal visual pathway. Photophobia may also occur because of meningeal irritation (eg, meningitis, subarachnoid hemorrhage) or migraine and is commonly reported by patients with traumatic brain injury.

Katz BJ, Digre KB. Diagnosis, pathophysiology, and treatment of photophobia. *Surv Ophthalmol*. 2016;61(4):466–477.

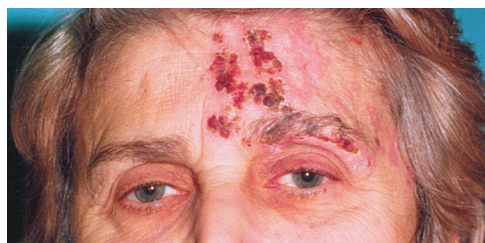## Facial Pain

There are several causes of facial pain, including herpes zoster neuralgia, trigeminal neuralgia, glossopharyngeal neuralgia, and temporomandibular joint (TMJ) syndrome. Facial pain is occasionally a symptom of nasopharyngeal carcinoma or perineural infiltration of skin cancer (squamous cell carcinoma, basal cell carcinoma, or melanoma) affecting the trigeminal nerve or dura at the base of the brain. The onset of facial pain in an older adult may indicate GCA. Patients may have localized facial pain that refers to the eye. Common sources of facial pain include dental disorders and sinus disease. Herpes zoster neuralgia can be associated with facial and/or auditory nerve involvement in herpes zoster oticus, or Ramsay Hunt syndrome.

## Herpes Zoster Ophthalmicus

When herpes zoster involves CN V dermatomes, pain may arise in the affected region days before a vesicular eruption appears (Fig 13-3). In rare cases, no vesicles are ever apparent (zoster sine herpete). Acutely, the pain may be exacerbated by concomitant iritis. The pain is usually burning, shooting/stabbing, tingling, or aching and is accompanied by cutaneous allodynia or dysesthesia. The pain may persist long after resolution of the acute infection (postherpetic neuralgia) and can be extremely discomforting and difficult to treat. Postherpetic neuralgia occurs in 30% of patients.

Medications that are effective for some patients include pregabalin, gabapentin, tricyclic antidepressants, and topical 5% lidocaine patches. Treatment with antiviral drugs during the acute phase (within 48–72 hours of onset) may decrease the risk of severe postherpetic neuralgia. The zoster vaccine, offered to immunocompetent persons aged 50 years and older,



**Figure 13-3** Herpes zoster ophthalmicus. This 63-year-old woman developed left-sided scalp pain and a rash in the  $V_1$  distribution on the left side. (Courtesy of Rod Foroozan, MD.)

significantly reduces the incidence of herpes zoster and markedly decreases the incidence and morbidity of postherpetic neuralgia. (See BCSC Section 9, *Uveitis and Ocular Inflammation*, for further discussion on herpes zoster.)

Kedar S, Jayagopal LN, Berger JR. Neurological and ophthalmological manifestations of varicella zoster virus. *J Neuroophthalmol*. 2019;39(2):220–231.

Oxman MN, Levin MJ, Johnson GR, et al; Shingles Prevention Study Group. A vaccine to prevent herpes zoster and postherpetic neuralgia in older adults. *N Engl J Med*. 2005;352(22):2271–2284.

## Internal Carotid Artery Dissection

Internal carotid artery dissection typically produces pain localized to the face or neck (see Chapter 15). It is often accompanied by ipsilateral sympathetic dysfunction (Horner syndrome, discussed in Chapter 11) due to involvement of the sympathetic fibers in the wall of the carotid artery.

## Giant Cell Arteritis

Giant cell arteritis may produce temporal tenderness and jaw claudication and therefore needs to be differentiated from pain caused by TMJ or muscle dysfunction. See Chapter 15 for additional discussion of GCA.

## Neoplastic Processes

Facial numbness with or without pain suggests pathologic involvement of CN V, such as neoplastic processes that affect the nerve in the area of the cavernous sinus and the Meckel cave. Rapidly growing tumors, such as aggressive undifferentiated malignancies, may produce pain in a large percentage of patients. Facial cutaneous malignancy may be associated with perineural invasion and cause progressive pain, numbness, and multiple CN palsies. Patients should therefore be questioned specifically about prior facial malignancies. Orbital imaging may reveal enlargement of the inferior or superior orbital nerves; results of biopsy of these nerves can confirm the diagnosis.

## Trigeminal Neuralgia

Trigeminal neuralgia, also known as *tic douloureux*, typically occurs in middle age or later. A complex classification system differentiates its causes. The key clinical decision is to distinguish classic (primary) trigeminal neuralgia, in which the abnormality is caused by vascular compression of CN V, from the secondary form, in which a lesion affecting the trigeminal nerve can be identified. Table 13-6 highlights the differences between these 2 categories; see also Table 13-1.

Classic trigeminal neuralgia has no obvious cause apparent on clinical examination, as sensory-function testing in the face is normal, and clinical examination findings are normal between episodes. In 80%–90% of cases, the neuralgia is caused by vascular compression of CN V. The pain typically involves V<sub>2</sub> (maxillary division of CN V) or V<sub>3</sub> (mandibular division of CN V); involvement of V<sub>1</sub> alone is rare (<5%). Chewing, teeth

**Table 13-6 Comparison of Primary (Classic) and Secondary Trigeminal Neuralgia**

Characteristic	Primary Trigeminal Neuralgia	Secondary Trigeminal Neuralgia
Cause	Vascular compression of CN V (80%–90%)	Neoplasia, demyelination, infiltration
CN division	V <sub>1</sub> , V <sub>2</sub> , V <sub>3</sub> (V <sub>1</sub> alone rare)	V <sub>1</sub> , V <sub>2</sub> , V <sub>3</sub> (V <sub>1</sub> alone possible)
Precipitating causes	Chewing, teeth brushing, cold wind	Spontaneous episodes but may also have precipitating cause
Clinical features	Duration of attacks: seconds to 2 minutes Type of pain: electric shock–like, shooting, stabbing	More likely to be longer lasting and not associated with precipitating cause; less likely stabbing in nature
Associated features	Background continuous pain of moderate severity	Other CN involvement
Facial examination findings	Normal sensory function	Hypoesthesia or dysesthesia
MRI findings	CN V root atrophy and/or displacement with causative vascular compression	Infiltration or other abnormalities
Treatment	Medical: gabapentin, carbamazepine, clonazepam, valproic acid Surgical: selective destruction of trigeminal fibers (rhizotomy) or surgical decompression of CN V in the posterior cranial fossa	Same as for primary trigeminal neuralgia

CN = cranial nerve; MRI = magnetic resonance imaging.

brushing, or exposure to cold wind may precipitate stabbing or electric shock–like jabs, which last seconds to minutes. There may be periods of remission.

Secondary (also called symptomatic) trigeminal neuralgia may result from an infiltrative process, a posterior cranial fossa mass lesion, or demyelinating disease. The presence of a sensory disturbance such as hypoesthesia or dysesthesia increases the likelihood of a secondary cause. Neuroimaging of the posterior cranial fossa, preferably with MRI, is indicated. Medication options include gabapentin, pregabalin, carbamazepine, phenytoin, baclofen, clonazepam, and valproic acid. Surgical options include selective destruction of trigeminal fibers (rhizotomy) and decompression of CN V in the posterior fossa.

## Occipital Neuralgia

Paroxysmal stabbing pain in the distribution of the greater or lesser occipital nerves caused by occipital neuralgia may lead to diagnostic confusion with other causes of head and facial pain. Occipital neuralgia is characterized by paroxysmal attacks that last seconds to minutes and have a stabbing or sharp quality. Tenderness may be elicited with pressure applied over the affected nerve. Injection of local anesthetic drugs relieves the pain, which is helpful in confirming the diagnosis.





# The Patient With Functional Neurological Symptom (Conversion) and Related Disorders



This chapter includes related videos. Go to [www.aao.org/bcscvideo\\_section05](http://www.aao.org/bcscvideo_section05) or scan the QR codes in the text to access this content.

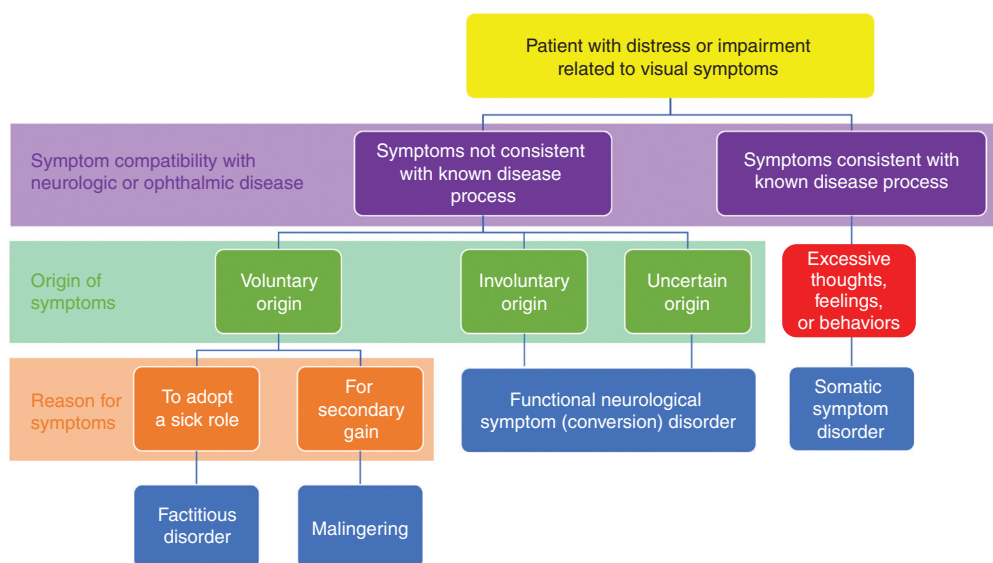
## Highlights

- Functional neurological symptom (conversion) disorder is diagnosed when there is incompatibility between the symptom and recognized neurologic or ophthalmic disease *and* the patient is impaired *or* distressed because of the symptom. The diagnosis does not require a judgment as to the involuntary nature of the symptom.
- Factitious disorder and malingering are differentiated from functional neurological symptom disorder by *definitive* evidence of voluntary expression of signs or symptoms.
- Somatic symptom disorder is characterized by *excessive* thoughts, feelings, or behaviors related to symptoms (including those due to known ophthalmic and/or neurologic disease).
- People with functional neurological symptom and related disorders can have coexisting neurologic or ophthalmic disease.
- Many, but not all, individuals with functional neurological symptom and related disorders have coexisting psychiatric disease.
- Careful observation of the patient, examination maneuvers, and ancillary testing are helpful in confirming inconsistency between symptoms and behavior in order to support the diagnosis of functional neurological symptom (conversion) disorder, factitious disorder, or malingering.
- First-line treatment of functional neurological symptom disorder is educating the patient about the disorder and managing comorbid diseases. Cognitive behavioral therapy can be helpful in persistent cases.

## Introduction

The patient with symptoms or signs that are incompatible with known neurologic or ophthalmic disease and the patient with *excessive* thoughts, feelings, or behaviors related to any symptom, including those due to known ophthalmic or neurologic disease, share the features of distress and impairment related to somatic symptoms. These disorders are thus grouped together in the current classification of mental health diagnoses (Fig 14-1). Although they are mental health diagnoses, care is often sought from non-mental health providers because of the somatic nature of the symptoms. Accordingly, patients manifesting visual symptoms and signs related to these disorders typically present to eye care providers, and it is important that the practicing ophthalmologist be able to recognize the conditions and facilitate care within the broader health care system. In addition, the ophthalmologist plays an important role in identifying known neurologic and ophthalmic diseases that are frequently misdiagnosed as functional neurological symptom disorder (Table 14-1).

Functional neurological symptom (conversion) disorder, factitious disorder, and malingering can occur in children or adults and are diagnosed after the clinician determines that there is no recognized neurologic or ophthalmic basis for the patient's signs or symptoms (referred to as *functional* symptoms in the remainder of this chapter). Neither functional neurological symptom disorder, factitious disorder, nor malingering is a diagnosis of exclusion; rather, each is an active diagnosis requiring confirmatory findings. *Functional neurological symptom disorder* and *conversion disorder* are the preferred diagnostic terms because they reduce stigma and reflect the lack of etiologic understanding, although other adjectives, such as nonorganic, nonphysiologic, psychogenic, hysterical, and medically unexplained, remain in use.



**Figure 14-1** An approach to functional neurological symptom (conversion) disorder and related disorders in the patient with distress or impairment due to visual symptoms. (Courtesy of Heather E. Moss, MD, PhD.)

**Table 14-1 Neurologic and Ophthalmic Diseases Frequently Misdiagnosed as Functional Neurological Symptom (Conversion) Disorder**


---

Acute idiopathic blind-spot enlargement syndrome, acute zonal occult outer retinopathy
Bilateral retrochiasmal disease (eg, occipital infarcts)
Chiasmal disease without optic atrophy (eg, craniopharyngioma, pituitary adenoma)
Cone-rod dystrophy
Early keratoconus, irregular astigmatism
Early posterior subcapsular cataracts
Leber hereditary optic neuropathy
Maculopathy (eg, subtle central serous retinopathy, macular edema, epiretinal membrane)
Paraneoplastic retinopathy
Retinitis pigmentosa sine pigmento
Retrobulbar optic neuropathy
Stargardt disease

---

Adapted from Albert DM, Miller JW, eds. *Albert & Jakobiec's Principles & Practice of Ophthalmology*. 3rd ed. Saunders/Elsevier; 2008:4019.

There are important differences between current and historical diagnostic criteria for functional neurological symptom (conversion) disorder, factitious disorder, and malingering. Current criteria are as follows:

- Diagnosis of vision loss due to functional neurological symptom (conversion) disorder does not require proof of an involuntary nature of the symptoms, as this is often difficult to determine.
- Factitious disorder and malingering are reserved for those patients in whom voluntary feigning of symptoms and signs with the motivation of assuming the sick role (factitious disorder) or for secondary gain such as monetary compensation from litigation or disability status (malingering) can be established with some certainty.
- A diagnosis of vision loss due to functional neurological symptom (conversion) disorder requires patient distress *or* impairment related to somatic symptoms. Lack of concern about impairment (“la belle indifférence”) does not exclude the diagnosis.

A substantial proportion of patients with ophthalmic and/or neurologic disease may experience superimposed functional symptoms. Other patients with symptoms due to known ophthalmic and/or neurologic disease have excessive thoughts, feelings, and behaviors consistent with *somatic symptom disorder*, the diagnosis of which does not require functional symptoms (ie, those for which there is incompatibility between symptoms/signs and known disease). Many patients in whom hypochondriasis was previously diagnosed fall into this category. Patients with so-called functional overlay and/or somatic symptom disorder may be very challenging; the ophthalmologist must ensure that the nonfunctional component of their disease is properly identified and treated while also identifying the mental health components so that they can be evaluated and managed by the broader health care team.

A substantial proportion of patients with functional neurological symptom (conversion) disorder may also have other psychiatric comorbidities, including anxiety disorders, depressive disorders, personality disorders, and somatic symptom disorder.

American Psychiatric Association. *Diagnostic and Statistical Manual of Mental Disorders, Fifth Edition*. American Psychiatric Association; 2013.

## Clinical Profile

The first step in identifying a patient with a functional neurological symptom (conversion) disorder, factitious disorder, or malingering is to have a high index of suspicion when the patient's pattern of vision loss does not fit the common sequence of known diseases. For example, trivial external trauma to the eye should not cause long-term disabling vision loss. Potential secondary gain factors may become evident as the examiner records the malingering patient's history. Some malingering patients may be more focused on impending litigation or disability determination than on the diagnosis or treatment of their issue.

"Everything counts" should be the clinician's guiding principle. Each piece of information about the patient, from the time the appointment is made through completion of the office visit, may help direct the examination. The patient's general behavior and ocular capabilities should be observed throughout the examination. Does the patient appear to have difficulty with nonvisual tasks such as signing in at the front desk? Can the patient successfully walk into the room and take a seat in a chair or shake the physician's silently outstretched hand? Wearing dark sunglasses into the examination room has been associated with functional visual loss. Displaying empathy, employing active listening, and carefully recording the patient's story help the clinician to ensure that the doctor-patient relationship remains productive and nonconfrontational.

Suspicion should increase if the ophthalmic examination shows a mismatch between objective and subjective findings. A diagnosis of a functional symptom can be confirmed when the patient demonstrates a capability that should not be possible on the basis of the stated symptoms or other examination findings. It is helpful to tailor the examination to the individual and the specific concerns. Examiners must be patient and persistent with the tests being used and confident in performing them. The examiner can use *misdirection* to encourage a patient's belief that a particular eye or function being tested is part of a normal eye examination, when in reality the examiner may be working to confirm a functional neurological symptom (conversion) disorder by demonstrating an inconsistent response. An important caveat is that lack of cooperation or understanding does not prove a symptom is functional.

Although the scope and economic impact of functional neurological symptom and related disorders are difficult to measure, patients with these disorders are a strong minority of clinical encounters, accounting for 4%–6% of neurology outpatient visits and 5%–12% of neuro-ophthalmology referrals in the United States. More broadly, the prevalence of somatic symptom disorders in primary care visits is 17%. The cost to society from functional visual symptoms and somatic symptom disorder related to visual symptoms is enormous.

Dattilo M, Biousse V, Bruce BB, Newman NJ. Functional and simulated visual loss. *Handb Clin Neurol*. 2016;129:329–341.

- Gilbert AL. Non-organic visual loss in children. American Academy of Ophthalmology. October 14, 2015. Accessed November 15, 2021. <https://www.aao.org/disease-review/neuro-ophthalmology-non-organic-visual-loss-in-children>
- Miller NR, Subramanian P, Patel VR, eds. Neuro-ophthalmologic manifestations of nonorganic disease. In: *Walsh and Hoyt's Clinical Neuro-ophthalmology: The Essentials*. 3rd ed. Lippincott Williams & Wilkins; 2016:451–464.

## Examination Techniques

The ophthalmologist's main goals for the examination of patients with suspected functional neurological symptom (conversion) disorder, factitious disorder, or malingering are as follows:

- Exclude ophthalmic and neurologic disease as a cause of all symptoms by performing a thorough and complete history and examination with supportive ancillary testing as needed.
- Distinguish symptoms caused by ophthalmic or neurologic disease from functional symptoms.
- Meticulously test for clinical features that support the diagnosis.

Manifestation of functional symptoms varies. The examination is based on the symptoms, which can be categorized as follows:

- afferent visual pathway (visual acuity and visual field)
- ocular motility and alignment
- pupils and accommodation
- eyelid position and function

### Afferent Visual Pathway

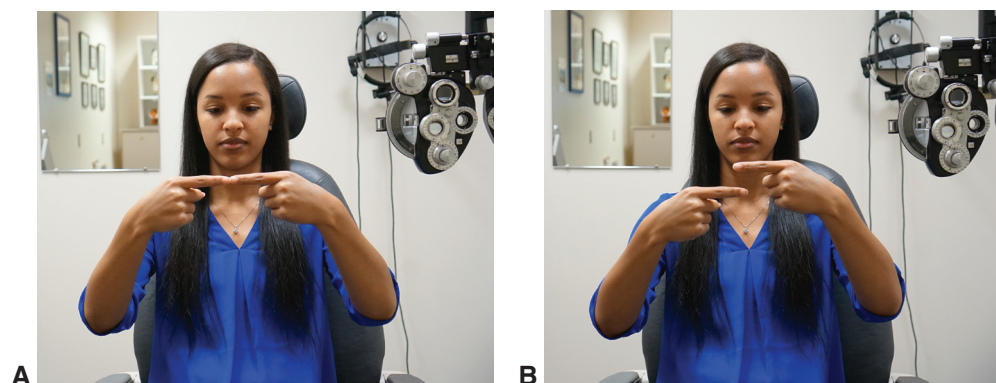
Selection of the appropriate tests of the afferent visual pathway will depend on whether the dysfunction appears to be visual acuity loss (complete or partial, both eyes or one eye) or a visual field defect.

#### **No light perception in both eyes**

Several tests, visual and nonvisual, are used when a patient reports complete blindness in both eyes (ie, no light perception [NLP]). A patient's inability to perform nonvisual tasks may provide evidence of a functional symptom component for that patient's report of total blindness. A poor performance on proprioceptive testing, such as failure to sign a paper or adequately perform a finger-to-nose test, in the absence of systemic neurologic diseases, should alert the clinician to inconsistencies between symptoms and examination findings.

**Finger-touching test** The patient is asked to touch the index fingertips of each hand together. A truly blind person can easily touch the fingertips together, because it requires proprioception, not vision (Fig 14-2). Therefore, a patient with NLP vision as their only neurologic symptom who cannot touch the fingertips of each hand together is responding in an inconsistent manner.





**Figure 14-2** Finger-touching test. The patient is asked to make the index fingers touch. **A**, A truly blind patient can easily perform this task. **B**, A patient with functional vision loss may demonstrate the inability to make the fingertips touch. (Courtesy of M. Tariq Bhatti, MD, and Mays A. El-Dairi, MD.)

**Pupillary reaction** The presence of normal (brisk) pupillary reactions suggests that the anterior visual pathways are intact. However, it does not prove that blindness in both eyes is a functional symptom; the pathways posterior to the branching of axons to the pretectal nuclei (eg, posterior optic tracts, lateral geniculate nucleus, optic radiations, or occipital cortex) could be involved.

**Optokinetic nystagmus** In this test, which is perhaps the easiest to perform in the assessment of NLP in both eyes, an optokinetic nystagmus (OKN) drum is slowly rotated in front of the patient (a smartphone video of a slowly moving wide-striped pattern can also be used). If the patient reports seeing nothing, but the patient's eyes move with the stripes (see Chapter 9, Video 9-6), a functional symptom component has been established. It is possible for those with malingering or factitious disorder to purposely minimize or prevent the response by looking around or focusing past the stripes.

**Mirror test** A large mirror is slightly and slowly tilted forward and backward and rotated from side to side in front of the patient (Video 14-1). As in the OKN test, if the patient reports seeing nothing but the examiner notes eye movement with the mirror, then a subjective–objective mismatch has been documented.



**VIDEO 14-1** Mirror test: normal response.  
Courtesy of M. Tariq Bhatti, MD.



**Electrophysiologic testing** Flash and pattern-reversal visual evoked potentials (VEPs) can play a role in assessing a possible functional neurological symptom disorder. Although both false-positive and false-negative results are possible, the results can be used to confirm ophthalmic or neurologic disease; for example, a VEP with increased latency and decreased amplitude suggests a demyelinating optic neuropathy. Normal VEP results for a patient who reports severe vision loss in one or both eyes and who has normal clinical

examination findings support a diagnosis of functional symptom disturbance of vision. However, an abnormal pattern-reversal VEP result in a patient who has normal findings on neuro-ophthalmic examination should not, by itself, lead to a diagnosis of an ophthalmic or neurologic disease because a variety of patient factors (eg, inattention, lack of concentration, meditation, defocusing) can suppress a VEP (see also “Visual evoked potential testing” in Chapter 3).

### **No light perception in one eye**

All the tests described for NLP in both eyes can be performed unilaterally. The clinician can also use tests that involve ocular viewing confusion or tests that require binocularity.

**Relative afferent pupillary defect** In patients whose eye examination findings are normal but who report complete vision loss (ie, NLP) in 1 eye only, the absence of a relative afferent pupillary defect (RAPD) is consistent with functional vision loss (see Chapter 3). A small amount of direct pupillary response to light in an eye with NLP vision can be observed in retinal or optic nerve diseases that spare fibers mediating the pupillary light reflex and therefore does not confirm diagnosis of a functional cause of vision loss.

**Base-out prism test** A base-out prism is placed in front of 1 eye while the patient keeps both eyes open; normally, this procedure elicits an inward shift of that eye (either as a conjugate saccade followed by a convergent movement of the opposite eye or by a convergent movement alone). Eye movement that occurs when the prism is placed over the eye with no vision (the reported bad eye) indicates vision in that eye (Video 14-2). This sign may be difficult to elicit in individuals with normal vision when the prism is placed over the nondominant eye or is of a low power, or in a patient with a suppression scotoma.



#### **VIDEO 14-2** Base-out prism test: normal result.


Courtesy of M. Tariq Bhatti, MD.



**Vertical prism dissociation test** A 4-diopter (D) prism is placed base-down in front of the eye with better vision (reported good eye) of a patient who reports blindness in 1 eye. If the patient has symmetric vision in both eyes, 2 images should be seen, 1 above the other, with equal clarity. If the patient is able to see the letters only with the reported good eye, only 1 image should be seen (Fig 14-3).

Golnik KC, Lee AG, Eggenberger ER. The monocular vertical prism dissociation test. *Am J Ophthalmol.* 2004;137(1):135–137.

**Stereopsis testing** Stereopsis requires binocular vision. Patients may be tested for stereopsis with the standard stereoacuity tests such as the fly, graded circle test, or animal test (using their appropriate near correction). Any evidence of stereopsis indicates that vision is present in the reported blind eye. It should be noted that patients with vision in only 1 eye may be able to detect asymmetries in the first several circles of the graded circle test on the basis of monocular clues. However, if the circle, animal, or fly is “standing out from the page,” the patient has binocularity.



**Figure 14-3** Monocular vertical prism dissociation test. **A**, With functional vision loss, the patient will describe seeing 2 images, 1 above the other. **B**, The patient with vision loss due to monocular ophthalmic disease will be unable to see the second image or will see only a very blurred second image. (Courtesy of Lanning B. Kline, MD.)

**Confusion tests** For confusion tests to be successful, the patient must be unaware of which eye is actually being tested. Also, testing must appear to be simply a normal part of the examination. Any suspicion on the part of the patient will be detrimental to interpretation of the results. Several tests can be used for confusion tests, some of which are discussed in the following sections.

**FOGGING TEST** A trial frame with plus and minus cylinder lenses (6 D), the axes of which are parallel, is placed in front of the patient's reported good eye. The patient is asked to read the Snellen chart while 1 of the cylinder lenses is rotated. The rotation will severely blur vision as the 2 axes are rotated out of alignment. If the patient continues to read, he or she is doing so with the reported bad eye (Fig 14-4).

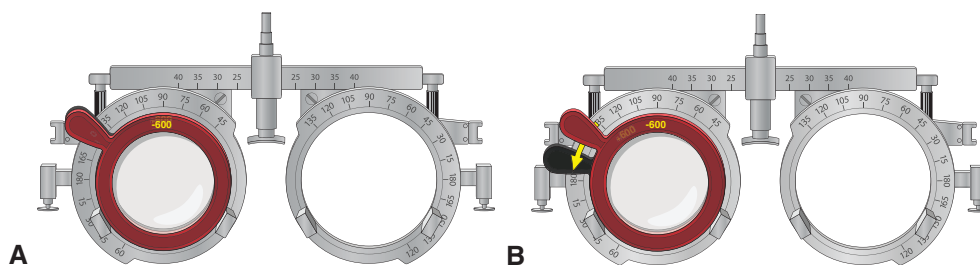
**DUOCHROME TEST** A duochrome (red-green) pair of glasses is placed over the patient's eyes, with the red lens over the reported bad eye. The red-green filter is then placed over the Snellen chart, presenting the letters on a split green and red background. The green lens will prevent the reported good eye from seeing the letters on a red background. If the red letters are read, the patient is reading with the reported bad eye (Fig 14-5).

**POLARIZED LENS TEST** The patient wears the polarized lenses that are used in the stereo-acuity test while reading a chart specially projected with corresponding polarized filters. The clinician can ask the patient to read specific letters or lines to determine whether the patient is reading with the reported bad eye.

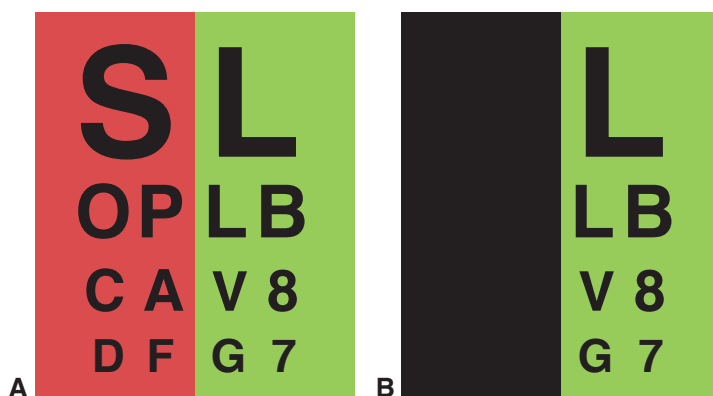
### ***Reduced vision in one eye***

Patients who report symptoms of reduced vision are more challenging than those who report NLP in 1 eye. The clinician must convincingly demonstrate that the patient has better visual acuity than initially measured. Many of the tests described for patients with NLP in 1 or both eyes can also be used for patients with reduced vision in 1 (or both) eyes.

**Stereopsis testing** As previously stated, the presence of stereopsis indicates that the patient has at least some vision in both eyes. Although attempts have been made to equate



**Figure 14-4** Fogging technique demonstrating the use of paired cylinders. **A**, A trial frame with +6 diopter (D) and -6 D cylinder lenses with parallel axes is placed in front of the “good” eye. **B**, As the patient reads the Snellen chart, a small turn of the cylinder axis for 1 lens makes the axes no longer parallel and blurs the image seen by the “good” eye, so that the patient is now reading with the “bad” eye. (Illustration by Mark Miller.)



**Figure 14-5** Views of a duochrome chart as seen by a patient wearing red-green glasses (red over the left eye). **A**, A patient with functional vision loss unknowingly reads both sides of the chart. **B**, A patient with ophthalmic disease of the left eye is unable to read the left side of the chart.

visual acuity with quantitative stereopsis, this relationship suggests, but does not establish, functional vision loss (Table 14-2).

**Confusion tests** The confusion tests described in the section “No light perception in one eye” are useful if the patient reports a substantial reduction in visual acuity in 1 eye. The fogging test, duochrome test, and polarized lens test may help the clinician obtain a quantitative visual acuity measurement if the patient is cooperative. The vertical prism dissociation test can also be used as a confusion test. Vertical prism is placed over the reported good eye while the patient views a single visual acuity testing line. The patient will see 2 lines, the top line with the reported bad eye and the bottom one with the reported good eye, and is asked to read them. Monocular acuity can then be established. Unlike for the assessment of a patient who claims blindness in 1 eye, in this case, simply demonstrating that the patient can see both lines is not sufficient; the clinician must demonstrate that the actual visual acuity for the reported bad eye is better than the acuity measured initially.

**Table 14-2 Comparison of Visual Acuity to Stereopsis**

Titmus Score in Wirt Circles (Stereoaucuity in arc seconds)	95% Prediction Interval Snellen Visual Acuity	99% Prediction Interval Snellen Visual Acuity
9 (40)	20/40	20/79
8 (50)	20/45	20/95
7 (60)	20/50	20/120
6 (80)	20/62	20/180
5 (100)	20/76	20/270
4 (140)	20/110	20/570
3 (200)	20/180	20/1800
2 (400)	20/690	20/39000
1 (800)	20/5300	20/7600000

How to interpret Table 14-2: A patient who demonstrates visual acuity of 20/400 in the eye with poorer vision and scores 7 circles (60 arc seconds) would be expected to have visual acuity in the eye with poorer vision no worse than 20/50 with 95% prediction interval and no worse than 20/120 with 99% prediction interval.

Adapted with permission from Sitko KR, Peragallo JH, Bidot S, Biousse V, Newman NJ, Bruce BB. Pitfalls in the use of stereoaucuity in the diagnosis of nonorganic visual loss. *Ophthalmology*. 2016;123(1):198–202.

**Reduced vision in both eyes**

Reduced vision in both eyes is the most difficult symptom to address in patients with functional vision loss. Proving a functional symptom requires time and patience from the examiner to induce the patient to respond to visual stimuli that are smaller than initially measured.

**Bottom-up acuity** This examination begins with a visual acuity determination on the smallest line on the Snellen chart (20/10). If the patient cannot see these letters, the examiner announces the use of a “larger line” and then switches to the 20/15 line and several different 20/20 lines. The examiner continually expresses disbelief that such “large” letters cannot be identified. If the patient still denies being able to read the letters, he or she is asked to determine the number of characters present and whether the characters are round, square, and so on. The examiner might suggest that the characters are letters and that the first one is easier to identify than the others. By the time the “very large letters” (ie, 20/50) are reached, the patient often can read optotypes that are much smaller than those identified initially.

A variation of this technique is to have the patient move toward the chart until he or she can read the letters. The examiner increases the size and asks the patient to step back until the letters can no longer be read. This process is repeated until the examination chair is reached, at which point the patient is often seeing optotypes that are smaller than those seen initially.

**“Visual aids”** The patient is given a trial frame to wear that has multiple lenses equaling the correct prescription but is told that that they are “special” magnifying lenses that might enable improved vision. Small ( $\frac{1}{8}$  D) plus and minus lenses or small cylinders are added and subtracted while the patient is asked how many letters are visible and what shape they are. The potential acuity meter can also be presented as a means of “bypassing the visual block.” Improvement in either case suggests a functional symptom.

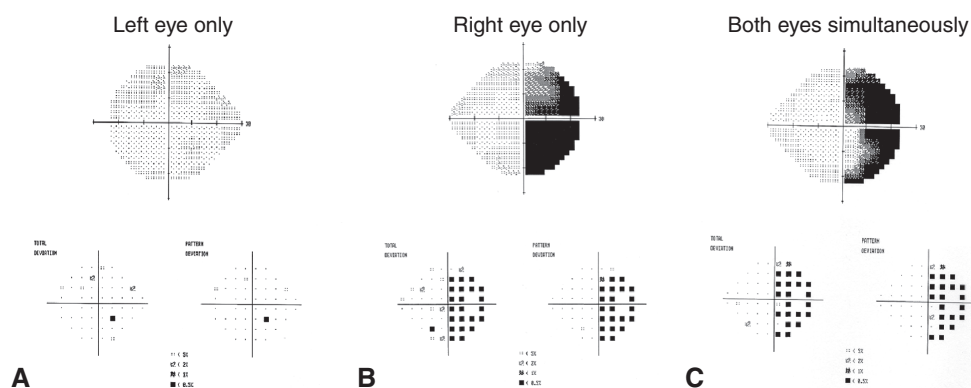
**Use of alternative charts** Patients may be able to see substantially better by a switch in optotypes. For example, a patient who is unable to read type smaller than 20/200 using standard optotypes might read much better from a tumbling E chart or a chart with numbers. Discrepancy in visual acuity measured using different optotypes and not accounted for by literacy or by the patient's ability to recognize letters or numbers different from his or her native language suggests a functional visual symptom.

**Specialty charts** Specialty charts with a top line whose optotype size is 50 instead of 400 are available. Patients who say they can read only the “top line” immediately improve their resolution by 4 lines. Alternatively, the standard chart may be moved farther away. A minimized near card or zoomed out near visual acuity card on a smartphone can achieve a similar effect.

### Visual field defect

Patients occasionally report difficulty seeing on 1 side, although this symptom is less common than visual acuity loss. The problem may be in both eyes but is more commonly in 1 eye with nonspecific constrictions.

**Automated perimetry testing** In general, this type of testing is not helpful in distinguishing ophthalmic or neurologic disease–related visual field loss from functional visual field loss. The machines are quite easy to fool; if motivated, an observant patient can reproduce homonymous visual field defects, altitudinal defects, or even arcuate and central scotomata. Nonetheless, central scotomata are extremely rare in functional vision loss and warrant further evaluation. There are no characteristic changes in automated perimetry testing results that would confirm the suspicion of a functional deficit. However, automated perimetry testing might be useful in a patient with a monocular defect that appears to respect the vertical midline, which is an unusual situation. If repeating the visual field test with both eyes open produces an incomplete defect or a defect similar to that produced by the eye with reported visual field loss, then the symptom is functional (Fig 14-6).



**Figure 14-6** Functional unilateral temporal visual field defect. A 33-year-old man reported decreased vision temporally in the right eye after being in a motor vehicle accident. Automated perimetry testing demonstrates a normal field in the left eye (**A**) and a temporal defect in the right eye (**B**). Visual field testing performed with both eyes open (**C**) demonstrates persistence of the visual field defect, supporting a functional basis for the visual complaint. (Courtesy of Karl C. Golnik, MD.)

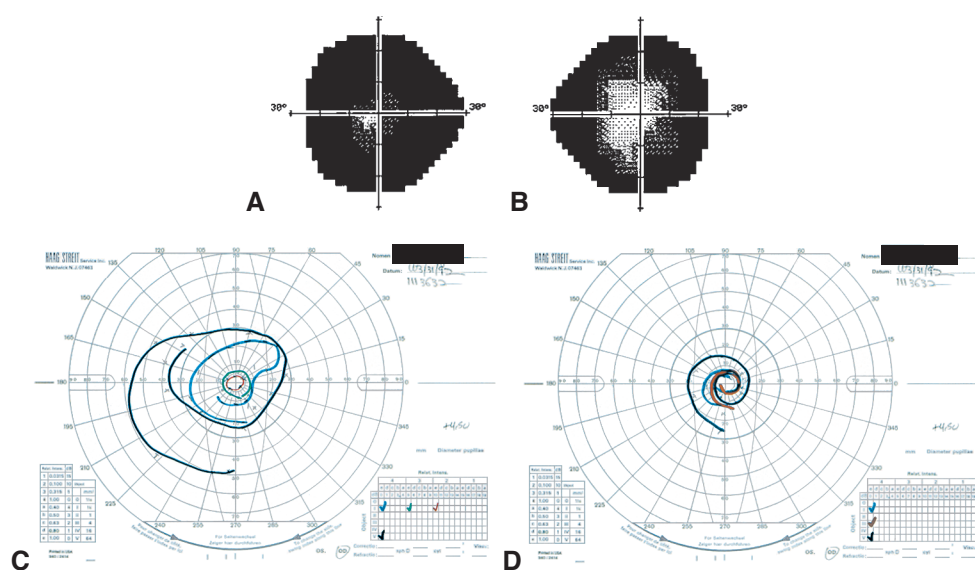


Frisen L. Identification of functional visual field loss by automated static perimetry. *Acta Ophthalmol.* 2014;92(8):805–809.

**Confrontation testing** This test is useful in the case of a dense visual field defect. The area where the patient cannot see is carefully identified. Later, the patient is tested for “motility.” As part of this examination, stimuli are placed in various areas of the patient’s peripheral field, including those areas where the patient could not see. Accurate saccades to these nonauditory targets indicate an intact visual field.

In some cases, confrontation testing (“silent visual fields”) might initially appear to confirm a dense visual field defect. The patient is subsequently asked to count fingers in the nonseeing field and is instructed to report “none” when no fingers are seen. As the test progresses, the examiner begins showing fingers without saying anything. A response of “none” each time the fingers are put up confirms vision in that area.

**Kinetic perimetry testing** In manual kinetic perimetry (Goldmann) testing, the visual field is tested continuously in a clockwise or counterclockwise direction starting with the I4e stimulus. A common functional response shows a spiraling isopter getting closer and closer to fixation as testing continues. As larger stimuli (III4e and V4e) are employed, there is often further constriction, resulting in overlapping isopters (Fig 14-7). The latter can also be detected with automated kinetic perimetry. It is important to make sure there is no step across the vertical or nasal horizontal midline; a step across the midline may indicate that neurologic or ophthalmic disease is contributing to the visual field abnormality.



**Figure 14-7** Functional bilateral constricted visual field defects. A 59-year-old woman reported 1 year of headaches. **A and B**, Automated static perimetry using a V-sized test object demonstrated severe constriction. **C and D**, Subsequent kinetic perimetry visual field testing revealed crossing and spiraling isopters, findings that are inconsistent with ophthalmic or neurologic disease. (Courtesy of Steven A. Newman, MD.)

**Tangent screen testing** The patient is tested with a sized (typically 9-mm white) stimulus at a particular distance (typically 1 m). The areas of patient response are marked and the patient is moved back to twice the initial distance (typically 2 m). The test is then repeated using a double-sized (typically 18-mm white) stimulus. The visual field should expand to twice the original size. Failure to expand (tubular or gun-barrel field) is not consistent with neurologic or ophthalmic disease and indicates a functional component to the visual field constriction (Fig 14-8).

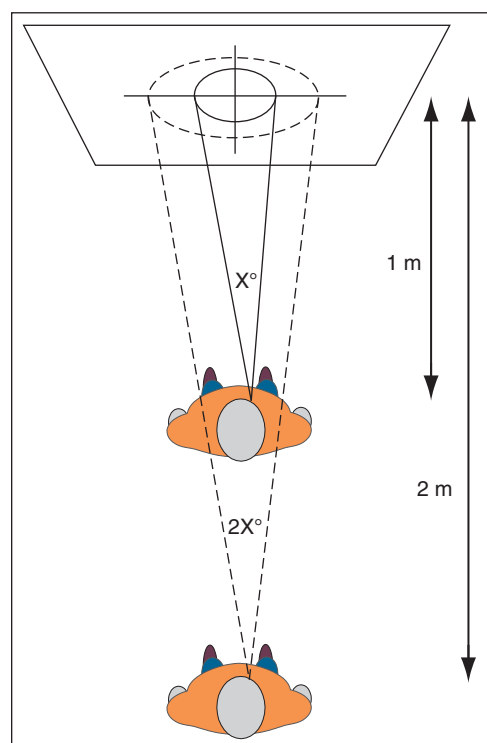
## Ocular Motility and Alignment

### *Voluntary flutter (“nystagmus”)*

Voluntary flutter, which is sometimes misdiagnosed as nystagmus, is characterized by irregular, brief fatigable bursts of rapid-frequency and low-amplitude eye movements with no slow phase. See Chapter 10 for further discussion and Video 10-14, which demonstrates voluntary nystagmus.

### *Gaze palsy*

Patients may report an inability to move the eyes horizontally or vertically. Often by observing patient behavior outside the formal ocular motility examination the clinician can identify better movement capability. Functional gaze palsies may be overcome by a variety of maneuvers or tests, such as oculcephalic reflex (doll’s head phenomenon), OKN drum,



**Figure 14-8** The tangent visual field test at 1 and 2 meters (m). Normally, the visual field expands upon increasing the testing distance from 1 to 2 m. This is due to the increase in the visual angle from  $X^\circ$  to  $2X^\circ$ . In a patient with functional vision loss, the normal expansion of the visual field is absent, and the field remains constricted despite the increase in testing distance. (Based on an illustration by Swaraj Bose, MD.)

mirror tracking, and inner ear caloric stimulation. It is important to note that supranuclear palsies due to neurologic disease are also overcome by some of these maneuvers.

### ***Spasm of the near reflex***

Spasm of the near reflex is characterized by episodes of intermittent inappropriate convergence, increased accommodation, and miosis. Patients generally report diplopia and, at times, micropsia. The degree of convergence is variable, ranging from a large esotropia to only 1 eye turning in. This syndrome may be mistaken for unilateral or bilateral cranial nerve (CN) VI palsies, divergence insufficiency, horizontal gaze paresis, or ocular myasthenia gravis. Variability of the eye movements, miosis with convergent eye movements, and lack of other neuro-ophthalmic abnormalities are clues that can help the examiner reach the correct diagnosis. Further, when ductions are examined with 1 eye occluded or with oculocephalic testing, both eyes demonstrate full abduction, and the miosis observed with the eyes in an esotropic position immediately resolves. Although isolated spasm of the near reflex is seldom related to neurologic disease, it has been associated with head trauma and with lesions at the junction of the diencephalon and mesencephalon, thalamus, lower brainstem, and cerebellum, such as Chiari type I malformation, posterior fossa tumors, and pituitary tumors.

Goldstein JH, Schneekloth BB. Spasm of the near reflex: a spectrum of anomalies.  
*Surv Ophthalmol.* 1996;40(4):269–278.

## **Pupils and Accommodation**

### ***Fixed, dilated pupil***

Few patients provoke more concern regarding a potentially life-threatening neurologic condition than those with headaches and a fixed, dilated pupil. The differential diagnosis can be narrowed to pharmacologic blockade, CN III palsy, and Adie pupil. *Pharmacologic blockade* can occur because of inadvertent or purposeful application of mydriatic or cycloplegic eyedrops; it can also occur after touching the eyes with fingers contaminated through use of a scopolamine patch or touching certain plants that contain parasympatholytic chemicals (see Chapter 11). Failure of an enlarged pupil to constrict after instillation of pilocarpine 1% supports a diagnosis of pharmacologic blockade.

### ***Changes in pupil size***

Intermittent miosis occurs in spasm of the near reflex (discussed earlier), accompanied by esotropia and accommodation. Widely dilated pupils may be observed in young patients, most likely caused by increased levels of circulating catecholamines. A few patients are able to voluntarily dilate both pupils.

### ***Changes in accommodation***

Weakness or paralysis of accommodation sometimes occurs, primarily in children and young adults. Patients may report an inability to read clearly even when using an appropriate plus lens. If a patient with normal distance vision is unable to read despite appropriate near-vision correction, a functional symptom is possible. Such patients should be carefully examined for posterior subcapsular cataract, which can disproportionately affect near vision owing to accommodation-induced miosis.

Spasm of accommodation can be observed with spasm of the near reflex. Patients may report blurred distance vision and often can produce 8–10 D of myopia. Refraction with and without cycloplegia during the period of spasm establishes the presence of the induced myopia.

## **Eyelid Position and Function**

### ***Ptosis***

Eyelid “droop” from functional causes can usually be distinguished by the position of the brow. In a patient with mechanical or neurologic ptosis, the brow is usually elevated as the patient tries to widen the palpebral fissure. With overactivity of the orbicularis oculi muscle driving functional ptosis, the brow is lowered.

Patients with functional ptosis generally cannot simultaneously elevate the eye and maintain a drooping eyelid. Thus, with upward gaze, the ptosis will “resolve.” In cases where the patient will not look up on command, the examiner can use his or her thumb to manually elevate the ptotic eyelid and ask the patient to look upward. If the patient looks up, the examiner then slowly moves the thumb away. If the ptosis returns, the condition may well have a basis in neurologic disease; if it “resolves,” it is a functional symptom.

### ***Eyelid closure***

Functional eyelid closure or spasm can be unilateral or bilateral and typically occurs in children and young adults. It may be associated with functional ptosis. Pressure over the supraorbital notch is often useful in raising the eyelids.

## **Management of the Patient With Functional Neurological Symptom and Related Disorders**

---

In all patients with functional neurological symptom and related disorders, diagnosis and treatment of any comorbid psychiatric disorders is important, typically in conjunction with the patient’s primary care provider, psychiatrist, or psychologist.

### **Functional Neurological Symptom (Conversion) Disorder**

After a detailed history is taken and a thorough examination performed, it is helpful if the clinician clearly documents (1) findings that indicate damage to the visual system caused by known ophthalmic or neurologic disease, if any; and (2) the symptoms that are due to those findings. In addition, the clinician should highlight specific findings from the clinical examination and tests that demonstrate inconsistencies and diagnose a functional etiology. The diagnosis is best presented to the patient as one of inclusion—“I think you have functional neurological symptom disorder”—rather than exclusion (ie, a list of conditions that the patient does not have).

Patients with functional neurological symptom disorder are first managed with education about the condition. It is important to take the symptoms and the distress they cause seriously. The clinician can explain that the problem is one of neurologic dysfunction

rather than structural damage and detail the basis of that conclusion. Reassurance can be provided regarding the structural integrity of the visual system and the potential for recovery. Patients can be actively engaged to work on recovering from their symptoms. For example, children may be encouraged through the prescription of “eye rest”—perhaps, by limiting the use of electronic technology and entertainment devices. Often, particularly in children, the symptoms will improve or resolve after 1 or 2 follow-up visits. Follow-up visits are important to show support, assess understanding, answer questions, and confirm the diagnosis even if the patient is referred to another provider for evaluation and management.

For patients who do not respond to education, psychotherapy, in particular cognitive behavioral therapy, can be helpful. Other approaches include medications, hypnosis, and multidisciplinary inpatient programs in collaboration with psychiatrists and psychologists.

For patients with combined neurologic or ophthalmic disease and functional neurological symptom disorder (functional overlay), it is best to acknowledge both problems and treat each appropriately. Finally, it is always important to monitor a patient who appears to have a functional visual symptom. In rare cases, an ophthalmic or neurologic disorder becomes apparent later and can be managed appropriately.

Leavitt JA. Diagnosis and management of functional visual deficits. *Curr Treat Options Neurol.* 2006;8(1):45–51.

Scott JA, Egan RA. Prevalence of organic neuro-ophthalmologic disease in patients with functional visual loss. *Am J Ophthalmol.* 2003;135(5):670–675.

Stone J, Carson A, Sharpe M. Functional symptoms in neurology: management. *J Neurol Neurosurg Psychiatry.* 2005;76(Suppl 1):13–21.

## Somatic Symptom Disorder

Education is an important part of managing the patient with somatic symptom disorder related to visual symptoms, including those due to neurologic or ophthalmic disease. This includes establishing an honest partnership with the patient by acknowledging the symptoms, admitting where there is uncertainty, explaining that some people experience symptoms differently owing to prior experiences or stress, and confirming that serious causes have been excluded or identified. Establishing a partnership with other treating providers is important because many patients with somatic symptom disorder have many doctors. In particular, the primary care provider can play an important role in integrating specialist information with which to counsel and reassure the patient. Most recommended treatment approaches are centered with the primary care provider.

The primary goal is to improve the patient’s ability to cope with symptoms. Scheduling regular follow-up visits is helpful to manage patients’ distress related to their visual symptoms. Limiting diagnostic testing and referrals is important because these address neither the symptoms nor the related anxiety. Although patients with somatic symptom disorder are often resistant to psychiatric care or psychotherapy, this can be pursued in those for whom primary care–centered approaches are insufficient.

Levenson JL. Somatic symptom disorder: treatment. In: *UpToDate*. Dimsdale J, Solomon D (eds). Updated September 19, 2021. Accessed November 15, 2021. [www.uptodate.com](http://www.uptodate.com)

# The Patient With a Systemic Disease



*This chapter includes a related video. Go to [www.aaao.org/bcscvideo\\_section05](http://www.aaao.org/bcscvideo_section05) or scan the QR code in the text to access this content.*

## Highlights

---

- Tocilizumab is an interleukin-6 antagonist that can prevent recurrence of giant cell arteritis during corticosteroid taper.
- Neuromyelitis optica spectrum disorder and myelin oligodendrocyte glycoprotein immunoglobulin G-associated disorder are considered in the differential diagnosis of demyelinating optic neuritis.
- Symptoms of vertebrobasilar transient ischemic attacks include diplopia, ataxia, loss or perturbations of vision, dysphagia, dysarthria, and drop attacks.
- Acute onset of anterior or posterior circulation transient ischemic attacks or fixed neurologic abnormalities should be evaluated emergently by a neurologist.

## Introduction

---

Certain neurologic and medical disorders affect vision with such frequency and are encountered in ophthalmic clinical practice often enough that they deserve special mention. Although a comprehensive discussion of these diseases is not possible here, this chapter addresses many aspects of their presentation and management that ophthalmologists should be familiar with.

## Immunologic Disorders

---

Of the various immune system-mediated disorders that produce neuro-ophthalmic signs and symptoms, giant cell arteritis, multiple sclerosis, myasthenia gravis, thyroid eye disease, and sarcoidosis are the most common.



## Giant Cell Arteritis

Giant cell arteritis (GCA), or *temporal arteritis*, is a systemic inflammatory granulomatous vasculitis that involves large and medium-sized arteries and can lead to permanent vision loss. It is part of a spectrum that includes polymyalgia rheumatica and affects almost exclusively those older than 50 years. The incidence of GCA increases with age; it is 20 times more common in the ninth decade of life than in the sixth decade. Women are 2–4 times more likely to experience GCA than men are, and Whites, especially those of Northern European and Scandinavian descent, are commonly affected.

To prevent or limit permanent vision loss from GCA, early diagnosis and treatment are critical.

### ***Clinical presentation of giant cell arteritis***

Systemic symptoms of GCA include headache and tenderness of the temporal artery or scalp. Jaw or tongue claudication (ie, a cramping pain that develops with extended chewing or talking) is the most specific symptom of the disorder, but malaise; anorexia and weight loss; fever; and neck, ear, and muscle pain may also be reported. Visual symptoms may include diplopia or transient or permanent vision loss. Systemic sequelae can include cerebrovascular ischemia, myocardial infarction, and aortic aneurysm or dissection.

The most common cause of vision loss in GCA is *arteritic anterior ischemic optic neuropathy* (AAION) (see Chapter 4, Fig 4-11), but central retinal artery occlusion (CRAO), cilioretinal artery occlusion, posterior ischemic optic neuropathy, choroidal infarction, ocular ischemic syndrome, and orbital ischemia also occur. In addition, ischemia of the ocular motor cranial nerves (CNs), extraocular muscles, or brainstem can result in transient or constant diplopia. Because it can be difficult to clinically differentiate transient visual loss due to thromboembolic disease from loss due to GCA, it is important that all patients older than 50 years undergo a workup for both (see Chapter 6).

### ***Diagnosis of giant cell arteritis***

When evaluating patients older than 50 years with a suggestive clinical presentation, a high level of suspicion of GCA is paramount. Diagnostic evaluation begins with testing of erythrocyte sedimentation rate (ESR), C-reactive protein (CRP) level, and complete blood count (CBC). Most cases of GCA show marked elevation in ESR (Westergren mean 70 mm/hour; often >100 mm/hour). However, the level may be normal in up to 16% of cases. The ESR also rises with anemia and with increasing age (ie, levels above a laboratory's upper limit of normal are common in patients older than 70 years without arteritis). A more accurate estimate of the upper normal value for the Westergren ESR can be obtained by using these formulas:  $[\text{age in years}]/2$  (*men*) or  $[\text{age} + 10]/2$  (*women*). CRP level, which is typically obtained in conjunction with the ESR, may be more specific for inflammation and less affected by increasing age and anemia, enhancing diagnostic accuracy. In addition, a CBC may reveal increased platelet count (ie, thrombocytosis), suggesting active GCA. A normochromic normocytic anemia may be present.

Whenever clinical suspicion or laboratory studies suggest GCA, corticosteroids should be initiated immediately and a temporal artery biopsy (TAB) performed within 10–14 days, ideally at a site of localized tenderness and/or on the side of the vision loss. Characteristic

pathologic findings are mononuclear inflammation with giant cells and loss of the internal elastic lamina, although giant cells are not required for the diagnosis (see BCSC Section 4, *Ophthalmic Pathology and Intraocular Tumors*, Chapter 15). Results from a unilateral TAB are falsely negative in approximately 9%–13% of cases. Factors that may produce a false-negative result include discontinuous arterial involvement (“skip areas”), missed lesions on pathology interpretation, prolonged corticosteroid use, or inadequate tissue collection (<2 cm long).

When the index of suspicion for GCA remains high after a negative biopsy result, a contralateral TAB is typically performed. Other imaging strategies, such as color Doppler ultrasonography, positron emission tomography (PET), and magnetic resonance imaging (MRI), may provide additional diagnostic clues. Vascular imaging of the chest may identify concomitant aortitis and other large-vessel inflammation, which also explains the increased risk of aortic dissection in patients with GCA. However, TAB remains the gold standard for GCA diagnosis because it excludes disorders with similar clinical presentations, such as amyloidosis or calciphylaxis in end-stage renal disease; it also has an essentially zero false-positive rate, thus avoiding unwarranted long-term corticosteroid treatment.

El-Dairi MA, Chang L, Proia AD, Cummings TJ, Stinnett SS, Bhatti MT. Diagnostic algorithm for patients with suspected giant cell arteritis. *J Neuroophthalmol*. 2015;35(3):246–253.

### **Treatment of giant cell arteritis**

Corticosteroids are the mainstay of treatment of GCA and should be initiated immediately when the disease is suspected. Left untreated, approximately 50% of patients with GCA and vision loss in 1 eye lose vision in the opposite eye within 7 days. In patients with acute vision loss, intravenous (IV) methylprednisolone (1 g/day for the first 3–5 days) is recommended. However, if IV therapy is not available, oral prednisone should be initiated without delay. For patients with suspected GCA but no vision loss, oral prednisone 1 mg/kg/day may be sufficient. Patients with transient visual loss or diplopia should be treated as aggressively as patients with sustained visual loss. Because GCA is a systemic disease, treatment is also required for patients with severe bilateral vision loss. The clinical response to corticosteroids is often dramatic, with symptoms reduced within several hours. However, visual recovery is not expected.

Although there is no consensus on tapering protocols, corticosteroids are generally tapered slowly, depending on response; administration should be decreased to zero over 12–18 months provided that GCA symptoms and signs or laboratory markers of inflammation do not recur. Slow, careful withdrawal from corticosteroid treatment can help prevent recurrent or contralateral optic nerve involvement, which has a reported risk of 7%. For patients at high risk of glucocorticoid toxicity and those receiving concomitant glucocorticoid-sparing therapy, a more rapid dose reduction can be considered. The number of relapses during corticosteroid tapering may also be reduced with use of tocilizumab, an interleukin-6 receptor alpha inhibitor that is administered as subcutaneous injections.

Patients undergoing long-term corticosteroid therapy should be monitored and treated as necessary for gastrointestinal issues, osteopenia and osteoporosis, diabetes mellitus, hypertension, infections, and mood disturbance. Patients with GCA are also at risk for thoracic

and aortic aneurysms, as well as cerebrovascular and cardiovascular ischemia; thus, their cases are usually co-managed with a rheumatologist or internist who can assess the risk and benefits of prophylactic low-dose aspirin use.

Mackie SL, DeJaco C, Appenzeller S, et al. British Society for Rheumatology guideline on diagnosis and treatment of giant cell arteritis. *Rheumatology*. 2020;59(3):e1–e23.

Oray M, Abu Samra K, Ebrahimiadib N, Meese H, Foster CS. Long-term side effects of glucocorticoids. *Expert Opin Drug Saf*. 2016;15(4):457–465.

Stone JH, Tuckwell K, Dimonaco S, et al. Trial of tocilizumab in giant-cell arteritis. *N Engl J Med*. 2017;377(4):317–328.

## Multiple Sclerosis

Multiple sclerosis (MS) is an inflammatory neurodegenerative disorder of the central nervous system (CNS) that causes progressive neurologic disability over time. Patients with MS frequently have visual symptoms, and the ophthalmologist is often the first physician consulted. Familiarity with both the ocular and the neurologic consequences of MS is important for guiding the ophthalmologist to the appropriate diagnosis. Related disorders such as neuromyelitis optica spectrum disorder and myelin oligodendrocyte glycoprotein immunoglobulin G–associated disorder are discussed in the following sections and in Chapter 4.

### ***Epidemiology and genetics of multiple sclerosis***

The prevalence of MS varies widely. It is more common in Whites and in individuals living in latitudes more than 40° from the equator and is 2–3 times more likely to affect women than men. MS is relatively uncommon in children younger than 10 years; the incidence is highest among young adults (25–40 years). However, onset after the age of 50 years is not rare.

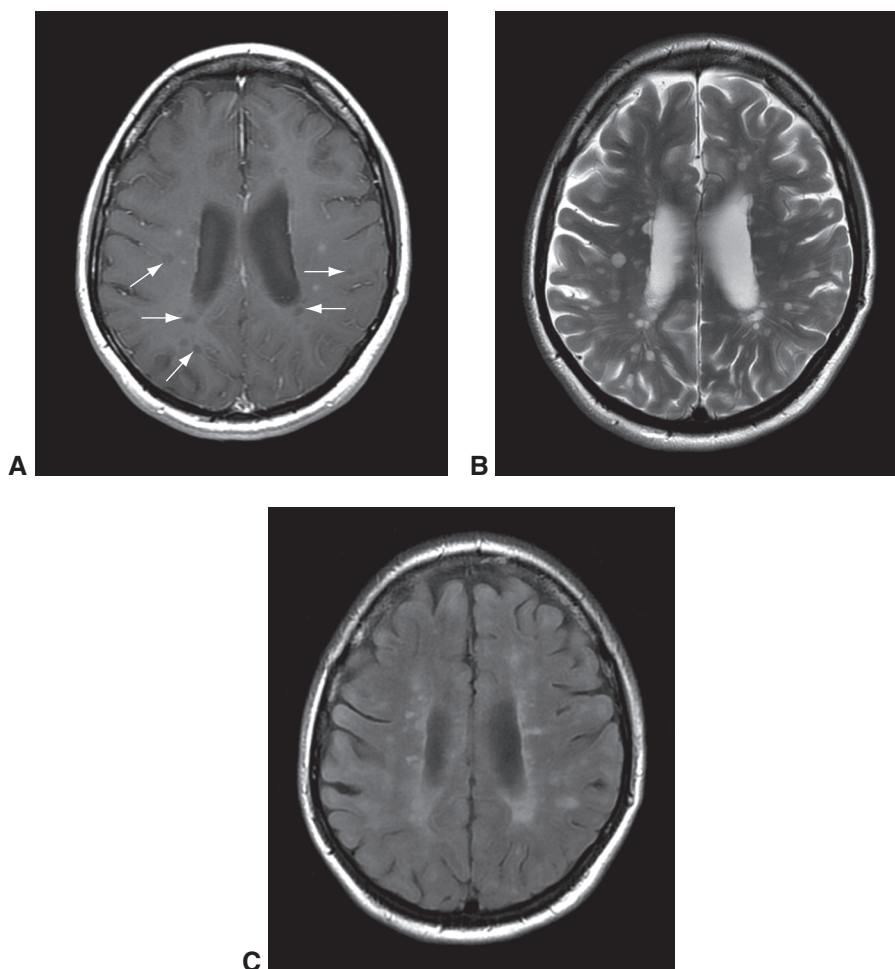
The cause of MS remains unknown. Vitamin D deficiency is a risk factor and is thought to underlie the relationship of MS with latitude. The risk of MS is also significantly increased in first-degree relatives of patients with the disease. Although there is a strong association with some HLA-DR antigens, the genetic associations are multifactorial.

### ***Course and prognosis of multiple sclerosis***

Initially, most patients with MS (85%) experience a relapsing-remitting clinical course, with episodes of neurologic dysfunction separated by *asymptomatic* intervals of months or years. However, MRI studies have revealed that the pathologic disease burden in the CNS accumulates even in the absence of clinical activity. Within 10 years of disease onset, approximately 50% of patients with relapsing-remitting disease exhibit a slow, seemingly continuous deterioration in neurologic status (secondary progressive form of MS). In the other 15% of patients, MS progresses inexorably from onset with no recognizable attacks (primary progressive form). Near total disability and, in rare instances, death within 1–2 years of onset, may result after a fulminant course. In approximately 5%–10% of patients with MS, the disease course is relatively benign, without serious disability or reduced life span.

### ***Pathology in multiple sclerosis***

Although MS is classically considered a demyelinating disease, axonal damage occurs early and is an integral part of the disease process. This axonal loss manifests as “black holes”



**Figure 15-1** Axial magnetic resonance imaging (MRI) scans from a patient with multiple sclerosis show demyelinating plaques. **A**, T1-weighted postgadolinium MRI scan demonstrates enhancing white matter lesions bilaterally, as well as “black holes” (arrows). **B**, T2-weighted MRI scan shows periventricular, multifocal, hyperintense white matter lesions consistent with demyelination. **C**, A fluid-attenuated inversion recovery (FLAIR) scan confirms periventricular white matter lesions. (Reprinted with permission from Slack. Lee AG, Brazis PW, Kline LB. Curbside Consultation in Neuro-Ophthalmology: 49 Clinical Questions. Slack; 2009.)

on T1-weighted MRI sequences (Fig 15-1). Myelin destruction is associated with local perivascular mononuclear cell infiltration, myelin removal by macrophages, and astrocytic proliferation with production of glial fibrils. The term *multiple sclerosis* stems from the presence of these numerous gliotic (sclerotic) plaque lesions. The plaques are often situated in the white matter adjacent to the ventricles, the optic nerves and chiasm, the corpus callosum, and the spinal cord and throughout the brainstem and cerebellar peduncles.

Criste G, Trapp B, Dutta R. Axonal loss in multiple sclerosis: causes and mechanisms. *Handb Clin Neurol*. 2014;122:101–113.

### ***Clinical presentation of multiple sclerosis***

Early symptoms of MS are often evanescent, benign, and/or lacking objective neurologic findings, leading patients to ignore episodes or fail to connect them. In contrast, significant episodes typically last for weeks or months.

Ocular symptomatology is commonly part of the clinical picture of MS (see the following sections). The physician should ask specifically about episodes of loss of or abnormal vision, eye pain, and diplopia. Nonocular signs and symptoms precede, follow, or coincide with the ocular signs. The cerebellum, brainstem, and spinal cord may be affected individually or simultaneously, thus producing single or multiple symptoms. Hence, the physician should ask about *nonocular* symptoms as well:

- *cerebellar dysfunction*: ataxia, dysarthria, intention tremor, truncal or head titubation, or dysmetria (sometimes described by the patient as poor depth perception)
- *mental changes*: emotional instability, depression, irritability, or fatigue; later in the course, cognitive dysfunction
- *motor symptoms*: extremity weakness, facial weakness, hemiparesis, or paraplegia
- *sensory symptoms*: paresthesias of the face or body (especially in a bandlike distribution around the trunk), Lhermitte sign (an electric shock–like sensation in the limbs and trunk produced by neck flexion), or pain (occasionally trigeminal neuralgia)
- *sphincter disturbances*: frequency, urgency, hesitancy, or incontinence; urinary retention that leads to urinary tract infection

### ***Optic neuritis in multiple sclerosis***

Optic neuritis is a presenting symptom in 25% of patients with MS, and symptoms of optic neuritis occur at some point in 75% of patients (see Chapter 4 for a discussion of the clinical signs and symptoms of optic neuritis). In addition, evidence of optic nerve involvement (as demonstrated by an abnormal visual evoked response) appears in 90% of patients with MS. Furthermore, autopsy studies show anterior visual pathway demyelination in virtually all patients with clinically definite MS.

Even after recovering from vision loss brought on by demyelinating optic neuritis, patients may experience transient deterioration of vision during exercise or with small elevations in body temperature, for example, from bathing (Uhthoff phenomenon). Some patients with optic neuritis also report phosphenes (bright flashes of light) with movement of the affected eye or photisms (light induced by noise, smell, taste, or touch). There is increasing interest in the use of optical coherence tomography (OCT) to measure the peripapillary retinal nerve fiber and ganglion cell layers in MS as a marker for neuronal damage.

Compared with the general population, patients with optic neuritis are at increased risk of developing MS. The 15-year follow-up study of the Optic Neuritis Treatment Trial (ONTT) showed that the strongest predictive factor for developing MS was the presence or absence of characteristic plaque lesions on an MRI scan of the brain obtained during an episode of optic neuritis at study entry. Overall, clinically definite MS developed in 50% of ONTT participants during the 15-year follow-up period. However, the probability of developing clinically definite MS ranged from 25% for patients with no lesions on brain MRI at study entry to 72% of patients with 1 or more lesions. Patients with a history of nonspecific neurologic symptoms were at higher risk of MS than those without symptoms.

Cerebrospinal fluid (CSF) analysis showed that oligoclonal banding was predictive for the future development of MS, but only in patients with a normal MRI scan at study entry.

Costello FE, Klistorner A, Kardon R. Optical coherence tomography in the diagnosis and management of optic neuritis and multiple sclerosis. *Ophthalmic Surg Lasers Imaging*. 2011;42(Suppl):S28–S40.

Optic Neuritis Study Group. Multiple sclerosis risk after optic neuritis: final optic neuritis treatment trial follow-up. *Arch Neurol*. 2008;65(6):727–732.

Rolak LA, Beck RW, Paty DW, Tourtellotte WW, Whitaker JN, Rudick RA. Cerebrospinal fluid in acute optic neuritis: experience of the Optic Neuritis Treatment Trial. *Neurology*. 1996;46(2):368–372.

### ***Ocular and retinal abnormalities in multiple sclerosis***

Uveitis is 10 times more common in patients with MS than in the general population, with the frequency of uveitis ranging from 0.4% to 28.5% depending on the study. MS-related uveitis generally presents as intermediate uveitis (including pars planitis), and mild vitritis with periphlebitis is common. Ocular inflammation may develop concurrent with, before, or after the development of neurologic signs and symptoms. See Chapter 3 in this volume for a discussion of retinal nerve fiber layer defects and BCSC Section 9, *Uveitis and Ocular Inflammation*, for additional discussion of MS-related uveitis.

Filippi M, Bar-Or A, Piehl F, et al. Multiple sclerosis. *Nat Rev Dis Primers*. 2018;4(1):43.

Messenger W, Hildebrandt L, Mackensen F, Suhler E, Becker M, Rosenbaum JT.

Characterisation of uveitis in association with multiple sclerosis. *Br J Ophthalmol*. 2015;99(2):205–209.

### ***Chiasmal and retrochiasmal abnormalities in multiple sclerosis***

White matter within the optic chiasm, optic tracts, and optic radiations is frequently involved pathologically in MS lesions. Lesions in these areas follow a recovery pattern similar to that of optic neuritis. In the ONTT, chiasmal or retrochiasmal visual field defects were observed in 13.2% of patients after 1 year of follow-up (see Chapter 4, Fig 4-30). When a patient with MS who is using natalizumab presents with homonymous visual field defects, progressive multifocal leukoencephalopathy (PML) should be considered (see Table 15-1 and the section on PML later in this chapter).

### ***Ocular motility disturbances in multiple sclerosis***

Diplopia is a frequent MS symptom. Motility abnormalities resulting from MS are typically localized to the supranuclear, nuclear, and fascicular portions of the ocular motor system. Internuclear ophthalmoplegia may present with exotropia in the primary position and unilateral or bilateral impaired adduction (ie, wall-eyed, bilateral internuclear ophthalmoplegia, or WEBINO; see Chapter 8) and is highly suggestive of MS in someone younger than 50 years. Other signs include complete or partial paralysis of horizontal or vertical gaze or a skew deviation (vertical misalignment not attributable to a single CN or muscle dysfunction). Although uncommon, MS should be considered in a young adult with an isolated ocular motor CN palsy and no history of trauma. Because ocular motor palsies most likely reflect fascicular involvement, they are frequently accompanied by other brainstem findings. CN VI involvement is most commonly reported, but CN III or CN IV paresis has also been



described. Rarely, ocular motility disturbances can be a result of brainstem PML associated with natalizumab treatment.

Nystagmus is frequently present in MS. It may be horizontal, rotary, or vertical, and both pendular and jerk types may occur. Concomitant vertical and horizontal nystagmus occurring out of phase produces circular or elliptical eye movements that are highly suggestive of MS. Common cerebellar eye findings include rebound nystagmus, fixation instability (macrosaccadic oscillations), saccadic dysmetria, and abnormal pursuit movements. Occasionally, MS lesions produce dorsal midbrain (Parinaud) syndrome. Patients with eye movement abnormalities also typically report diplopia, blurred vision, or oscillopsia. See Chapters 8, 9, and 10 for further discussion of ocular motility disorders.

### **Diagnosis of multiple sclerosis**

Multiple sclerosis is diagnosed using the 2017 modifications to the McDonald criteria, which are based on a combination of clinical history and presentation along with neuroradiologic imaging, with or without the presence of CSF oligoclonal immunoglobulin G (IgG) bands. Even an insidious neurologic progression suggestive of MS can lead to a definite diagnosis if appropriate paraclinical abnormalities are present. However, in the absence of other clinical or laboratory manifestations, recurrent optic neuritis is insufficient for diagnosing MS.

Thompson AJ, Banwell BL, Barkhof F, et al. Diagnosis of multiple sclerosis: 2017 revisions of the McDonald criteria. *Lancet Neurol*. 2018;17(2):162–173.

**Laboratory evaluation of multiple sclerosis** No test unequivocally establishes the presence of MS, which remains a *clinical* diagnosis. The CSF in patients with definite MS is abnormal in more than 90% of cases. The most common abnormalities are the presence of oligoclonal IgG bands (in CSF but not in serum), elevated IgG level, and elevated IgG/albumin index. None of these findings, however, is specific for MS.

**Neuroimaging in multiple sclerosis** MRI is particularly sensitive for identifying white matter plaques in the CNS and is far superior to computed tomography (CT) for showing the posterior fossa and spinal cord (see Fig 15-1; see also Chapter 2, Fig 2-9, and Chapter 4, Fig 4-9). In addition, MRI depicts multiple brain lesions in 85%–95% of patients with clinically definite MS and in 66%–76% of patients with suspected MS. Although the abnormalities that are apparent on MRI are not specific for MS, multifocal lesions that are periventricular and ovoid are most consistent with the condition. In addition, the lesions observed with MRI can fluctuate over time.

Neuroimaging for the diagnosis and management of MS should include MRI with T1-weighted, T2-weighted, *fluid-attenuated inversion recovery* (FLAIR), diffusion-weighted, and gadolinium infusion images. Active lesions will enhance with gadolinium administration, and hypointense regions on T1-weighted scans (black holes) are also a marker of progressive disease. In the optic nerves of patients with symptomatic optic neuritis, lesions are best visualized on MRI with fat suppression techniques and gadolinium infusion (see Chapter 4, Fig 4-9C).

### **Treatment of multiple sclerosis**

There is no cure for MS; however, several therapies slow the disease and help alleviate specific symptoms. As in the management of optic neuritis, high-dose IV corticosteroids are

often used to treat acute exacerbations of MS. In patients at risk of MS or those with newly diagnosed disease, vitamin D deficiency is routinely corrected, although the benefit of such therapy remains unproven.

Disease-modifying therapy (DMT) is typically recommended for long-term treatment of MS. Several studies have also demonstrated the benefits of early DMT initiation in subjects with clinically isolated syndrome at risk of developing MS. In addition, several US Food and Drug Administration (FDA)–approved DMTs are currently available for relapsing forms of the disease (Table 15-1). These drugs, which should be used with caution, are often prescribed by physicians with experience in MS therapy. Novel drugs and combinations of immunomodulating therapies are also being investigated.

Macular edema has been reported in 0.5% of patients treated with fingolimod, a once-daily oral sphingosine-1-phosphate (S1P) receptor modulator approved for the treatment of relapsing MS. Fingolimod-associated macular edema (FAME) is more common in patients with diabetes and uveitis and is more likely to develop within 4 months of treatment initiation; it is best detected by OCT. The macular edema typically resolves upon cessation of fingolimod therapy. Figure 15-2 shows the screening protocol for FAME. Macular edema has also been reported with other S1P receptor modulators and is not unique to fingolimod.

Eckstein C, Bhatti MT. Currently approved and emerging oral therapies in multiple sclerosis: an update for the ophthalmologist. *Surv Ophthalmol.* 2016;61(3):318–332.

Jain N, Bhatti MT. Fingolimod-associated macular edema: incidence, detection, and management. *Neurology.* 2012;78(9):672–680.

Thompson AJ, Baranzini SE, Geurts J, Hemmer B, Ciccarelli O. Multiple sclerosis. *Lancet.* 2018;391(10130):1622–1636.

## **Neuromyelitis Optica Spectrum Disorder and Myelin Oligodendrocyte Glycoprotein Immunoglobulin G–Associated Disorder**

Neuromyelitis optica spectrum disorder (NMOSD) and myelin oligodendrocyte glycoprotein immunoglobulin G–associated disorder (MOGAD) are immune-mediated inflammatory conditions of the CNS that frequently involve the optic nerve and spinal cord. Because of their predilection for a relapsing course and clinical manifestations similar to those of demyelinating optic neuritis, NMOSD and MOGAD are considered in the differential diagnosis of this disease. However, because these distinct conditions have different treatments, early and accurate diagnosis is imperative. Furthermore, some agents used to treat MS may be deleterious to patients with NMOSD and are not effective for MOGAD. A more comprehensive discussion of MOGAD can be found in Chapter 4.

Neuromyelitis optica (NMO; also called Devic disease) is characterized by severe attacks of optic neuritis and longitudinally extensive transverse myelitis. In comparison, NMOSD has other diverse neurologic manifestations that include area postrema syndrome (intractable hiccups, vomiting, and nausea) and brainstem, diencephalic, and cerebral symptoms that may be associated with MRI abnormalities. Both NMO and NMOSD can be associated with serum aquaporin-4 IgG (AQP4-IgG).

NMOSD represents a rare cause of inflammatory white matter disease in North America; however, it accounts for almost 50% of demyelinating disorders in Asia and the West Indies. NMOSD can be differentiated from MS by its distinct clinical, radiographic, pathologic,

**Table 15-1 Multiple Sclerosis Disease-Modifying Therapies and Adverse Effects**

Drug	Route	Multiple Sclerosis Subtype	Dosing Frequency	Adverse Effects
Interferon beta-1a (Avonex)	Intramuscular	RRMS, CIS	Once weekly	Flulike symptoms, liver enzyme changes, bone marrow suppression, thyroid dysfunction
Interferon beta-1a (Rebif)	Subcutaneous	RRMS, CIS	22 µg or 44 µg 3 times weekly	Flulike symptoms, liver enzyme changes, bone marrow suppression, thyroid dysfunction
Interferon beta-1b (Betaseron, Extavia)	Subcutaneous	RRMS, CIS	3 times weekly	Flulike symptoms, liver enzyme changes, bone marrow suppression, thyroid dysfunction
Glatiramer acetate (Copaxone, Glatopa)	Subcutaneous	RRMS, CIS	Once daily (20 mg/mL) or 3 times weekly (40 mg/mL)	Skin irritation, skin lipoatrophy, panic attack–like events
Ofatumumab (Kesimpta)	Subcutaneous	RRMS	Once monthly	Injection site reactions, upper respiratory tract infections, urinary tract infections, headache, reduced IgM
Natalizumab (Tysabri)	Intravenous	RRMS	Once monthly	Nausea, infection, liver dysfunction, PML <sup>a</sup>
Ocrelizumab (Ocrevus)	Intravenous	RRMS, PPMS, SPMS	Every 6 months	Conjunctivitis, respiratory infections, herpes infections
Mitoxantrone (Novantrone)	Intravenous	RRMS, SPMS	Every 3 months	Blue sclera, bone marrow suppression, nausea, arrhythmia, alopecia
Fingolimod (Gilenya)	Oral	RRMS	Once daily	Macular edema, bradyarrhythmia, QT interval prolongation, hypertension, severe varicella-associated complications in nonimmune patients, increased risk of herpes zoster in all patients, PML (rare)
Siponimod (Mayzent)	Oral	RRMS, SPMS	Once daily	Macular edema, leukopenia, bradycardia

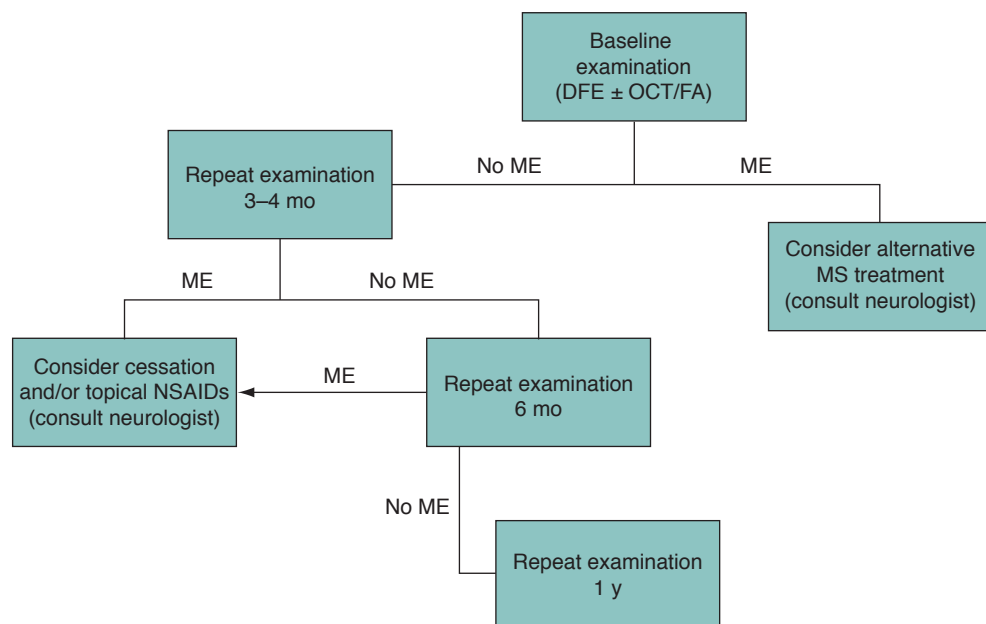
Drug	Route	Multiple Sclerosis Subtype	Dosing Frequency	Adverse Effects
Ozanimod (Zeposia)	Oral	RRMS <sup>b</sup>	Once daily	Macular edema, infections, bradycardia
Dimethyl fumarate (Tecfidera, Vumerity)	Oral	RRMS	Twice daily	Flushing, gastrointestinal distress, lymphopenia (rare), PML (rare)
Teriflunomide (Aubagio)	Oral	RRMS	Once daily	Alopecia, liver dysfunction
Cladribine (Mavenclad)	Oral	RRMS, SPMS	Cycle based	Bone marrow suppression, conjunctivitis, liver injury
Alemtuzumab (Lemtrada)	Intravenous	RRMS	Minimum of 2 cycles (baseline and year 1)	Infusion reactions, mild-moderate infections, thyroid dysfunction, idiopathic thrombocytopenic purpura, anti-glomerular basement membrane disease

CIS = clinically isolated syndrome; PML = progressive multifocal leukoencephalopathy; PPMS = primary progressive multiple sclerosis; RRMS = relapsing-remitting multiple sclerosis; SPMS = secondary progressive multiple sclerosis.

<sup>a</sup> PML risk increases with a history of immunosuppression, John Cunningham virus positivity, and use of the drug for >2 years. Risk for the entire cohort ("all-comers") is approximately 3–4/10,000.

<sup>b</sup> The US Food and Drug Administration has recommended this drug be used only if the patient manifests an inadequate therapeutic response to 2 or more other disease-modifying therapies.

Adapted with permission from Costello F, Burton JM, Lee AG. Neuro-ophthalmologic manifestations of multiple sclerosis (MS). Medscape Drugs & Diseases. Updated January 25, 2021. Accessed November 15, 2021. <http://emedicine.medscape.com/article/1214270-overview>



**Figure 15-2** Proposed screening protocol for fingolimod-associated macular edema. Patients with visual symptoms at any time during treatment, particularly during the initial months, should have an additional eye examination. DFE = dilated fundus examination; FA = fluorescein angiography; ME = macular edema; MS = multiple sclerosis; NSAID = nonsteroidal anti-inflammatory drug; OCT = optical coherence tomography. (Adapted from Jain N, Bhatti MT. Macular edema associated with fingolimod. *EyeNet*. 2012;43–44.)

and serologic features. However, there is significant overlap between NMOSD and MS, and even patients with “typical” optic neuritis should be carefully evaluated for NMOSD. NMOSD is associated with severe visual impairment; early diagnosis and aggressive treatment are important for the best chance of preserving visual and neurologic function.

### ***Clinical presentation of neuromyelitis optica spectrum disorder***

Optic neuritis, the classic ophthalmic manifestation of NMOSD, is typically severe (visual acuity <20/200). The optic chiasm and tracts may be involved, resulting in bitemporal or homonymous hemianopic visual field defects. Recurrent optic neuritis, poor visual outcomes, or concurrent autoimmune disease should also raise concerns for NMOSD-related optic neuritis (see Chapter 4).

Eye movement disorders that can develop secondary to brainstem lesions include nystagmus (upbeat, downbeat, or mixed horizontal-torsional), internuclear ophthalmoplegia, and opsoclonus. Patients with transverse myelitis may present with weakness and numbness of the limbs, deficits in sensation and motor skills, dysfunctional sphincter activities, or dysfunction of the autonomic nervous system.

### ***Diagnosis of neuromyelitis optica spectrum disorder***

In 2015, an international panel published revised diagnostic criteria for NMO and recommended unifying the disorder and related syndromes under the term NMOSD (see Chapter 4, Table 4-5, for NMOSD diagnosis criteria). Concurrently, the ability to diagnose

NMOSD drastically improved with the identification of AQP4-IgG as a serum marker for NMO. The live cell-based assay for AQP4-IgG has a sensitivity and a specificity of 76% and 99.8%, respectively, for NMOSD.

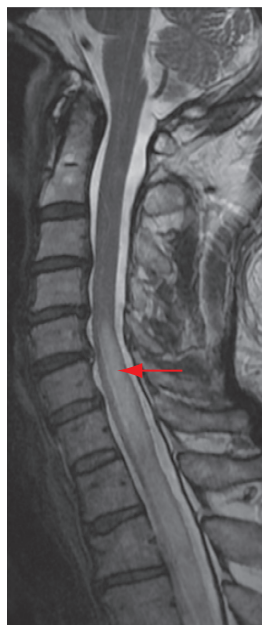
Other CSF findings suggestive of NMOSD include a pleocytosis level  $>50$  cells per microliter, an increased proportion of polymorphonuclear cells, or the presence of eosinophils. In rare instances, AQP4-IgG has been detected in the CSF of seronegative patients.

MRI can facilitate the diagnosis of NMOSD. Conventional MRI shows typical changes resulting from acute NMOSD-related optic neuritis, including optic nerve enlargement and enhancement, as well as increased T2 signal. These changes are often more longitudinally extensive than in MS, involving more than 50% of the nerve length, and are frequently bilateral and may involve the optic chiasm and tracts. At disease onset, MRI of the brain has revealed abnormalities in 43%–70% of patients. NMOSD lesions are typically found surrounding the third ventricle and the cerebral aqueduct (which include the thalamus, hypothalamus, and anterior border of the midbrain), as well as the dorsal brainstem adjacent to the fourth ventricle and the corpus callosum. Extensive and confluent hemispheric white matter lesions can also be seen, occasionally mimicking posterior reversible encephalopathy syndrome (discussed in the later section on pregnancy). Spinal cord MRI typically shows contiguous signal abnormality extending over 3 or more vertebral segments, termed *longitudinally extensive transverse myelitis* (Fig 15-3).

Kim HJ, Paul F, Lana-Peixoto MA, et al. MRI characteristics of neuromyelitis optica spectrum disorder: an international update. *Neurology*. 2015;84(11):1165–1173.

Wingerchuk DM, Banwell B, Bennett JL, et al; International Panel for NMO Diagnosis.

International consensus diagnostic criteria for neuromyelitis optica spectrum disorders. *Neurology*. 2015;85(2):177–189.



**Figure 15-3** Sagittal T2-weighted MRI of the spinal cord in a patient with neuromyelitis optica spectrum disorder depicting a T2-hyperintense lesion over more than 3 vertebral segments (arrow). (Courtesy of John J. Chen, MD, PhD.)



### ***Treatment of neuromyelitis optica spectrum disorder***

Treatment of NMOSD includes managing acute attacks and preventing future exacerbations. For patients experiencing an acute attack, IV methylprednisolone therapy (1000 mg daily for 3–5 days) remains the first-line therapy. When there is no significant clinical improvement with corticosteroids, plasma exchange has been effective and should be considered. IV immunoglobulin (IVIG) has also been used to treat acute NMOSD exacerbations and prevent relapses. Immunosuppressive therapy (eg, azathioprine, mycophenolate, or rituximab) is required to lower the frequency and severity of future exacerbations after an initial attack.

In 2020, the FDA approved eculizumab, inebilizumab, and satralizumab as immunosuppressive/immunomodulator treatments for NMOSD after randomized clinical trials demonstrated their efficacy in reducing relapses. Several disease-modifying agents frequently used to treat MS (eg, interferon-beta, natalizumab, and fingolimod) have been studied, but results showed they may increase the relapse rate in patients with NMOSD. This phenomenon likely reflects the different immunobiology of these conditions and emphasizes the importance of accurate diagnosis to ensure proper treatment.

Kowarik MC, Soltys J, Bennett JL. The treatment of neuromyelitis optica. *J Neuroophthalmol*. 2014;34(1):70–82.

Pittock SJ, Berthele A, Fujihara K, et al. Eculizumab in aquaporin-4-positive neuromyelitis optica spectrum disorder. *N Engl J Med*. 2019;381(7):614–625.

Sato DK, Lana-Peixoto MA, Fujihara K, de Seze J. Clinical spectrum and treatment of neuromyelitis optica spectrum disorders: evolution and current status. *Brain Pathol*. 2013;23(6):647–660.

### **Myasthenia Gravis**

Myasthenia gravis (MG) is an immunologic disorder characterized by variable and fatigable weakness. Neuro-ophthalmic abnormalities develop in most patients with MG. Although the disease is usually systemic, one-half of affected patients have ocular symptoms and signs at onset. The pathophysiology arises from antibodies that reduce the number of available nicotinic acetylcholine receptors. MG may be caused, unmasked, or worsened by numerous medications, including antiarrhythmics, statins, antibiotics, chemotherapeutic drugs, antiepileptic drugs, quinolones, penicillamine, corticosteroids,  $\beta$ -blockers, and calcium channel blockers.

### ***Clinical presentation of myasthenia gravis***

The hallmarks of MG are fluctuation and fatigability (although these are not invariably present). Clinical signs and symptoms usually worsen in the evening and with use of the eyes and may improve with rest. The most common sign of MG is unilateral or bilateral ptosis (see Chapter 12). The extent of ptosis varies, with the eyelid more ptotic in the evening, after exertion, or after prolonged upward gaze. Cogan lid-twitch sign, elicited by having the patient initiate saccades during refixation from extended downgaze to primary position or upgaze, is a brief overelevation of the upper eyelid. Another eyelid sign is enhancement of ptosis; when the more ptotic eyelid is elevated manually, the less ptotic eyelid falls, in keeping with Hering's law of motor correspondence (equal and simultaneous innervation) (see Chapter 12, Fig 12-3). Fatigue of ptosis can be assessed by asking the patient to sustain upgaze for 1 minute or longer.

MG frequently causes diplopia. The diplopia may be variable, both during the day and from one day to another. The ocular motility pattern may simulate ocular motor CN paresis (usually CN VI or partial, pupil-sparing CN III palsy), internuclear ophthalmoplegia, supranuclear motility disturbances (eg, gaze palsies), or isolated muscle “palsy” (eg, isolated inferior rectus). Total ophthalmoplegia can also occur. Any changing pattern of diplopia, with or without ptosis, should suggest MG. As with ptosis, motility fatigue can be assessed by having the patient sustain gaze in the direction of paresis. When present in patients with ocular MG, orbicularis oculi weakness can be diagnostically crucial in differentiating MG from other causes of external ophthalmoplegia.

Because the pupil contains muscarinic acetylcholine receptors, pupillary abnormalities are not associated with MG; if abnormalities are present, the clinician should search for another diagnosis.

Systemic symptoms and signs associated with MG include dysarthria, dysphagia, dyspnea, hoarseness, and weakness in the mastication muscles and in the extensors of the neck, trunk, and limbs. Dysphagia and dyspnea can be life threatening and require prompt treatment. Thyroid eye disease (TED) occurs in about 5% of patients with MG. The presence of exotropia and/or ptosis in a patient with TED should raise concern for superimposed MG.

### ***Diagnosis of myasthenia gravis***

The diagnosis of MG is made clinically by identifying typical signs and symptoms, pharmacologically by overcoming the receptor block via the administration of acetylcholinesterase inhibitors, serologically by demonstrating elevated anti-acetylcholine receptor antibody titers or anti-muscle-specific kinase antibodies, and electrophysiologically by electromyography (EMG).

When an obvious abnormality is present on examination, results of an *edrophonium chloride* (a short-acting acetylcholinesterase inhibitor) *test*, a sleep test, or an ice-pack test can confirm a diagnosis of MG. Edrophonium chloride tests are not commonly performed in eye clinics because rare but serious adverse effects can occur from administration of the drug, including bradycardia, bronchospasm, cholinergic crisis, respiratory arrest, or syncope episodes. Thus, before the test is performed on a patient with a history of cardiac or pulmonary disease, consultation with the primary physician is suggested. Atropine sulfate (0.4–0.6 mg) should be available for immediate use in case of bradycardia. Some physicians pretreat with atropine (0.4 mg subcutaneously) before administering edrophonium. Patients should also be warned of the possibility of short-lived but often discomforting adverse reactions from the medication, including fasciculations, sweating, lacrimation, abdominal cramping, nausea, vomiting, and salivation.

In most protocols, a small test dose of 2 mg (0.2 mL) edrophonium is first injected intravenously, and the patient is observed for 60 seconds. If the symptoms disappear or decrease (for example, the eyelid elevates or motility improves), the test result is considered positive and can be discontinued. If no response is elicited, additional doses of 4 mg, up to a total of 10 mg, are given. When the ocular symptom is marked (eg, complete ptosis), the endpoint (eyelid elevation) is often dramatic. However, a subtle deficit, such as minimal diplopia, may require other means to better define the endpoint. Maddox rod testing with prisms or diplopia fields may be performed before and after edrophonium (see Chapter 8). False-positive

responses are rare. A negative test result does not exclude a diagnosis of MG, and repeated testing may be needed later.

An alternative to the edrophonium test is the *neostigmine methylsulfate test*. This test is particularly useful for children and for adults without ptosis, who may require a longer observation period for accurate ocular alignment measurements than is allowed by edrophonium testing. Adverse reactions are similar to those for edrophonium, the most frequent of which are salivation, fasciculations, and gastrointestinal discomfort. Intramuscular neostigmine and atropine are injected concurrently. Improvement of signs within 30–45 minutes represents a positive test result.

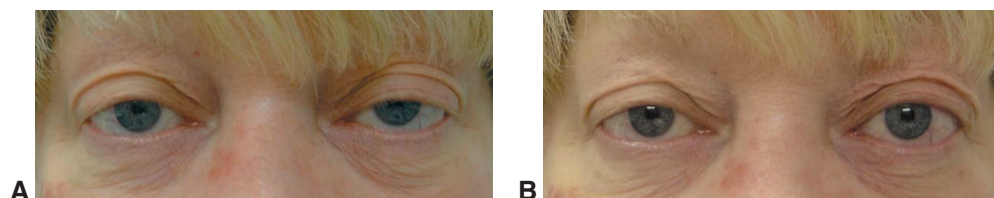
The *ice-pack test* is often helpful for diagnosing MG, but only if the patient has ptosis. An ice pack is placed over the patient's lightly closed eyes for 2 minutes. Improvement of ptosis by 2 mm is considered a positive test result. The sensitivity of the ice-pack test in MG is approximately 90%. Improvement of ptosis occurs in most patients with MG (Fig 15-4); however, the cooling effect may be insufficient to overcome severe weakness in patients with *complete* myasthenic ptosis.

The *sleep test* is a safe, simple office test that eliminates the need for edrophonium testing in many patients. After a baseline deficit has been documented (eg, measurements of ptosis, motility disturbance), the patient rests quietly with eyes closed for 30 minutes. The measurements are repeated immediately after the patient “wakes up” and opens his or her eyes. Improvement after rest is highly suggestive of MG.

Other diagnostic tests for MG include electrophysiologic testing and serum assays for anti-acetylcholine receptor (AChR) antibodies or anti-muscle-specific kinase (MuSK) antibodies. Three types of AChR antibody tests are commercially available: binding, blocking, and modulating. Tests for binding antibodies are usually requested first, because these highly specific antibodies (near 100% specificity) are detected in approximately 90% of patients with generalized MG and in 50%–70% of patients with ocular MG. Blocking antibodies are rarely present (1%) without binding antibodies. Modulating antibodies are present as frequently as binding antibodies. Blocking and modulating antibody testing is usually reserved for patients who have negative test results for the binding antibody and for whom MG is still suspected.

An assay for MuSK antibodies may confirm an MG diagnosis in some patients who do not have AChR antibodies. Patients with MuSK-positive test results tend to have prominent bulbar weakness (eg, dysphagia, dysphonia, chewing difficulties) and present with purely ocular manifestations only in rare instances.

In many patients with systemic MG, *EMG repetitive nerve stimulation* shows a characteristic decremental response. Single-fiber EMG is most sensitive for the disorder. In



**Figure 15-4** Ice-pack test. **A**, A woman with myasthenia gravis presented with moderate left ptosis. **B**, The left ptosis improved after a 2-minute ice-pack test. (Courtesy of Karl C. Golnik, MD.)

addition, all patients with MG should be examined radiologically for thymomas, which are observed on 10% of CT scans in these patients. Malignant thymomas are present in a small percentage of patients. Because MG has a high concordance with other autoimmune disorders, serologic testing should be considered for thyroid dysfunction and systemic lupus erythematosus.

Gwathmey KG, Burns TM. Myasthenia gravis. *Semin Neurol.* 2015;35(4):327–339.

Merckel R, Merckel V. Diagnostic utility of stimulated single-fiber electromyography of the orbicularis oculi muscle in patients with suspected ocular myasthenia. *Muscle Nerve.* 2011;43(2):168–170.

Peeler CE, De Lott LB, Nagia L, Lemos J, Eggenberger ER, Cornblath WT. Clinical utility of acetylcholine receptor antibody testing in ocular myasthenia gravis. *JAMA Neurol.* 2015;72(10):1170–1174.

### **Treatment of myasthenia gravis**

Symptomatic, nonpharmacologic treatment for ptosis or diplopia may include use of a patch, a ptosis crutch, or prisms; however, prisms are typically used when the variability of measurements is small and with the understanding that the treatment is not always helpful. Pharmacologic treatment for MG includes the use of acetylcholinesterase inhibitors (eg, neostigmine and pyridostigmine), corticosteroids, and immunosuppressants such as azathioprine, cyclosporine, mycophenolate, tacrolimus, methotrexate, cyclophosphamide, eculizumab, tocilizumab, and rituximab. Thymectomy is performed in patients with a thymoma and should be considered in patients with generalized MG with or without thymic abnormalities. Short-term therapies such as IVIG or plasmapheresis are occasionally necessary.

In many cases, MG is a systemic disease with a potentially fatal outcome. Although patients may present with purely ocular MG, 20%–50% of them will develop systemic effects over the next 2 years. Because these effects may include respiratory and other life-threatening manifestations, managing patient care in cooperation with a neurologist is prudent. Even in patients who continue to experience isolated ocular signs for more than 2 years, late conversion to generalized MG is still possible.

Wang S, Breskowska I, Gandhi S, Punga AR, Guptill JT, Kaminski HJ. Advances in autoimmune myasthenia gravis management. *Expert Rev Neurother.* 2018;18(7):573–588.

### **Thyroid Eye Disease**

Thyroid eye disease, also known as *thyroid-associated orbitopathy* and *Graves ophthalmopathy*, is an autoimmune inflammatory disorder. Although the underlying cause remains unknown, characteristic clinical signs may include a combination of eyelid retraction, lid lag, proptosis, restrictive extraocular myopathy, and optic neuropathy. Refer to Chapter 4 in this volume as well as BCSC Section 7, *Oculofacial Plastic and Orbital Surgery*, for further discussion of TED.

### **Sarcoidosis**

After the facial nerve, the optic nerve is the CN most frequently affected by sarcoidosis, which may manifest as either a papillitis or retrobulbar optic neuropathy. Less commonly, a sarcoid granuloma may occur at the optic nerve head (ONH) (see Chapter 4, Fig 4-14).

Infrequently, sarcoidosis may cause neuroretinitis, optic perineuritis, or papilledema. Bitemporal and homonymous visual field defects may also occur from chiasmal and retrochiasmal visual pathway involvement. Sarcoidosis can also cause ocular motor CN palsy, gaze palsy, and a variety of pupillary abnormalities, including Adie pupil, Horner syndrome, and Argyll Robertson pupil.

A comprehensive discussion of sarcoidosis is provided in BCSC Section 9, *Uveitis and Ocular Inflammation*.

Frohman LP. Treatment of neuro-ophthalmic sarcoidosis. *J Neuroophthalmol*. 2015;35(1):65–72.

Phillips YL, Eggenberger ER. Neuro-ophthalmic sarcoidosis. *Curr Opin Ophthalmol*. 2010;21(6):423–429.

## Inherited Disorders With Neuro-Ophthalmic Signs

Numerous inherited disorders manifest with neuro-ophthalmic signs. The most common systemic conditions are myopathies and neurocutaneous syndromes (phakomatoses). Hereditary optic neuropathies are discussed in Chapter 4.

### Myopathies

Several inherited conditions affect the extraocular muscles, resulting in mitochondrial dysfunction.

#### **Chronic progressive external ophthalmoplegia**

Chronic progressive external ophthalmoplegia (CPEO) is an inherited mitochondrial myopathy characterized by slowly progressive, symmetric ophthalmoplegia with or without ptosis (Video 15-1; Fig 15-5). Most patients with CPEO have mitochondrial DNA (mtDNA) deletions or point mutations, but nuclear DNA mutations can also cause CPEO. Thus, the mode of inheritance can be mitochondrial (maternal), autosomal, or sporadic (most common), and the disorder may not be transmissible to the next generation.

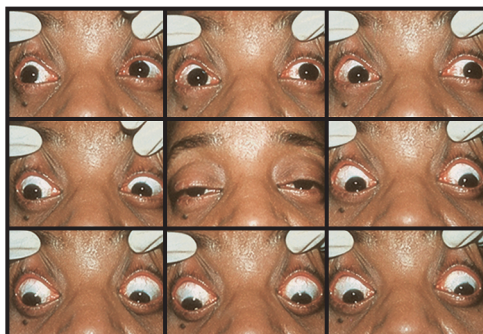


**VIDEO 15-1** Chronic bilateral external ophthalmoplegia with bilateral ptosis.

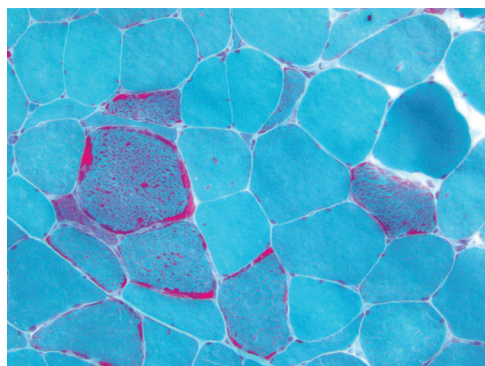
*Courtesy of M. Tariq Bhatti, MD. Narration by Adam Rasky, MD.*



**Figure 15-5** Chronic progressive external ophthalmoplegia in a patient with a 2-year history of progressive ptosis and bilateral external ophthalmoplegia. (Courtesy of Steven A. Newman, MD.)







**Figure 15-6** Histologic examination of a muscle biopsy specimen shows ragged red fibers (modified Gomori trichrome stain). (Courtesy of Marjorie R. Grafe, MD.)

Clinical signs of CPEO usually develop in patients between 18 and 40 years of age. They often present initially with ptosis and do not generally report diplopia. However, most patients have visual impairment and difficulty reading. At presentation, ocular MG may be considered in the differential diagnosis, but in contrast to patients with CPEO, patients with myasthenia typically have variable signs and symptoms. Systemic symptoms in CPEO may include generalized muscle weakness.

Genetic tests can detect abnormalities in mtDNA or mutations in select nuclear DNA genes. Histologic examination of muscle biopsy specimens shows characteristic “ragged red fibers” (Fig 15-6) and mitochondrial proliferation, whereas electron microscopic studies show inclusion body abnormalities in the affected mitochondria.

*Kearns-Sayre syndrome* is another inherited mitochondrial myopathy. It includes CPEO, pigmentary retinopathy, and cardiac conduction abnormalities and variably includes cerebellar ataxia, deafness, and elevated CSF protein levels. Cardiac evaluation is essential to rule out conduction defects and should be obtained for all patients with CPEO.

Yu Wai Man CY, Smith T, Chinnery PF, Turnbull DM, Griffiths PG. Assessment of visual function in chronic progressive external ophthalmoplegia. *Eye (Lond)*. 2006;20(5):564–568.

### ***Oculopharyngeal dystrophy***

Oculopharyngeal dystrophy is a hereditary condition, either autosomal dominant or recessive, with onset in the fifth and sixth decades of life. The typical presentation is progressive bilateral ptosis followed by dysphagia and proximal muscle weakness. Most patients have an external ophthalmoplegia that, when asymmetric, may be accompanied by diplopia. Pathologic studies show a vacuolar myopathy. The disease is classically observed in patients of French-Canadian ancestry. The only causative mutation described to date is a triplet repeat expansion consisting of 2–7 additional base triplets in a repeat sequence in exon 1 of the poly(A) binding protein nuclear 1 gene (*PABPN1*), located on chromosome 14.

### ***Myotonic dystrophy***

Myotonic dystrophy, a dominantly inherited multisystem disorder, produces ophthalmoplegia that may mimic CPEO. Symptoms usually start in late childhood or early adulthood with myotonia that is exacerbated by excitement, cold, and fatigue. The myotonia can be easily detected by asking the patient to shake hands; the patient will not be able to quickly release his or her grasp. This myopathy is unusual in that it affects distal limb musculature first. Wasting of



the temporalis and masseter muscles produces the typical “hatchet face,” whereas myopathic facies, frontal balding, and ptosis cause a distinct and remarkably characteristic appearance.

Ocular findings include ptosis, pigmentary retinopathy, ophthalmoparesis, and polychromatic lenticular deposits (“Christmas tree” cataracts). The pupils are miotic and respond sluggishly to light. Other features of this dystrophy include low intelligence, insulin resistance, hearing loss, cardiomyopathy, cardiac conduction abnormalities, testicular atrophy, and uterine atony.

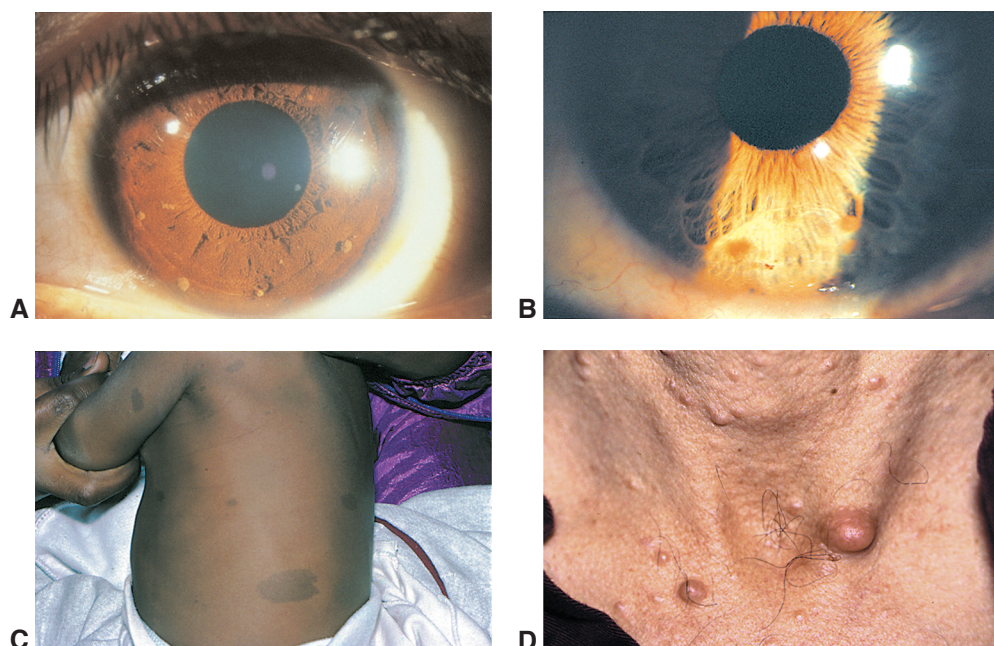
EMG studies can demonstrate characteristic myotonic discharges, and genetic testing can confirm the diagnosis of myotonic dystrophy. Myotonic dystrophy is associated with mutations in the *DMPK* or *CNBP* (*ZNF9*) gene.

Turner C, Hilton-Jones D. The myotonic dystrophies: diagnosis and management. *J Neurol Neurosurg Psychiatry*. 2010;81(4):358–367.

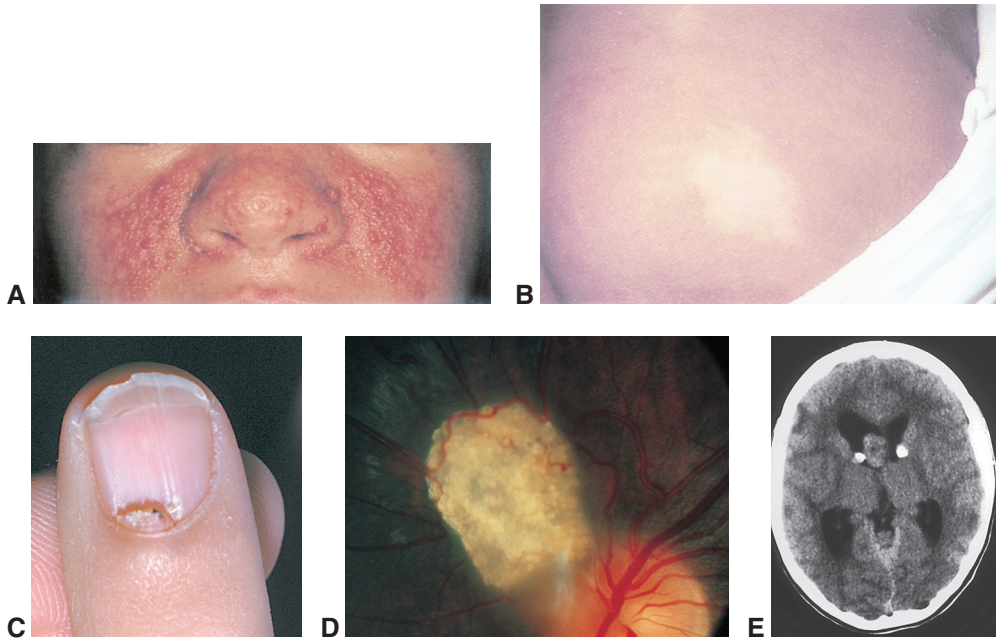
## Neurocutaneous Syndromes

Neurocutaneous syndromes, or *phakomatoses*, are characterized by lesions involving different organ systems, such as the skin, eyes, CNS, and viscera. Four major disorders have been traditionally designated phakomatoses:

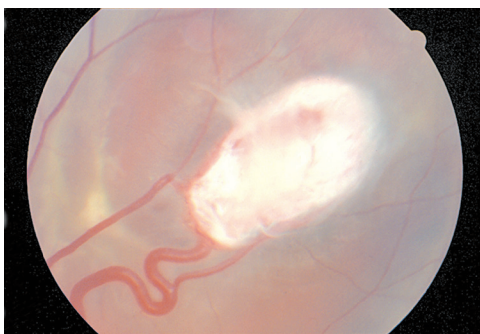1. neurofibromatosis type 1 (von Recklinghausen disease; Fig 15-7) and type 2
2. tuberous sclerosis (Bourneville disease; Fig 15-8)



**Figure 15-7** The most common ocular finding in neurofibromatosis type 1 is the presence of iris (Lisch) nodules. These are often light colored in a patient with dark irides (**A**) but may be relatively darker in patients with light irides (**B**). The diagnosis is often suggested by cutaneous findings, including café-au-lait spots (**C**) or skin neurofibromas (**D**). (Part A courtesy of Mark J. Greenwald, MD; parts B–D courtesy of Steven A. Newman, MD.)



**Figure 15-8** Tuberous sclerosis. **A**, Hamartomatous angiofibromas (previously called adenoma sebaceum) are a hallmark of tuberous sclerosis and involve the cheek, particularly in the area of the nasolabial fold. Other classic skin findings include an ash-leaf spot (**B**), best observed with ultraviolet light, and subungual lesions (**C**). **D**, Ophthalmic findings include astrocytic hamartomas on ophthalmoscopic examination. **E**, Intracranial hamartomas often line the subependymal surface. They frequently calcify, becoming obvious on computed tomography scan. (Parts A and B courtesy of Mark J. Greenwald, MD; parts C and E courtesy of Steven A. Newman, MD. Part D reprinted from Kline LB, Foroozan R, eds. Optic Nerve Disorders. 2nd ed. Ophthalmology Monographs 10. Oxford University Press, in cooperation with the American Academy of Ophthalmology; 2007:164.)

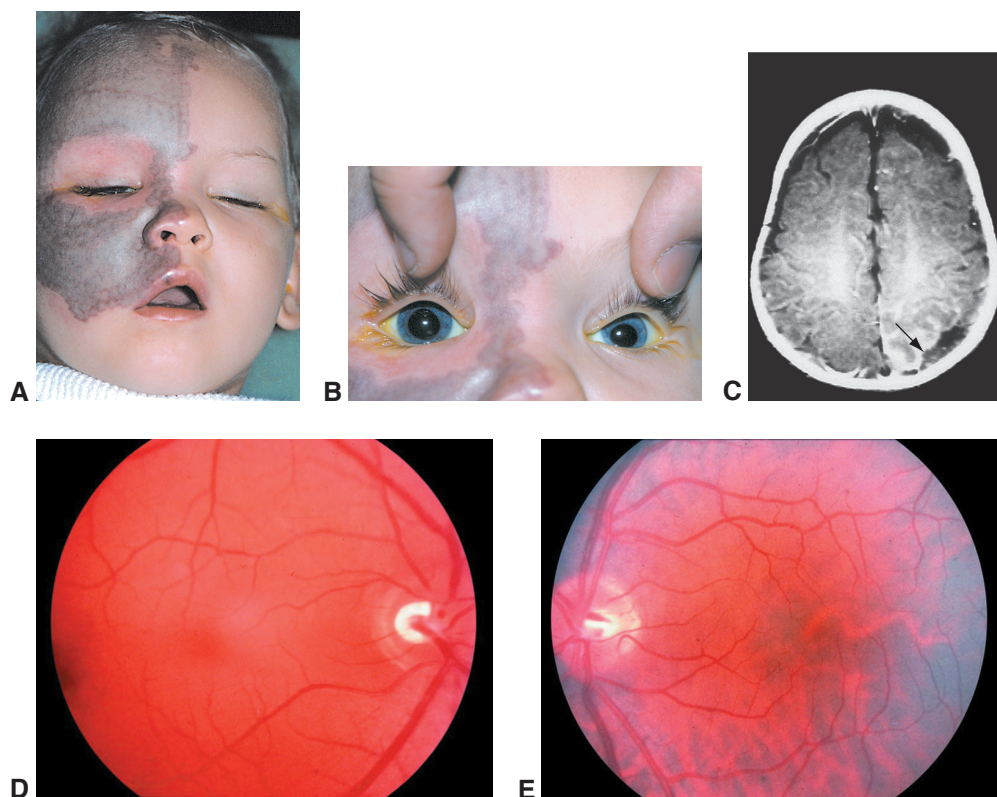
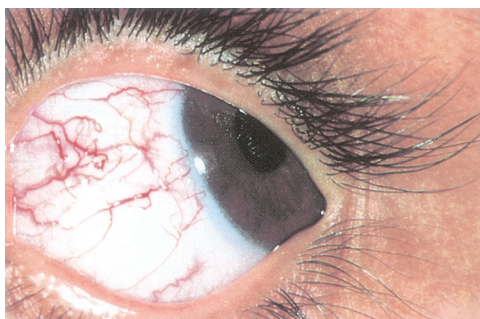


**Figure 15-9** von Hippel-Lindau disease. Fundus photograph showing a retinal hemangioblastoma. (Courtesy of Steven A. Newman, MD.)

3. angiomatosis of the retina and cerebellum (von Hippel-Lindau disease; Fig 15-9)
4. ataxia-telangiectasia (Louis-Bar syndrome; Fig 15-10)

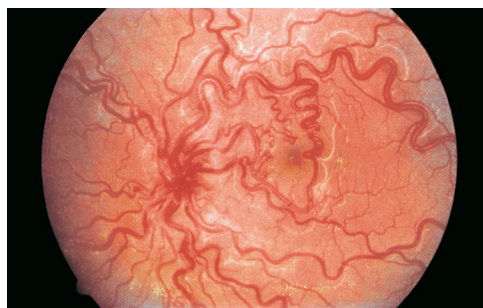Encephalofacial angiomatosis (Sturge-Weber syndrome; Fig 15-11), racemose angioma (Wyburn-Mason syndrome; Fig 15-12), incontinentia pigmenti, and Klippel-Trénaunay-Weber syndrome are other conditions sometimes classified as phakomatoses.

**Figure 15-10** Ataxia-telangiectasia. External photograph demonstrating abnormally dilated and tortuous conjunctival vessels. (Courtesy of Mark J. Greenwald, MD.)



**Figure 15-11** Sturge-Weber syndrome. **A**, This 1-year-old exhibits a port-wine stain involving the  $V_1$  and  $V_2$  distributions on the right side, a classic finding in this syndrome. These patients often have congenital glaucoma. **B**, In an infant with congenital glaucoma, the globe may enlarge significantly (buphthalmos). **C**, MRI scan shows cortical vascular malformations following the gyral pattern (arrow). Diffuse choroidal hemangiomas may also occur, causing increased hyperemia and redness of the choroid. Fundus photographs show choroidal hemangioma (**D**) and the contralateral normal eye (**E**). (Parts A and B courtesy of Steven A. Newman, MD; part C courtesy of Mark J. Greenwald, MD; parts D and E courtesy of James J. Augsburger, MD.)





**Figure 15-12** Wyburn-Mason syndrome. Fundus photograph showing a retinal arteriovenous malformation (racemose angioma). (Courtesy of Mark J. Greenwald, MD.)

The phakomatoses are characterized by tumors formed from normal tissue elements: hamartomas and choristomas. A *hamartoma* is composed of elements normally found at the involved site; hamartomas are not true neoplasms because they are anomalies of tissue formation that lack the capability for limitless proliferation. One example of a hamartoma is the glial retinal tumor of tuberous sclerosis. *Choristomas* are tumor-like growths composed of tissue not normally present at the site of growth. Although most phakomatous lesions are hamartomas or choristomas, some are neoplasms.

Table 15-2 summarizes the important features of the most common phakomatoses. Phakomatoses are discussed at length in BCSC Section 6, *Pediatric Ophthalmology and Strabismus*.

Ullrich NJ. Neurocutaneous syndromes and brain tumors. *J Child Neurol*. 2016;31(12):1399–1411.

## Selected Neuro-Ophthalmic Disorders Associated With Pregnancy

During pregnancy or the postpartum period, several neuro-ophthalmic abnormalities can be exacerbated or may occur with greater frequency than normal, including cerebral venous thrombosis (CVT), idiopathic intracranial hypertension (IIH), pituitary apoplexy, and lymphocytic hypophysitis. (CVT is discussed later in this chapter [see Cerebrovascular Disorders], and IIH and pituitary apoplexy are discussed in Chapter 4.) Preexisting pituitary macroadenomas, meningiomas, schwannomas, and orbital and choroidal hemangiomas can also undergo rapid expansion during pregnancy.

Pregnancy is also associated with a number of cranial neuropathies, most frequently involving CN VII followed by CN VI. These cranial neuropathies are thought to result from compression due to increased interstitial fluid around the nerve. Hypercoagulopathy and hypertension are also potential causes.

In addition, severe preeclampsia/eclampsia can lead to various ophthalmic manifestations, including serous retinal detachment, choroidal infarction, retinal vascular narrowing, and retinal artery vasospasm or occlusion. The optic nerve may become edematous secondary to systemic hypertension, IIH, or ischemic optic neuropathy. Disorders of higher cortical function, such as alexia, simultagnosia, and cortical visual impairment, have also been

Table 15-2 Neurocutaneous Syndromes

	Neurofibromatosis Type 1 (NF1)	Neurofibromatosis Type 2 (NF2)	Tuberous Sclerosis (TS)	Retinal and Cerebellum Angiomatosis	Ataxia-Telangiectasia (AT)	Encephalofacial Angiomatosis	Racemose Angioma
Common name	von Recklinghausen disease	Bilateral acoustic neuro-fibromatosis	Bourneville disease	von Hippel-Lindau (VHL) disease	Louis-Bar syndrome	Sturge-Weber syndrome (SWS)	Wyburn-Mason syndrome
Chromosome location	17q11.2	22q12.2	9q34 ( <i>TSC1</i> ), 16q13.3 ( <i>TSC2</i> )	3p26-p25	11q22.3	9q21 ( <i>GNAQ</i> )	Not genetically transmitted
Gene name	Neurofibromin 1	Neurofibromin 2	<i>TSC1</i> , hamartin <i>TSC2</i> , tuberlin	<i>VHL</i>	<i>ATM</i>		
Inheritance pattern	Autosomal dominant	Autosomal dominant	Autosomal dominant	Autosomal dominant	Autosomal recessive	Somatic mosaicism	Sporadic
Classic manifestations	Lisch nodules Fibroma molluscum Plexiform neurofibroma Café-au-lait spots Optic pathway glioma Osseous defects including sphenoid wing dysplasia Hyperpigmented choroidal lesions	Acoustic neuromas Meningioma(s) Café-au-lait spots Posterior subcapsular cataract Epiretinal membrane Retinal hamartoma	Facial angiofibromas Subungual fibromas Shagreen patches Ash-leaf spots Retinal and intracranial astrocytic hamartomas ("brain stones," often calcified) Seizures Cardiac rhabdomyoma Renal hamartomas or cysts Renal cell carcinoma Cognitive impairment	Retinal hemangioblastoma that is often multiple and bilateral; can cause serous retinal detachment Cerebellar hemangioblastoma Pheochromocytomas Renal cysts or renal cell carcinoma	Cerebellar ataxia Conjunctival telangiectasia Poor initiation of saccades associated with head thrusts Horizontal and vertical supranuclear gaze palsies Increased risk of malignancies Recurrent respiratory tract infections	Hemifacial nevus flammeus (port-wine stain) Ipsilateral leptomeningeal vascular malformation with subcortical calcifications Choroidal hemangioma Glaucoma Seizures Focal neurologic deficits	Intracranial arteriovenous malformation (AVM) Ipsilateral retinal AVM (racemose angioma) Spontaneous intracranial hemorrhage

reported. In addition, posterior reversible encephalopathy syndrome (PRES) may develop in the context of preeclampsia/eclampsia (see the following section).

Digre KB. Neuro-ophthalmology and pregnancy: what does a neuro-ophthalmologist need to know? *J Neuroophthalmol*. 2011;31(4):381–387.

### Posterior Reversible Encephalopathy Syndrome

This syndrome is characterized by headache, altered mental status, seizures, and visual disturbances. These disturbances include blurred vision, homonymous visual field loss, cortical visual impairment, photopsias, and visual hallucinations. MRI shows T2-hyperintense vasogenic edema involving the white matter of the cerebral posterior regions, especially the parieto-occipital lobes; however, the frontal and temporal lobes, basal ganglia, and brainstem can also be involved (Fig 15-13).

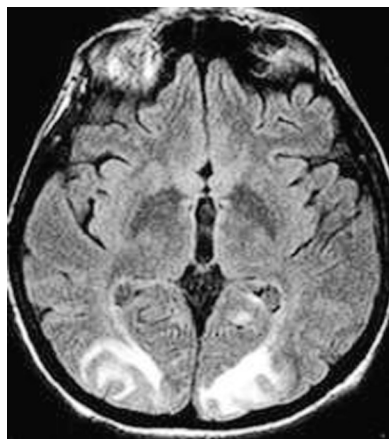
In addition to preeclampsia/eclampsia, other conditions that predispose patients to PRES include acute hypertension, use of immunosuppressive drugs (eg, cyclosporine, tacrolimus), renal disease, sepsis, and multiorgan dysfunction syndrome. PRES is less commonly reported in patients with autoimmune disease.

The abnormalities visible on neuroimaging are reversible, and the visual prognosis is usually excellent. The underlying pathophysiology of PRES remains elusive.

Fugate JE, Claassen DO, Cloft HJ, Kallmes DF, Kozak OS, Rabinstein AA. Posterior reversible encephalopathy syndrome: associated clinical and radiologic findings. *Mayo Clin Proc*. 2010;85(5):427–432.

### Lymphocytic Hypophysitis

Lymphocytic hypophysitis is a rare neuroendocrine disorder characterized by autoimmune inflammation of the pituitary gland, with various degrees of pituitary dysfunction, including permanent hypopituitarism. Histologic findings consist of an initial monoclonal lymphocytic infiltrate, which can either resolve with minimal sequelae or progress to fibrosis. Ophthalmic manifestations include chiasmal compression–type visual field defects



**Figure 15-13** Posterior reversible encephalopathy syndrome in the setting of preeclampsia. Axial FLAIR MRI scan shows hyperintense signal changes of the occipital lobes (posterior circulation). (Courtesy of Lanning B. Kline, MD.)



secondary to suprasellar extension or, less frequently, diplopia due to invasion of the cavernous sinus.

Imaging and endocrine testing results are nonspecific. The diagnosis should be suspected in a woman who is pregnant or in the peripartum period and who presents with headache, bitemporal visual field defects, and changes in 1 or more pituitary hormone levels. However, cases do occur outside pregnancy.

Corticosteroids and other immunosuppressive drugs may be needed in some patients. Surgical treatment is typically required when vision is compromised.

## Cerebrovascular Disorders

---

Although a comprehensive discussion of cerebrovascular disorders is beyond the scope of this text, the following sections summarize common conditions that present with neuro-ophthalmic signs and symptoms.

### Transient Visual Loss

Transient neurologic or ophthalmic symptoms in middle-aged or older patients suggest a vascular origin. Localization of the symptoms and signs determines whether they result from ischemia in the vertebrobasilar or the carotid artery territory. Although recurrent cerebrovascular ischemia is a concern in these patients, the major cause of death is coronary artery disease. Thus, efforts should be made to control risk factors for cardiovascular disease, such as hypertension, diabetes mellitus, and hyperlipidemia, accompanied by cessation of smoking. Diagnostic and therapeutic efforts are directed at the cerebrovascular circulation. Carotid system disorders characterized mainly by transient visual loss are discussed in Chapter 6.

### Vertebrobasilar System Disease

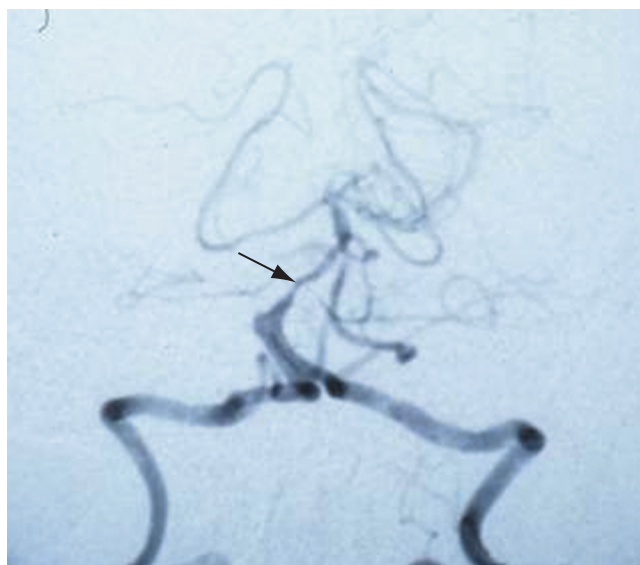
The vertebrobasilar arterial system (posterior circulation) comprises the vertebral, basilar, and posterior cerebral arteries (Fig 15-14). These blood vessels supply the occipital cortex, brainstem, and cerebellum.

#### ***Clinical presentation of vertebrobasilar insufficiency***

*Transient ischemic attacks (TIAs)* originating from the vertebrobasilar system are often recognized by their nonophthalmic symptoms, which include

- ataxia, imbalance, or staggering
- vertigo combined with other brainstem symptoms such as deafness or vomiting
- transient dysarthria and dysphagia
- hemiparesis, hemiplegia, and hemisensory disturbances
- drop attacks (patient suddenly falls to the ground with no warning and no loss of consciousness)

Nevertheless, patients with vertebrobasilar insufficiency often present to the ophthalmologist first because ocular motor and visual symptoms are also prominent. For example,



**Figure 15-14** Posterior circulation transient ischemic attack. Cerebral angiogram demonstrates basilar artery stenosis (*arrow*) in a patient with diplopia due to a right cranial nerve III palsy and ataxia that resolved over 24 hours. (Courtesy of Karl C. Golnik, MD.)

bilateral blurring or dimming of vision occurs almost as frequently as vertigo. The patient may report sudden bilateral graying or whiting out of vision secondary to ischemia in the occipital lobe. These episodes of dimming may last seconds to minutes and may be accompanied by flickering or flashing stars. Migraine (discussed in Chapter 13) can produce similar symptoms, with or without an associated headache. For example, the scintillating scotomata of migraine may mimic photopsias of occipital lobe ischemia. The latter attacks are frequently repetitive and may occur alone or in combination with other transient symptoms of vertebrobasilar insufficiency.

Homonymous visual field changes without other neurologic symptoms indicate involvement of the retrochiasmal visual pathways. Highly congruous homonymous visual field defects without other systemic symptoms are typical of occipital lobe infarcts. Patients who report reading difficulties without an obvious cause should undergo a careful visual field and Amsler grid examination to search for central congruous homonymous visual field defects.

Chapter 5 details the visual manifestations of cortical infarction. Cerebral blindness (cortical visual impairment), caused by bilateral occipital lobe lesions, is characterized by amaurosis, normally reactive pupils, and an unremarkable fundus appearance. Frequently, patients with cerebral blindness will deny their blindness (Anton syndrome; see Chapter 7).

Ocular motor disturbances are also common with vertebrobasilar insufficiency, and diplopia is frequently reported. Examination may reveal horizontal or vertical gaze palsies, internuclear ophthalmoplegia, skew deviation, ocular motor CN palsies, or nystagmus. An ipsilateral central Horner syndrome may be present with pontine or medullary infarcts (Wallenberg syndrome).

Levin LA. Topical diagnosis of chiasmal and retrochiasmal disorders. In: Miller NR, Newman NJ, Biousse V, Kerrison JB, eds. *Walsh and Hoyt's Clinical Neuro-Ophthalmology*. Vol 1. 6th ed. Lippincott Williams & Wilkins; 2005:539–554.

### ***Etiologies of posterior circulation ischemia***

The most frequent causes of vertebrobasilar TIAs and stroke are atheromatous occlusion, hypertensive vascular disease (lacunar infarction), microembolization (either from the vertebrobasilar system or from the heart), fluctuations in cardiac output, and arterial dissection. The following conditions have all been associated with symptoms and signs of vertebrobasilar ischemia: polycythemia, hypercoagulable states, anemia, vasospasm, and congenital aplasia or hypoplasia of a vertebral or posterior communicating artery. Mechanical factors such as cervical spondylosis and chiropractic manipulation of the cervical spine have also been implicated in vertebrobasilar occlusions, resulting in severe neurologic deficits. A less common cause of vertebrobasilar dysfunction is a reversal of blood flow in the vertebral artery (*subclavian steal*); this reversal is caused by a proximal occlusion of the subclavian artery, which produces an unusual alteration in the direction of flow in the ipsilateral vertebral artery. Lowered pressure in the distal segment of the subclavian artery can siphon, or “steal,” blood from the vertebral artery and produce fluctuating symptoms of vertebrobasilar artery insufficiency.

### ***Investigation of posterior circulation ischemia***

Evaluation for posterior circulation ischemia is similar to the medical workup for carotid system disease. In general, acute onset of anterior or posterior circulation TIAs or fixed neurologic abnormalities is a medical emergency, and the patient should be evaluated immediately by a neurologist in an emergency department. As for all cases of homonymous visual field defects and other signs of brainstem or cerebellar dysfunction, neuroimaging is typically performed. The best noninvasive methods for evaluating the posterior circulation are magnetic resonance angiography (MRA) and computed tomography arteriography (CTA). Visualization of the aortic arch, the configuration of the vertebrobasilar vessels, and the extent of filling from the anterior circulation through the circle of Willis are usually necessary. Carotid Doppler imaging is inadequate for evaluating suspected posterior circulation symptoms.

The evaluation of patients with posterior circulation symptoms includes a search for underlying cardiac or systemic disorders, including hypercholesterolemia, hypertension, diabetes mellitus, and postural hypotension. Cardiac evaluation should include echocardiography.

Markus HS, van der Worp HB, Rothwell PM. Posterior circulation ischaemic stroke and transient ischaemic attack: diagnosis, investigation, and secondary prevention. *Lancet Neurol*. 2013;12(10):989–998.

### ***Treatment of vertebrobasilar ischemia***

Most vertebrobasilar TIAs are treated with statins and antiplatelet therapy or anticoagulants. Intravascular stent placement can be used in select patients with symptomatic vertebrobasilar stenosis for whom maximal medical therapy has been ineffective.

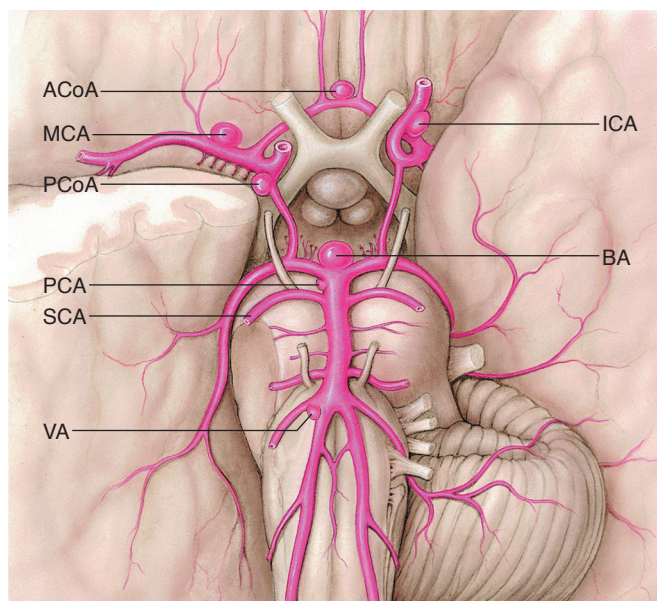
## Cerebral Aneurysms

Cerebral aneurysms are localized dilations of the vessel wall. They are present in approximately 5% of the population but rarely become symptomatic before 20 years of age. Cerebral aneurysms may be an isolated finding and are often associated with hypertension. Less common predisposing conditions include arteriovenous malformations, coarctation of aorta, polycystic kidney disease, and connective tissue diseases (eg, fibromuscular dysplasia, Marfan syndrome, and Ehlers-Danlos syndrome). A familial occurrence is possible, and tobacco use is a risk factor. Among patients with a cerebral aneurysm, 10% will have more than 1.

Figure 15-15 shows possible locations for cerebral aneurysms. The most common type of intracranial aneurysm is the saccular, or “berry,” aneurysm that arises at arterial bifurcations. Of these aneurysms, 90% are supratentorial and 10% are infratentorial. Aneurysms arising from the internal carotid artery and basilar artery may have neuro-ophthalmic manifestations. In general, aneurysms larger than 10 mm are most likely to rupture. If they are 25 mm or larger, they are termed “giant aneurysms.” Because high morbidity and mortality rates are associated with aneurysm rupture, early detection and surgical intervention can be lifesaving.

### ***Clinical presentation of cerebral aneurysms***

Signs and symptoms of cerebral aneurysms vary by their location. Unruptured aneurysms, particularly giant aneurysms, may cause progressive neurologic dysfunction because of their



**Figure 15-15** Drawing shows locations for intracranial aneurysms arising from cerebral blood vessels. ACoA=anterior communicating artery; BA=basilar artery; ICA=internal carotid artery; MCA=middle cerebral artery; PCA=posterior cerebral artery; PCoA=posterior communicating artery; SCA=superior cerebellar artery; VA=vertebral artery. (Reprinted from Kline LB, Foroozan R, eds. *Optic Nerve Disorders*. 2nd ed. *Ophthalmology Monographs* 10. Oxford University Press, in cooperation with the American Academy of Ophthalmology; 2007:131.)

mass effect. An ophthalmic artery aneurysm may cause a progressive unilateral optic neuropathy and ipsilateral periocular pain. Anterior communicating artery aneurysms may cause loss of vision by compressing the optic chiasm or optic tract. Aneurysms at the junction of the internal carotid and posterior communicating arteries cause an ipsilateral CN III palsy. For this reason, any complete CN III palsy with pupil involvement and any partial CN III palsy with or without pupil involvement should raise suspicion for an aneurysm and prompt immediate neuroimaging. Intracavernous internal carotid artery aneurysms typically produce a cavernous sinus syndrome. These aneurysms are often a fusiform enlargement (dolichoectasia) and not saccular. CNs III, IV, and VI, the ophthalmic branch of CN V, and the sympathetic nerves are involved, singly or in combination. Because these aneurysms are confined by the walls of the cavernous sinus, they typically do not rupture, instead causing progressive neurologic dysfunction. Of note, aneurysms in this location often produce facial pain and should be considered in the differential diagnosis of painful ophthalmoplegia.

Diagnostically, pain is not a differentiating symptom for cerebral aneurysms because it may occur with CN palsies from microvascular ischemia and may be absent with unruptured aneurysms. TIAs, cerebral infarction, and seizures may be caused by flow phenomena or distal embolization, similarly complicating the diagnosis of cerebral aneurysms.

As noted previously, a ruptured aneurysm is a neurosurgical emergency. Patients exhibit symptoms and signs of subarachnoid or intraparenchymal hemorrhage. The headache resulting from a ruptured aneurysm may be localized or generalized and is often described as “the worst headache in my life.” Many patients recall symptoms that could be attributed to a “sentinel bleed.” Transient or mild neurologic symptoms are most commonly described along with the headache. Nausea, vomiting, and neck stiffness may be caused by meningeal irritation from subarachnoid blood. In rare cases, fever may be present. Elevated intracranial pressure may produce papilledema and CN VI palsies. Patients may be disoriented, lethargic, or comatose. Altered mental status is a sign of poor prognosis. Vasospasm from subarachnoid hemorrhage may cause cerebral infarction, including in the occipital lobe, with consequent unilateral or bilateral homonymous hemianopia.

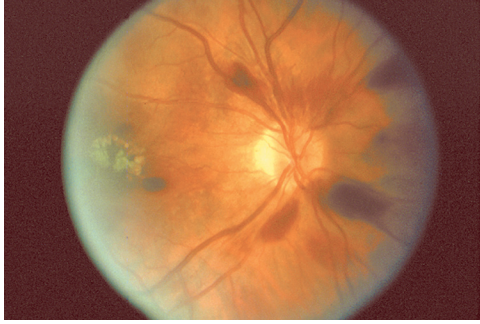
Subarachnoid hemorrhage may be accompanied by ocular (ie, intraretinal, preretinal, subhyaloid, vitreous, subconjunctival), orbital, or optic nerve sheath hemorrhage. Ocular hemorrhages are most likely produced when intracranial pressure in the optic nerve sheath exceeds ocular venous pressure, reducing ophthalmic venous drainage and causing venous rupture. The combination of intraocular (vitreous, preretinal, or retinal) and subarachnoid hemorrhage is called *Terson syndrome* (Fig 15-16).

### **Diagnosis of cerebral aneurysms**

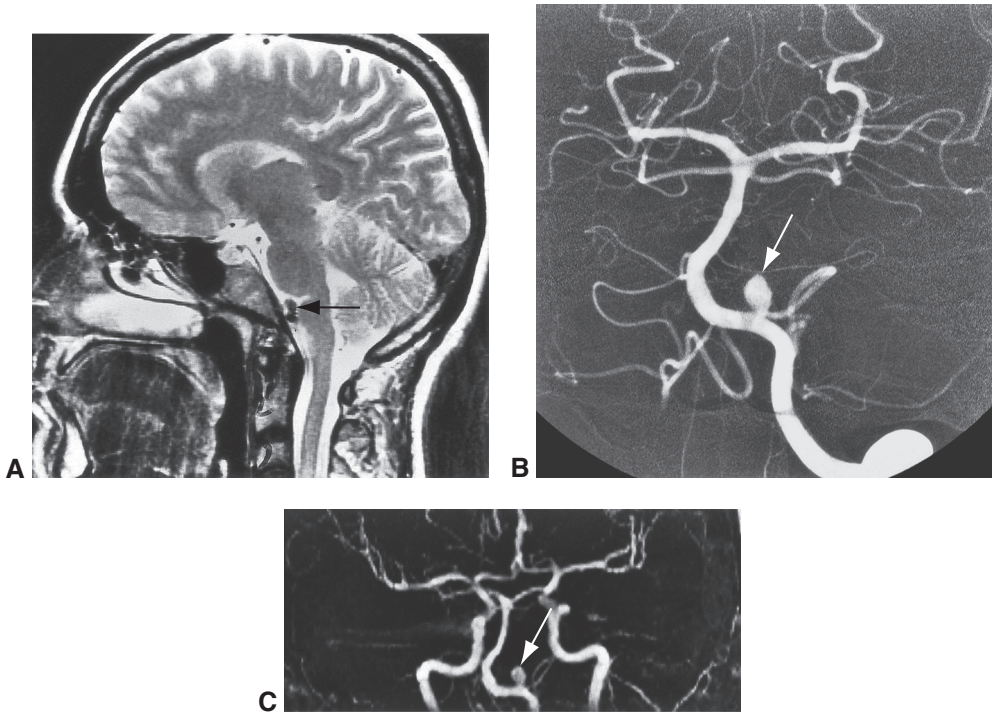
Any patient with a suspected aneurysm requires urgent neuroradiologic assessment. The type of study ordered varies, and the decision should involve the neuroradiologist (see Chapter 2).

At most sites, CTA is the modality of choice for diagnosis of clinically relevant aneurysms. MRI depicts most aneurysms larger than 5 mm, and high-quality MRA can detect aneurysms as small as 2–3 mm. Either CTA or MRA is useful to screen for unruptured aneurysms, and both procedures are associated with lower morbidity than conventional angiography (Fig 15-17). However, when suspicion for aneurysm is high but findings are negative





**Figure 15-16** Terson syndrome. Fundus photograph showing retinal, preretinal, and vitreous hemorrhages in the setting of a ruptured intracranial aneurysm. (Courtesy of Steven A. Newman, MD.)



**Figure 15-17** Imaging of cerebral aneurysms. **A**, Sagittal view of the brain on a T2-weighted MRI scan shows a low-intensity signal in the subarachnoid space anterior to the medulla (arrow) and contiguous with the vertebral artery inferiorly, consistent with flowing blood. **B**, Conventional arteriography shows a vertebral artery aneurysm (arrow). **C**, The same aneurysm, as demonstrated by magnetic resonance angiography (arrow). (Courtesy of Leo Hochhauser, MD.)

on MRA or CTA, conventional cerebral arteriography (ie, the gold standard for evaluation) can be considered in consultation with the radiologist.

CT is useful immediately after aneurysm rupture to detect intraparenchymal and subarachnoid blood. Enhanced CT can depict large aneurysms, but CT alone is not an acceptable screening test for unruptured aneurysms. If a subarachnoid hemorrhage is suspected and the CT is negative, a CTA will help detect an aneurysm and lumbar puncture can



confirm the presence of subarachnoid blood. However, a lumbar puncture should not be attempted in the presence of midline shift or evidence of cerebral (uncal) herniation.

### ***Prognosis for patients with cerebral aneurysms***

Modern imaging technology (MRA and CTA) has dramatically increased the detection of unruptured intracranial aneurysms. The risk of rupture is related to the size of these aneurysms. Aneurysms that are 7–12 mm, 13–24 mm, and  $\geq 25$  mm have yearly rupture rates of 1.2%, 3.1%, and 8.6%, respectively. Once an aneurysm has ruptured, morbidity and mortality are high. The proportion of patients who die at the time of rupture is 30%. If untreated, another 33% die within 6 months of rupture, and an additional 15% die within 10 years. Many of those who survive experience severe neurologic deficits.

Wiebers DO, Whisnant JP, Huston J III, et al. Unruptured intracranial aneurysms: natural history, clinical outcome, and risks of surgical and endovascular treatment. *Lancet*. 2003;362(9378):103–110.

### ***Treatment of cerebral aneurysms***

Treatment of symptomatic aneurysms before rupture is ideal and should be performed without delay. Supportive efforts to stabilize the patient include lowering intracranial pressure (via hyperventilation or administration of mannitol), treating cerebral vasospasm (with calcium channel blockers and blood volume expansion), controlling blood pressure, and preventing seizures.

Depending on the aneurysm's size, location, and anatomy, treatments include surgical clipping of the aneurysm or endovascular techniques such as coil embolization or stent placement.

Thompson BG, Brown RD Jr, Amin-Hanjani S, et al. Guidelines for the management of patients with unruptured intracranial aneurysms: a guideline for healthcare professionals from the American Heart Association/American Stroke Association. *Stroke*. 2015;46(8):2368–2400.

## **Arterial Dissection**

Dissections may develop in the internal carotid, vertebral, and basilar arteries or in their branches, along either the extracranial or intracranial course. Risk factors for dissection include trauma, cervical manipulation, connective tissue disorders, and fibromuscular dysplasia. Sometimes symptoms of arterial dissection are delayed for weeks or months after trauma.

### ***Clinical presentation of internal carotid artery dissection***

The most common presentation of internal carotid artery (ICA) dissection is acute pain located on the ipsilateral forehead, around the orbit, or in the neck. Other manifestations include ipsilateral ophthalmic signs and contralateral neurologic deficits. A bruit may also be present. Transient or permanent neurologic symptoms and signs include amaurosis fugax, acute stroke, monocular vision loss, and ipsilateral Horner syndrome. If the dissection extends to the intracranial carotid segment, cranial neuropathies can occur, producing diplopia, dysgeusia, tongue paralysis, or facial numbness.

Arterial closure, or formation of a thrombus above the dissection, which then embolizes, can cause transient ischemia or stroke, usually within 30 days of the first sign or symptom. With ICA dissection, embolic occlusion of the ophthalmic artery, central retinal artery, short posterior ciliary arteries, or retinal branch arteries may cause vision loss. Alternatively, ophthalmic artery occlusion may be caused by the dissection itself closing off its branch from the ICA. Reduced blood flow from ICA dissection is a rare cause of ocular ischemic syndrome.

The vertebral and basilar arteries are affected in 40% of dissections. General features of these dissections are headache, neck pain, and signs of brainstem and cerebellar dysfunction. Ocular motor CN palsies are common, and the consequences may progress to cortical visual impairment, quadriplegia, coma, and death.

Biousse V, D'Anglejan-Chatillon J, Touboul PJ, Amarenco P, Boussier MG. Time course of symptoms in extracranial carotid artery dissections. A series of 80 patients. *Stroke*. 1995;26(2):235–239.

Caplan LR, Biousse V. Cervicocranial arterial dissections. *J Neuroophthalmol*. 2004;24(4):299–305.

### **Imaging of internal carotid artery dissection**

CT/CTA or MRI/MRA is the diagnostic test of choice for an extracranial ICA dissection. MRI can show a false lumen or an area of clotting in the cervical portion of the carotid artery (“crescent moon” sign; see Chapter 11, Fig 11-4) and may identify areas of brain infarction. CTA and MRI/MRA have a sensitivity of 87%–100%. Digital subtraction angiography may also be used to diagnose arterial dissection. Ultrasonography, which does not allow visualization of the distal carotid or the vertebrobasilar system, is insufficient to detect a carotid dissection, and test results are falsely negative in nearly one-third of cases.

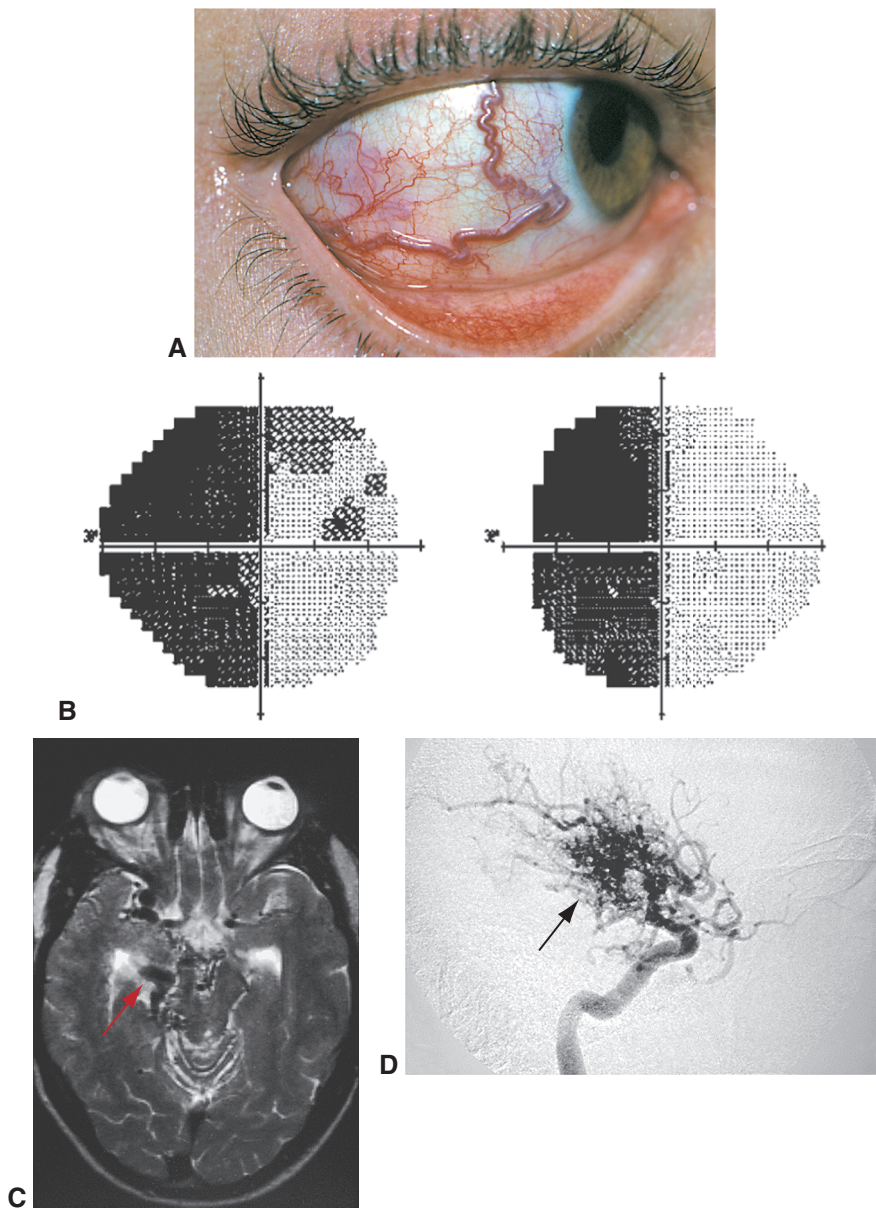
### **Treatment of arterial dissection**

Treatment of arterial dissection depends on the extent and location of the dissection and the patient's overall condition. Treatment methods may include medical therapy using antiplatelet drugs or anticoagulants, endovascular therapy with stent placement, and in rare cases, a surgical bypass procedure.

### **Arteriovenous Malformations**

Arteriovenous malformations (AVMs) are usually congenital and may be familial. Symptoms typically arise before 30 years of age, with a slight preponderance in males, and 6% of patients also have an intracranial aneurysm. Intracranial hemorrhage with or without subarachnoid hemorrhage is the initial presentation in half of cases. In contrast to patients with saccular aneurysms, patients with AVMs are much more likely to become symptomatic before a hemorrhage occurs (Fig 15-18). Seizures are the first manifestation in 30% of affected patients, whereas 20% have headaches or other focal neurologic deficits initially. The neurologic symptoms may be progressive or transient.

Of the 90% of AVMs that are supratentorial, about 70% are cortical and 20% are deep. The remaining 10% of these AVMs are located in the posterior fossa or dura mater. When



**Figure 15-18** Arteriovenous malformation (AVM). **A**, This 24-year-old man was referred with a 2- to 3-year history of prominent blood vessels in the right eye. Visual acuity was 20/20 bilaterally, but visual fields (**B**) demonstrated a left homonymous hemianopia. **C**, A T2-weighted MRI scan demonstrated a large right basal ganglia AVM (red arrow). **D**, Angiogram of the right internal carotid artery confirmed the basal ganglia AVM (arrow). (Courtesy of Steven A. Newman, MD.)

bleeding takes place, early mortality occurs in up to 20% of cases, and the rebleeding rate is 2.5% each year. Most AVMs bleed into the brain, causing headaches and focal neurologic deficits.

Neuro-ophthalmic manifestations of an AVM depend on its location. Cortical AVMs in the occipital lobe may produce visual symptoms and headaches that resemble migraine. The visual phenomena are usually brief and unformed; typical migrainous scintillating scotomata may occur but are rare (see Chapter 13, Fig 13-1). AVM visual phenomena are always referable to the affected side, unlike migraine, which varies in laterality. Hemispheric AVMs may produce homonymous visual field defects. With brainstem AVMs, signs and symptoms are not specific and may include diplopia, nystagmus, dizziness, ocular motor nerve palsy, gaze palsy, anisocoria, or pupillary light–near dissociation. Transient monocular visual loss caused by a steal phenomenon from an intracranial AVM is rare.

Some patients with AVMs report a subjective intracranial bruit, and occasionally the examiner detects a bruit via auscultation of the skull over the AVM.

Dural AVMs account for 10%–15% of intracranial AVMs. A dural AVM, or abnormal arterial communication with one of the dural venous sinuses, elevates venous pressure and, in turn, increases intracranial pressure. Patients often have pulsatile tinnitus and an audible bruit in addition to signs and symptoms of increased intracranial pressure, leading to misdiagnosis as typical IIH (see Chapter 4). Dural AVMs should be considered when a patient does not fit the typical IIH demographics and there is no other demonstrable cause of increased intracranial pressure. These AVMs can be diagnosed with MRI/MRA and, if those results are negative, with catheter angiography.

### ***Diagnosis of arteriovenous malformations***

When bleeding is suspected, an unenhanced CT scan will show any hemorrhage. Although unruptured AVMs are typically apparent on an enhanced CT scan, MRI is more sensitive for visualizing small AVMs. MRI demonstrates the heterogeneous signals from the various elements of the lesion: blood vessels, brain, flowing and clotted blood, calcium, hemorrhage, and edema. Calcified AVMs are sometimes identifiable on plain radiography or CT. Cerebral angiography is required to show the anatomy clearly and to define the feeding and draining vessels of the AVM.

### ***Treatment of arteriovenous malformations***

The location of an AVM, the anatomy of the feeding and draining vessels, and the size of the lesion all affect treatment choice. Surgical resection, ligation of feeding vessels, embolization, and stereotactic radiosurgery can be used alone or in combination. Seizures usually improve with anticonvulsant therapy.

Crimmins M, Gobin YP, Patsalides A, Knopman J. Therapeutic management of cerebral arteriovenous malformations: a review. *Expert Rev Neurother*. 2015;15(12):1433–1444.

## **Cerebral Venous Thrombosis**

Occlusion of the cortical and subcortical veins causes focal neurologic symptoms and signs, including neuro-ophthalmic findings. Most commonly affected are the superior sagittal

sinus, cavernous sinus, and lateral (transverse) sinus, each of which produces a distinct clinical syndrome. During pregnancy, the lateral and superior sagittal sinuses are more commonly affected. Patients with thrombosis may present with headaches and papilledema, and the thrombosis could be confused with IIH (discussed at length in Chapter 4). Thus, when IIH is suspected in patients who do not fit the typical disease profile (eg, slim women and men), a diagnosis of cerebral venous thrombosis should be considered. Thrombosis of the deep veins may cause infarction of the thalamus or basal ganglia, and death may occur in 3%–15% of cases.

### ***Types of cerebral venous thrombosis***

**Superior sagittal sinus thrombosis** The most commonly thrombosed cerebral venous sinus is the superior sagittal sinus (SSS). Symptoms depend on the extent and location of the occlusion. With thrombosis of the anterior third of the sinus, symptoms are mild or absent. Posterior SSS thrombosis may produce a clinical picture similar to that of IIH (discussed at length in Chapter 4), with headaches and papilledema. In addition, seizures and motor deficits may occur in some patients with SSS thrombosis but are not typical in IIH.

**Cavernous sinus thrombosis** Cavernous sinus thrombosis (CST) in the *septic* form results from an infection of the face, oral cavity, or sphenoid or ethmoid sinuses. Otitis media or orbital cellulitis is a rare cause. Patients experience headache, nausea, vomiting, and somnolence. There may also be fever, chills, tachycardia, evidence of meningitis, or generalized sepsis. Ocular signs from anterior infection (facial, dental, or orbital) are initially unilateral but frequently become bilateral. They include orbital congestion, lacrimation, conjunctival edema, eyelid swelling, ptosis, proptosis, and ophthalmoplegia. CN VI palsy is the most consistent early neurologic sign. Corneal anesthesia, facial numbness, Horner syndrome, and venous stasis retinopathy can also occur.

Septic CST is a medical emergency; when it is not recognized promptly and treatment is not initiated immediately, it has a high mortality rate. The mainstay of therapy is early and aggressive antibiotic administration. Anticoagulation is often recommended as adjunctive therapy, and corticosteroids may help to reduce inflammation and edema. When feasible, the primary source of infection should be drained.

With *aseptic* CST, the signs and symptoms resemble those of septic CST, but clinical or laboratory examination shows no evidence of infection. Pain around the eye is common, but orbital congestion is typically less severe than with septic CST. Anticoagulation or antiplatelet therapy is often used.

**Lateral (transverse) sinus thrombosis** Lateral sinus thrombosis may be septic or spontaneous (see Chapter 2, Fig 2-17). Septic thrombosis may result from otitis media, but this has been rare since the widespread use of antibiotics. Patients with septic lateral sinus thrombosis have features of systemic infection as well as neck pain, tenderness of the ipsilateral jugular vein, retroauricular edema, and sometimes facial weakness. Severe facial pain also may occur and, when accompanied by CN VI palsy, is called *Gradenigo syndrome*. Nevertheless, lateral sinus thrombosis is much more likely to be spontaneous and produce an

IIH-like syndrome with increased intracranial pressure. The most common ophthalmic signs are papilledema and CN VI palsy.

### ***Diagnosis of cerebral venous thrombosis***

Neuroimaging is required to diagnose CVT. CT or MRI is often used initially, but a targeted venographic study, such as magnetic resonance venography (MRV) or CT venography (CTV), should be considered. Cerebral venography may be used when clinical suspicion for CVT is high but MRV or CTV findings are normal.

### ***Laboratory evaluation of cerebral venous thrombosis***

Prothrombotic conditions are present in 21%–34% of patients with CVT, most commonly protein C deficiency, protein S deficiency, presence of antiphospholipid and anticardiolipin antibodies, factor V Leiden, presence of the prothrombin G20210A mutation, and hyperhomocysteinemia. Other predisposing factors include pregnancy, use of oral contraceptives, and systemic conditions such as cancer, facial infections, inflammatory diseases, and hematologic diseases.

### ***Treatment of cerebral venous thrombosis***

Treatment of CVT, which is directed toward the underlying condition, includes use of anticoagulants, fibrinolytic drugs, and therapy to lower intracranial pressure. Antiepileptic drugs are used for patients with seizures. Corticosteroids are typically not used in CVT treatment unless required to manage the underlying inflammatory disease. Endovascular interventional therapy using modern approaches to intracranial recanalization may be needed in symptomatic patients showing resistance to medical treatment.

To ensure adequate treatment and prevent complications, patients with CVT may benefit from receiving care in a dedicated hospital stroke service.

Bushnell C, Saposnik G. Evaluation and management of cerebral venous thrombosis.

*Continuum (Minneapolis Minn)*. 2014;20(2 Cerebrovascular Disease):335–351.

Mokin M, Lopes DK, Binning MJ, et al. Endovascular treatment of cerebral venous thrombosis: contemporary multicenter experience. *Interv Neuroradiol*. 2015;21(4):520–526.

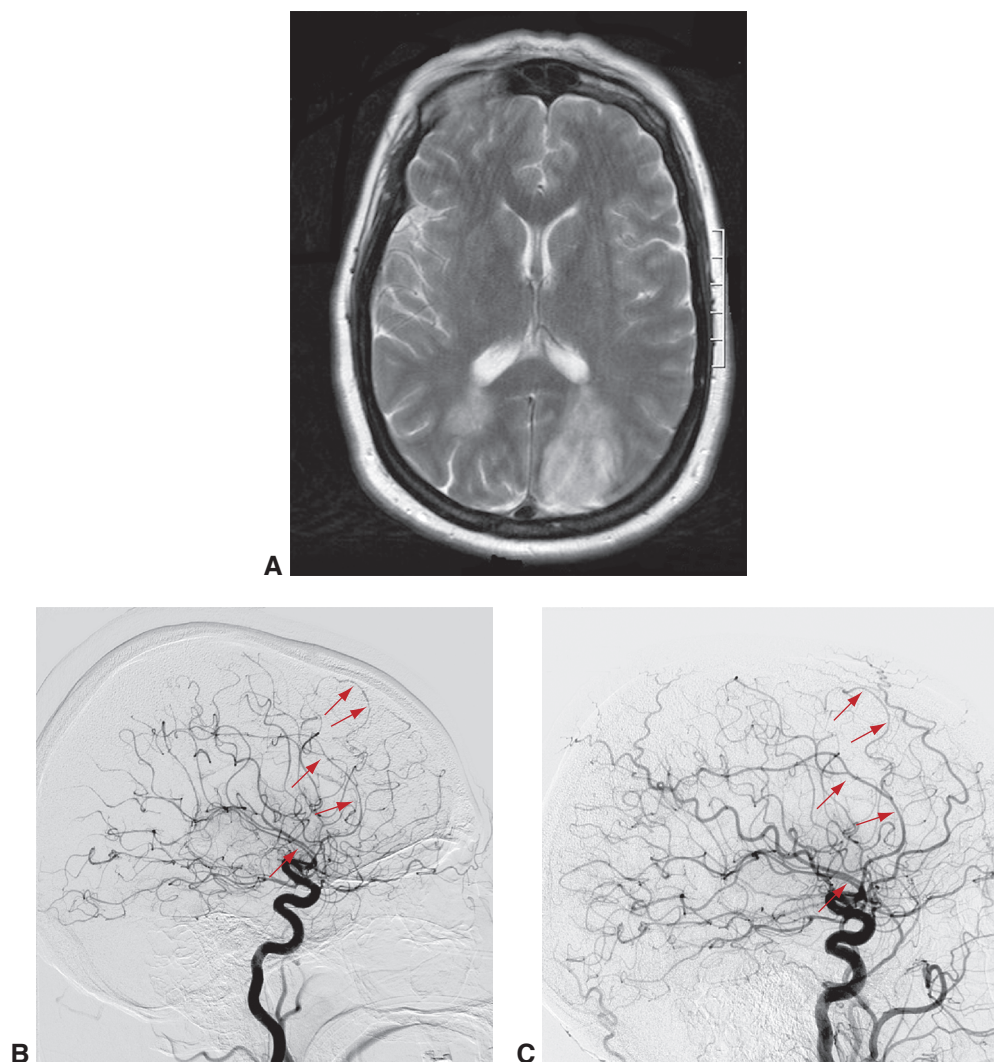
## **Reversible Cerebral Vasoconstriction Syndrome**

Reversible cerebral vasoconstriction syndrome (RCVS) is characterized by severe recurrent headaches (thunderclap headaches) with or without focal neurologic deficits and/or seizures, as well as segmental constriction of cerebral arteries that resolves within 3 months. Patients frequently report visual symptoms, including light sensitivity, blurred vision, and hemianopic visual field loss.

This syndrome is most common in middle-aged women, and more than one-half of RCVS cases occur during the postpartum period or after exposure to vasoactive substances (eg, selective serotonin reuptake inhibitors, triptans, amphetamines, ergotamine, nasal decongestants, or cannabis). Although the syndrome is usually self-limited and benign, it may lead to ischemic stroke or nonaneurysmal subarachnoid hemorrhage.

In patients with RCVS, MRA or conventional angiography may demonstrate the characteristic “string-of-beads” appearance of the cerebral arteries. Calcium channel blockers





**Figure 15-19** Reversible cerebral vasoconstriction syndrome in a 34-year-old woman presenting with headache and a right homonymous hemianopia. **A**, Axial T2-weighted MRI shows a bilateral occipital infarct that is greater on the left than on the right. **B**, Cerebral angiogram demonstrates multiple areas of segmental arterial narrowing (*arrows*). **C**, Areas of intracerebral vasoconstriction quickly improved 5 minutes after treatment with intravenous verapamil (*arrows*). (Courtesy of Hormozd Bozorgchami, MD.)

are standard therapies, but they have no proven effect on the syndrome's hemorrhagic and ischemic complications (Fig 15-19).

Raven ML, Ringeisen AL, McAllister AR, Knoch DW. Reversible cerebral vasoconstriction syndrome presenting with visual field defects. *J Neuroophthalmol.* 2016;36(2):187–190.

## Neuro-Ophthalmic Manifestations of Infectious Diseases

A great number of infectious diseases may have neuro-ophthalmic manifestations. The following sections cover the most common infections producing neuro-ophthalmic symptoms in the United States.

### Human Immunodeficiency Virus Infection

Neuro-ophthalmic disorders associated with human immunodeficiency virus (HIV) infection may result either directly from the infection or indirectly from secondary opportunistic infections, a malignancy, microvasculopathy, uveitis, or other causes. The eye, afferent visual pathways, and ocular motor system can all be affected. BCSC Section 1, *Update on General Medicine*, and Section 9, *Uveitis and Ocular Inflammation*, provide further information.

#### **Human immunodeficiency virus**

HIV infection causes acute and chronic CNS manifestations. Acute aseptic meningitis and meningoencephalitis affect 5%–10% of patients soon after an initial HIV infection. Headache, fever, and meningeal signs may accompany a mononucleosis-like syndrome. Occasionally, altered mental status, seizures, optic neuropathy, and cranial neuropathies occur, most commonly CN VII paresis.

*HIV encephalopathy*, also known as *acquired immunodeficiency syndrome (AIDS) dementia complex* or *HIV-associated neurocognitive disorder*, begins with impaired memory and concentration, behavioral changes, and mental slowness. Abnormal pursuit, saccadic eye movements, and saccadic intrusions (square-wave jerks) may also be present. Late manifestations include profound dementia, behavioral changes, psychosis, psychomotor impairment, weakness, visual neglect, visual hallucinations, seizures, and tremor. In addition, an optic neuropathy may develop. MRI demonstrates cerebral atrophy and hyperintense areas of white matter on T2-weighted images that correspond to areas of demyelination produced by the virus.

Ocular signs of HIV infection include cotton-wool spots, perivasculitis, and retinal hemorrhages. Subtle structural and functional retinal and optic nerve abnormalities, termed *HIV-associated neuroretinal disorder (HIV-NRD)*, have been reported in patients with HIV infection without infectious retinitis or apparent ophthalmoscopic abnormalities. Risk factors for this disorder include low CD4<sup>+</sup> T-cell counts, detectable HIV RNA in the blood, and hepatitis C infection. Patients with HIV-NRD may demonstrate thinning of the retinal nerve fiber layer, subtle loss of color vision and/or contrast sensitivity, visual field deficits, and subnormal electrophysiologic responses. Studies found that HIV-NRD is associated with increased mortality and increased risk of bilateral visual impairment. Anti-retroviral therapy decreases but does not eliminate the risk of HIV-NRD.

Jabs DA, Drye L, Van Natta ML, Thorne JE, Holland GN; Studies of the Ocular Complications of AIDS Research Group. Incidence and long-term outcomes of the human immunodeficiency virus neuroretinal disorder in patients with AIDS. *Ophthalmology*. 2015;122(4):760–768.

### **Central nervous system lymphoma**

After Kaposi sarcoma, which is the most common AIDS-associated neoplasia of the eyelid or conjunctiva, high-grade B-cell non-Hodgkin lymphoma is the second-most common malignancy in patients with AIDS and the most common neoplasm to affect the CNS. CNS lymphoma can cause diplopia from CN III, IV, or VI involvement. Lymphomatous infiltration of the orbit and optic nerve may lead to ONH swelling and vision loss.

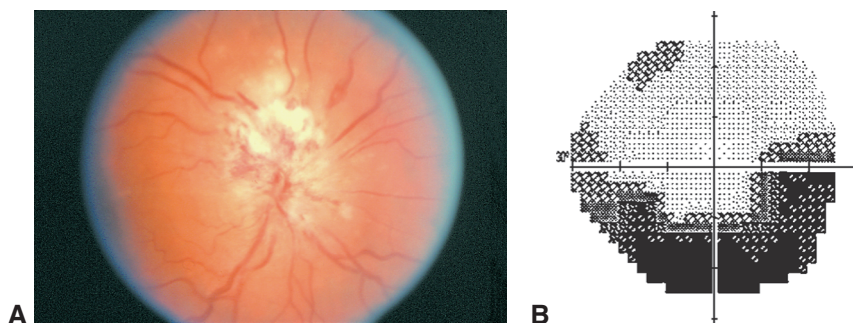
CNS lymphoma is diagnosed by confirming the presence of neoplastic lymphomatous cells in the CSF or through results of stereotactic brain or meningeal biopsy. Changes observed on MRI may resemble those of toxoplasmosis, but they are typically periventricular with subependymal spread. Treatment consists of combined radiotherapy and chemotherapy.

### **Cytomegalovirus**

Cytomegalovirus (CMV) infection is a common opportunistic condition and a major cause of vision loss in patients with HIV infection. CMV retinitis is often the presenting sign of untreated advanced HIV infection, primarily in patients with extremely low CD4<sup>+</sup> T-lymphocyte cell counts. Within the CNS, CMV infection causes optic neuritis and brainstem encephalitis. Anterior optic nerve infection produces acute loss of vision with ONH swelling; this condition usually occurs in patients with severe CMV retinitis. In other patients, anterior optic neuropathy presents with minimal retinitis (Fig 15-20). Posterior optic neuropathy, which is rare, is characterized by slowly progressive loss of vision without ONH edema. Brainstem involvement may cause ptosis, internuclear ophthalmoplegia, ocular motor CN palsies, horizontal and vertical gaze paresis, and nystagmus.

CMV infection is diagnosed clinically on the basis of characteristic ocular findings. Results of serologic tests and cultures may be inconclusive. Polymerase chain reaction testing of CSF is an important molecular diagnostic tool. See BCSC Section 9, *Uveitis and Ocular Inflammation*, for a complete discussion of CMV diagnosis and treatment.

Butler NJ, Thorne JE. Current status of HIV infection and ocular disease. *Curr Opin Ophthalmol*. 2012;23(6):517–522.



**Figure 15-20** Cytomegalovirus (CMV) optic neuritis in the setting of HIV seropositivity. **A**, Fundus photograph shows optic nerve head appearance in a 42-year-old woman who presented 3 weeks after noticing inferior shadows in the right eye. Visual acuity was 20/20, but visual field testing (**B**) demonstrated an inferior arcuate visual field defect. (Courtesy of Steven A. Newman, MD.)

## Herpesvirus

Herpes simplex virus (human herpesvirus 1 and 2) and varicella-zoster virus can cause acute outer retinal necrosis, resulting in photophobia, ocular pain, floaters, and decreased visual acuity. Ophthalmic findings include panuveitis, vitritis, retinal arteritis, ONH edema, and a necrotizing retinitis that initially spares the posterior pole. See BCSC Section 1, *Update on General Medicine*, and Section 9, *Uveitis and Ocular Inflammation*, for further information.

The most common neurologic manifestation of herpes infection is CNS encephalitis (Fig 15-21). Radiculitis may occur, producing Ramsay Hunt syndrome (see Chapter 12) and herpes zoster ophthalmicus (HZO). Neuro-ophthalmic complications of HZO include ischemic optic neuropathy, optic neuritis, and ocular motor CN palsy. In most cases, HZO-induced ophthalmoplegia occurs within 2 weeks of onset of the HZO rash.

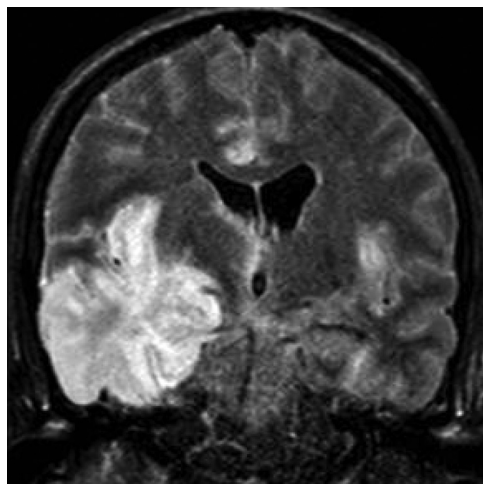
Treatment with oral antiviral therapy and oral corticosteroids is usually recommended. This self-limiting ophthalmoplegia improves over the course of several months, and most patients recover from the diplopia, at least in primary gaze.

Marra F, Ruckenstein J, Richardson K. A meta-analysis of stroke risk following herpes zoster infection. *BMC Infect Dis.* 2017;17(1):198.

## Mycobacterium

*Mycobacterium tuberculosis* and *Mycobacterium avium-intracellulare* complex can infect the brain and eye. The neuro-ophthalmic manifestations of tuberculous meningitis include photophobia, CN III and VI paresis, papilledema, retrobulbar optic neuritis, and anisocoria. Cerebral infarction can result from obliterative endarteritis.

Neuroimaging studies may show hydrocephalus, abscess formation, and granulomas, as well as enhanced basal meninges with contrast agent administration. Treatment of mycobacterial infection involves use of multiple medications including ethambutol; however, this medication can cause bilateral, progressive, painless optic neuropathy (see Chapter 4).



**Figure 15-21** Herpes simplex virus encephalitis. Coronal FLAIR MRI scan showing signal abnormalities affecting the temporal lobes (right greater than left). (Courtesy of Bronwyn Hamilton, MD.)

## Syphilis

Syphilis is a chronic multisystem bacterial disease caused by the spirochete *Treponema pallidum* that has been associated with numerous ophthalmic and neurologic manifestations. Although syphilis can be resolved with appropriate antimicrobial therapy, a delay in diagnosis can result in significant ocular and neurologic morbidity. See BCSC Section 1, *Update on General Medicine*, and Section 9, *Uveitis and Ocular Inflammation*, for an extensive review of syphilis.

## Progressive Multifocal Leukoencephalopathy

Originally described in immunocompromised patients with lymphoproliferative disorders and impaired cell-mediated immunity, progressive multifocal leukoencephalopathy (PML) occurs in 1%–4% of patients with HIV infection and has been reported in patients with MS treated with immunomodulating medications such as natalizumab. The disease is caused by the JC (John Cunningham) virus, a ubiquitous polyomavirus that infects oligodendrocytes. Gray matter is relatively spared, but the central visual pathways and ocular motor fibers can be affected. Neuro-ophthalmic manifestations include homonymous hemianopia, blurred vision, cerebral blindness, prosopagnosia, and diplopia. Other neurologic findings are altered mental status, ataxia, dementia, hemiparesis, and focal deficits. Behavioral and cognitive abnormalities are very common.

In patients with PML, MRI shows areas of demyelination, most frequently in the parieto-occipital region. The disease typically involves the subcortical white matter, with nonenhancing focal or confluent lesions (Fig 15-22). Therapy is aimed at correcting the underlying immune deficiency state, but prognosis is poor. In some cases, plasma exchange may be helpful.

Sørensen PS, Bertolotto A, Edan G, et al. Risk stratification for progressive multifocal leukoencephalopathy in patients treated with natalizumab. *Mult Scler*. 2012;18(2):143–152.

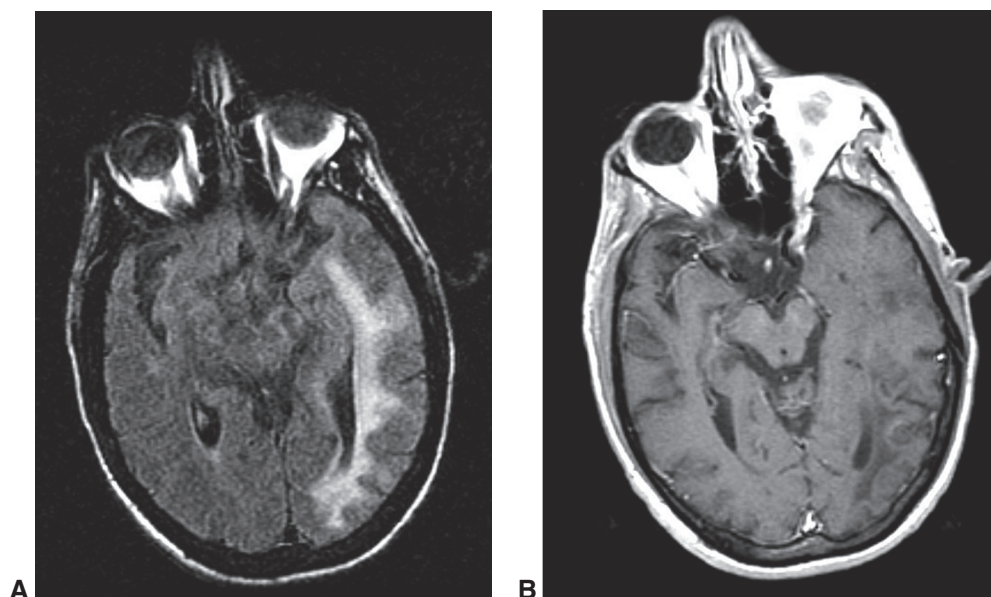
Sudhakar P, Bachman DM, Mark AS, Berger JR, Kedar S. Progressive multifocal leukoencephalopathy: recent advances and a neuro-ophthalmological review. *J Neuro-ophthalmol*. 2015;35(3):296–305.

## Toxoplasmosis

Toxoplasmosis is the most common cause of infectious posterior uveitis in adults and children. Detailed information and ocular manifestations, which are common, are discussed in BCSC Section 1, *Update on General Medicine*, and Section 9, *Uveitis and Ocular Inflammation*.

CNS toxoplasmosis is often associated with immune deficiency. However, toxoplasmosis optic neuritis, characterized by subacute visual loss and ONH swelling and at times accompanied by a macular star (neuroretinitis), is rare. CNS toxoplasmosis produces multifocal lesions, with a predilection for the basal ganglia and the frontal, parietal, and occipital lobes. Patients experience headaches, focal neurologic deficits, seizures, mental status changes, and fever. Neuro-ophthalmic findings include homonymous hemianopia and quadrantanopia, ocular motor CN palsies, and gaze palsies. Long-term antitoxoplasmosis treatment is necessary to prevent recurrences.





**Figure 15-22** Progressive multifocal leukoencephalopathy (PML) in a patient with AIDS. **A**, Axial FLAIR image demonstrates increased signal in the left occipital lobe white matter that extends anteriorly. **B**, Axial gadolinium-enhanced T1-weighted spin-echo image (same location as in **A**) demonstrates a nonenhancing hypointense lesion in the left occipital white matter. T1 hypointensity is typical of PML lesions. Note the absence of mass effect and negligible enhancement. (Courtesy of Joel Curé, MD.)

MRI typically shows multiple lesions that are isointense with the brain on T1-weighted images and isointense or hyperintense on T2-weighted images, and they enhance after gadolinium administration.

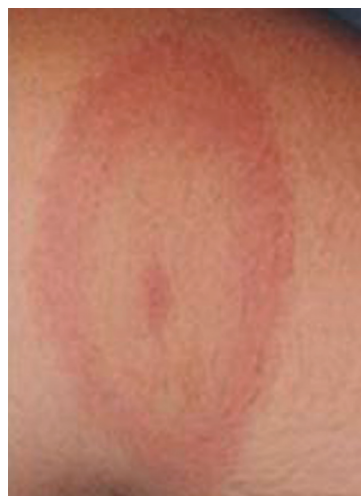## Lyme Disease

Lyme borreliosis is caused by infection with *Borrelia burgdorferi*, a spirochete transmitted by deer ticks. The disease, which typically occurs in 3 stages, can have ocular and neuro-ophthalmic manifestations. During *stage 2*, neuro-ophthalmic findings, including papilledema (IIH-like syndrome), optic neuritis, papillitis, neuroretinitis, and orbital myositis, occur along with various uveitic entities. Two-thirds of patients have ocular findings at this stage. Cranial neuropathies can also occur, most commonly CN VII palsy, as well as radiculopathies and meningitis with headache and neck stiffness. In *stage 3*, neurologic conditions (neuroborreliosis) predominate, including chronic encephalomyelitis, spastic paraparesis, ataxic gait, subtle mental disorders, and chronic radiculopathy. The neurologic picture may clinically and radiographically resemble that of MS. In rare instances, Lyme disease can cause repeated cerebrovascular events in multiple locations within short intervals.

The diagnosis of Lyme disease is made clinically after the patient has been exposed to an endemic area (the patient might not recall a tick bite but may have had the typical erythema chronicum migrans rash seen in stage 1 (Fig 15-23). An elevated Lyme antibody titer in the serum or CSF is helpful. The enzyme-linked immunosorbent assay (ELISA)



**Figure 15-23** Erythema chronicum migrans, the characteristic rash of stage 1 Lyme disease. (Courtesy of Robert L. Lesser, MD.)



is typically used for screening, but a positive Western blot result confirms the diagnosis. Treatment should be orchestrated by a specialist in infectious diseases.

Lyme disease is discussed further in BCSC Section 1, *Update on General Medicine*, and Section 9, *Uveitis and Ocular Inflammation*.

Träisk F, Lindquist L. Optic nerve involvement in Lyme disease. *Curr Opin Ophthalmol*. 2012;23(6):485–490.

## Fungal Infections

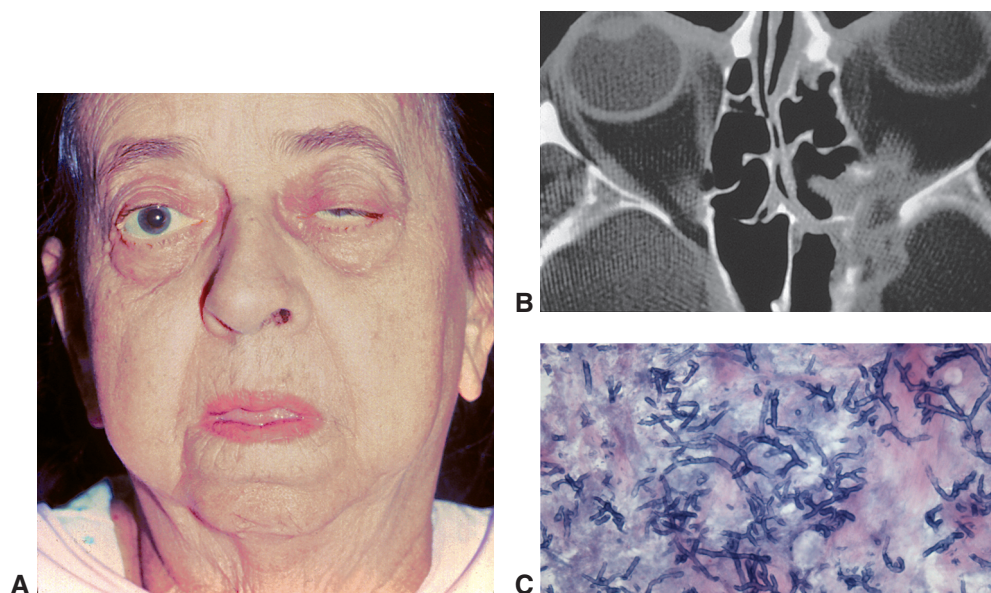
The 2 main types of fungi are molds and yeasts, although some fungi can have characteristics of both. Molds (filamentous fungi) are composed of hyphae, which extend and branch to form a mycelium, enabling them to grow. Molds reproduce when a portion of the hyphae breaks off. CNS infections caused by molds are aspergillosis and mucormycosis.

Yeasts are round, with outpouchings called buds or pseudohyphae. They are septated and reproduce by budding: The parent cell divides, and one of the daughter nuclei migrates into a bud on the surface of a cell. Coccidioidomycosis, cryptococcosis, and histoplasmosis are caused by yeasts. *Candida* can grow as a yeast or a mold.

### **Aspergillosis**

The most frequent mode of transmission of *Aspergillus* species is inhalation of spores. The mold causes 3 main types of disease: allergic aspergillosis, aspergillomas, and invasive aspergillosis. Allergic aspergillosis affects the bronchopulmonary system and the paranasal sinuses. Allergic *Aspergillus* sinusitis occurs in immunocompetent patients with chronic sinusitis and nasal polyposis. It can invade the orbit, especially with sphenoid sinus involvement, and can cause secondary optic neuropathy, proptosis, diplopia, and retrobulbar pain.

Aspergillomas, or fungus balls, may arise in the orbit, paranasal sinuses, or brain in either immunocompromised or immunocompetent patients. Orbital aspergillomas produce symptoms of orbital masses, with proptosis, vision loss, diplopia, and pain. Orbital lesions



**Figure 15-24** Sino-orbital aspergillosis in an 82-year-old woman who presented with a 6-week history of left brow and orbital pain. **A**, Four weeks before evaluation, she suddenly lost vision in her left eye, and ptosis and proptosis developed 1 week later. **B**, A computed tomography scan revealed a destructive lesion at the orbital apex. **C**, Biopsy of the lesion showed septate hyphae consistent with aspergillosis. (Part C courtesy of Julie Falardeau, MD.)

also typically involve the sinuses or brain, whereas extension to the optic canal, cavernous sinus, optic nerves, and optic chiasm produces neuro-ophthalmic findings (Fig 15-24). Intracranial aspergillomas act like mass lesions, causing progressive neurologic deficits.

Invasive aspergillosis typically occurs in immunocompromised patients; however, the disease can also affect immunocompetent patients. Most patients initially have pulmonary involvement, although the skin, orbit, or sinuses may be the nidus of infection. CNS infection occurs secondarily by either direct or hematogenous spread of organisms. Ophthalmic manifestations include acute retrobulbar optic neuropathy, endophthalmitis, orbital apex syndrome, and cavernous sinus syndrome. The presentation of invasive aspergillosis is highly variable and can mimic malignancy, idiopathic orbital inflammatory syndrome, GCA, and bacterial cellulitis. Vascular invasion produces cerebral infarction or hemorrhage. Serious sequelae of invasive aspergillosis are meningitis, intracranial abscess, epidural and subdural hematoma, mycotic aneurysm formation, and encephalitis.

Treatment of aspergillosis includes antifungal agents such as voriconazole, isavuconazole, and liposomal or lipid-complex amphotericin B. Voriconazole may be associated with transient visual disturbances. Surgical intervention is often necessary to treat aspergillomas and invasive aspergillosis. The mortality rate for invasive aspergillosis varies from 40% to 80%, depending on predisposing risk factors.

Thurtell MJ, Chiu ALS, Goold LA, et al. Neuro-ophthalmology of invasive fungal sinusitis: 14 consecutive patients and a review of the literature. *Clin Exp Ophthalmol*. 2013;41(6):567–576.

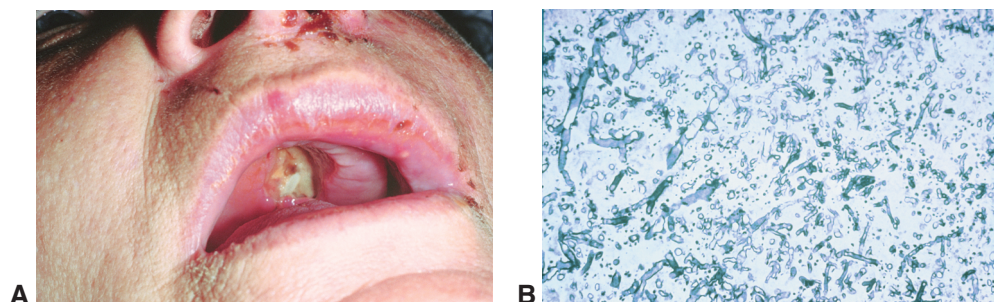
## Zygomycosis

Zygomycetes (genus *Mucor* or *Rhizopus*) are ubiquitous organisms that typically have low virulence except in debilitated hosts. The molds enter the body through the respiratory tract and proliferate, causing hyphal invasion of tissues. They grow rapidly, producing a more acute infection than other fungi. Because these organisms have a predilection for blood vessels, hemorrhage, thrombosis, and ischemic necrosis are hallmarks of the disease. Rupture of aneurysms and pseudoaneurysms in the intracranial vasculature can have devastating consequences.

The 2 types of zygomycosis (also known as *mucormycosis* or *phycomycosis*) that cause ophthalmic involvement are rhinocerebral zygomycosis and CNS zygomycosis. Rhinocerebral zygomycosis usually occurs in patients with diabetes mellitus, patients taking corticosteroids, or neutropenic patients receiving antibiotics. The initial infection occurs in the facial skin, nasal mucosa, paranasal sinuses, or hard palate (Fig 15-25). The fungus then spreads to nearby blood vessels, affecting the orbital vessels, carotid arteries, cavernous sinuses, or jugular veins. Orbital and neurologic signs are produced by infarction, thrombosis, or hemorrhage. Retinal infarction, ophthalmic artery occlusion, and optic nerve infiltration are mechanisms of blindness. Neurologic signs include hemiparesis, aphasia, seizures, and altered mental status. If untreated, rhinocerebral zygomycosis can cause rapid deterioration, leading to death within days. In contrast, a few patients may have a chronic course with little indication of systemic illness. The most common signs and symptoms include fever, nasal necrosis, periorbital swelling, decreased vision, ophthalmoplegia, sinusitis, and headache.

In contrast, CNS zygomycosis is very rare. The fungus usually gains access to the CNS from the nose or paranasal sinus, but nasal, sinus, ocular, or orbital disease is absent when neurologic manifestations appear. Instead, infection of the orbit, palate, nose, and sinuses typically occurs secondarily. Meningitis, abscesses, CN involvement, and seizures are common.

The diagnosis of zygomycosis requires a high index of suspicion. Clinically, examination of the nasal cavity for evidence of a black eschar, which may be accompanied by purulent discharge, is best accomplished by an otolaryngologist. CT may demonstrate bone destruction, soft-tissue alteration in the paranasal sinuses and orbit, air–fluid levels in the sinuses and orbits, or brain abscess formation. MRI, MRA, and arteriography may also demonstrate



**Figure 15-25** Rhinocerebral zygomycosis. **A**, Erosion of the hard palate. **B**, Biopsy specimen demonstrates typical nonseptate hyphae. (Courtesy of Lanning B. Kline, MD.)

vascular thrombosis. However, the definitive test is a biopsy specimen that shows vascular invasion, tissue necrosis, eschar formation, inflammatory cells, and nonseptate hyphae (by histologic examination).

Zygomycosis has a high mortality rate, but prompt diagnosis and aggressive therapy may be life-saving. The underlying systemic disease should be treated and immunosuppressant agents eliminated, if possible. Therapy includes aggressive surgical debridement of necrotic tissue and administration of antifungal agents both locally and systemically. Hyperbaric oxygen has been used as adjuvant therapy.

Gamaletsou MN, Sipsas NV, Roilides E, Walsh TJ. Rhino-orbital-cerebral mucormycosis.

*Curr Infect Dis Rep.* 2012;14(4):423–434.

Trief D, Gray ST, Jakobiec FA, et al. Invasive fungal disease of the sinus and orbit: a comparison between mucormycosis and *Aspergillus*. *Br J Ophthalmol.* 2016;100(2):

184–188.

### **Cryptococcosis**

Cryptococcosis is a fungal disease caused mainly by *Cryptococcus neoformans* and *Cryptococcus gattii*. Inhalation of these fungi and subsequent pulmonary infection may spread to the CNS, causing meningitis or meningoencephalitis. Although *C neoformans*, which is found in pigeon droppings and contaminated soil, is ubiquitous, it rarely causes infection in otherwise healthy people. Affected individuals are typically immunocompromised, predominantly patients with HIV infection or AIDS. In contrast, *C gattii* typically grows in soil around various trees; it can produce severe meningoencephalitis as well as pulmonary disease in immunocompromised or immunocompetent individuals. It is the most common cause of meningitis in HIV-infected individuals.

The most common neuro-ophthalmic abnormality of cryptococcosis is papilledema from cryptococcal meningitis. Retrobulbar optic neuritis may also be present, with gradual loss of vision over hours to days. Other ophthalmic complications include retinochoroiditis and cotton-wool spots. Cranial neuropathies may occur, including unilateral or bilateral CN VI palsies. Photophobia, blurred vision, retrobulbar pain, homonymous visual field defects, or nystagmus may also occur. The onset of symptoms is usually insidious, with a waxing and waning course. Headache, nausea, vomiting, dizziness, and mental status changes are most commonly reported.

Diagnosis of cryptococcosis is confirmed by isolating the yeast in the CSF or by demonstrating the capsular antigen for *C neoformans* or *C gattii*. In most patients with CNS cryptococcosis, the disease is disseminated; there is evidence of infection in the blood, lungs, bone marrow, skin, kidneys, and other organs. Serum antigen titers are helpful for this reason.

Antifungal treatment should be urgently initiated, and aggressive management of intracranial hypertension is often needed. Vision loss caused by papilledema may be treated with CSF shunting or optic nerve sheath fenestration. The mortality rate of patients with treated CNS cryptococcosis is 25%–30%. The prognosis is worse in patients with an underlying malignancy or AIDS.

Franco-Paredes C, Womack T, Bohlmeier T, et al. Management of *Cryptococcus gattii* meningoencephalitis. *Lancet Infect Dis.* 2015;15(3):348–355.

## Prion Diseases

Prion diseases, also known as *transmissible spongiform encephalopathies*, include kuru in New Guinea; sporadic Creutzfeldt-Jakob disease (sCJD), which is found worldwide; familial CJD (fCJD); and variant CJD (vCJD), which is found mostly in the United Kingdom and France. vCJD has been linked to bovine spongiform encephalopathy (“mad cow” disease), a prion disease in cattle. Other rare prion diseases include fatal familial insomnia (a rare hereditary disorder that causes difficulty sleeping) and Gerstmann-Sträussler-Scheinker syndrome (an extremely rare disorder that typically occurs around age 40 years).

Prions are infectious agents formed by the conversion of a normal cell surface protein (PrP<sup>C</sup>) to a misfolded cell surface protein called PrP<sup>CJD</sup> or PrP<sup>SC</sup> (“SC” stands for the animal prion disease scrapie). sCJD may result from somatic mutation in the prion protein gene or, more likely, from the spontaneous, random conversion of a normal prion protein to an abnormal prion protein and the subsequent expansion of the altered form. Approximately 10% of CJD cases are familial, resulting from inherited mutations in the *PRNP* gene.

The most commonly reported visual manifestations of CJD include diplopia, supranuclear palsies, complex visual disturbances, homonymous visual field defects, hallucinations, and cortical visual impairment. In the Heidenhain variant of CJD, patients present primarily with isolated visual symptoms. Because of the complex clinical manifestations, this rare but clinically distinct group of patients with sCJD may pose a diagnostic dilemma. Early cortical changes may be observed on diffusion-weighted and FLAIR MRI, whereas a PET scan may reveal hypometabolism in posterior cortical regions.

Diagnostic testing for prion disease includes MRI, electroencephalography (EEG), lumbar puncture, and possibly brain biopsy. Diffusion-weighted MRI shows typical high-intensity caudate and/or putamen lesions, and EEG shows characteristic periodic sharp wave complexes. CSF usually contains the 14-3-3 protein. For prion detection, real-time quaking-induced conversion (RT-QuIC) is a fast and efficient protein amplification technique applied to the CSF. Brain histologic studies can also reveal spongiform degeneration.

No treatment is currently available for prion diseases. CJD is uniformly fatal, with a rapidly progressive dementia and death usually within 8 months.

Geschwind MD. Prion diseases. *Continuum (Minneapolis)*. 2015;21(6 Neuroinfectious Disease):1612–1638.

## Radiation Therapy

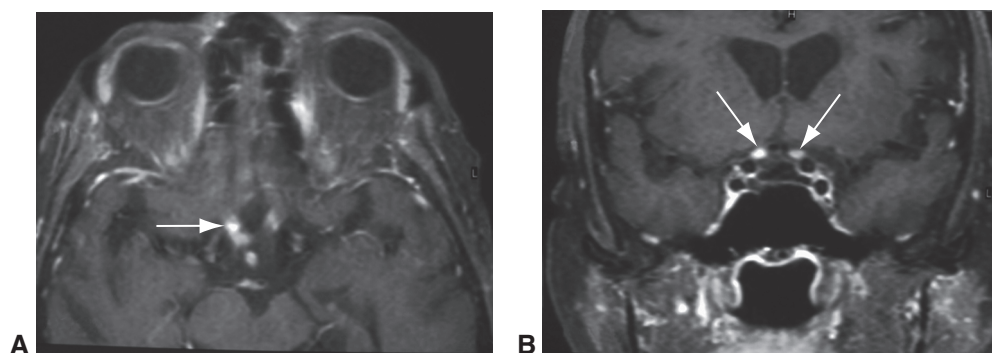
Several types of radiation therapy (RT) are currently available, with standard techniques continuously evolving and new ones emerging with scientific advances (see BCSC Section 1, *Update on General Medicine*). Traditional whole-brain RT, which is used to treat cerebral malignancies, is delivered in fractions over approximately 4–6 weeks. In 3-dimensional conformal RT, a computer helps concentrate radiation in a precise area; this concentration is accomplished through the use of complex, asymmetric, 3-dimensional shapes. In contrast, radiation surgery (radiosurgery) refers to linear accelerator or gamma knife techniques that are distinct from traditional fractionated RT. Radiosurgery is typically conducted in a single sitting, using computer-based techniques to focus radiation at



the desired regions. Radiation therapies are used to treat malignancies, vascular malformations, and occasionally inflammatory lesions. Tumors that are very close to anterior visual pathway structures may not be suitable targets for single-fraction radiosurgery; thus, linear accelerator, gamma knife, or proton-beam techniques are often used.

Complications resulting from RT directed at the CNS may take several forms and can occur years after therapy. Immediate complications include transient swelling of the involved tissue. Later complications of neuro-ophthalmic interest include radiation necrosis, cranial neuropathies, and ocular neuromyotonia (see Chapter 8). *Radiation necrosis* involves death of nervous system tissue with attendant edema. This complication may simulate the appearance of recurrent neoplasm on traditional MRI or CT imaging. Occasionally, functional imaging techniques such as PET or magnetic resonance spectroscopy are required to separate these entities radiographically; neoplasms generally display a hypermetabolic profile, whereas radiation necrosis is hypometabolic in nature.

Of greater concern to the neuro-ophthalmologist is *radiation optic neuropathy (RON)*. The mechanism likely involves formation of free radicals with damage to tissue, as well as loss of vascular endothelium and ischemic injury. Patients typically present with acute, painless vision loss, which progresses over months. RON most commonly occurs between 10 and 20 months after treatment, with peak incidence at 12–18 months. RON is in part dose related and more likely to occur with higher doses of radiation (often >50 Gy in fractions <2 Gy). Single doses >10 Gy also increase risk. Other factors that increase susceptibility include increasing age, diabetes mellitus, and concurrent chemotherapy. The main differential is recurrence of the original tumor, so neuroimaging is mandatory. MRI can exclude tumor recurrence and help confirm the diagnosis of RON. MRI of the anterior visual pathways in patients with RON usually demonstrates enhancement of the optic nerve(s) on postcontrast T1-weighted sequences (Fig 15-26). No proven effective treatment for RON exists, although hyperbaric oxygen, corticosteroids, pentoxifylline/vitamin E, and intravitreal or IV bevacizumab have all been attempted with variable and usually unsatisfactory results. Challenges to assessing the efficacy of any treatment include the



**Figure 15-26** Bilateral radiation optic neuropathy (RON) occurring months after radiation therapy for a pituitary adenoma. Axial (**A**) and coronal (**B**) T1-weighted, fat-suppressed MRI scans performed after gadolinium injection demonstrate enhancing optic nerves (arrows) in the pre-chiasmal region. (Courtesy of Eric Eggenberger, DO.)



rarity of the condition, delay in diagnosis, and variable timing of interventions. Visual outcomes are generally poor.

Another condition typically occurring many years after radiation therapy is *stroke-like migraine attacks after radiation therapy (SMART)*, a syndrome related to delayed complications from brain irradiation for CNS malignancies. Patients present with recurrence of complex neurologic signs and symptoms, including headache, visual disturbances, and seizures. Debilitating stroke-like deficits such as homonymous hemianopia, hemiplegia, and/or aphasia typically resolve over an average of 2 months; however, in some cases, the neurologic recovery is incomplete. MRI findings include unilateral increased T2 signal within the temporal, parietal, or occipital cortex with pronounced gyral cortical gray matter enhancement. As symptoms resolve, the MRI findings disappear.

Stieber VW. Radiation therapy for visual pathway tumors. *J Neuroophthalmol.* 2008;28(3):222–230.

# Additional Materials and Resources

## Related Academy Materials

---

The American Academy of Ophthalmology is dedicated to providing a wealth of high-quality clinical education resources for ophthalmologists.

### Print Publications and Electronic Products

For a complete listing of Academy clinical education products, visit our online store at:  
<https://store.aao.org/clinical-education.html>

Or call Customer Service at 866.561.8558 (toll free, US only) or +1 415.561.8540, Monday through Friday, between 8:00 a.m. and 5:00 p.m. (PST).

### Online Resources

Visit the Ophthalmic News and Education (ONE®) Network at <https://www.aao.org/neuro-ophthalmology-orbit> to find relevant videos, online courses, journal articles, practice guidelines, self-assessment quizzes, images, and more. The ONE Network is a free Academy-member benefit.

Access free, trusted articles and content with the Academy's collaborative online encyclopedia, EyeWiki, at [aao.org/eyewiki](http://aao.org/eyewiki).

Get mobile access to the *Wills Eye Manual*, watch the latest 1-minute videos, and set up alerts for clinical updates relevant to you with the AAO Ophthalmic Education App. Download today: Search for "AAO Ophthalmic Education" in the Apple app store or in Google Play.

## Basic Texts and Additional Resources

---

Barton JJS, Benatar M. *Field of Vision. A Manual and Atlas of Perimetry*. Humana Press; 2003.

Bhatti MT, Schmalzfuss I. *Handbook of Neuroimaging for the Ophthalmologist*. JP Medical Ltd; 2014.

Biousse V, Newman NJ. *Neuro-Ophthalmology Illustrated*. 3rd ed. Thieme; 2019.

Brodsky MC. *Pediatric Neuro-Ophthalmology*. 3rd ed. Springer; 2016.

Foroozan R, Vaphiades MS. *Kline's Neuro-Ophthalmology Review Manual*. 8th ed. Slack; 2018.

Gold DH, Weingeist TA, eds. *Color Atlas of the Eye in Systemic Disease*. Lippincott Williams & Wilkins; 2001.

Harrington DO, Drake MV. *The Visual Fields: Textbook and Atlas of Clinical Perimetry*. 6th ed. Elsevier/Mosby; 1990.

Lee AG, Kline LB, Brazis PW, eds. *Curbside Consultation in Neuro-Ophthalmology: 49 Clinical Questions*. 2nd ed. Slack; 2015.

- Leigh RJ, Zee DS. *The Neurology of Eye Movements*. 5th ed. Oxford University Press; 2015.
- Liu GT, Volpe NJ, Galetta SL. *Liu, Volpe, and Galetta's Neuro-Ophthalmology: Diagnosis and Management*. 3rd ed. Elsevier/Saunders; 2018.
- Loewenfeld IE. *The Pupil: Anatomy, Physiology, and Clinical Applications*. 2 vols. Elsevier/ Butterworth-Heinemann; 1999.
- Miller NR, Newman NJ, Biousse V, Kerrison JB, eds. *Walsh and Hoyt's Clinical Neuro-Ophthalmology: The Essentials*. 6th ed. 3 vols. Lippincott Williams & Wilkins; 2005.
- Trobe JD. *The Neurology of Vision*. Oxford University Press; 2001.
- Wong AMF. *Eye Movement Disorders*. Oxford University Press; 2008.

## Requesting Continuing Medical Education Credit

The American Academy of Ophthalmology is accredited by the Accreditation Council for Continuing Medical Education (ACCME) to provide continuing medical education for physicians.

The American Academy of Ophthalmology designates this enduring material for a maximum of 15 *AMA PRA Category 1 Credits™*. Physicians should claim only the credit commensurate with the extent of their participation in the activity.

To claim *AMA PRA Category 1 Credits™* upon completion of this activity, learners must demonstrate appropriate knowledge and participation in the activity by taking the posttest for Section 5 and achieving a score of 80% or higher.

There is no formal American Board of Ophthalmology (ABO) approval process for self-assessment activities. Any CME activity that qualifies for ABO Continuing Certification credit may also be counted as “self-assessment” as long as it provides a mechanism for individual learners to review their own performance, knowledge base, or skill set in a defined area of practice. For instance, grand rounds, medical conferences, or journal activities for CME credit that involve a form of individualized self-assessment may count as a self-assessment activity.

### To take the posttest and request CME credit online:

1. Go to [www.aao.org/cme-central](http://www.aao.org/cme-central) and log in.
2. Click on “Claim CME Credit and View My CME Transcript” and then “Report AAO Credits.”
3. Select the appropriate media type and then the Academy activity. You will be directed to the posttest.
4. Once you have passed the test with a score of 80% or higher, you will be directed to your transcript. *If you are not an Academy member, you will be able to print out a certificate of participation once you have passed the test.*

CME expiration date: June 1, 2024. *AMA PRA Category 1 Credits™* may be claimed only once between June 1, 2021 (original release date), and the expiration date.

For assistance, contact the Academy’s Customer Service department at 866.561.8558 (US only) or + 1 415.561.8540 between 8:00 a.m. and 5:00 p.m. (PST), Monday through Friday, or send an e-mail to [customer\\_service@aao.org](mailto:customer_service@aao.org).



# Study Questions

Please note that these questions are not part of your CME reporting process. They are provided here for your own educational use and for identification of any professional practice gaps. The required CME posttest is available online (see “Requesting Continuing Medical Education Credit”). Following the questions are answers with discussions. Although a concerted effort has been made to avoid ambiguity and redundancy in these questions, the authors recognize that differences of opinion may occur regarding the “best” answer. The discussions are provided to demonstrate the rationale used to derive the answer. They may also be helpful in confirming that your approach to the problem was correct or, if necessary, in fixing the principle in your memory. The Section 5 faculty thanks the Resident Self-Assessment Committee for drafting these self-assessment questions and the discussions that follow.

1. Which nerve courses along the surface of the clivus?
  - a. abducens
  - b. oculomotor
  - c. trigeminal
  - d. trochlear
2. Which imaging technique is preferred to detect an acute subarachnoid hemorrhage?
  - a. magnetic resonance imaging (MRI)
  - b. computed tomography (CT)
  - c. magnetic resonance angiography (MRA)
  - d. computed tomography angiography (CTA)
3. What optical coherence tomography (OCT) measurement provides an early indication of neuronal loss in the setting of optic neuropathy with optic nerve head (ONH) edema?
  - a. ellipsoid zone
  - b. ganglion cell layer + inner plexiform layer thickness
  - c. peripapillary OCT angiography vessel density
  - d. peripapillary retinal nerve fiber layer thickness
4. Which electrophysiologic test is abnormal in acute zonal occult outer retinopathy (AZOOR)?
  - a. full-field electroretinography
  - b. multifocal electroretinography
  - c. single-fiber electromyography
  - d. visual evoked potential



5. What central nervous system demyelinating disorder commonly presents with an optic neuritis that is associated with bilateral optic nerve and perineural enhancement on MRI?
  - a. glial fibrillary acidic protein astrocytopathy
  - b. multiple sclerosis (MS)
  - c. myelin oligodendrocyte glycoprotein immunoglobulin G-associated disorder
  - d. neuromyelitis optica spectrum disorder
6. Which visual field defect is typically associated with Leber hereditary optic neuropathy?
  - a. arcuate defect
  - b. cecocentral scotoma
  - c. altitudinal defect
  - d. bitemporal hemianopia
7. A 19-year-old woman has new-onset headaches and transient visual obscurations. She has severe acne and uses a topical medication prescribed by her dermatologist. She weighs 110 pounds and is 5 feet, 2 inches tall. Visual acuity is 20/20 OU with normal color vision. Static perimetry shows blind-spot enlargement bilaterally, and ductions are full. What ONH finding is expected to be seen on ophthalmoscopy?
  - a. mild hyperemia with telangiectatic vasculature
  - b. bilateral pallor
  - c. bilateral edema
  - d. normal architecture
8. What clinical feature best distinguishes a parietal lobe lesion from an occipital lobe lesion?
  - a. abnormal optokinetic nystagmus response
  - b. achromatopsia
  - c. homonymous hemianopia
  - d. relative afferent pupillary defect (RAPD)
9. Damage to the Meyer loop produces what type of homonymous visual field defect?
  - a. contralateral inferior
  - b. contralateral superior
  - c. ipsilateral inferior
  - d. ipsilateral superior
10. A 79-year-old woman presents with a 1-month history of difficulty chewing food, weight loss, and headache. Her dentist recently diagnosed temporomandibular joint inflammation and prescribed ibuprofen. Over the past week, she has experienced transient visual

- loss (TVL) in the left eye. Findings from the ophthalmologic examination are normal except for 1 cotton-wool spot in the left eye. What is the best next step in the management of this patient?
- Stop the ibuprofen to minimize postoperative bleeding and schedule a temporal artery biopsy.
  - Obtain a Westergren erythrocyte sedimentation rate and initiate systemic corticosteroids.
  - Begin aspirin and obtain a carotid Doppler ultrasonogram and echocardiogram.
  - Obtain a facial CT scan.
11. An 80-year-old man with hypertension presents with 3 episodes of binocular TVL over the last week. He describes a sudden and complete blackout of the entire visual field for 1 to 2 minutes that resolved as quickly as it started. What is the most likely cause of this patient's symptoms?
- migraine
  - arteriovenous malformation
  - seizures
  - ischemia
12. A 36-year-old woman with a history of migraine reports seeing a trail of an image when looking at a moving object. Which term is used to describe this phenomenon?
- visual snow
  - Riddoch phenomenon
  - visual aura
  - illusory palinopsia
13. Acquired cases of prosopagnosia typically result from stroke affecting what region(s) of the brain?
- bilateral occipitoparietal lobes or left parietal lobe
  - bilateral inferior occipitotemporal lobes or right inferior occipital lobe
  - bilateral posterior occipital lobes or splenium of corpus callosum and unilateral occipital lobe
  - bilateral superior occipitoparietal lobes or right superior parietal lobe
14. A lesion to which anatomical pathway results in Balint syndrome?
- medial longitudinal fasciculus
  - ventral occipitotemporal
  - dorsal occipitoparietal
  - optic tract

15. A 35-year-old man has vertical, binocular diplopia. He has a left hypertropia of 5 prism diopters ( $\Delta$ ) in primary gaze that is absent on right gaze but increases to 9 $\Delta$  on left gaze. There is also a clockwise gaze-evoked nystagmus. What additional clinical finding would be expected on examination?
  - a. variable ptosis with sustained upgaze
  - b. slow left-eye adducting saccade
  - c. proptosis of right eye greater than left
  - d. increased vertical fusional amplitude
16. A 20-year-old man notes pulsatile synchronous tinnitus and horizontal diplopia following head trauma from a motor vehicle accident. Examination reveals enlarged, corkscrew-shaped conjunctival blood vessels; a sixth nerve palsy; and an audible cranial bruit. On neuroimaging, what vessel would be expected to be dilated?
  - a. vein of Galen
  - b. superior ophthalmic vein
  - c. transverse sinus
  - d. ophthalmic artery
17. A 54-year-old man with hypertension experienced onset of complete left ptosis 2 days ago. There is anisocoria and partial limitation of ductions in the left eye. What is the most appropriate initial management strategy?
  - a. observation
  - b. CTA
  - c. edrophonium test
  - d. referral to a primary care physician
18. In a patient with ptosis but no extraocular motility limitation, what additional finding should prompt a workup for myasthenia gravis (MG)?
  - a. pupil involvement
  - b. loss of corneal sensation
  - c. eyelid elevation on adduction
  - d. orbicularis oculi muscle weakness
19. Which of the following would be the most likely associated examination finding in a patient with convergence-retraction nystagmus?
  - a. limitation of conjugate upgaze
  - b. monocular elevation deficit
  - c. apraxia of eyelid opening
  - d. comitant esotropia

20. A patient has a Horner pupil, ipsilateral impairment of facial pain and temperature sensation, and contralateral impairment of pain and temperature sensation over the trunk and limbs. A lesion involving which anatomical structure would explain these findings?
- cavernous sinus
  - internal carotid artery
  - lateral medulla
  - brachial plexus
21. A 72-year-old man is admitted to the neurology department because of an acute stroke. Both eyes are tonically deviated to the left, but the doll's head maneuver produces full ocular motility. What is the most likely location of the stroke to explain the clinical findings?
- left pons
  - right pons
  - left cortex
  - right cortex
22. In what class of eye movements does dysfunction characterize congenital ocular motor apraxia?
- vertical smooth pursuit
  - horizontal smooth pursuit
  - vertical saccades
  - horizontal saccades
23. A patient reports 3 months of oscillopsia. A moderate-amplitude, low-frequency nystagmus is noted in which 1 eye elevates and rotates inward while the fellow eye depresses and rotates outward. What afferent visual disturbance might be found with additional testing?
- inferior altitudinal defects
  - cecocentral scotomata
  - bitemporal hemianopia
  - homonymous sectoranopia
24. What type of nystagmus is characterized by reversal of the normal pattern of optokinetic nystagmus?
- fusional maldevelopment nystagmus syndrome (latent nystagmus)
  - infantile nystagmus syndrome (congenital nystagmus)
  - spasmus nutans syndrome
  - gaze-evoked nystagmus

25. A patient reports oscillopsia while chewing. Examination shows reduced voluntary vertical eye movements. What is the most likely cause of these symptoms and findings?
- midbrain degeneration
  - Tropheryma whipplei* infection
  - Chiari type I malformation
  - chronic alcohol intoxication
26. What is the most likely cause of unilateral upper eyelid retraction on attempted ipsilateral adduction?
- aberrant regeneration of cranial nerve (CN) III
  - thyroid eye disease
  - dorsal midbrain syndrome
  - Duane syndrome
27. A 28-year-old woman reported having a small left pupil for the past few weeks. She denied ptosis, diplopia, or pain. In bright light, the pupils measured 6 mm OD and 3 mm OS. In dim light, the pupils measured 6 mm OD and 4.5 mm OS. What is the most appropriate next step in the management of this patient?
- pilocarpine 1% in each eye
  - pilocarpine 0.1% in each eye
  - cranial MRI with fat suppression
  - cocaine 10% in each eye
28. An asymptomatic, healthy 38-year-old man has small, irregular pupils that react minimally to light stimulus. With attempted reading, the pupils become even smaller. What is the most appropriate next step in the management of this patient?
- observation and follow-up for 1 month
  - syphilis serology
  - apraclonidine testing
  - orbital MRI with contrast
29. In benign essential blepharospasm, where in the central nervous system is the seventh nerve hyperactivity thought to originate?
- midbrain
  - cerebellopontine angle
  - pons
  - basal ganglia

30. A 53-year-old woman reports worsening ability to keep her eyes open, which has resulted in her not being able to read or drive. She is noted to have forceful, episodic bilateral eyelid closure with simultaneous contraction of the corrugator and procerus muscles. What is the best next step in management of this patient?
- acetylcholine receptor antibody test
  - psychiatric referral
  - botulinum toxin injection
  - cranial MRI
31. A 35-year-old man with a history of migraine with aura presents with new onset of weakness. MRI demonstrates widespread leukoencephalopathy. His father had early-onset dementia. A mutation in which gene is responsible for his presentation?
- ABCA4*
  - NOTCH3*
  - OPA1*
  - WFS1*
32. A 40-year-old woman had sudden onset of severe headache, diplopia, and decreased vision in both eyes. Examination shows bilateral ptosis, poorly reactive pupils, and ophthalmoparesis. What abnormality is most likely to be present on neuroimaging?
- posterior communicating artery aneurysm
  - internal carotid artery dissection
  - extensive periventricular white matter lesions
  - hemorrhagic sellar/suprasellar mass
33. A 38-year-old man has periodic right-sided headache with right eye redness and tearing. The pain occasionally wakes him from sleep. What additional right eye or orbital sign is most likely to be associated with his headache events?
- 1+ anterior chamber inflammation
  - 2-mm upper eyelid ptosis
  - grade II ONH swelling
  - 5-mm pupil, poor light reactivity
34. What term describes an oscillating eye movement characterized by irregular, brief bursts of rapid frequency and low amplitude with no slow phase?
- end-gaze nystagmus
  - voluntary flutter
  - spasm of the near reflex
  - see-saw nystagmus



35. A 12-year-old boy presents with sudden vision loss in the right eye. Visual acuity was no light perception OD and 20/20 OS. There was no RAPD; nonorganic vision loss is suspected. Which test is most appropriate to perform to demonstrate normal 20/20 vision OD in this patient?
- mirror test
  - fogging test
  - optokinetic nystagmus drum
  - base-out prism test
36. An 18-year-old woman reports tunnel vision in both eyes. Visual acuity is 20/400 OU, pupils react briskly, and anterior and posterior segments are normal. She is able to ambulate without difficulty. What finding on Goldmann perimetry would confirm a functional component to her vision loss?
- overlapping and spiraling isopters
  - central scotomata
  - nasal step
  - generalized visual field constriction
37. An 89-year-old woman with a history of osteoporosis and poorly controlled diabetes mellitus was recently diagnosed with temporal artery biopsy-proven giant cell arteritis. Initiation of which treatment agent is most appropriate to reduce her risk of corticosteroid adverse effects?
- eculizumab
  - rituximab
  - teprotumumab
  - tocilizumab
38. A 48-year-old woman suddenly has painful vision loss in the right eye. Two weeks later, similar symptoms develop in the left eye. Visual acuity is counting fingers OD and hand motion OS. Both pupils are sluggishly reactive to light without an RAPD. The fundus of the right eye is normal, but there is mild ONH edema in the left eye. MRI shows bilateral optic nerve enhancement. After treatment with intravenous methylprednisolone, she experiences only minimal recovery of vision. Which condition is the most likely cause of the vision loss?
- MS
  - neuromyelitis optica
  - giant cell arteritis
  - AZOO

39. Which medication has been most commonly associated with mental status changes and hemianopia?
- a. fingolimod
  - b. glatiramer acetate
  - c. natalizumab
  - d. interferon beta-1a
40. During ocular motility testing, a patient has episodic diplopia lasting 30–60 seconds and is noted to have a transient right exotropia in primary gaze after maintaining both eyes in extreme right gaze for several seconds. Which of the following is most commonly associated with the clinical findings?
- a. poorly controlled diabetes mellitus treated with oral hypoglycemic
  - b. progressive MS treated with glatiramer acetate
  - c. metastatic breast cancer treated with tamoxifen
  - d. tuberculum sellae meningioma treated with radiation therapy



# Answers

1. **a.** Exiting the brainstem, the abducens nerve (cranial nerve [CN] VI) runs rostrally within the subarachnoid space on the surface of the clivus from the area of the cerebellopontine angle to the superior portion of the posterior fossa. The nerve pierces the dura approximately 1 cm below the petrous apex and travels beneath the petroclinoid ligament (the Gruber ligament, which connects the petrous pyramid to the posterior clinoid) to enter the canal of Dorello. Lesions within the clivus and certain skull base fractures may damage the abducens nerve in this location. The oculomotor and trochlear nerves travel above the clivus in the subarachnoid space to pass into the cavernous sinus. The fascicles of the trigeminal nerve (CN V) enter the brainstem ventrally in the pons and extra-axially traverse the subarachnoid space to penetrate the dura just over the petrous pyramid.
2. **b.** Computed tomography (CT) is the preferred imaging modality to detect acute subarachnoid hemorrhage. Magnetic resonance imaging (MRI) is not preferred for detecting acute hemorrhage, but it can clarify the evolution of intraparenchymal hemorrhage. Computed tomography angiography (CTA) and magnetic resonance angiography (MRA) are preferred for detecting aneurysms and carotid stenosis.
3. **b.** Optical coherence tomography (OCT) provides noninvasive, high-resolution, in situ visualization of the retina and optic nerve head (ONH). Automatic segmentation of OCT images allows for quantification of various retinal layers. The peripapillary retinal nerve fiber layer (pRNFL) thickness measurement provides indirect information about the axonal integrity of the optic nerve, with thinning indicating axonal damage; however, this measurement is confounded in the setting of ONH swelling, in which there is thickening of the pRNFL that can coexist with axonal loss. In these cases, evaluation for thinning of the ganglion cell–inner plexiform layer, which does not swell, can provide an early indication of neuronal loss. The ellipsoid zone of the outer retina is affected early in autoimmune retinopathy and hydroxychloroquine toxicity but does not provide useful information in the setting of optic neuropathy. OCT angiography (OCTA) uses OCT technology to generate depth-resolved images of the retinal and choroidal vasculature without the need for contrast dye administration. OCTA is useful for the evaluation of retinal vascular disease and age-related macular degeneration, but its uses in optic neuropathy are still being explored.
4. **b.** Electroretinography (ERG) measures the electrical activity in the retina in response to various light stimuli under different states of light adaptation. Multifocal ERG (mfERG) records and maps ERG signals from up to 250 focal retinal locations within the central 30°. It can differentiate optic nerve from macular disease in occult central vision loss, as the signal generally remains normal in optic nerve disease. Causes of outer retinal degeneration, such as multiple evanescent white dot syndrome, acute idiopathic blind-spot enlargement syndrome, and acute zonal occult outer retinopathy (AZOOR), result in decreased waveforms on mfERG. Full-field ERG (ffERG) detects diffuse retinal disease in cases of generalized or peripheral vision loss; because ffERG measures only a mass response of the entire retina, localized retinal disease, even with severe visual acuity loss, may not produce an abnormal response. Visual evoked potential (VEP) testing measures electrical signals over the occipital cortex produced in response to a visual stimulus. VEP is useful for evaluation of the visual pathways in inarticulate patients and in patients with suspected nonorganic vision loss. Single-fiber electromyography may be abnormal

in neuromuscular conditions like myasthenia gravis (MG) but would not provide useful information regarding vision loss.

5. **c.** Myelin oligodendrocyte glycoprotein immunoglobulin G–associated disorder (MOGAD) can involve recurrent optic neuritis, myelitis, and encephalitis, with optic neuritis being the most common of these presentations in adults. Compared with typical multiple sclerosis (MS)–optic neuritis, MOG-IgG–optic neuritis is more likely to be bilateral, recurrent, and associated with ONH edema on clinical examination. In addition, perineural enhancement is often observed on MRI (enhancement extending to the optic nerve sheath and surrounding periorbital fat). Although neuromyelitis optica spectrum disorder should be considered in cases of bilateral or recurrent optic neuritis, it is not commonly associated with perineural involvement. Optic neuritis associated with MS is usually unilateral at presentation and does not typically show perineural enhancement. Glial fibrillary acidic protein astrocytopathy presents as a meningoencephalitis sometimes with ONH edema; however, isolated optic neuritis has not been described in association with this condition.
6. **b.** Central or cecentral visual field defects are typical of Leber hereditary optic neuropathy (LHON). Primary open-angle glaucoma is usually characterized by slowly progressive arcuate and peripheral visual field loss. Arcuate defects may be seen with chronic papilledema. In nonarteritic anterior ischemic optic neuropathy, the most common pattern of visual field loss is an altitudinal defect, but any pattern may be observed. Bitemporal hemianopia suggests a chiasmal process, such as compression from a pituitary adenoma or craniopharyngioma.
7. **c.** Bilateral ONH edema is observed in papilledema from increased intracranial pressure. Use of anti-acne medication (including tetracyclines like minocycline, as well as retinoic acid) is associated with idiopathic intracranial hypertension, as in this case. Normal ONH appearance is incorrect because the patient's history and visual field findings are consistent with papilledema. ONH pallor is incorrect because there is no indication of optic neuropathy, suggested by visual field testing showing only blind-spot enlargement, by normal color vision, and by normal visual acuity. Mild hyperemia with telangiectatic vasculature is characteristic of pseudoedema from LHON in the acute stage, or possibly consistent with diabetic papillitis. Neither diagnosis is indicated in this prompt, which describes a young woman with symptoms of increased intracranial pressure.
8. **a.** Parietal and occipital lobe lesions can produce similar visual field defects (homonymous hemianopia) with normal pupil responses (no relative afferent pupillary defect [RAPD]). Cerebral achromatopsia is a feature of occipital lobe lesions. Pursuit and reflexive saccade movements are initiated in the parietal lobe; consequently, abnormal optokinetic nystagmus (OKN) responses can occur with a parietal lobe lesion but not with an occipital lobe lesion.
9. **b.** From the lateral geniculate nucleus, inferior visual fibers first course anteriorly and then laterally and posteriorly to the *Meyer loop* of the temporal lobe. Superior fibers course posteriorly in the parietal lobe. Lesions affecting the Meyer loop thus produce superior incongruous homonymous defects contralateral to the lesion, also known as *pie in the sky* defects. Lesions affecting the optic radiations in the parietal lobe produce predominantly inferior homonymous defects affecting the contralateral visual field. No optic radiation lesion would produce an ipsilateral visual field defect.
10. **b.** The patient's clinical picture is highly suggestive of giant cell arteritis (GCA). GCA is an ophthalmologic emergency because of the potential for bilateral, irreversible vision loss. This patient is already visually symptomatic and has evidence of possible posterior

segment ischemia (cotton-wool spot). The most important next step is the immediate initiation of appropriately dosed systemic corticosteroids, either orally or intravenously, along with initial serologic testing; in cases with a high suspicion for GCA, the results of serologic testing should not delay corticosteroid therapy. Serology usually includes the triad of Westergren erythrocyte sedimentation rate, C-reactive protein, and complete blood count. The gold standard for the diagnosis of GCA is a temporal artery biopsy (TAB), which can be safely performed in most patients even while they are anticoagulated. TAB should be performed as soon as possible, ideally within 10–14 days, as corticosteroid treatment can alter histologic findings; in some cases, however, the biopsy result remains positive for months after the start of therapy. Although carotid stenosis may present with amaurosis fugax, and carotid ultrasonography may in fact be necessary should the workup for GCA prove negative, the leading diagnosis in this case remains GCA. Jaw claudication can be misdiagnosed by clinicians as temporomandibular joint disease, but jaw or tongue claudication is the symptom most specific for GCA. This symptom should always be sought by the clinician in any patient older than 50 years who reports transient visual loss (TVL).

11. **d.** Episodes of complete binocular TVL may represent a transient ischemic attack (TIA) that involves the occipital lobes in the distribution of the basilar artery or posterior cerebral arteries. These episodes are particularly common in older patients with vascular risk factors or cardiac anomalies. Patients with suspected occipital TIA must be referred immediately to an emergency department and evaluated by a neurologist.

Migraine is the most common cause of TVL that is generally hemianopic, involving dynamic positive visual phenomena such as zigzag flashes, and lasts between 20 and 30 minutes; however, the duration can be outside this range. Arteriovenous malformation or other mass may be suspected in a patient with hemianopic visual field loss that is repeatedly in the same location, especially with associated headache that worsens in frequency or severity. Seizures may cause transient hemianopic unformed hallucinations such as grid patterns more frequently than negative visual symptoms.

12. **d.** Palinopsia is visual perseveration after removal of the original stimulus (multiple after-images) and can be divided into 2 categories: illusory and hallucinatory. Illusory palinopsia is triggered by contrast and/or motion; the afterimage or visual trails appear in the same location in the visual field as the original stimulus. Migraine, hallucinogenic drugs such as LSD, and some medications can cause illusory palinopsia. In contrast, hallucinatory palinopsia is not affected by environmental conditions, and the perseverated image can occur in a different location in the visual field than the original stimulus. When the afterimages are associated with homonymous hemianopia and appear in the blind hemifield, a posterior cortical lesion is usually present.

Visual snow also is often seen in patients with migraine and is described as snowy, pixelated vision, similar to television static. It is not uncommon for a patient to have both visual snow and illusory palinopsia. Visual aura is also common in migraineurs and is classically described as scintillating scotoma with a fortification spectrum that lasts 5–60 minutes and is usually followed by headache. Riddoch phenomenon is the preservation of the perception of motion in a blind hemifield.

13. **b.** A more specific form of agnosia, prosopagnosia is characterized by the inability to recognize familiar faces. Acquired cases result predominantly from stroke. The condition usually occurs with bilateral inferior occipitotemporal lobe damage but may also occur with right inferior occipital lobe damage. The ventral occipitotemporal pathway helps process the physical attributes of an object. Examination typically shows superior



homonymous visual field defects. The dorsal occipitoparietal pathway is responsible for visual-spatial analysis and for guiding movements toward items of interest. Alexia without agraphia (patient cannot read but can write) results from damage to the splenium of the corpus callosum and the left occipital lobe.

14. **c.** Balint syndrome results from bilateral occipitoparietal lesions and clinically consists of the triad of simultanagnosia, optic ataxia, and acquired ocular motor apraxia. Lesions of the medial longitudinal fasciculus result in internuclear ophthalmoplegia. Bilateral ventral pathway dysfunction that affects occipitotemporal projections can cause object agnosia. Lesions of the optic tract cause complete or incomplete homonymous hemianopia.
15. **b.** This patient has an incomitant left hypertropia (worse in left gaze) and gaze-evoked nystagmus. The hypertropia does not follow a CN pattern, and the presence of nystagmus suggests a supranuclear disorder such as skew deviation. Skew deviation may occur with internuclear ophthalmoplegia (INO) in a young person who has demyelinating disease, and in an older person may result from ischemia. Given the left hypertropia, the lesion causing the skew deviation is most likely on the left side of the brainstem; the hallmark of a left INO would therefore be slowed adduction saccadic velocity in the left eye.

Both thyroid eye disease (which can cause proptosis) and ocular MG (which can cause fluctuating ptosis) may produce the same ocular deviation (left hypertropia worse in left gaze), but they would not produce nystagmus. Increased vertical fusional amplitude occurs most commonly with long-standing abducens nerve palsy or other vertical strabismus and would not be expected in this patient, whose strabismus does not fit that pattern.

16. **b.** The patient has classic signs and symptoms of a direct carotid-cavernous sinus fistula. A high-flow, direct fistula most commonly occurs after severe head trauma and produces a cranial bruit. Arterialization of conjunctival vessels is a classic sign of carotid-cavernous sinus fistulas. These fistulas often produce elevated intraocular pressure and proptosis. Diplopia can occur from congestion of the extraocular muscles or involvement of any of the CNs in the cavernous sinus, most commonly CN VI. In rare cases, a posteriorly draining fistula can cause an isolated CN palsy with a quiet-appearing eye. Abnormal connections between the cavernous sinus and the carotid artery or its branches introduce high arterial pressure into the normally low-pressure venous circulation of the cavernous sinus. Such a high-pressure connection may reverse blood flow within the superior ophthalmic vein, leading to an enlarged and dilated superior ophthalmic vein, which is typically seen on CT or MRI. The other vessels listed (vein of Galen, transverse sinus, and ophthalmic artery) would not be expected to be enlarged from a carotid-cavernous sinus fistula.
17. **b.** The description is of a patient with pupil-involving third nerve palsy, the usual causes of which are intracranial aneurysm, microvascular ischemia, and diabetes. Because an aneurysm may be fatal, it must be ruled out. Observation is not appropriate. The edrophonium test could be considered for a patient suspected of having MG, which can produce ptosis and abnormal extraocular motility but does not cause anisocoria. Evaluation by a primary care physician to control hypertension is good medical practice, but a compressive lesion needs to be ruled out first in a patient with a pupil-involving third nerve palsy.
18. **d.** Ptosis is a common problem whose etiology varies from benign involutional changes to serious neurologic disease. A thorough examination is critical for determining the workup. Unilateral or bilateral ptosis is the most common sign of MG. In addition to fatigability and improvement with ice testing, myasthenic ptosis is often accompanied

by orbicularis oculi muscle weakness on examination. This is tested with the patient squeezing both eyes shut and the examiner manually applying pressure around the eyes to attempt to reopen them. MG never involves the pupil or sensory nerves, and it does not cause aberrant regeneration/synkinesis of other extraocular muscle nerve fibers.

19. **a.** Convergence-retraction nystagmus is a feature of the dorsal midbrain syndrome, which also includes conjugate limitation of vertical gaze (usually upgaze), mid-dilated pupils with light–near dissociation, and retraction of the eyelids in primary position (Collier sign). Limitation of conjugate upgaze is the most common feature. Supranuclear fibers that control vertical gaze decussate through the pretectum as they pass to the rostral interstitial nucleus of medial longitudinal fasciculus, the midbrain structure that functions as the saccadic generator for vertical eye movements. Comitant esotropia, monocular elevation deficit, and apraxia of eyelid opening are not the correct answers because they are not part of the dorsal midbrain syndrome.
20. **c.** Lateral medullary syndrome (Wallenberg syndrome) produces an ipsilateral Horner syndrome, ipsilateral impairment of pain and temperature sensation over the face (involvement of the descending tract of CN V), contralateral impairment of pain and temperature sensation over the trunk and limbs (involvement of the lateral spinothalamic tract), ipsilateral cerebellar ataxia (damage to spinocerebellar tracts), nystagmus, and the ocular tilt reaction. In addition, patients with lateral medullary syndrome may have dysarthria, dysphagia, vertigo, persistent hiccups, lateropulsion, and ocular lateropulsion. A cavernous sinus lesion, an internal carotid artery dissection, or a congenital brachial plexus injury might cause Horner syndrome, but they would not cause the crossed impaired pain and temperature sensation of the face and rest of the body.
21. **c.** Gaze preference is an inability to produce volitional gaze contralateral to the side of a cerebral (supranuclear) lesion to the frontal eye field. It is accompanied by a tendency for tonic deviation of the eyes toward the side of the lesion. The doll's head maneuver generates a full range of horizontal eye movements because the vestibular-ocular pathways are intact. Stroke is the most common etiology.  
 Gaze palsy is a symmetric limitation of the movements of both eyes in the same direction. Brainstem lesions producing a horizontal gaze palsy disrupt eye movements toward the side of the lesion. CN VI nuclear lesions damage the final common site for supranuclear innervation of horizontal eye movements; thus, the doll's head maneuver is ineffective in driving the parietic eyes toward the side of the lesion.
22. **d.** As described by Cogan, congenital ocular motor apraxia is idiopathic and is characterized by increased latency and intermittent failure of horizontal saccadic initiation. Vertical eye movements are normal.
23. **c.** See-saw nystagmus is a form of disjunctive nystagmus in which 1 eye elevates and intorts while the other eye depresses and extorts, movement reminiscent of that of a see-saw. The eye movements are typically pendular, slow, and low frequency, as well as similar in amplitude between the eyes. It is most commonly observed in patients with large tumors of the parasellar region, which can compress the optic chiasm and cause bitemporal hemianopia. The other scotomata and visual field defects would not be expected for a parasellar lesion causing see-saw nystagmus.
24. **b.** There are 2 characteristic signs of infantile nystagmus syndrome: (1) reversal of the normal pattern of OKN, characterized by slow-phase eye movements in the direction opposite that of the rotating OKN drum, and (2) pattern in which the velocity of slow-phase

movement increases exponentially. This increasing-velocity waveform is punctuated by foveation periods. Identification of this pattern requires eye movement recordings.

Fusional maldevelopment nystagmus syndrome (latent nystagmus) is an early-onset, conjugate, horizontal jerk nystagmus that is accentuated by monocular fixation. Spasmus nutans syndrome is a childhood nystagmus characterized by asymmetric, small-amplitude, high-frequency, shimmering eye movements, often accompanied by head nodding and an abnormal head position (*torticollis*). Gaze-evoked nystagmus develops because of an inability to maintain fixation in eccentric gaze. The eyes drift back to the midline, and a corrective saccade is generated to reposition the eyes on the eccentric target. Thus, the fast phase is always in the direction of gaze.

25. **b.** The patient is reporting symptoms of oculomasticatory myorhythmia, in which pendular vergence oscillations that occur with contractions of the masticatory muscles may develop. Vertical saccadic palsy may be an early neurologic finding in Whipple disease. The infectious agent responsible for this condition is *Tropheryma whippelii*. Patients may have only the neurologic manifestations, but more commonly, they also have unexplained fever, diarrhea, cognitive dysfunction, weight loss, and lymphadenopathy.

Midbrain degeneration is associated with progressive supranuclear palsy and vertical gaze deficiencies but not oscillopsia. In individuals with alcoholism, vitamin deficiencies may develop, as well as Wernicke encephalopathy, which includes ophthalmoparesis but not oscillopsia with chewing. Chiari type I malformation may result in downbeat nystagmus that is constant and not induced by mastication.

26. **a.** The clinical presentations of patients with aberrant regeneration of CN III are varied and include upper eyelid retraction on attempted adduction and pupillary miosis with attempted eyelid elevation, adduction, or infraduction. Aberrant regeneration is common after trauma or compression by an aneurysm or tumor but does not occur with microvascular ischemia. Signs of aberrant regeneration without a history of CN III palsy—*primary aberrant regeneration*—are presumptive evidence of a slowly expanding parasellar lesion, most commonly a meningioma or carotid aneurysm within the cavernous sinus. Thyroid eye disease is the most common cause of upper eyelid retraction, but the retraction is not triggered by adduction. Dorsal midbrain syndrome is a bilateral condition in which upper eyelid retraction (Collier sign) occurs as a result of compression of the posterior midbrain, but the retraction manifests with convergence insufficiency and impaired upgaze and is not triggered by adduction. Lastly, Duane syndrome produces a narrowed, not widened, interpupillary fissure on adduction, due to anomalous co-contraction of the medial and lateral rectus muscles of the involved eye(s), which causes globe retraction.
27. **b.** Although she reports having a small left pupil, this patient presents with anisocoria that is greater in bright light than in dim light, indicating a problem with iris sphincter constriction in light and, therefore, damage to the ciliary ganglion or short ciliary nerves (postganglionic parasympathetic nerve injury). A dilated, poorly reactive pupil, in the absence of ptosis or motility dysfunction, is consistent with Adie pupil. Additional characteristics of Adie pupil include light–near dissociation (poor reaction to light but strong and tonic pupillary response to near vision), sectoral palsy of the iris sphincter, and supersensitivity of the short ciliary nerves to parasympathomimetics such as pilocarpine. While normal pupils would be expected to constrict in response to pilocarpine 1%, only the Adie pupil becomes miotic after instillation of pilocarpine 0.1%.

Cocaine (4% or 10%) is a test for Horner pupil, not Adie pupil. Cranial MRI with fat suppression would be appropriate as part of the workup for Horner syndrome. Adie

pupil is generally benign and does not raise concern for a compressive mass, aneurysm, or dissection.

28. **b.** The patient is demonstrating light–near dissociation with brisk near pupillary response in the absence of a good light response. The small, irregular pupils in this context raise the possibility of Argyll Robertson pupils, which occur in patients with tertiary syphilis involving the central nervous system. Findings can be similar in widespread autonomic neuropathies, including those due to diabetes and chronic alcoholism. In this case, testing for syphilis should be performed. If the test result is positive, referral to a specialist in infectious diseases for further evaluation and treatment should be made.

Observation is inappropriate because there is concern for syphilis in this case. Apraclonidine testing is used for diagnosis of a Horner pupil and is not indicated. Orbital lesions are extremely unlikely to cause bilateral pupil findings of this sort.

29. **d.** Functional neuroimaging suggests that benign essential blepharospasm occurs because of dysfunction of the basal ganglia. The site of dysfunction in hemifacial spasm is the facial root exit zone in the cerebellopontine angle. Facial myokymia typically signifies intramedullary disease of the pons involving the CN VII nucleus or fascicle. The midbrain is not involved in eyelid closure.
30. **c.** Benign essential blepharospasm consists of episodic contraction of the orbicularis oculi muscle. Onset usually occurs between ages 40 and 60 years. Initially, the spasms are mild and infrequent, but they may progress to the point that the patient's daily activities are severely disrupted. Currently, the treatment of choice for benign essential blepharospasm is injection of botulinum toxin into the orbicularis oculi muscle. Neuroradiologic studies are generally unrevealing and rarely indicated. Benign essential blepharospasm can be exacerbated by stress, but referral to psychiatry is typically not warranted. An acetylcholine receptor antibody test is used to diagnose MG, which does not cause forceful contracture of the facial muscles.
31. **b.** Cerebral autosomal dominant arteriopathy with subcortical infarcts and leukoencephalopathy (CADASIL) is an autosomal dominant angiopathy associated with a mutation in *NOTCH3* on chromosome 19. Presentation commonly occurs around age 30 years. Headaches that mimic migraine are common in patients with CADASIL. Recurrent lacunar strokes, cognitive decline, and widespread leukoencephalopathy also characterize this condition. Mutations in *ABCA4* are associated with Stargardt disease; in *OPA1*, with dominant optic atrophy; and in *WFS1*, with Wolfram (diabetes insipidus, diabetes mellitus, optic atrophy, deafness [DIDMOAD]) syndrome.
32. **d.** The constellation of bilateral vision loss, ophthalmoparesis, and ptosis indicates involvement of multiple CNs as well as the optic nerves or chiasm in the pathologic process. Tumors or skull base disorders can have all of these findings, either unilaterally or bilaterally. The sudden onset with headache should create suspicion for pituitary apoplexy, in which rapid tumor expansion with hemorrhage causes compression of the optic chiasm and/or optic nerves as well as CNs in the cavernous sinuses.
- With a posterior communicating artery aneurysm, there would be unilateral findings without vision loss, because the optic nerve is not compressed. Internal carotid artery dissection in the cavernous sinus can result in CN paresis without vision loss that is almost always unilateral. Demyelinating disease presents in a less acute and rarely painful manner.
33. **b.** Unilateral headache with eye redness and tearing characterizes the trigeminal autonomic cephalalgias, which include cluster headache, short-lasting unilateral neuralgiform

headache attacks with conjunctival injection and tearing (SUNCT) syndrome, and hemi-crana continua. Autonomic dysfunction and Horner syndrome–like findings may accompany the headache pain, and 1-mm to 2-mm eyelid ptosis may be seen. The pupil may be miotic, not dilated (as may occur with migraine headache), and intraocular inflammation and/or ONH swelling is not caused by these headaches.

34. **b.** Voluntary flutter, sometimes misdiagnosed as nystagmus, is characterized by irregular, brief, fatigable bursts of rapid-frequency and low-amplitude eye movements with no slow phase. Voluntary flutter is usually seen in patients with nonorganic motility disturbances. End-gaze nystagmus has a fast and slow phase. Spasm of the near reflex consists of intermittent episodes of excess convergence, increased accommodation, and pupillary constriction. See-saw nystagmus is a form of disjunctive nystagmus in which one eye elevates and intorts while the other eye depresses and extorts, movement reminiscent of that of a see-saw.
35. **b.** While all the listed techniques may help uncover functional vision loss in a patient claiming monocular no light perception vision, only the fogging test can demonstrate 20/20 vision OD with suspected nonorganic vision loss. To perform the fogging test, the clinician uses a trial frame with plus and minus cylinder lenses (6.00 D), the axes of which are parallel; these are placed in front of the patient's "good" eye. The patient is then asked to read the Snellen chart while 1 of the cylinder lenses is rotated. The cylinder rotation will severely blur vision as the 2 axes are rotated out of alignment. If the patient continues to read, he or she is doing so with the "bad" eye. The fogging test is a form of confusion testing, which requires the patient to be unaware of which eye is being tested.

The mirror test can demonstrate at least light perception vision but would not help prove that the patient has 20/20 vision. The generation of eye movement with rotation of the OKN drum indicates 20/400 vision but cannot determine whether the vision is any better than 20/400. A base-out prism test showing eye movement when the prism is placed over the "bad" eye indicates some vision in that eye, but it cannot prove 20/20 vision.

36. **a.** The disparity between visual acuity and examination result raises suspicion for nonorganic vision loss. In Goldmann manual kinetic perimetry, the visual field is tested continuously in a clockwise or counterclockwise direction, starting with the (smallest) I4e stimulus. A common functional response shows a spiraling isopter getting closer and closer to fixation as testing continues. As larger stimuli (III4e and V4e) are employed, there is often further constriction, resulting in overlapping isopters.

A step across the vertical or nasal horizontal midline may indicate that neurologic or ophthalmic disease is contributing to the visual field abnormality. Central scotomata may occur in many disease processes, such as toxic or nutritional optic neuropathy or LHON, and are not suggestive of functional disease. While generalized visual field constriction can occur with nonphysiologic vision loss, it also can occur in disease processes such as retinitis pigmentosa. Generalized constriction does not confirm functional vision loss.

37. **d.** The number of relapses during corticosteroid tapering may be reduced with use of tocilizumab, an interleukin-6 receptor alpha inhibitor. Corticosteroid adverse effects can be problematic in any case, but this woman is at particularly high risk because of her underlying conditions (diabetes, osteoporosis); thus, tocilizumab treatment should be considered to allow for tapering to lower corticosteroid doses. Eculizumab, a recombinant humanized monoclonal antibody against the complement protein C5, is used in the treatment of neuromyelitis optica spectrum disorder. Rituximab, a monoclonal antibody against CD20, can be

used for the treatment of MG, neuromyelitis optica spectrum disorder, and other neoplastic and autoimmune diseases. Teprotumumab, a humanized monoclonal antibody that inhibits the insulin-like growth factor 1 receptor on orbital fibroblasts, is used to treat thyroid eye disease.

38. **b.** This vision loss is most consistent with bilateral optic neuritis. The bilateral nature of the vision loss, the severity of visual impairment, and the minimal recovery after treatment raise a concern for neuromyelitis optica. It is uncommon for MS to present with bilateral optic neuritis with minimal recovery. GCA can cause bilateral severe vision loss associated with headache, but it does not affect young patients. Acute zonal occult outer retinopathy is a retinal disorder resulting in vision loss associated with photopsias but no optic nerve enhancement on MRI.
39. **c.** Altered mental status in the presence of a hemianopic visual field defect raises concern for progressive multifocal leukoencephalopathy, a condition associated with natalizumab use in patients who are John Cunningham (JC)–virus positive. The other medications have either not been associated or been associated with encephalopathy only in rare cases. Fingolimod can cause macular edema.
40. **d.** Ocular neuromyotonia, in which episodic diplopia lasting 30–60 seconds develops after sustained activation of a cranial ocular motor nerve, is usually associated with a history of radiation therapy for a skull base neoplasm.





# Index

(*f*= figure; *t*= table)

- AAION. *See* Arteritic anterior ischemic optic neuropathy
- Abducens nerve. *See* Cranial nerve VI
- Aberrant regeneration, of cranial nerve III, 243*f*, 243–244, 325–326, 334
- AC/A ratio. *See* Accommodative convergence/accommodation (AC/A) ratio
- ACA. *See* Anterior cerebral artery
- Accommodation, 378–379
- Accommodative convergence/accommodation (AC/A) ratio, 280
- Accommodative esotropia, 281
- Accommodative vergence, 279
- Acephalgic migraine, 218, 352
- Acetazolamide, for increased intracranial pressure, 141
- Acetylcholinesterase inhibitors, for myasthenia gravis, 397
- AChR antibody tests. *See* Anti-acetylcholine receptor (AChR) antibody tests
- ACoA. *See* Anterior communicating artery
- Acute angle-closure glaucoma, 360
- Acute hemorrhage, 68*t*
- Acute idiopathic blind-spot enlargement (AIBSE) syndrome, 107, 122, 123*f*, 127–128
- Acute inflammatory demyelinating optic neuritis, 143*f*, 143–146
- Acute macular neuroretinopathy (AMN), 107, 120*f*
- Acute migraine, 355
- Acute zonal occult outer retinopathy (AZOOR), 107, 109*f*, 127–128, 216
- ADC. *See* Apparent diffusion coefficient
- Adie pupil
  - accommodative symptoms associated with, 324
  - anisocoria caused by, 316, 322–324
  - characteristics of, 323
  - ciliary ganglion damage as cause of, 323
  - gender predilection of, 322
  - left, 324*f*
  - light–near dissociation in, 41, 326*t*
  - mydriasis caused by, 322
  - pharmacologic diagnosis of, 323–324
  - right, 325*f*
- Adie syndrome, 323
- ADON. *See* Autosomal dominant optic neuropathy
- Adrenergic mydriasis, 322
- Afferent visual pathways
  - description of, 24
  - examination techniques for, 366–377
  - functional neurological symptom disorder symptoms, 366–377
  - optic nerve, 25–27
  - optic tract, 27–29
  - retina, 24*f*, 24–25
- Afferent visual system, 257
- Agnosia, object, 221–222
- AIBSE syndrome. *See* Acute idiopathic blind-spot enlargement (AIBSE) syndrome
- AICA. *See* Anterior inferior cerebellar artery
- Akinetopsia, 222
- Alemtuzumab, 391*t*
- Alexander's law, 262, 295
- Alexia with agraphia, 223
- Alexia without agraphia, 222*f*, 222–223
- Alice in Wonderland effect, 218
- Allergic aspergillosis, 424
- Alternating oculomotor hemiplegia, 238
- Altitudinal scotoma, 131, 133*t*
- Alzheimer disease
  - cortical visual impairment caused by, 195, 220
  - hallucinations associated with, 220
- Amaurosis fugax, 202
- Ambient cistern, 28
- Amblyopia, 93
- Amiodarone, 171
- AMN. *See* Acute macular neuroretinopathy
- Amsler grid testing, 98
- Analgesic rebound headache, 355
- Anderson-Kestenbaum procedure, 291, 292*f*
- Andexanet alfa, 207–208
- Aneurysms
  - basilar artery, 409
  - cerebral. *See* Cerebral aneurysms
  - computed tomography angiography of, 73
  - cranial nerve III palsy associated with, 239, 242–243, 410
  - giant, 409
  - imaging modality for, 68*t*
  - internal carotid artery, 13, 184, 239, 409, 409*f*
  - middle cerebral artery, 409*f*
  - ophthalmic artery, 15, 410
  - posterior cerebral artery, 409*f*
  - posterior communicating artery, 73*f*, 74*f*, 239, 240*f*, 241*f*, 410
  - rupture of, 410–411
  - superior cerebellar artery, 409*f*
  - vertebral artery, 409*f*
- Angiofibromas, 401*f*
- Angiography
  - catheter, 72, 73*f*
  - computed tomography. *See* Computed tomography angiography
  - digital subtraction, 72, 73*f*
  - fluorescein
    - advantages of, 106*t*
    - disadvantages of, 106*t*
    - giant cell arteritis evaluations, 104, 105*f*

- indications for, 106*t*
- optic disc drusen on, 176
- optic nerve head pseudoedema on, 107*f*
- vision loss evaluations with, 104–105, 106*t*
- indocyanine green
  - advantages of, 106*t*
  - disadvantages of, 106*t*
  - indications for, 106*t*
  - vision loss evaluations with, 105, 106*t*
- magnetic resonance. *See* Magnetic resonance
- angiography
- optical coherence tomography, 108, 110
- reversible cerebral vasoconstriction syndrome on, 417, 418*f*
- Angle-closure glaucoma, 200, 360
- Angular artery, 12*f*
- Angular gyrus, 222
- Angular vein, 21, 22*f*, 23
- Anhidrosis, 317
- Aniridia, 313
- Aniseikonia, 255
- Anisocoria
  - in bright light, 314–316, 322–325
  - definition of, 314
  - denervation, 316*t*
  - in dim light, 314–322
  - essential, 314
  - eyelid position affected by, 330
  - flowchart diagram for, 315*f*
  - history-taking for, 311
  - inflammatory, 316*t*
  - mechanical, 316*t*
  - in migraine, 354
  - pharmacologic, 316*t*
  - physiologic, 314–317
  - postcocaine, 318
  - simple, 314
- Anisometropia, 255
- Annulus of Zinn, 7, 8*f*, 26, 41, 43*f*, 45, 48
- Ansa subclavia, 52
- Anterior cerebral artery (ACA)
  - anatomy of, 16, 18, 19*f*
  - branches of, 16
  - occlusion of, 16
- Anterior choroidal artery
  - anatomy of, 14*f*, 15, 19*f*
  - occlusion of, 189*f*, 189–190
- Anterior ciliary artery, 15
- Anterior circulation, 12*f*, 12–17, 14*f*, 16*f*, 17*f*
- Anterior clinoid
  - anatomy of, 4, 5*f*, 6*f*
  - meningiomas of, 4
- Anterior clinoid process, 14*f*
- Anterior communicating artery (ACoA)
  - anatomy of, 14*f*, 19*f*
  - aneurysms of, 409*f*, 410
  - occlusion of, 16
- Anterior cranial fossa
  - anatomy of, 4*f*, 7–8, 9*f*, 10
  - magnetic resonance imaging of, 60*f*
- Anterior ethmoidal artery, 14*f*, 15
- Anterior ethmoidal foramen, 10
- Anterior inferior cerebellar artery (AICA), 18, 20*f*
- Anterior ischemic optic neuropathy
  - arteritic
    - characteristics of, 151*t*
    - giant cell arteritis associated with, 151, 382
    - optic nerve head edema caused by, 95
    - vision loss caused by, 151*t*, 151–153
  - characteristics of, 151*t*
  - description of, 151
  - giant cell arteritis associated with, 151
  - nonarteritic, 151, 151*t*, 152*f*, 153–155, 171
- Anterior optic neuropathy, 420, 420*f*
- Anterior segment
  - magnetic resonance imaging of, 60*f*
  - slit-lamp examination of, 313
- Anterograde axonal transport, 25
- Anti-CGRP (calcitonin gene-related peptide)
  - monoclonal antibody therapies, 356
- Anti-acetylcholine receptor (AChR) antibody tests, 396
- Anticholinergic drug-induced mydriasis, 322
- Antiemetics, 355
- Anti-muscle-specific kinase (MuSK) antibody test, 396
- Anti-neuronal nuclear antibody type 1, 307
- Anti-neuronal nuclear antibody type 2, 307
- Antiphospholipid syndrome, 210*t*
- Anton syndrome, 224, 407
- Aortic aneurysms, 384
- Aortic arch atheromas, 203
- Aponeurotic ptosis, 332
- Apparent diffusion coefficient (ADC)
  - definition of, 64
  - edema imaging using, 67*t*
  - indications for, 64
- Apraclonidine, 311, 317*f*, 317–318
- Apraxia of eyelid opening, 334
- AQP4-IgG (aquaporin-4 immunoglobulin G), 146, 147*t*
- Aquaporin-4, 389, 393
- Arcade retinal veins, 20
- Arcuate fibers, 131
- Arcuate scotoma, 131, 133*t*, 134*f*
- Argyll Robertson-like pupils, 326
- Argyll Robertson pupils, 325–326
- Arterial dissection
  - basilar artery, 413
  - internal carotid artery, 199, 321*f*, 350, 362, 412–413
  - risk factors for, 412
  - vertebral artery, 413
- Arteriovenous malformations (AVMs)
  - basal ganglia, 414*f*
  - binocular transient visual loss caused by, 211
  - brainstem, 415
  - bruit associated with, 415
  - calcified, 415
  - clinical presentation of, 413
  - cortical, 415
  - description of, 13
  - diagnosis of, 415
  - dural, 415

- epidemiology of, 413
- hemispheric, 415
- imaging of, 68*t*, 413, 414*f*
- intracranial, 415
- locations of, 413, 415
- neuro-ophthalmic manifestations of, 415
- occipital lobe, 352*f*
- supratentorial, 413
- treatment of, 415
- Arteritic anterior ischemic optic neuropathy (AAION)
  - characteristics of, 151*t*
  - giant cell arteritis associated with, 151, 382
  - optic nerve head edema caused by, 95
  - vision loss caused by, 151*t*, 151–153
- Artery of Percheron, 19
- Aseptic cavernous sinus thrombosis, 416
- Ash-leaf spot, 401*f*
- Aspergillomas, 424–425
- Aspergillosis, 424–425, 425*f*
- Aspergillus* spp, 424
- Astrocytic hamartomas, 136*f*, 176–177, 401*f*
- Ataxia-telangiectasia, 401, 402*f*, 404*t*
- Atheroma, 203
- Atropine sulfate, 395
- Aubagio. *See* Teriflunomide
- Aura
  - brainstem, 353
  - description of, 218, 220
  - migraine with, 351, 351*f*
  - without headache, 352
- Autofluorescence, of optic disc drusen, 106, 108*f*, 176
- Autoimmune retinopathies, 114, 129–131, 130*f*, 216
- Automated perimeters, 100
- Automated perimetry
  - acute inflammatory demyelinating optic neuritis findings, 143*f*
  - static, 99*f*, 99–102, 101*f*
  - thyroid eye disease findings, 164*f*
  - visual field defect evaluations, 375*f*, 375–376
- Autonomic pathways
  - parasympathetic, 55–56
  - sympathetic, 52–54
- Autosomal dominant optic neuropathy (ADON), 167–169, 168*f*, 169*t*
- AVMs. *See* Arteriovenous malformations
- Avonex. *See* Interferon beta-1a
- Axons, retinal ganglion cell, 26*f*
- AZOOR. *See* Acute zonal occult outer retinopathy
- Baclofen, 302
- Balint syndrome, 224, 275
- Bartonella henselae*, 149
- Bartonella quintana*, 149
- Basal ganglia arteriovenous malformation, 414*f*
- Base-in prism, 280
- Base-out prism, 301, 371
- Basilar artery
  - anatomy of, 10, 20*f*
  - aneurysms of, 409, 409*f*
  - dissection of, 413
  - perforators of, 18
  - pontine branches of, 19
  - stenosis of, 407*f*
- Basilar plexus, 23*f*
- Basilar vein of Rosenthal, 21
- Battle sign, 341
- BEB. *See* Benign essential blepharospasm
- Bell palsy, 337, 338*t*, 339–340
- Benedikt syndrome, 238
- Benign episodic unilateral mydriasis, 326, 354
- Benign essential blepharospasm (BEB), 342–344, 343*f*, 343*t*
- Benign eyelid myokymia, 343*t*, 346
- Benign paroxysmal positional vertigo (BPPV), 298–299
- Berry aneurysm, 409
- Best-corrected visual acuity, 89
- Beta-blockers, 356
- Betaseron. *See* Interferon beta-1b
- Binocular diplopia, 228–229, 253, 353
- Birdshot chorioretinopathy, 216
- Bitemporal hemianopia, 180, 186
- “Black holes,” 384, 385*f*, 388
- Blepharophimosis syndrome, 331
- Blepharoptosis, 327
- Blepharospasm
  - benign essential, 342–344
  - description of, 328
  - dry eye as cause of, 200
  - in extrapyramidal disorders, 344
  - reflex, 343
- Blind spot. *See* Physiologic scotoma
- Blindness
  - cerebral, 193, 407
  - examination techniques for, 369, 370*f*
- Blindsight, 224
- Blood oxygenation level-dependent responses, 75
- Blood vessels, 73, 74*f*. *See also specific blood vessel*
- Blood–retina barrier
  - description of, 15
  - fluorescein blockade by, 104
- Blowout fractures, orbital, 252–253
- Blue-yellow color defects, 91
- Bone disease, 68*t*
- Borrelia burgdorferi*, 340, 423
- Bottom-up acuity, 374
- Botulinum toxin
  - benign essential blepharospasm treated with, 303
  - description of, 303
  - hemifacial spasm treated with, 345
  - pericranial, for migraine headaches, 356
- Botulism, 333
- Bourneville disease, 400, 401*f*, 404*t*
- Bovine spongiform encephalopathy (BSE), 428
- “Bow-tie” optic atrophy, 188
- BPPV. *See* Benign paroxysmal positional vertigo
- Brachium conjunctivum, 17*f*
- Brain
  - magnetic resonance imaging of, 60*f*
  - visual processing pathways in, 31*f*
- Brain lesions, 219

- Brainstem  
arteriovenous malformations of, 415  
in conjugate eye movements, 35–37, 36f  
glioma of, 247
- Brainstem lesions  
description of, 232, 238  
eye movement disorders caused by, 392  
facial weakness caused by, 338–339  
vestibular imbalance associated with, 266
- Branch retinal artery occlusions  
calcific embolus with, 203f  
in Susac syndrome, 104
- Brodmann area 17, 29
- Brown syndrome, 254
- Bruch membrane  
anterior displacement of, 113  
optical coherence tomography of, 76f
- Bruit, 204, 415
- Bruns nystagmus, 299
- BSE. *See* Bovine spongiform encephalopathy
- Budge-Waller, ciliospinal center of, 52
- Buds, 424
- Burst cells, 269, 269f, 271, 275, 305
- C-reactive protein, 151, 348, 382
- CADASIL, 347, 358–359, 359t
- Café-au-lait spots, 400f
- Caffeine, 355
- Calcarine artery  
anatomy of, 19f, 20f, 21f  
occlusion of, 17
- Calcific embolus, 202, 203f, 204t
- Calcifications, 68t
- Calcium channel blockers, 417–418
- Callosomarginal artery, 14f
- Cancer-associated retinopathy (CAR), 120, 121f, 129, 216
- CAR. *See* Cancer-associated retinopathy
- Cardiac emboli, 203, 206
- Carotid artery  
anatomy of, 6f, 9f  
common. *See* Common carotid artery  
internal. *See* Internal carotid artery
- Carotid artery dissection  
imaging modality for, 68t  
internal, 199, 321f, 350, 362, 412–413
- Carotid artery stenosis  
imaging modality for, 68t  
photostress recovery time in, 104  
retinal transient ischemic attack caused by, 207  
ultrasonography of, 75
- Carotid canal, 6f
- Carotid-cavernous fistula, 10, 20–21, 68t, 250–251, 251f
- Carotid Doppler imaging, 75
- Cataracts, 93, 290
- Catheter angiography, 72, 73f
- Cavernous meningioma, 157
- Cavernous sinus  
anatomy of, 4f, 6f, 10, 23f, 43f  
drainage system of, 23f  
internal carotid artery course through, 14f  
lesions of, 248–249  
thrombosis of, 20, 416  
Tolosa-Hunt syndrome involvement of, 249–250
- Cecocentral scotoma, 131, 133t, 134f
- Central caudal nucleus, 234
- Central caudate nucleus, 40
- Central nervous system (CNS)  
cryptococcosis, 427  
encephalitis of, 421, 421f  
lesions of, 265–266, 298f  
lymphoma of, 420  
toxoplasmosis of, 422  
zygomycosis of, 426
- Central-peripheral rivalry–type diplopia, 255
- Central retinal artery  
anatomy of, 3, 13, 14f, 19f, 25  
embolization of, 13  
vasospasm of, 198
- Central retinal artery occlusion (CRAO), 15, 382
- Central retinal vein (CRV)  
anatomy of, 20, 22f, 25  
occlusion of, 208–209
- Central retinal vein obstruction (CRVO)  
description of, 137  
papillophlebitis, 157, 157f
- Central scotoma, 131, 133t, 134f, 375
- Central vestibular instability nystagmus, 302
- Central vestibular nystagmus  
description of, 299–300  
downbeat nystagmus, 300–301  
periodic alternating nystagmus, 302  
torsional nystagmus, 302  
upbeat nystagmus, 301
- Cerebellar angiomatosis, 401, 401f, 404t
- Cerebellar disease, 279
- Cerebellopontine angle lesions/tumor, 246, 299, 335, 337, 340, 344
- Cerebral achromatopsia, 31, 223
- Cerebral aneurysms  
clinical presentation of, 409–410  
computed tomography angiography of, 73–74, 410, 412  
definition of, 409  
diagnosis of, 410–412, 411f  
locations for, 409, 409f  
magnetic resonance angiography of, 410, 411f, 412  
pain associated with, 410  
prevalence of, 409  
prognosis for, 412  
rupture of, 410–412  
treatment of, 412
- Cerebral angiography, 415
- Cerebral autosomal dominant arteriopathy with subcortical infarcts and leukoencephalopathy. *See* CADASIL
- Cerebral blindness, 193, 407
- Cerebral ischemia  
diffusion-weighted imaging of, 64  
transient visual loss caused by, 199
- Cerebral peduncle, 17f
- Cerebral polyopia, 216

- Cerebral ptosis, 333  
 Cerebral stroke, 205–206  
 Cerebral venous disease, 68*t*  
 Cerebral venous sinus system, 23*f*  
 Cerebral venous thrombosis (CVT), 403, 415–417  
 Cerebrospinal fluid (CSF)  
   leakage of, 8  
   magnetic resonance imaging of, 62*f*  
   in multiple sclerosis diagnosis, 388  
   in neuromyelitis optica spectrum disorder  
     diagnosis, 393  
   optic nerve circulation of, 25  
   prion disease findings in, 428  
   superior sagittal sinus absorption of, 21  
 Cerebrovascular disorders  
   arteriovenous malformations. *See* Arteriovenous malformations  
   cerebral venous thrombosis. *See* Cerebral venous thrombosis  
   imaging modality for, 68*t*  
   internal carotid artery dissection, 321*f*, 350, 362, 412–413  
   reversible cerebral vasoconstriction syndrome, 417–418, 418*f*  
   transient visual loss, 406  
   vertebrobasilar system disease, 406–408, 407*f*  
 Cervical plaques, 205  
 Chair rotation fixation test, 279  
 Charles Bonnet syndrome, 219  
 Chiari type I malformation, 300, 300*f*  
 Chiasmal compression, 113, 114*f*  
 Chiasmal lesions  
   compressive, 113  
   extrinsic, 181–185  
   intrinsic, 185–186  
   in multiple sclerosis, 387  
   optic nerve head in, 181  
   parasellar meningiomas, 184  
   peripapillary retinal nerve fiber layer thinning as  
     cause of, 113  
   pituitary adenomas, 181, 183*f*, 184  
   relative afferent pupillary defect caused by, 92  
   vision loss caused by, 180–186  
   vision loss from, 172  
 Chiasmal neuritis, 185*f*  
 Chiasmal syndrome, 68*t*  
 Children  
   functional neurological symptom disorder in, 380  
   idiopathic intracranial hypertension in, 140*t*  
   optic disc drusen in, 176  
   optic neuritis in, 142  
   papillitis in, 142  
 Chloroquine retinal toxicity, 114  
 Cholesterol emboli, 202, 203*f*, 204*t*  
 Chorda tympani, 51  
 Chorioretinitis, 361  
 Choristomas, 403  
 Choroidal hemangiomas, 402*f*  
 Choroidal ischemia, 216  
 Choroidal veins, 20  
 “Christmas tree” cataracts, 400  
 Chronic papilledema, 137–139, 138*f*  
 Chronic paroxysmal hemicrania, 349*t*  
 Chronic progressive external ophthalmoplegia (CPEO), 398*f*, 398–399, 399*f*  
 Chronic relapsing inflammatory optic neuropathy (CRION), 146  
 CI. *See* Convergence insufficiency  
 Ciliary body, 15  
 Ciliary ganglion  
   anatomy of, 52, 55*f*  
   damage to, 323  
 Cilioretinal arteries, 15  
 Circle of Willis, 16, 18*f*, 408  
 Circle of Zinn-Haller, 15  
 Circular nystagmus, 303  
 Circular venous plexus, 23*f*  
 Circulation  
   anterior, 12*f*, 12–17, 13*f*, 14*f*, 15*f*, 16*f*, 17*f*  
   posterior, 18–20, 20*f*, 21*f*  
 CJD. *See* Creutzfeldt-Jakob disease  
 Cladribine, 391*t*  
 Classic trigeminal neuralgia, 349*t*, 362, 363*t*  
 “Classification of eye movement abnormalities and strabismus,” 287–288  
 Claude syndrome, 238  
 Clivus  
   anatomy of, 5, 6*f*, 43, 43*f*  
   lesions of, 43  
 Clonazepam, 301  
 Cluster headaches, 321, 357  
 CMV. *See* Cytomegalovirus  
 CNBP gene, 400  
 CNS. *See* Central nervous system  
 Cocaine, 318  
 Cochlear nerve, 36  
 Cogan congenital ocular motor apraxia, 273–274  
 Cogan lid-twitch sign, 330, 394  
 Cognitive behavioral therapy, 380  
 Cognitive impairment  
   polypharmacy as cause of, 88  
   vision loss assessments in, 88  
   visual field testing in, 88  
 Cogwheel pursuit, 276  
 Cogwheeling, 342  
 Collier sign, 308, 325, 334  
 Coloboma, 116*f*, 179, 313  
 Color perception changes, 216  
 Color vision testing  
   Hardy-Rand-Rittler plates for, 90*f*, 90–91  
   Ishihara plates for, 90, 90*f*  
   pseudoisochromatic plates for, 90, 90*f*  
   vision loss evaluations with, 90–91  
 Comitant deviations, 232  
 Common carotid artery  
   anatomy of, 10, 12  
   bifurcation of, atheroma formation at, 203  
 Compressive optic neuropathy, 157–163, 172  
 Computed tomography (CT)  
   advantages of, 59, 61*t*



- aneurysm rupture evaluations, 411
- arteriovenous malformation on, 415
- contrast-enhanced, 59
- description of, 58
- disadvantages of, 59, 61*t*
- Horner syndrome evaluations, 320–321
- indications for, 68*t*, 70*f*
- internal carotid artery dissection on, 413
- ionizing radiation from, 59
- magnetic resonance imaging and, comparison
  - between, 59, 61*t*, 69–70
- medial rectus muscle entrapment on, 70*f*
- optic disc drusen on, 176
- orbital, 59, 59*f*
- radiation dose delivered with, 59
- sinuses on, 69, 70*f*
- Computed tomography angiography (CTA)
  - advantages of, 61*t*
  - aneurysm imaging using, 73–74, 410
  - cerebral aneurysms on, 73–74, 410
  - cranial nerve III palsy evaluations, 242
  - description of, 73–74
  - disadvantages of, 61*t*
  - Horner syndrome evaluations, 320–321
  - indications for, 58, 68*t*
  - internal carotid artery dissection on, 413
  - magnetic resonance angiography versus, 73–74
  - monocular transient visual loss on, 205
  - multidetector, 74
  - posterior circulation evaluations, 408
- Computed tomography venography (CTV)
  - advantages of, 61*t*
  - cerebral venous thrombosis evaluations, 417
  - disadvantages of, 61*t*
  - indications for, 58, 68*t*
  - magnetic resonance venography versus, 74
- Cone dystrophy
  - color vision in, 90, 126–127
  - early, 122*f*
  - vision loss caused by, 126–127
- Confrontation testing
  - false-negatives caused by, 98
  - in vision loss assessments, 97–98, 376
  - visual field defect evaluations, 376
- Confusion tests, 372–373, 373*f*
- Congenital Horner syndrome, 321–322
- Congenital nystagmus, 289–291
- Congenital ocular motor apraxia, 273–274
- Congenital ptosis, 331*f*, 331–332
- Conjunctival vessel arterIALIZATION, 250
- Contrast-enhanced computed tomography, 59
- Contrast sensitivity testing
  - grating tests, 102–103
  - letter tests, 102–103, 103*f*
  - in vision loss evaluations, 102–104
  - visual acuity testing versus, 102
- Convergence
  - assessment of, 280
  - near point of, 280
- Convergence insufficiency (CI), 280–281
- Convergence-retraction nystagmus, 307–308
- Convergence spasm, 281
- Conversion disorder. *See* Functional neurological symptom (conversion) disorder
- Cookie theft picture, 223
- Copaxone. *See* Glatiramer acetate
- Corneal edema, 215
- Coronal suture, 4
- Corpus callosum, splenium of, 222, 222*f*
- Corrected distance visual acuity, 89–90, 104, 199
- Cortical function disorders
  - akinetopsia, 222
  - alexia without agraphia, 222*f*, 222–223
  - Anton syndrome, 224
  - Balint syndrome, 224
  - blindsight, 224
  - cerebral achromatopsia, 223
  - classification of, 221*t*
  - hemispatial neglect, 224–225, 225*f*
  - object agnosia, 221–222
  - overview of, 213–214, 220
  - physiology of, 220, 221*f*
  - prosopagnosia, 222
  - recognition disorders, 221*t*, 221–223
  - Riddoch phenomenon, 194, 224
  - simultanagnosia, 223*f*, 223–224
  - visual allesthesia, 224
  - visual awareness disorders, 224–225
  - visual deficit disorders, 224–225
  - visual-spatial relationship disorders, 223–224
- Cortical spreading depression, 218, 350
- Cortical visual impairment (CVI), 194–195
- Corticobasal degeneration, 220
- Corticosteroid(s)
  - acute inflammatory demyelinating optic neuritis
    - treated with, 145
  - Bell palsy treated with, 340
  - giant cell arteritis treated with, 208, 382–383
  - idiopathic intracranial hypertension treated with, 141
  - lymphocytic hypophysitis treated with, 406
  - monitoring of, 383
  - multiple sclerosis treated with, 145, 388–389
  - neuromyelitis optica spectrum disorder treated with, 394
  - optic nerve compression treated with, 163
  - papilledema treated with, 141
- Corticosteroid Randomization After Significant Head Injury (CRASH) study, 173–174
- Cotton-wool spots, 97*f*, 137*f*, 152*f*
- CPEO. *See* Chronic progressive external ophthalmoplegia
- Cranial nerve(s). *See also specific nerve*
  - localization of lesions involving, 232–233, 233*f*
  - nuclear lesions, 234
  - ocular motor, 37–45
  - palsies of. *See also specific nerve*
    - cavernous sinus involvement, 248–249
    - intra-axial, 238

- ischemic, 237
- isolated, 237
- microvascular causes of, 241–242
- of multiple cranial nerves, 248
- ocular misalignment caused by, 237
- orbital apex involvement, 248–249
- Cranial nerve III
  - aberrant regeneration of, 243*f*, 243–244, 325–326, 334
  - anatomy of, 233*f*
  - course of, 39*f*, 44*f*
  - dysfunction of, 330–331
  - Edinger-Westphal nuclei of, 55
  - inferior, 8*f*
  - intra-axial involvement of, 238
  - mononeuropathy of, 237
  - nucleus of, 38–41, 40*f*, 234, 279
  - parasympathetic fibers of, 56
  - ptosis caused by weakness of, 331
  - recurrent painful ophthalmoplegic neuropathy of, 248
  - schwannoma of, 71*f*
- Cranial nerve III palsy
  - acute, 324
  - aneurysms associated with, 74, 239, 242–243, 410
  - congenital, 332
  - description of, 40
  - dilated pupil versus, 322
  - divisional, 243
  - imaging priority for, 69
  - microvascular ischemia as cause of, 241–242
  - mydriasis caused by, 322
  - pupil-involving, 239–242, 241*f*, 324–325
  - pupil-sparing, 242–243
  - signs and symptoms of, 239, 240*f*
  - vasculopathic form of, 241
- Cranial nerve IV
  - anatomy of, 8*f*, 233*f*
  - course of, 39*f*, 41, 42*f*
  - description of, 3
  - fascicle of, 41
  - fascicular lesions of, 238
  - head trauma susceptibility of, 245
  - nucleus of, 41, 234
  - recurrent painful ophthalmoplegic neuropathy of, 248
  - superior oblique muscle innervation by, 7
- Cranial nerve IV palsy
  - bilateral, 245
  - congenital, 245, 245*f*
  - diplopia caused by, 244–246, 245*f*, 319
  - giant cell arteritis as cause of, 246
  - Horner syndrome associated with, 234
  - imaging of, 69
  - microvascular ischemia as cause of, 245
  - ophthalmoscopy findings in, 230
  - Parks-Bielschowsky 3-step test for, 244
  - skew deviation versus, 244, 264
  - superior oblique myokymia secondary to, 308
  - vertical strabismus secondary to, 244
- Cranial nerve V
  - anatomy of, 45–49
  - central pathways of, 47*f*
  - dermatomes of, herpes zoster involvement of, 361
  - divisions of, 4*f*, 14*f*, 48–49, 49*f*
  - fascicles of, 47
  - functioning of, 45
  - mandibular division of, 4*f*, 14*f*, 49
  - maxillary division of, 4*f*, 14*f*, 48–49
  - in migraine pathophysiology, 351
  - motor nucleus of, 47, 47*f*
  - nuclear complex of, 45–49
  - ophthalmic branch of, 44*f*, 47–48
  - peripheral innervation of, 47*f*
  - sensory nuclei of, 47
  - superior cerebellar artery and, 47
  - trigeminal neuralgia, 47, 347, 349*t*, 362–363, 363*t*
- Cranial nerve VI
  - anatomy of, 42–43, 233*f*
  - course of, 39*f*
  - fascicles of, 238
  - head trauma susceptibility of, 247
  - intra-axial lesions of, 238
  - nucleus of, 42, 234, 276
  - palsy of, 43, 246*f*, 246–247, 281
  - pregnancy-related disorders of, 403
  - recurrent painful ophthalmoplegic neuropathy of, 248
  - segments of, 43*f*
- Cranial nerve VII
  - assessment of, 335
  - branches of, 51
  - fascicles of, 51
  - function of, 49
  - infranuclear anatomy of, 50*f*
  - lesions of, 335, 336*f*
  - motor nucleus of, 56
  - neoplasms of, 340
  - nuclear anatomy of, 50*f*
  - nucleus of, 49
  - palsy of, 3, 49, 339*f*, 341–342, 423
  - sarcoidosis involvement of, 341
  - supranuclear anatomy of, 50*f*
  - synkinesis of, 330*f*
  - temporal branch of, 51
  - weakness of, 335
  - zygomatic branch of, 51
- Cranial nerve VII disorders
  - benign essential blepharospasm, 342–344, 343*f*, 343*t*
  - benign eyelid myokymia, 343*t*
  - facial myokymia, 343*t*, 345–346
  - hemifacial spasm, 342, 343*t*, 344–345, 345*f*
  - neoplasms, 340
  - overactivity-related, 342–346, 343*f*, 343*t*
  - in pregnancy, 403
  - spastic paretic hemifacial contracture, 345
  - treatment of, 341–342
  - underactivity-related, 337–342
- Cranial nerve VIII, 260, 276
- Cranial nerve XII, 270
- Cranial neuropathies, 403
- Craniopharyngiomas, 184
- Craniotomy, 7

- CRAO. *See* Central retinal artery occlusion
- CRASH study. *See* Corticosteroid Randomization After Significant Head Injury (CRASH) study
- “Crescent moon” sign, 321*f*
- Creutzfeldt-Jakob disease (CJD), 220, 428
- Cribriform plate, 4*f*
- CRION. *See* Chronic relapsing inflammatory optic neuropathy
- CRV. *See* Central retinal vein
- CRVO. *See* Central retinal vein obstruction
- Cryptococcosis, 427
- Cryptococcus gattii*, 427
- Cryptococcus neoformans*, 427
- CSF. *See* Cerebrospinal fluid
- CT. *See* Computed tomography
- CTA. *See* Computed tomography angiography
- CTV. *See* Computed tomography venography
- CVI. *See* Cortical visual impairment
- CVT. *See* Cerebral venous thrombosis
- Cyclotropia, 230
- Cytomegalovirus (CMV), 420, 420*f*
- Cytotoxic edema, 67*t*
- Dabigatran, 207
- Dalfampridine, 301
- Dawson fingers, 67*f*
- de Morsier syndrome, 187
- Deep temporal artery, 12*f*
- Demyelinating disease
- fluid-attenuated inversion recovery imaging of, 64, 67*f*
  - imaging modality for, 68*t*
  - internuclear ophthalmoplegia caused by, 236
  - multiple sclerosis. *See* Multiple sclerosis
  - neuromyelitis optica spectrum disorder. *See* Neuromyelitis optica spectrum disorder
  - signs and symptoms of, 88
- Denervation anisocoria, 316*t*
- Deoxyhemoglobin, 63*f*
- Devic disease, 146, 389. *See also* Neuromyelitis optica
- DI. *See* Divergence insufficiency
- Diabetic papillopathy, 156
- DIDMOAD (diabetes insipidus, diabetes mellitus, optic atrophy, and deafness) syndrome, 169
- Diffusion-weighted imaging (DWI)
- cerebral ischemia on, 64
  - description of, 64
  - edema imaging using, 67*t*
  - infarction on, 64, 69*f*
  - prion diseases on, 428
  - retinal ischemia evaluations, 205
- Digital subtraction angiography (DSA), 72, 73*f*, 413
- Dilated pupil, 378
- Dilator muscles, 53
- Dimethyl fumarate, 391*t*
- Diplopia
- binocular, 228–229, 253, 353
  - Brown syndrome as cause of, 254
  - carotid-cavernous sinus fistula as cause of, 250–251, 251*f*
  - cavernous sinus lesions as cause of, 248–249
  - central-peripheral rivalry-type, 255
  - comitant deviations, 232
  - cranial nerve (CN) palsies
    - CN III. *See* Cranial nerve III palsy
    - CN IV, 244–246, 245*f*, 319
    - CN VI, 246*f*, 246–247
    - multiple cranial nerves, 248
  - “fixation switch,” 255
  - forced duction test of, 231, 231*f*
  - foveal displacement syndrome as cause of, 255–256
  - in giant cell arteritis, 237
  - heavy eye syndrome as cause of, 254
  - history-taking, 228–229
  - in horizontal gaze, 228
  - incomitant deviations, 232
  - internuclear causes of, 235–237
  - internuclear ophthalmoplegia as cause of, 235*f*, 235–236
  - localization of lesions causing, 232–233
  - in migraine, 353–354
  - monocular, 231
  - multiple sclerosis as cause of, 387
  - myasthenia gravis as cause of, 395, 397
  - neoplastic causes of, 254
  - neuromuscular junction cause of, 254
  - nuclear causes of, 234
  - ocular neuromyotonia as cause of, 254
  - one-and-a-half syndrome as cause of, 236–237, 237*f*
  - orbital apex involvement, 248–249
  - orbital blowout fractures as cause of, 252–253
  - orbital myositis as cause of, 252, 253*f*
  - paretic causes of, 231–232
  - physical examination of, 229*f*, 229–230, 230*f*
  - posttraumatic causes of, 252–253
  - refractive procedure–induced, 255
  - restrictive causes of, 231–232
  - sagging eye syndrome as cause of, 254
  - supranuclear causes of, 233, 233*t*
  - surgical causes of, 253–254
  - thyroid eye disease as cause of, 252
  - vertical, 230*f*
    - in vertical gaze, 228
    - vertical-oblique, 235
- Direct oral anticoagulants (DOACs), 207–208
- Direct thrombin inhibitors, 207
- Disconjugate nystagmus, 289
- Disconnection syndromes, 220
- Disease-modifying therapy
- for multiple sclerosis, 389, 390–391*t*
  - for neuromyelitis optica spectrum disorder, 394
- Disjunctive nystagmus, 289
- Dissociated nystagmus
- description of, 289
  - with internuclear ophthalmoplegia, 304
- Divergence insufficiency (DI), 281
- Divisional cranial nerve III palsy, 243
- Dix-Hallpike maneuver, 298
- DMPK gene, 400
- DOACs. *See* Direct oral anticoagulants
- Dolichoectasia, 410

- Doll's head maneuver, 282, 284, 377  
 Dorello canal, 22, 43, 43*f*, 247  
 Dorsal midbrain damage, 325  
 Dorsal midbrain syndrome, 280, 283*f*, 283–284, 308, 325, 334, 388  
 Dorsal visual processing stream, 276  
 Dorsolateral pontine nucleus, 35*f*, 276  
 Dorsum sellae, 6*f*  
 Dot-and-blot hemorrhages, 209*f*  
 Double Maddox rod test, 230, 230*f*, 244  
 Double-ring sign, 177, 177*f*  
 Double vision, 228, 353  
 Downbeat nystagmus, 300–301  
 Driving, 195  
 Drop attacks, 406  
 Drusen, optic disc. *See* Optic disc drusen  
 Dry eye/dry eye syndrome, 200, 215, 354, 360  
 DSA. *See* Digital subtraction angiography  
 Ductions, 229  
 Duochrome test, 372, 373*f*  
 Dural arteriovenous malformation, 415  
 DWI. *See* Diffusion-weighted imaging  
 Dynamic visual acuity, 264  
 Dyschromatopsia  
   in acute inflammatory demyelinating optic neuritis, 143  
   in optic neuropathy, 90, 163  
 Dysmetric saccades, 272  
 Dysphotopsia, 215  
 Dysplastic nerve, of papillorenal syndrome, 179  
  
 Early cone dystrophy, 122*f*  
 Early Treatment Diabetic Retinopathy Study (ETDRS)  
   chart, 103, 103*f*  
 Echocardiography, 206  
 Eclampsia, 403, 405  
 Eculizumab, 146, 394  
 Edema  
   cytotoxic, 67*t*  
   vasogenic, 67*t*  
 EDI-OCT. *See* Enhanced depth imaging optical coherence tomography  
 Edinger-Westphal nucleus, 55, 55*f*, 234, 313, 325, 326*t*  
 Edrophonium chloride test, 395–396  
 Efferent visual system, 227–228  
   brainstem, 35–37  
   cortical input, 33–34  
   overview of, 32–33  
   saccadic system, 33, 34*f*  
   smooth-pursuit system, 34, 35*f*  
   subcortical structures, 34  
 Eight-and-a-half syndrome, 236  
 Electromyography (EMG)  
   myotonic dystrophy findings on, 400  
   repetitive nerve stimulation testing, 396–397  
 Electroretinography (ERG)  
   full-field, 120, 127  
   multifocal, 122, 122*f*, 127  
   vision loss evaluations with, 120–122, 122*f*  
 ELISA. *See* Enzyme-linked immunosorbent assay  
 Elliptical nystagmus, 303  
 Emboli  
   calcific, 202, 203*f*, 204*t*  
   cardiac, 203, 206  
   cholesterol, 202, 203*f*, 204*t*  
   platelet-fibrin, 202, 203*f*, 204*t*  
   retinal, 198, 202–208, 203*f*, 204*t*  
 Embolization  
   of central retinal artery, 13  
   of internal carotid artery branches, 13  
 EMG. *See* Electromyography  
 Encephalitis, central nervous system, 421, 421*f*  
 Encephalofacial angiomatosis, 401, 402*f*, 404*t*  
 End-organ damage, 296–297  
 Endolymph, 260  
 Endoscopic sinus procedure, 8  
 Endovascular interventional therapy, for cerebral venous thrombosis, 417  
 Enhanced depth imaging optical coherence tomography (EDI-OCT), 108–109, 110*f*, 176  
 Enophthalmos, 254, 330  
 Entopic phenomenon, 214  
 Enzyme-linked immunosorbent assay (ELISA), 423  
 Epidermoid cyst, 64*f*  
 Epiretinal membrane peeling, 256  
 Episcleral venous plexus, 20  
 Episodic paroxysmal hemicrania, 349*t*  
 ERG. *See* Electroretinography  
 Erythema chronicum migrans rash, 423, 424*f*  
 Erythrocyte sedimentation rate (ESR), 382  
 ESR. *See* Erythrocyte sedimentation rate  
 Essential anisocoria, 314  
 Estrogen, 354  
 ETDRS chart. *See* Early Treatment Diabetic Retinopathy Study (ETDRS) chart  
 Ethmoid sinus, 7, 9*f*  
 Ethmoidal bone, 6*f*, 7  
 Ethmoidal complex, 7  
 Ethmoidal foramen  
   anterior, 10  
   posterior, 10  
 Evanescent white dot syndrome, 216  
 Exophthalmos, 330  
 Extavia. *See* Interferon beta-1b  
 External carotid artery  
   anatomy of, 12, 12*f*  
   internal carotid artery and, collateral connections between, 13  
   meningeal system of, 13  
 External jugular vein, 23  
 Extinction, 98  
 Extorsion, Double Maddox rod test for, 230, 230*f*  
 Extraocular movements, 37–38  
 Extraocular muscles  
   anatomy of, 45, 46*f*  
   cancer involvement of, 254  
   functions of, 45, 46*f*  
   innervation of, 227  
   surgery of, for infantile nystagmus syndrome, 291, 292*f*

- Extrapyramidal disorders, 344
- Extrastriate cortex lesions, 193
- Eye movement(s)
- brainstem involvement in, 35–37, 36*f*
  - conjugate, 35
  - coordination of, 34–35
  - description of, 32
  - horizontal, 38*f*
  - in ocular fixation, 259
  - pain with, 360
  - pursuit, 276
  - slow drift, 259
- Eye movement disorders
- assessment of, 288–289
  - brainstem lesions as cause of, 392
  - convergence-retraction nystagmus, 307–308
  - nystagmus. *See* Nystagmus
  - oculomasticatory myorhythmia, 309
  - overview of, 287–288
  - superior oblique myokymia, 308–309
  - terminology associated with, 287–288
- Eye pain, 354
- “Eye rest,” 380
- “Eye strain,” 359
- Eyelid(s)
- apraxia of eyelid opening, 334
  - closure of, 51–52, 330, 379
  - examination techniques for, 328–331
  - muscles of, 51–52
  - palpebral muscles of, 51
  - retraction of, 334, 335*f*, 335*t*
  - superficial venous system of, 22*f*
  - veins of, 22*f*, 23
- Eyelid abnormalities
- apraxia of eyelid opening, 334
  - examination techniques for, 328–331
  - overview of, 327–328
  - ptosis. *See* Ptosis
- Eyelid weight implant, 342
- FA. *See* Fluorescein angiography
- Facial artery
- anatomy of, 12*f*
  - terminal branches of, 13
- Facial genu, 238
- Facial motor function, 330*f*, 330–331
- Facial movement abnormalities
- aberrant facial movements, 337
  - cranial nerve VII disorders. *See* Cranial nerve VII disorders
  - evaluation of, 335
  - overview of, 327–328
- Facial muscles, 49
- Facial myokymia, 343*t*, 345–346
- Facial nerve. *See* Cranial nerve VII
- Facial numbness, 362
- Facial pain, 361–363
- Facial paralysis
- Bell palsy as cause of, 337, 338*t*, 339–340
  - brainstem lesions as cause of, 338–339
  - etiology of, 337, 338*t*
  - infections as cause of, 340–341
  - neoplasms as cause of, 340
  - peripheral lesions as cause of, 339
  - supranuclear lesions as cause of, 338
- Facial vein, 21, 22*f*
- Facial venous system, 22
- Facial weakness, 337, 341
- Factitious disorder
- clinical profile of, 368–369
  - description of, 365
  - diagnosis of, 366–367
- Factor Xa inhibitors, 207
- FAF. *See* Fundus autofluorescence
- Fallopian canal, 51, 337
- False-negative response rate, 101–102
- False-positive response rate, 101
- Familial Creutzfeldt-Jakob disease (fCJD), 428
- Farnsworth-Munsell 100-hue test, 91
- Farnsworth panel D-15 test, 91
- Fascicles, cranial nerve III, 40
- Fatal familial insomnia, 428
- Fatigable ptosis, 330
- fCJD. *See* Familial Creutzfeldt-Jakob disease
- FEFs. *See* Frontal eye fields
- ffERG. *See* Full-field electroretinography
- Finger comparison test, 97–98
- Finger counting, 97
- Finger-touching test, 369, 370*f*
- Fingolimod, 389, 390*t*, 392*f*
- Fingolimod-associated macular edema, 389, 390*t*, 392*f*
- First-order central neuron, 54*f*
- First-order neuron, Horner syndrome with, 319*f*, 320*t*
- 5-HT<sub>1B/1D</sub>-receptor agonists, 355
- Fixation losses, 102
- “Fixation switch” diplopia, 255
- Fixed, dilated pupil, 378
- FLAIR images. *See* Fluid-attenuated inversion recovery (FLAIR) images
- Flame hemorrhages, 97*f*
- Flash and pattern-reversal visual evoked potentials, 370–371
- Fluid-attenuated inversion recovery (FLAIR) images
- example of, 62*f*
  - indications for, 63–64
  - multiple sclerosis on, 64, 67*f*
  - signal intensity with, 62*t*
- Fluorescein angiography (FA)
- advantages of, 106*t*
  - disadvantages of, 106*t*
  - giant cell arteritis evaluations, 104, 105*f*
  - indications for, 106*t*
  - optic disc drusen on, 176
  - optic nerve head pseudoedema on, 107*f*
  - vision loss evaluations with, 104–105, 106*t*
- Fluphenazine, 284
- FMNS. *See* Fusional maldevelopment nystagmus syndrome
- fMRI. *See* Functional magnetic resonance imaging
- Focal cortical seizures, 346

- Focal seizure, 284
- Fogging test, 372, 373*f*
- Foramen lacerum, 6*f*
- Foramen magnum
  - anatomy of, 5
  - lesions of, 300
- Foramen ovale, 4*f*, 6*f*
- Foramen rotundum, 4*f*, 8, 48
- Foramen spinosum, 4*f*, 6*f*, 12
- Forced duction test, 231, 231*f*, 252
- Foreign bodies, 68*t*
- Formed hallucinations, visual, 193
- Fourier-domain optical coherence tomography, 108–109
- Fovea, 257
- Foveal displacement syndrome, 255–256
- Foveal hypoplasia, 290
- Foveation periods, 289–290
- Foville syndrome, 238
- Frenzel goggles, 289
- Frontal artery, 15
- Frontal bone, 4, 6*f*, 7
- Frontal eye fields (FEFs), 268–270, 277*f*, 282, 284
- Frontal lobe lesions, 338
- Frontal nerve, 8*f*, 48
- Frontal sinus, 7, 9*f*
- Frontoethmoidal suture
  - anatomy of, 7–8
  - surgical intervention above, 8
- Frontozygomatic suture, 7
- Full-field electroretinography (ffERG), 120, 127
- Functional gaze palsies, 377
- Functional magnetic resonance imaging (fMRI), 75
- Functional neurological symptom (conversion) disorder
  - algorithm for, 366*f*
  - in children, 380
  - clinical features of, 366
  - clinical profile of, 368–369
  - cognitive behavioral therapy for, 380
  - diagnosis of, 365, 367–368, 379
  - examination techniques and tests for
    - alternative charts, 375
    - base-out prism test, 371
    - bottom-up acuity, 374
    - confusion tests, 372–373
    - duochrome test, 372, 373*f*
    - electrophysiologic testing, 370–371
    - finger-touching test, 369, 370*f*
    - flash and pattern-reversal visual evoked potentials, 370–371
    - fogging test, 372, 373*f*
    - goal of, 369
    - kinetic perimetry, 376, 376*f*
    - mirror test, 370
    - optokinetic nystagmus, 370
    - optotypes, 375
    - polarized lens test, 372
    - pupillary reaction, 370
    - specialty charts, 375
    - stereopsis testing, 371–373
    - tangent screen testing, 377, 377*f*
    - vertical prism dissociation test, 371, 372*f*, 373
    - “visual aids,” 374
  - management of, 379–380
  - neurologic and ophthalmic diseases misdiagnosed as, 367*t*
  - prevalence of, 368
  - psychiatric comorbidities with, 368
  - psychotherapy for, 380
  - signs and symptoms of
    - accommodation-related, 378–379
    - afferent visual pathway-related, 366–377
    - description of, 366
    - eyelid-related, 379
    - near reflex spasm, 378
    - no light perception in both eyes, 369–371, 370*f*
    - no light perception in one eye, 371–372
    - ocular motility and alignment, 377–378
    - ptosis, 379
    - pupil-related, 378–379
    - reduced vision in both eyes, 374–375
    - reduced vision in one eye, 372–373
    - visual field defects, 375*f*, 375–377, 376*f*, 377*f*
    - voluntary flutter, 377
  - treatment of, 365
  - vision loss in, 367
- Functional overlay disorder, 367
- Fundus
  - examination of, in vision loss evaluations, 94–95, 95*f*, 96*f*
  - fluorophores in, 105
- Fundus autofluorescence (FAF)
  - advantages of, 106*t*
  - disadvantages of, 106*t*
  - indications for, 106*t*
  - vision loss evaluations with, 105–107, 106*t*
- Fungal infections
  - aspergillosis, 424–425, 425*f*
  - cryptococcosis, 427
  - description of, 424
  - zygomycosis, 426*f*, 426–427
- Fungus balls, 424
- Fusional maldevelopment nystagmus syndrome (FMNS), 291–293
- Fusional vergence, 279–280
- Gabapentin
  - infantile nystagmus syndrome treated with, 291
  - pendular nystagmus treated with, 303
- GAD. *See* Glutamic acid decarboxylase
- Gadolinium-enhanced magnetic resonance imaging
  - contraindications for, 66
  - description of, 65
  - meningiomas on, 65, 65*f*, 66*f*
  - nephrogenic systemic fibrosis caused by, 66
  - optic nerve sheath meningioma on, 65, 65*f*, 66*f*, 72*f*
  - optic neuritis on, 65, 67*f*, 70
- Ganglion cell complex, 141



- Ganglion cell–inner plexiform layer (GC-IPL)  
 measurement of, 78  
 optical coherence tomography of, 76, 78, 83*f*, 84*f*, 110, 112*f*  
 segmentation errors of, 83*f*, 84*f*  
 thickness of  
   description of, 78, 83*f*  
   in multiple sclerosis, 112–113  
   vitamin D deficiency effects on, 113  
 thinning of  
   chiasmal compression as cause of, 113, 114*f*  
   compressive optic neuropathy as cause of, 113  
   description of, 110, 112*f*  
   toxic optic neuropathy as cause of, 170
- Gaze-evoked nystagmus  
 description of, 273, 295–296  
 vertical, 236
- Gaze-evoked transient visual loss, 200
- Gaze palsy, 282–285
- Gaze preference, 282–285
- GC-IPL. *See* Ganglion cell–inner plexiform layer
- GCA. *See* Giant cell arteritis
- Geniculate ganglion lesions, 335
- Geniculate ganglionitis, 337
- Gerstmann–Sträussler–Scheinker syndrome, 428
- Gerstmann syndrome, 191, 223
- GFAP optic neuritis. *See* Glial fibrillary acidic protein (GFAP) astrocytopathy optic neuritis
- Ghost images, 215
- Giant aneurysms, 409
- Giant cell arteritis (GCA)  
 arteritic anterior ischemic optic neuropathy caused by, 95, 382  
 clinical presentation of, 382  
 corticosteroids for, 208, 382–383  
 cranial nerve IV palsy caused by, 246  
 definition of, 382  
 diagnosis of, 382–383  
 diplopia associated with, 237  
 facial pain associated with, 361–362  
 fluorescein angiography evaluation of, 104, 105*f*  
 gender predilection of, 382  
 headache associated with, 348  
 imaging studies for, 382  
 laboratory studies for, 382  
 methylprednisolone for, 383  
 prednisone for, 383  
 signs and symptoms of, 88, 208, 382  
 temporal artery biopsy for, 382–383  
 transient visual loss caused by, 198, 204, 208  
 treatment of, 383–384  
 ultrasonography evaluations, 75
- Giant drusen of the optic disc, 177
- Gilenya. *See* Fingolimod
- Glatiramer acetate, 390*t*
- Glatopa. *See* Glatiramer acetate
- Glaucoma, acute angle-closure, 360
- Glaucomatous optic neuropathy, 172, 172*t*
- Glial fibrillary acidic protein (GFAP) astrocytopathy optic neuritis, 148
- Gliosis, of peripapillary retinal nerve fiber layer, 137, 138*f*
- Globe  
 arterial system of, 11*f*  
 venous circulation of, 22*f*
- Glutamic acid decarboxylase (GAD), 301
- Graded circle test, 371
- Gradenigo syndrome, 247, 416
- Gradient echo imaging, 64
- Grating tests, for contrast sensitivity testing, 102–103
- Graves ophthalmopathy. *See* Thyroid eye disease
- Greater arterial circle, 15
- Greater superficial petrosal nerve, 51–52, 53*f*, 56
- Greater wing of sphenoid bone, 5, 5*f*, 6*f*, 10
- Gruber ligament, 43
- Guillain–Barré syndrome, 333, 340*t*, 341, 346
- Guillain–Mollaret triangle, 303–304
- Gustatory fibers, 56
- Gyrus rectus, 27
- Habit spasm, 346
- Hallucinations  
 aura and, 218, 220  
 brain lesions as cause of, 219  
 cortical origin of, 217–220  
 definition of, 213, 216  
 formed, 193, 216  
 hypnagogic, 218  
 hypnopompic, 218  
 illusion versus, 213  
 intermittent, 218  
 migraine as cause of, 218  
 neurodegenerative disease as cause of, 219–220  
 nonophthalmic conditions that cause, 214*t*  
 ocular origin of, 216–217  
 optic neuritis as cause of, 217  
 palinopsia as cause of, 217–218  
 perception of entoptic phenomenon versus, 214  
 persistent positive visual phenomena as cause of, 218  
 release, 219  
 sleep-associated, 218  
 treatment of, 220  
 unformed, 193, 216  
 vision loss as cause of, 219
- Hallucinatory palinopsia, 217
- Haloperidol, 284
- Hamartomas  
 astrocytic, 136*f*, 176–177, 401*f*  
 composition of, 403  
 intracranial, 401*f*
- Hamartomatous angiofibromas, 401*f*
- Hardy–Rand–Rittler (HRR) plates, 90*f*, 90–91
- Harlequin syndrome, 317
- Head impulse test, 263
- Head tilt, 261
- Headaches  
 analgesic rebound, 355  
 caffeine for, 355  
 cluster, 349*t*, 357

- foods that trigger, 354
- giant cell arteritis as cause of, 348
- “ice pick,” 358
- idiopathic stabbing, 358
- internal carotid dissection as cause of, 350
- intracranial hemorrhage associated with, 348
- intracranial pressure elevation as cause of, 348
- meningitis as cause of, 350
- migraine. *See* Migraine
- overview of, 347–348
- precipitating factors for, 354
- primary, 347
- prophylactic treatment of, 355–357, 356*t*
- ruptured aneurysm as cause of, 410
- screening assessments for, 348
- secondary, 347
- systemic conditions that cause, 348–350, 349*t*
- tension-type, 354–357
- treatment of, 354–357, 356*t*
- trochlear, 360
- trochleitis as cause of, 360
- Headshaking, 264
- Heavy eye syndrome, 254
- Heidenhain variant, of Creutzfeldt-Jakob disease, 428
- Heimann-Bielschowsky phenomenon, 293
- Hemangioblastoma, retinal, 401*f*
- Hemangiomas
  - choroidal, 402*f*
  - ptosis caused by, 332
  - transient visual loss caused by, 200
- Hemeralopia, 128
- Hemianopia, 133*t*
  - bitemporal, 180, 186
- Hemianopic dyslexia, 196
- Hemicrania continua, 349*t*, 358
- Hemifacial spasm, 342, 343*t*, 344–345, 345*f*
- Hemispatial neglect, 224–225, 225*f*
- Hemorrhage
  - imaging modality for, 68*t*
  - intracranial, 348
  - intraparenchymal, 410
  - magnetic resonance imaging of, 63*f*
  - optic nerve sheath, 410
  - retinal, 157, 410, 411*f*
  - subarachnoid, 410–411
- Hepatolenticular degeneration, 334
- Hereditary ataxias, 169
- Hering’s law of equal innervation, 304, 329*f*, 334, 394
- Herpes zoster neuralgia, 361
- Herpes zoster ophthalmicus, 48, 361*f*, 361–362, 421
- Herpes zoster oticus, 341
- Herpesvirus, 421
- Heterochromia, iris, 317
- Heterophoria method, 280
- HFA. *See* Humphrey Field Analyzer
- High hyperopia, 77
- High myopia, 77
- HINTS test, 265–266, 302–303
- Hippus, 313
- HIV. *See* Human immunodeficiency virus
- HIV-associated neuroretinal disorder, 419
- HIV encephalopathy, 419
- Hollenhorst plaque, 202, 203*f*
- Holmes-Adie syndrome, 323
- Homonymous, 133*t*
- Homonymous hemianopia
  - in arteriovenous malformation, 414*f*
  - complete, 188
  - congruous, 191, 192*f*
  - macula-sparing, 192*f*, 192–193
  - management of, 195
  - in migraine aura, 352
  - parietal lobe lesion as cause of, 191
  - pathogenesis of, 29
  - peripheral sector prism eyeglasses for, 195
  - scotoma, 193, 194*f*
  - transient, 198
  - vision loss in, 88
  - vision rehabilitation for, 195
- Homonymous quadrantanopsia, 190*f*
- Homonymous scotoma, 211
- Homonymous sectoranopia, 189
- Homonymous visual field defects, 97, 188, 398, 407–408
- Horizontal eye movements, 38*f*
- Horizontal gaze-evoked nystagmus, 295
- Horizontal gaze palsy, 282, 282*f*
- Horizontal jerk nystagmus, 291
- Horizontal rectus muscle, 307–308
- Horizontal saccades, 269*f*
- Horizontal-torsional nystagmus, 264, 266
- Horner pupil, 318
- Horner syndrome
  - apraclonidine test for, 317*f*, 317–318
  - characteristics of, 316, 317*f*
  - clinical features of, 320*t*
  - congenital, 321–322
  - description of, 43, 54, 234, 249
  - first-order neuron with, 319*f*, 320*t*
  - internal carotid artery dissection associated with, 350, 362
  - lesion localization and evaluation, 318–320, 320*t*
  - magnetic resonance imaging of, 320–322
  - medullary infarcts associated with, 407
  - neurogenic ptosis caused by, 333
  - nontraumatic, 321–322
  - painful postganglionic, 320–321
  - periocular pain in, 199
  - pharmacologic testing of, 317*f*, 317–318
  - physiologic anisocoria versus, 317
  - pontine infarcts associated with, 407
  - pseudo-Horner syndrome versus, 316
  - ptosis caused by, 333
  - pupillary dilation in, 317
  - second-order neuron with, 319*f*, 320*t*
  - third-order neuron with, 319*f*, 320*t*
- HRR plates. *See* Hardy-Rand-Rittler (HRR) plates
- Human immunodeficiency virus (HIV)
  - central nervous system lymphoma associated with, 420
  - cryptococcosis associated with, 427

- cytomegalovirus associated with, 420, 420*f*
- neuro-ophthalmic disorders associated with, 419–421
- Humphrey Field Analyzer (HFA)
  - report from, 101*f*
  - SITA used by, 102
  - 24-2 program, 102
  - 30-2 program, 102
- Huntington disease, 334
- Hutchinson sign, 48
- Hydroxyamphetamine, 319
- Hydroxychloroquine retinal toxicity, 114
- Hypercoagulability, 210, 210*t*
- Hyperfluorescence, of optic disc drusen, 108*f*
- Hypermetric saccades, 272–273
- Hyperpolarization, 261*f*
- Hyperviscosity syndrome, 210
- Hyphae, 424
- Hyphema, recurrent, 200
- Hypnagogic hallucinations, 218
- Hypnopompic hallucinations, 218
- Hypochondriasis, 367
- Hypometric saccade, 272
- Hypoperfusion, 193, 208–210
- Hypotropia, 334
  
- Ice-pack test, 396, 396*f*
- “Ice pick” headache, 358
- ICG angiography. *See* Indocyanine green (ICG) angiography
- Idarucizumab, 207
- Idebenone, 165, 167
- Idiopathic blind-spot enlargement, 127*f*
- Idiopathic intracranial hypertension (IIH)
  - age at onset, 139
  - cerebral venous thrombosis versus, 416
  - in children, 140*t*, 142
  - chronic headaches associated with, 142
  - corticosteroids for, 141
  - diagnosis of, 139, 140*t*
  - differential diagnosis of, 416
  - drugs associated with, 139
  - dural arteriovenous malformation versus, 415
  - lumbar puncture for, 139
  - magnetic resonance imaging of, 139
  - management of, 140–142
  - neuroimaging of, 139
  - obesity and, 141
  - papilledema caused by, 135, 139–142
  - signs and symptoms of, 139
  - treatment of, 141
  - weight loss benefits for, 141
- Idiopathic Intracranial Hypertension Treatment Trial (IIHTT), 141–142
- Idiopathic multiple cranial neuropathy syndrome, 248
- Idiopathic stabbing headache, 358
- Idiopathic tonic pupil. *See* Adie pupil
- IIH. *See* Idiopathic intracranial hypertension
- IIHTT. *See* Idiopathic Intracranial Hypertension Treatment Trial
  
- Illusions
  - assessment of, 214
  - cortical nerve origin of, 216
  - definition of, 213
  - nonophthalmic conditions that cause, 214*t*
  - ocular origin of, 215–216
  - optic nerve origin of, 216
  - optical causes of, 215
  - perception of entopic phenomenon versus, 214
  - retinal causes of, 215–216
  - treatment of, 220
- Illusory palinopsia, 217, 217*f*
- Immunoglobulin G4-related disease, 249*f*, 250
- Immunologic disorders
  - description of, 381
  - giant cell arteritis. *See* Giant cell arteritis
  - multiple sclerosis. *See* Multiple sclerosis
  - myasthenia gravis. *See* Myasthenia gravis
  - myelin oligodendrocyte glycoprotein
    - immunoglobulin G-associated disorder. *See* Myelin oligodendrocyte glycoprotein immunoglobulin G-associated disorder
    - neuromyelitis optica spectrum disorder. *See* Neuromyelitis optica spectrum disorder
    - sarcoidosis, 397–398
    - thyroid eye disease. *See* Thyroid eye disease
- Incontinentia pigmenti, 401
- Increased intracranial pressure
  - acetazolamide for, 141
  - cerebral venous disorders as cause of, 139
  - lumboperitoneal shunt for, 142
  - optic nerve head edema caused by, 133
  - ventriculoperitoneal shunt for, 142
- Indocyanine green (ICG) angiography
  - advantages of, 106*t*
  - disadvantages of, 106*t*
  - indications for, 106*t*
  - vision loss evaluations with, 105, 106*t*
- Induced convergence-retraction, 307
- Inebilizumab, 146
- Infantile nystagmus syndrome (INS)
  - description of, 288*f*, 289–291
  - spasmus nutans syndrome versus, 294
- Infantile-onset saccade initiation delay, 273
- Infarction
  - diffusion-weighted imaging of, 64, 69*f*
  - middle cerebral artery, 17
- Infections
  - facial paralysis caused by, 340–341
  - imaging modality for, 68*t*
- Infectious diseases
  - fungal infections. *See* Fungal infections
  - herpesvirus, 421
  - human immunodeficiency virus, 419–421, 420*f*
  - Lyme disease, 423–424, 424*f*
  - Mycobacterium avium intracellulare* complex, 421
  - Mycobacterium tuberculosis*, 421
  - progressive multifocal leukoencephalopathy, 422, 423*f*
  - syphilis, 422
  - toxoplasmosis, 422–423

- Infectious meningitis, 340–341
- Inferior muscular artery, 15
- Inferior oblique muscle
  - anatomy of, 45
  - functions of, 46*f*
  - innervation of, 37
  - magnetic resonance imaging of, 60*f*
- Inferior olivary hypertrophy, 304
- Inferior ophthalmic vein, 8*f*, 21, 22*f*, 23*f*
- Inferior orbital fissure
  - anatomy of, 6*f*, 8, 10
  - postganglionic fibers, 56
- Inferior orbital rim, 7
- Inferior palpebral vein, 22*f*
- Inferior petrosal sinus, 22
- Inferior rectus muscle
  - anatomy of, 8*f*, 45
  - functions of, 46*f*
  - magnetic resonance imaging of, 60*f*
- Inferior sagittal sinus, 23*f*
- Infiltrative optic neuropathy, 157–163
- Inflammation, orbital, 360
- Inflammatory anisocoria, 316*t*
- Infranuclear pathways, 228
- Intraorbital artery
  - anatomy of, 12*f*
  - terminal branches of, 15
- Infraorbital canal, 8
- Infraorbital nerve, 49
- Infraorbital vein, 22*f*
- INL. *See* Inner nuclear layer
- Inner nuclear layer (INL), 76*f*
- Innominate artery, 10, 18
- INO. *See* Internuclear ophthalmoplegia
- INS. *See* Infantile nystagmus syndrome
- Interferon beta-1a, 390*t*
- Interferon beta-1b, 390*t*
- Intermediate uveitis, 387
- Intermittent hallucinations, 218
- Intermittent saccade failure, 273
- Internal auditory artery, 18
- Internal carotid artery (ICA)
  - anatomy of, 9*f*, 12*f*, 13, 17*f*, 19*f*, 39*f*
  - aneurysms of, 13, 184, 239, 409, 409*f*
  - branches of, 13, 14*f*, 16
  - course of, 13, 14*f*
  - damage to, 10
  - dissection of, 199, 321*f*, 350, 362, 412–413
  - embolization of, 13
  - external carotid artery and, collateral connections between, 13
  - magnetic resonance imaging of, 60*f*
- Internal jugular vein, 21, 23*f*
- International Headache Society, 211–212, 347
- International Optic Nerve Trauma Study, 173
- Internuclear ophthalmoplegia (INO)
  - description of, 235*f*, 235–236
  - dissociated nystagmus with, 304
  - wall-eyed bilateral, 387
- Intersaccadic interval
  - definition of, 259
  - saccadic intrusions with and without, 305–307
- Interstitial nucleus of Cajal, 35, 271
- Intra-axial ocular motor cranial nerve palsies, 238
- Intracranial hamartomas, 401*f*
- Intracranial hemorrhage, 348
- Intracranial hypertension
  - in cryptococcosis, 427
  - imaging modality for, 68*t*
- Intracranial meningioma, 158
- Intracranial pressure, elevated, 198, 348, 410
- Intraocular pressure (IOP), 209
- Intraparenchymal hemorrhage, 410
- Intraparenchymal tumors, 338
- Intravenous immunoglobulin (IVIG), 129, 131, 394
- Intrinsically photosensitive retinal ganglion cells, 24, 28
- Invasive aspergillosis, 424–425
- IONDT. *See* Ischemic Optic Neuropathy Decompression Trial
- Ionizing radiation, 59
- IOP. *See* Intraocular pressure
- Iowa Reference algorithm, 83*f*
- Iridodialysis, 313–314
- Iris
  - damage to, 322
  - heterochromia of, 317
  - innervation abnormalities of, 314
  - nodules of, 400*f*
  - stroma of, 323*f*
  - synechiae of, 318
- Iris crypts, 323
- Iris sphincter paralysis, 322, 323*f*
- Ischemia
  - microvascular
    - cranial nerve III palsy caused by, 241–242
    - cranial nerve IV palsy caused by, 245
  - occipital, 211
  - posterior circulation, 407*f*, 408
  - retinal arterial, 202
  - visual dysfunction caused by, 10
- Ischemic Optic Neuropathy Decompression Trial (IONDT), 154
- Ischemic stroke, 207–208
- Ishihara test/plates, 90, 90*f*, 195, 223
- Isolated ipsilateral tear deficiency, 337
- IVIG. *See* Intravenous immunoglobulin
- “Jabs and jolts” syndrome, 358
- JC (John Cunningham) virus, 422
- Jerk nystagmus
  - definition of, 260
  - horizontal, 291
  - in multiple sclerosis, 388
  - phases of, 287
- Jugular bulb, 21
- Junctional scotoma, 181, 182*f*
- Junctional scotoma of Traquair, 181

- Kaposi sarcoma, 420  
 Kearns-Sayre syndrome, 399  
 Keratitis, 361  
 Keratoconus, 215  
 Kinetic perimetry, 98–100, 376, 376*f*  
 Kinetic red target test, 97–98  
 Kjer disease, 167  
 Klippel-Trénaunay-Weber syndrome, 401  
 Kuru, 428
- Lacrimal artery, 12*f*, 15  
 Lacrimal bone, 6*f*, 7  
 Lacrimal function, 52  
 Lacrimal gland, 56  
 Lacrimal nerve, 48  
 Lacrimal reflex arc, 53*f*  
 Lacrimal sac fossa, 6*f*  
 Lambdoid suture, 4  
 Lamin papyracea, 7  
 Lamina cribrosa, 25  
 Lasmiditan, 355  
 Latent nystagmus, 291–293  
 Lateral geniculate nucleus  
   anatomy of, 16, 17*f*, 19*f*, 27  
   lesions of, 189*f*, 189–190  
   M-cell layers of, 31  
 Lateral long posterior ciliary artery, 15  
 Lateral medullary syndrome, 18, 64*f*, 266  
 Lateral rectus muscle  
   anatomy of, 45  
   anterior ciliary artery of, 15  
   functions of, 46*f*  
   magnetic resonance imaging of, 60*f*  
   malpositioning of, 281  
 Lateral sinus thrombosis, 416–417  
 Lateral striate artery, 19*f*  
 Laterally scrolling text, 196  
 Lateropulsion, 266  
 Leber hereditary optic neuropathy (LHON), 95, 104,  
   164–167, 166*f*, 169*t*  
 Leigh disease, 294  
 Lemtrada. *See* Alemtuzumab  
 Lens gradient method, 280  
 Lesser wing of sphenoid bone, 4–5, 5*f*, 6*f*  
 Letter tests, for contrast sensitivity testing, 102–103, 103*f*  
 Levator aponeurotic defects, 332  
 Levator muscle  
   anatomy of, 8*f*  
   steroid-induced myopathy of, 333  
 Levator palpebrae superioris muscle  
   anatomy of, 45  
   dystrophic development of, 331  
   magnetic resonance imaging of, 60*f*  
 Lewy body dementia, 219  
 LHON. *See* Leber hereditary optic neuropathy  
 Light, pupillary response to, 314  
 Light–near dissociation  
   aberrant regeneration of cranial nerve III as cause  
     of, 326  
   in Adie pupil, 41, 326*t*  
     causes of, 325–326, 326*t*  
     definition of, 325  
     optic neuropathy as cause of, 325  
 Lightning streaks of Moore, 216  
 Lingua plicata, 341  
 Lipofuscin, 106  
 Lisch nodules, 400*f*  
 Longitudinally extensive transverse myelitis, 393, 393*f*  
 Louis-Bar syndrome, 401, 402*f*  
 Lumbar puncture  
   for cerebral aneurysm detection, 411–412  
   for idiopathic intracranial hypertension, 139  
 Lumboperitoneal shunt, 142  
 Lyme disease, 423–424, 424*f*  
 Lymphocytic hypophysitis, 405–406  
 Lymphoma, central nervous system, 420
- M ganglion cells, 276  
 Macropsia, 215  
 Macrosaccadic oscillations, 305*f*, 306  
 Macrosquare-wave jerks, 305*f*  
 Macula  
   ischemia of, 199  
   photostress recovery testing of, 104  
 Macula-sparing homonymous hemianopia, 192*f*,  
   192–193  
 Macular edema, fingolimod-associated, 389, 390*t*,  
   392*f*  
 Maculopathy  
   optic neuropathy versus, 106, 126*t*, 126–127  
   photostress recovery time in, 104  
   vision loss from, 106, 126–127  
   visual field defects in, 127  
 “Mad cow” disease, 428  
 Maddox rod test/testing, 229*f*, 229–230, 241, 324, 395  
 Magnetic resonance angiography (MRA)  
   advantages of, 61*t*  
   aneurysm imaging, 239, 410, 411*f*  
   cerebral aneurysm imaging, 410, 411*f*, 412  
   computed tomography angiography versus, 73–74  
   cranial nerve III palsy evaluations, 242–243  
   description of, 73  
   disadvantages of, 61*t*  
   Horner syndrome evaluations, 320–321  
   indications for, 58–59, 68*t*, 73, 74*f*  
   internal carotid artery on  
     dissection, 413  
     stenosis, 205*f*  
   monocular transient visual loss on, 205  
   posterior circulation evaluations, 408  
   reversible cerebral vasoconstriction syndrome on, 417  
 Magnetic resonance imaging (MRI)  
   acute inflammatory demyelinating optic neuritis  
     on, 143*f*  
   advantages of, 61*t*  
   apparent diffusion coefficient, 64  
   arteriovenous malformation on, 415  
   “black holes” on, 384, 385*f*  
   brain, 60*f*  
   carotid-cavernous sinus fistula on, 251*f*

- cerebrospinal fluid on, 62*f*
- closed machines for, 62
- computed tomography and, comparison between, 59, 61*t*, 69–70
- description of, 58
- diffusion-weighted
  - cerebral ischemia on, 64
  - description of, 64
  - edema imaging using, 67*t*
  - infarction on, 64, 69*f*
  - prion diseases on, 428
  - retinal ischemia evaluations, 205
- diffusion-weighted imaging, 64, 69*f*
- disadvantages of, 61*t*
- downbeat nystagmus on, 300*f*
- epidermoid cyst on, 64*f*
- fat-suppression techniques with, 63
- fluid-attenuated inversion recovery images, 62*f*, 62*t*, 63
- functional, 75
- gadolinium-enhanced
  - contraindications for, 66
  - description of, 65
  - meningiomas on, 65, 65*f*, 66*f*
  - multiple sclerosis on, 388
  - nephrogenic systemic fibrosis caused by, 66
  - optic nerve sheath meningioma on, 65, 65*f*, 66*f*, 72*f*
  - optic neuritis on, 65, 67*f*, 70
- Horner syndrome evaluations, 320–322
- idiopathic intracranial hypertension evaluations, 139
- indications for, 68*t*, 70
- internal carotid artery dissection on, 413
- lateral medullary syndrome on, 64*f*
- multiple sclerosis on, 385, 385*f*, 388
- neuromyelitis optica spectrum disorder on, 393, 393*f*
- open machines for, 62
- optic disc drusen on, 176
- optic neuritis on, 65, 67*f*, 70, 144, 388
- orbital, 60*f*, 70
- orbital myositis on, 253*f*
- papilledema evaluations, 137
- perineuritis on, 150
- pituitary apoplexy on, 183*f*
- posterior reversible encephalopathy syndrome on, 405, 405*f*
- principles of, 62
- prion diseases on, 428
- progressive multifocal leukoencephalopathy on, 422, 423*f*
- protocols for, 62–63
- radiation optic neuropathy on, 429, 429*f*
- radiofrequency pulse sequences with, 63
- sequences of, 62*f*, 62–64
- short tau inversion recovery, 62*t*, 63
- signal intensity, 62*t*
- spinal cord on, 393
- stroke-like migraine attacks after radiation therapy on, 430
- Sturge-Weber syndrome on, 402*f*
- T1-weighted
  - description of, 62, 62*f*
  - hemorrhage on, 63*f*
  - signal intensity, 62*t*
- T2-weighted
  - description of, 62, 62*f*
  - hemorrhage on, 63*f*
  - signal intensity, 62*t*
  - toxoplasmosis on, 423
  - tumors on, 64*f*
- Magnetic resonance spectroscopy (MRS), 75
- Magnetic resonance venography (MRV)
  - advantages of, 61*t*
  - cerebral venous thrombosis evaluations, 417
  - computed tomography venography versus, 74
  - description of, 73
  - disadvantages of, 61*t*
  - indications for, 58, 68*t*
  - papilledema evaluations, 137
  - venous sinus thrombosis evaluation, 73, 74*f*
- Main sensory nucleus, 46
- Main sequence, 268
- Malignant gliomas of the anterior visual pathway, 162
- Malignant optic gliomas of adulthood (MOGAs), 162
- Malingering
  - clinical profile of, 368–369
  - description of, 365–366
  - diagnosis of, 367
- Manifest latent nystagmus, 293
- MAR. *See* Melanoma-associated retinopathy
- Marcus Gunn jaw-winking syndrome, 331, 331*f*, 334
- Mavenclad. *See* Cladribine
- Maxillary artery
  - anatomy of, 12*f*
  - branches of, 12
- Maxillary bone, 4, 6*f*, 7
- Maxillary division of trigeminal nerve, 4*f*, 14*f*, 48–49
- Maxillary sinus, 7, 9*f*
- Mayzent. *See* Siponimod
- Mechanical anisocoria, 316*t*
- Mechanical ptosis, 329*f*
- Medial ciliary artery, 15
- Medial geniculate nucleus, 17*f*
- Medial longitudinal fasciculus (MLF)
  - description of, 35, 42, 228, 234
  - lesions of, internuclear ophthalmoplegia caused by, 304
  - rostral interstitial nucleus of, 33, 35, 270, 283
- Medial rectus muscle
  - anatomy of, 8*f*, 45
  - computed tomography of, 70*f*
  - convergent movements caused by, 307
  - entrapment of, 70*f*
  - functions of, 46*f*
  - horizontal rectus muscle, co-contraction of, 307–308
  - magnetic resonance imaging of, 60*f*
- Medial superior temporal area, 276
- Medial vestibular nucleus (MVN), 277*f*



## Medications

- hallucinations caused by, 214*t*, 216

- illusions caused by, 214*t*, 216

Meige syndrome, 342, 343*f*Melanoma-associated retinopathy (MAR), 120, 129, 130*f*, 131

Melanopsin-containing retinal ganglion cells, 24

Melanopsin retinal ganglion cells, 93

MELAS, 347, 358–359, 359*t*Mekersson-Rosenthal syndrome, 340*t*, 341

## Memantine

- infantile nystagmus syndrome treated with, 291

- pendular nystagmus treated with, 303

Ménière disease, 298

Meningeal disorders, 68*t*

## Meningiomas

- anterior clinoid, 4

- gadolinium-enhanced magnetic resonance imaging of, 65, 65*f*, 66*f*, 72*f*

- intracranial, 158

- optic nerve sheath. *See* Optic nerve sheath meningioma

- parasellar, 184

- transient visual loss caused by, 200

Meningitis, 350, 421

Meningohypophyseal trunk, 13

Mesencephalic nucleus, 46

Metabolic imaging, 75

Metamorphopsia, 98, 127, 215, 353

Methemoglobin, 63*f*

## Methylprednisolone

- acute inflammatory demyelinating optic neuritis treated with, 145

- giant cell arteritis treated with, 383

- neuromyelitis optica spectrum disorder treated with, 394

Metoclopramide, 284

MEWDS. *See* Multiple evanescent white dot syndrome

## Meyer loop

- anatomy of, 29, 190

- lesions of, 190

mfERG. *See* Multifocal electroretinographyMG. *See* Myasthenia gravis

Micropsia, 215

Microsaccadic refixation movements, 259

Microvascular cranial neuropathies, 360

Microvascular decompression, 345

## Microvascular ischemia

- cranial nerve III palsy caused by, 241–242

- cranial nerve IV palsy caused by, 245

Midbrain corectopia, 314

## Middle cerebral artery

- anatomy of, 14*f*, 17*f*, 18*f*, 19*f*, 21*f*, 192–193

- aneurysms of, 409*f*

- branches of, 17

- infarction of, 17

Middle cranial fossa, 60*f*Middle cranial fossa disease, 68*t*Middle meningeal artery, 4*f*, 12, 12*f*

## Migraine

- acephalgic, 352

- acute, 355

- anisocoria associated with, 354

- with aura, 218, 220, 351, 351*f*

- binocular transient visual loss caused by, 198, 211

- clinical features of, 350, 350*t*

- diagnosis of, 350

- diplopia associated with, 353–354

- dry eye associated with, 354

- evaluation of, 352–353, 353*t*

- eye pain associated with, 354

- foods that trigger, 354

- hallucinations caused by, 218

- inherited encephalopathies resembling, 358–359, 359*t*

- ophthalmic features of, 353–354

- ophthalmoplegic, 354

- photophobia associated with, 354

- precipitating factors for, 354

- prevalence of, 350

- prophylactic treatment of, 355–357, 356*t*

- “red-flag” features for, 353*t*

- retinal, 211–212

- topiramate for, 355

- transient visual loss caused by, 198

- treatment of, 354–357, 356*t*

- triptans for, 355

- vertebrobasilar insufficiency versus, 407

- visual disturbances associated with, 353

- without aura, 350–351

Migraine visual aura, 347

Millard-Gubler syndrome, 238

Miller Fisher syndrome, 333, 341

Miosis, 378

Mirror test, 370

Misdirection phenomenon, 339

Mitochondrial DNA, 164–165, 398–399

Mitochondrial encephalopathy, lactic acidosis, and stroke-like episodes. *See* MELASMitoxantrone, 390*t*MLF. *See* Medial longitudinal fasciculus

Möbius syndrome, 282, 339

MOGAD. *See* Myelin oligodendrocyte glycoprotein immunoglobulin G–associated disorderMOGAs. *See* Malignant optic gliomas of adulthood

Molds, 424

Monocular diplopia, 231

Monocular nystagmus, 293

Morning glory syndrome, 179

Motoneurons, 49

Motor nucleus of trigeminal nerve, 47, 47*f*MRA. *See* Magnetic resonance angiographyMRI. *See* Magnetic resonance imagingMRS. *See* Magnetic resonance spectroscopyMRV. *See* Magnetic resonance venographyMS. *See* Multiple sclerosis

Mucormycosis, 426

Mulberry lesions, 176

Müller muscle, 52, 54

- Multifocal electroretinography (mfERG), 122, 122*f*, 128
- Multiple evanescent white dot syndrome (MEWDS), 107, 122, 127–128
- Multiple sclerosis (MS)
- acute exacerbations of, 389
  - cerebellar dysfunction associated with, 386
  - chiasmal abnormalities in, 387
  - clinical presentation of, 386
  - corticosteroids for, 145, 388–389
  - course of, 384
  - definition of, 384
  - diagnosis of, 388
  - diplopia associated with, 387
  - disease-modifying therapy for, 389, 390–391*t*
  - dorsal midbrain syndrome caused by, 388
  - epidemiology of, 384
  - fluid-attenuated inversion recovery image of, 64, 67*f*
  - genetics of, 384
  - laboratory evaluation of, 388
  - magnetic resonance imaging of, 385, 385*f*, 388
  - McDonald criteria for, 388
  - mental changes associated with, 386
  - motor symptoms of, 386
  - neuroimaging in, 388
  - neuromyelitis optica spectrum disorder versus, 389, 392
  - nonocular symptoms of, 386
  - nystagmus associated with, 388
  - ocular abnormalities in, 387
  - ocular motility disturbances in, 387–388
  - ocular motor palsies associated with, 387–388
  - optic neuritis in, 148, 149*t*, 386–387
  - optical coherence tomography of, 112–113
  - pathology in, 384–385
  - periventricular white matter lesions in, 64, 67*f*, 70, 144–145
  - plaque lesions associated with, 385
  - prevalence of, 384
  - prognosis for, 384
  - relapsing-remitting, 145, 384
  - retinal abnormalities in, 387
  - retinal nerve fiber layer in, 112, 386
  - retrochiasmal abnormalities in, 387
  - sensory symptoms of, 386
  - signs and symptoms of, 386
  - sphincter disturbances associated with, 386
  - treatment of, 388–389
  - uveitis in, 387
- Multiple system atrophy, 334
- Muscular artery, 12*f*, 15
- MuSK antibody test. *See* Anti–muscle-specific kinase (MuSK) antibody test
- MVN. *See* Medial vestibular nucleus
- Myasthenia gravis (MG)
- acetylcholinesterase inhibitors for, 397
  - anti–acetylcholine receptor antibody tests for, 396
  - anti–muscle-specific kinase antibody test for, 396
  - characteristics of, 394
  - clinical presentation of, 394–395
  - definition of, 394
  - diagnosis of, 395–397, 396*f*
  - diplopia caused by, 255, 395, 397
  - edrophonium chloride test for, 395–396
  - electromyography repetitive nerve stimulation testing for, 396–397
  - ice-pack test for, 396, 396*f*
  - neostigmine methylsulfate test for, 396
  - outcome for, 397
  - pseudo-internuclear ophthalmoplegia caused by, 236
  - ptosis caused by, 328, 329*f*, 330, 333, 394–397, 396*f*
  - signs and symptoms of, 395
  - sleep test for, 396
  - thymomas associated with, 397
  - thyroid eye disease associated with, 395
  - treatment of, 397
- Mycobacterium avium* intracellular complex, 421
- Mycobacterium tuberculosis*, 421
- Mydriasis, 322, 326, 354
- Myelin oligodendrocyte glycoprotein immunoglobulin G–associated disorder (MOGAD)
- definition of, 389
  - description of, 147–148, 149*t*
- Myelin oligodendrocyte glycoprotein immunoglobulin G–associated optic perineuritis, 150
- Myoclonus, oculopalatal, 303–304
- Myoepithelial cells, 53
- Myogenic ptosis, 332*t*, 333
- Myopathies
- chronic progressive external ophthalmoplegia, 398*f*, 398–399, 399*f*
  - myotonic dystrophy, 399–400
  - oculopharyngeal dystrophy, 399
- Myopia, induced, 379
- Myotonic dystrophy, 333, 399–400
- NAION. *See* Nonarteritic anterior ischemic optic neuropathy
- Narcolepsy, 218
- Nasal arcuate, 134*f*
- Nasal radiating fibers, 131
- Nasociliary nerve, 8*f*, 48
- Nasolacrimal duct, 10
- Nasopharyngeal carcinoma, 361
- Natalizumab, 387, 390*t*
- National Institutes of Health Stroke Scale, 223
- Near point of convergence (NPC), 280
- Near reflex, 55
- spasm of, 281, 378
- Negative dysphotopsia, 215
- Neoplasms
- AIDS-associated, 420
  - cranial nerve VII, 340
  - facial pain caused by, 362
  - imaging modality for, 68*t*
- Neostigmine methylsulfate test, 396
- Nephrogenic systemic fibrosis, 66
- Nervus intermedius, 51, 56
- Neural integration, 270–271

- Neuro-ophthalmology  
 anatomy of  
   bony, 4f, 4–10, 5f, 6f, 7f, 8f, 9f  
   vascular, 10–24  
 anterior circulation, 12f, 12–17, 13f, 14f, 15f, 16f, 17f  
 arterial system, 10, 11f  
 imaging in. *See* Neuroimaging  
 posterior circulation, 18–20, 20f, 21f  
 venous system, 20–24, 21f, 22f, 23f
- Neuroblastoma, 322
- Neurocutaneous syndromes  
   ataxia-telangiectasia, 401, 402f, 404t  
   cerebellar angiomas, 401, 401f, 404t  
   characteristics of, 400  
   choristomas associated with, 403  
   hamartomas associated with, 403  
   incontinentia pigmenti, 401  
   Klippel-Trénaunay-Weber syndrome, 401  
   neurofibromatosis type 1, 161, 400, 400f, 404t  
   retinal angiomas, 401, 401f, 404t  
   Sturge-Weber syndrome, 401, 402f, 404t  
   tuberous sclerosis, 400, 401f, 404t  
   von Hippel-Lindau disease, 401, 401f, 404t  
   Wyburn-Mason syndrome, 401, 403f, 404t
- Neurofibromas, 332, 400f
- Neurofibromatosis (NF), 328, 329f
- Neurofibromatosis type 1, 161, 400, 400f, 404t
- Neurofibromatosis type 2, 400, 404t
- Neurogenic ptosis, 332, 332t, 333
- Neuroimaging. *See also specific imaging modality*  
   cerebral venous thrombosis evaluations, 417  
   communication with radiologist, 58, 70  
   considerations in, 66, 69–72  
   errors to avoid, 58  
   how to order, 70–71  
   interpreting of, 71–72  
   modality-specific selection, 68t, 69–70  
   multiple sclerosis evaluations, 388  
   optic disc drusen on, 176  
   ordering considerations for, 66, 69–72  
   overview of, 57–58  
   timing of, 58, 69
- Neuromuscular junction disorders, 254
- Neuromyelitis optica (NMO)  
   characteristics of, 389  
   description of, 146–147  
   diagnosis of, 392–393  
   neuromyelitis optica spectrum disorder versus, 389
- Neuromyelitis optica-optic neuritis, 113, 146, 148, 149t
- Neuromyelitis optica spectrum disorder (NMOSD)  
   aquaporin-4 as serum marker for, 389, 393  
   cerebrospinal fluid findings in, 393  
   clinical presentation of, 392  
   corticosteroids for, 394  
   definition of, 389  
   description of, 146–147, 147t  
   diagnosis of, 392–393  
   exacerbations of, 394  
   global prevalence of, 389  
   intravenous immunoglobulin for, 394  
   magnetic resonance imaging of, 393, 393f  
   methylprednisolone for, 394  
   multiple sclerosis versus, 389, 392  
   neuromyelitis optica versus, 389  
   optic neuritis associated with, 392  
   spinal cord in, 393, 393f  
   treatment of, 394
- Neuromyotonia, ocular, 255
- Neuroretinitis, 148–150, 150f
- NF. *See* Neurofibromatosis
- NMO. *See* Neuromyelitis optica
- NMOSD. *See* Neuromyelitis optica spectrum disorder
- Nodulus, 37
- Nonarteritic anterior ischemic optic neuropathy (NAION), 151, 151t, 152f, 153–155, 171
- Nonglaucomatous optic neuropathy, 172, 172t
- Nonparaneoplastic autoimmune retinopathy (npAIR), 131
- Nonrhegmatogenous serous retinal detachments, 179
- Nonspecific orbital inflammation, 252
- Norepinephrine, 318
- Nose, 10
- Nothnagel syndrome, 238
- Novantrone. *See* Mitoxantrone
- npAIR. *See* Nonparaneoplastic autoimmune retinopathy
- NPC. *See* Near point of convergence
- Nuclear facial palsy, 336f
- Nucleus of the tractus solitarius, 56
- Nucleus prepositus hypoglossi, 270
- Nucleus prepositus hypoglossi-medial vestibular nucleus  
   description of, 36, 277f  
   gaze-evoked nystagmus caused by dysfunction of, 295
- Null point, 289
- Nutritional deficiency optic neuropathy, 113, 169–171
- Nystagmus  
   Bruns, 299  
   circular, 303  
   congenital, 289–291  
   convergence-retraction, 307–308  
   definition of, 287  
   disconjugate, 289  
   disjunctive, 289  
   dissociated, 289  
   dissociated, with internuclear ophthalmoplegia, 304  
   downbeat, 300–301  
   elliptical, 303  
   fusional maldevelopment nystagmus syndrome, 291–293  
   gaze-evoked, 295–296  
   gaze position and, 289  
   Heimann-Bielschowsky phenomenon, 293  
   HINTS test for, 265–266, 302–303

- infantile nystagmus syndrome, 288*f*  
289–291
- jerk
  - definition of, 260
  - description of, 260
  - horizontal, 291
  - in multiple sclerosis, 388
  - phases of, 287
- latent, 291–293
- manifest latent, 293
- monocular, 293
- in multiple sclerosis, 388
- oblique, 303
- optokinetic, 17, 191, 267–268, 290, 370
- pendular, 260, 287, 288*f*, 303–304
- periodic alternating, 302
- rebound, 296
- see-saw, 304
- small-amplitude, 262
- spasmus nutans syndrome, 294–295
- torsional, 299, 302
- upbeat, 301
- vertical, 299
- vestibular. *See* Vestibular nystagmus
- vestibular-ocular reflex, 261
- voluntary, 307, 377
- Obesity, 141
- Object agnosia, 221–222
- Oblique nystagmus, 303
- Occipital artery, 12
- Occipital bone, 4–5, 6*f*
- Occipital cortex
  - anatomy of, 21*f*
  - blood supply to, 21*f*
  - injury to, 193
- Occipital ischemia, 211
- Occipital lobe
  - arteriovenous malformation of, 352*f*
  - blood supply to, 192
  - cerebral blindness caused by damage to, 193
  - disorders of
    - hallucinations caused by, 219
    - illusions caused by, 216
  - optic radiations of, 191–194
- Occipital neuralgia, 360, 363
- Occipital seizures, 212
- Occipitotemporal pathway, 31*f*
- Occlusion
  - anterior cerebral artery, 16
  - anterior communicating artery, 16
- Ocrelizumab, 390*t*
- Ocrevus. *See* Ocrelizumab
- OCT. *See* Optical coherence tomography
- Octopus perimeter, 102
- Ocular adnexa, 11*f*
- Ocular autonomic pathways
  - parasympathetic, 55–56
  - sympathetic, 52–54
- Ocular deviation, 230
- Ocular-facial synkinesis, 330
- Ocular fixation system
  - anatomical pathways involved in, 259
  - dysfunction of, 259–260
  - eye movement in, 259
  - function of, 258*t*, 258–259
  - microsaccadic refixation movements, 259
- Ocular flutter, 305*f*, 306–307
- Ocular hypoperfusion, 208–210
- Ocular ischemic syndrome, 199, 209*f*, 209–210
- Ocular lateropulsion, 266
- Ocular media abnormalities
  - automated static perimetry findings in, 100
  - vision loss caused by, 126
- Ocular misalignment
  - comitant, 232
  - cranial nerve palsies as cause of, 237
  - description of, 228
  - nonspecific patterns of, 245
  - physical examination of, 229
  - vertical, 264
- Ocular motility
  - functional neurological symptom disorder–related
    - symptoms of, 377–378
  - multiple sclerosis–related disturbances of, 387–388
- Ocular motor apraxia
  - acquired, 224, 274–275
  - causes of, 275*t*
  - congenital, 273–274
- Ocular motor control systems
  - infranuclear, 257–258
  - principles of, 257–259
  - supranuclear
    - anatomy of, 257–258, 258*t*
    - examination of, 259
    - ocular fixation system, 258*t*, 258–260
    - optokinetic system, 258, 258*t*, 267–268
    - pathways involved in, 257–258
    - saccadic system, 258, 258*t*, 268–275, 269*f*, 270*f*, 271*f*
    - smooth-pursuit system, 276–279, 277*f*, 278*f*
    - vergence system, 258, 258*t*
    - vestibular-ocular system, 258, 258*t*
- Ocular motor cranial nerve paresis, 395
- Ocular motor cranial nerves, 37–45
- Ocular motor disturbances, 407
- Ocular motor nuclei, 234
- Ocular motor pathway lesions, 232–233, 233*f*
- Ocular neuromyotonia, 255
- Ocular pain, 359–361
- Ocular tilt reaction, 261–262, 263*f*, 265
- Oculocardiac reflex, 47
- Oculogyric crisis, 284–285
- Oculomasticatory myorhythmia, 309
- Oculomotor nerve. *See* Cranial nerve III
- Oculopalatal myoclonus, 303–304
- Oculopharyngeal dystrophy, 333, 399
- Oculosympathetic fibers, 10, 52–54
- Ofatumumab, 390*t*
- OKN. *See* Optokinetic nystagmus
- Olfactory fossa, 60*f*

- Omnipause cells, 269, 270*f*, 272, 305
- One-and-a-half syndrome, 236–237, 237*f*
- ONH. *See* Optic nerve head
- ONL. *See* Outer nuclear layer
- ONSF. *See* Optic nerve sheath fenestration
- ONSM. *See* Optic nerve sheath meningioma
- ONTT. *See* Optic Neuritis Treatment Trial
- OPA1 protein, 167
- OPG. *See* Optic pathway glioma
- Ophthalmic artery
- anastomoses of, 13
  - anatomy of, 3–4, 8*f*, 12*f*, 13, 14–15, 19*f*
  - aneurysms of, 15, 410
  - branches of, 14*f*, 15
  - course of, 15
  - terminal branch of, 15
- Ophthalmic branch, of trigeminal nerve, 44*f*, 47–48
- Ophthalmic vein
- inferior, 8*f*
  - superior, 8*f*
- Ophthalmoplegia
- cavernous sinus lesion as cause of, 248–249
  - chronic progressive external, 398*f*, 398–399, 399*f*
  - Tolosa-Hunt syndrome as cause of, 249
- Ophthalmoplegic migraine, 354
- Opsoclonus, 306–307
- Optic ataxia, 224, 275
- Optic atrophy
- “bow-tie,” 188
  - imaging of, 95*f*
  - optic nerve head pallor as indicator of, 94, 95*f*
- Optic canal
- anatomy of, 3, 4*f*, 5*f*, 6*f*, 10, 26–27
  - optic nerve passage into, 26–27
- Optic chiasm
- anatomy of, 3, 19*f*, 28*f*, 188
  - surgical decompression of, 7
- Optic disc drusen
- autofluorescence of, 106, 108*f*, 176
  - buried, 109, 110*f*, 136*f*
  - calcified, 175*f*, 176
  - in children, 176
  - definition of, 174
  - fluorescein angiography of, 176
  - fundus autofluorescence detection of, 106, 106*t*, 108*f*
  - hyperfluorescence of, 108*f*
  - imaging of, 174, 175*f*
  - optic nerve head edema versus, 75, 175*f*, 176
  - optic nerve head in, 174, 176–177
  - papilledema versus, 113
  - pathophysiology of, 174
  - prevalence of, 174
  - pseudopapilledema caused by, 135–136, 136*f*
  - visual field defects associated with, 174
- Optic disc neovascularization, 156
- Optic disc tilt, 95
- Optic nerve
- afferent visual pathways, 25–27
  - anatomy of, 8*f*, 17*f*
  - cerebrospinal fluid circulation around, 25
  - coloboma of, 116*f*
  - compression of, 200
  - excavation of, 173
  - hypoplasia of, 177*f*, 177–178
  - intracranial passage of, 27
  - intraorbital, 25
  - metastasis to, 162–163
  - in optic canal, 26–27
  - optical coherence tomography of, 77
  - pregnancy-related disorders of, 403
  - relative afferent pupillary defect as indicator of dysfunction of, 92
  - retrobulbar infiltration of, 162–163
  - sarcoidosis involvement of, 397–398
  - sheath of, 25
  - vascular supply, 16*f*, 19*f*
- Optic nerve glioma
- biopsy of, 161
  - optic nerve sheath meningioma versus, 160*t*
- Optic nerve head (ONH)
- anatomy of, 25
  - anomalous, 113
  - blood supply to, 15
  - congenital anomalies of, 177–179
  - cupping of, 172*t*
  - in diabetic papillopathy, 156
  - edema of
    - arteritic anterior ischemic optic neuropathy as cause of, 95
    - bilateral, 111*f*
    - blind-spot enlargement caused by, 131
    - chalky white, 95, 152
    - clinical features of, 95
    - increased intracranial pressure as cause of, 95, 97*f*. *See also* Papilledema
    - infectious disease associated with, 104
    - inflammatory disease associated with, 104
    - in neuroretinitis, 148, 150*f*
    - nonarteritic anterior ischemic optic neuropathy as cause of, 153
    - optic disc drusen versus, 75, 175*f*, 176
    - optic neuropathy with, 110, 111*f*
    - papilledema. *See* Papilledema
    - in papillophlebitis, 157*f*
    - peripapillary capillary telangiectasias associated with, 95
    - segmentation errors on optical coherence tomography in, 82*f*
    - true, 95, 104, 136
  - examination of, 94–95, 95*f*, 96*f*
  - excavated anomalies of, 179
  - hyaloid remnants on, 136
  - hyperemia of, 95, 133, 166*f*
  - hypoplasia of, 177*f*, 177–178
  - leakage of, 107*f*
  - normal appearance of, 95*f*
  - in optic disc drusen, 174, 176–177
  - orbital Doppler ultrasonography of, 75
  - pallor of, 94–95, 95*f*, 118*f*, 131, 172

- pseudoedema of, 104, 107*f*
- rakelike defects, 94, 95*f*
- refractile bodies of, 138, 138*f*
- retinal ganglion cell nerve fibers in, 131, 132*f*
- sarcoid granuloma of, 397
- tilted disc syndrome, 178*f*, 178–179
- transient visual loss associated with anomalies of, 200
- vascular supply to, 16*f*
- Optic nerve pit, 179
- Optic nerve sheath
  - anatomy of, 8*f*
  - gadolinium-enhanced magnetic resonance imaging of, 65*f*
  - hemorrhage of, 410
- Optic nerve sheath fenestration (ONSF), 141
- Optic nerve sheath meningioma (ONSM)
  - description of, 157
  - diagnosis of, 158–159
  - etiology of, 158
  - imaging of, 65*f*, 66*f*, 72*f*, 159*f*
  - intracranial meningioma versus, 158
  - optic nerve glioma versus, 160*t*
  - relative afferent pupillary defect associated with, 159
  - stereotactic fractionated radiation therapy for, 159
- Optic neuritis
  - acute inflammatory demyelinating, 143*f*, 143–146
  - in children, 142
  - cytomegalovirus as cause of, 420
  - definition of, 142
  - demyelinating
    - illusions secondary to, 216
    - vision loss caused by, 386
  - gadolinium-enhanced magnetic resonance imaging of, 65, 67*f*, 70
  - glial fibrillary acidic protein astrocytopathy, 148
  - hallucinations caused by, 217
  - illusions secondary to, 216
  - imaging modality for, 68*t*
  - magnetic resonance imaging of, 65, 67*f*, 70, 144, 388
  - in multiple sclerosis, 148, 149*t*, 386–387
  - myelin oligodendrocyte glycoprotein
    - immunoglobulin G-associated disorder, 147–148, 149*t*
  - neuromyelitis optica, 113, 146, 148, 149*t*
  - in neuromyelitis optica spectrum disorder, 392
  - nonarteritic anterior ischemic optic neuropathy versus, 154
  - optic perineuritis versus, 150
  - periorbital pain associated with, 88
  - peripapillary retinal nerve fiber layer thinning
    - associated with, 113
  - retrobulbar, 142, 143*f*
  - toxoplasmosis, 422
- Optic Neuritis Treatment Trial (ONTT), 144–145, 386
- Optic neuropathy
  - anterior ischemic
    - arteritic, 151*t*, 151–153
    - characteristics of, 151*t*
    - description of, 151
  - giant cell arteritis associated with, 151, 382
  - nonarteritic, 151, 151*t*, 152*f*, 153–155, 171
- automated static perimetry findings in, 100
- autosomal dominant, 167–169, 168*f*, 169*t*
- causes of, 135*t*
  - cavernous meningioma, 157
  - clinical characteristics used to determine, 132
  - compressive lesions, 157–163, 172
  - diabetic papillopathy, 156
  - hereditary, 164–169
  - infiltrative lesions, 157–163
  - inflammatory diseases, 142–150
  - myelin oligodendrocyte glycoprotein
    - immunoglobulin G-associated disorder, 147–148, 149*t*
  - neuromyelitis optica, 146–147
  - neuromyelitis optica spectrum disorder, 146–147, 147*t*
  - neuroretinitis, 148–150, 150*f*
  - nutritional deficiency, 113, 169–171
  - optic disc drusen, 174–177, 175*f*
  - optic nerve sheath meningioma, 157–160
  - optic neuritis. *See* Optic neuritis
  - optic pathway glioma, 157, 160–162, 161*f*
  - optic perineuritis, 150
  - papilledema, 132–142, 136*f*, 137*f*, 138*f*. *See also* Papilledema
  - papillophlebitis, 157, 157*f*
  - retrobulbar infiltration of the optic nerve, 162–163
  - thyroid eye disease, 163–164, 164*f*
  - toxic substances, 113, 169–171
  - trauma, 172–174
    - vascular conditions, 151–156
- chronic relapsing inflammatory, 146
- color vision testing in, 90
- dyschromatopsia in, 90
- glaucomatous, 172, 172*t*
- in infantile nystagmus syndrome, 290
- Leber hereditary, 95, 104, 164–167, 166*f*, 169*t*
- light–near dissociation caused by, 325
- maculopathy versus, 106, 126*t*, 126–127
- nonglaucomatous, 172, 172*t*
- nutritional, 113
- optic nerve head edema with, 110, 111*f*
- perioperative ischemic, 155–156
- posterior ischemic, 155, 420
- radiation, 429, 429*f*
- sarcoid, 158*f*
- toxic, 113
- traumatic
  - computed tomography of, 173*f*
  - description of, 172–174
  - direct, 172
  - indirect, 173
  - relative afferent pupillary defect in, 91*f*
  - visual field patterns in, 131, 134*f*
- Optic pathway glioma (OPG), 157, 160–162, 161*f*
- Optic perineuritis, 150



- Optic radiations
  - anatomy of, 19*f*
  - fibers of, 29, 30*f*
  - of temporal lobe, 190–191
- Optic strut, 4, 14*f*
- Optic tract
  - anatomy of, 19*f*, 27–29
  - lesions of
    - ischemic, 188
    - relative afferent pupillary defect associated with, 92–93, 188
    - vision loss caused by, 188–189
  - sella and, comparison between, 29*f*
- Optic tract syndrome, 16, 188–189
- Optical coherence tomography (OCT)
  - enhanced depth imaging, 108–109, 110*f*, 176
  - Fourier-domain, 108–109
  - ganglion cell–inner plexiform layer on, 76, 78, 83*f*, 84*f*, 110, 112*f*
  - indications for, 58, 107
  - macular cube, 113
  - multiple sclerosis evaluations, 112–113
  - optic disc drusen on, 176
  - optic nerve on, 77
  - papilledema evaluations, 76–77, 113
  - peripapillary retinal nerve fiber layer on, 76–77, 78*f*, 80*f*, 95, 107, 110, 386
  - reading of results, 76*f*, 76–78, 77*f*, 78*f*
  - retinal layers on, 76, 76*f*
  - segmentation errors of, 82*f*
  - signal strength of, 77
  - spectral-domain, 108–109
  - swept-source, 108–109
  - time-domain, 107–108
  - vision loss evaluations using, 106*t*, 107–115
- Optical coherence tomography angiography, 108, 110
- Optociliary shunt vessels, 20, 159, 161
- Optokinetic nystagmus (OKN), 17, 191, 267–268, 278, 290, 370
- Optokinetic system
  - assessment of, 267–268
  - function of, 258, 258*t*, 267
- Optotypes, 104, 375
- Oral contraceptives, 354
- Oral facial dyskinesias, 346
- Orbicularis oculi muscle
  - contraction of, in benign essential blepharospasm, 342, 343*f*
  - facial myokymia of, 345
  - hemifacial spasm of, 344
  - intermittent fluttering of, 346
  - myokymia of, 345
  - weakness of, 335
- Orbit
  - arterial system of, 10, 11*f*
  - aspergillomas of, 424, 425*f*
  - blowout fractures of, 252–253
  - bony anatomy of, 5–9, 6*f*, 6*t*, 7*f*, 8*f*, 9*f*
  - canals of, 10
  - computed tomography of, 59, 59*f*
  - fissures of, 10
  - magnetic resonance imaging of, 60*f*
  - medial wall of, 10
  - short tau inversion recovery of, 63, 65*f*, 66*f*
  - vascular anatomy of, 10–24
  - venous circulation of, 22*f*
  - venous system of, 20–24, 21*f*, 22*f*, 23*f*
- Orbital apex, 6*f*, 8, 48
- Orbital apex syndrome, 249
- Orbital cellulitis, 360, 416
- Orbital Doppler ultrasonography, 75
- Orbital myositis, 252, 253*f*
- Orbital pain, 359–361
- Orbital rim
  - inferior, 7
  - superior, 7
- Orbital varices
  - imaging of, 70, 70*f*
  - with Valsalva maneuver, 70, 70*f*
- Oscillopsia, 288, 290, 293
- Otitis media, 416
- Otoconia particles, 298
- Otolith pathway dysfunction, 264–265
- Otoliths, 261
- Ototoxins, 299
- Outer nuclear layer (ONL), 76*f*
- Oxyhemoglobin, 63*f*
- Ozanimod, 391*t*
- PACT. *See* Prism and cover test
- Pain
  - cerebral aneurysm, 410
  - facial, 361–363
  - occipital neuralgia, 360, 363
  - ocular, 359–361
  - orbital, 359–361
- Painful postganglionic Horner syndrome, 320–321
- Palatal myoclonus, 303–304
- Palatine bone, 7
- Palinopsia, 217–218, 353
- Palpebral artery, 12*f*
- Palpebral muscles, 51
- PAN. *See* Periodic alternating nystagmus
- Pancoast tumor, 319*f*
- Papilledema
  - acute, 133, 135
  - anomalous optic nerve heads versus, 113
  - chronic, 137–139, 138*f*, 176
  - corticosteroids for, 141
  - elevated intracranial pressure as cause of, 410
  - idiopathic intracranial hypertension as cause of, 135, 139–142
  - imaging of, 97*f*, 136*f*, 137
  - magnetic resonance imaging of, 137
  - magnetic resonance venography of, 137
  - optic disc drusen versus, 113

- optic nerve sheath fenestration for, 141
- optical coherence tomography of, 76–77, 113, 140
- peripapillary retinal nerve fiber layer in, 135
- pseudopapilledema versus, 135–136, 136*f*
- transient visual loss associated with, 200
- Papillitis
  - in children, 142
  - definition of, 142
- Papillomacular bundle, 25
- Papillomacular fibers, 131
- Papillopathy, diabetic, 156
- Papillophlebitis, 157, 157*f*
- Papillorenal syndrome, 179
- Paracentral scotoma, 131, 133*t*, 134*f*
- Paramedian pontine reticular formation (PPRF), 34*f*, 36, 42, 236, 269, 282, 305–306
- Paranasal sinuses. *See also specific sinus*
  - anatomy of, 7, 9*f*
  - blood supply to, 12
  - disease of, 68*t*
- Parasellar meningiomas, 184
- Parasellar region, 5, 5*f*
- Parasellar syndrome, 249
- Parasellar tumors, 184–185
- Parastriate cortex, 31
- Parasympathetic fibers, 51
- Parasympathetic pathways, 55–56
- Paretic strabismus, 253
- Parietal bone, 4
- Parietal lobe
  - disorders of
    - hallucinations caused by, 219
    - illusions caused by, 216
  - optic radiations of, 191
- Parietal lobe syndromes, 191
- Parieto-occipital artery, 19*f*, 21*f*
- Parieto-occipital stroke, 192*f*
- Parinaud syndrome, 283, 325, 388
- Parkinson disease, 219, 334
- Parkinsonism, 338
- Parks-Bielschowsky 3-step test, 244
- Paroxysmal hemicrania, 349*t*, 358
- PCA. *See* Posterior cerebral artery
- PCoA. *See* Posterior communicating artery
- Peduncular hallucinosis, 219
- Pelizaeus-Merzbacher disease, 294
- Pelli-Robson contrast sensitivity chart, 103, 103*f*
- Pelopsia, 216
- Pendular nystagmus, 260, 303–304
- Perception of entopic phenomenon, 214
- Pericallosal artery, 14*f*
- Perineuritis, 150
- Periodic alternating nystagmus (PAN), 302
- Perioperative ischemic optic neuropathy, 155–156
- Periorbital pain
  - in Horner syndrome, 199
  - in optic neuritis, 88
- Peripapillary capillary telangiectasias, 95
- Peripapillary retina, 131, 134*f*
- Peripapillary retinal nerve fiber layer (pRNFL)
  - dropout of, 94
  - edematous, 135
  - gliosis of, 137, 138*f*
  - opacification of, 95
  - optical coherence tomography of, 76–77, 78*f*, 80*f*, 95, 107, 110, 386
- in papilledema, 135
- rakelike defects, 94, 95*f*
- segmentation of, 80*f*
- thickening of, 97*f*
- thickness of
  - imaging of, 81*f*
  - in multiple sclerosis, 113
  - optic atrophy effects on, 141
- thinning of
  - in autosomal dominant optic neuropathy, 168*f*
  - chiasmal lesions as cause of, 113
  - description of, 76, 78*f*
  - in Leber hereditary optic neuropathy, 165
  - in neuromyelitis optica, 113
  - in nutritional optic neuropathy, 113
  - in optic neuritis, 113
  - in toxic optic neuropathy, 113, 170
- Peripheral iridectomy, 215
- Peripheral iridotomy, 215
- Peripheral sector prism eyeglasses, for homonymous hemianopia, 195
- Peripheral vestibular dysfunction, 298–299
- Peripheral vestibular nystagmus, 296–297, 297*t*
- Periventricular white matter lesions, 64, 67*f*, 70, 144–145
- Persistent positive visual phenomena, 218
- PET. *See* Positron emission tomography
- Petroclinoid ligament, 22, 43
- Petrosal sinuses, 23*f*
- Petrous bone, 5
- Phakomatoses. *See* Neurocutaneous syndromes
- Pharmacologic anisocoria, 316*t*
- Pharmacologic mydriasis, 322
- Phenylephrine, 318
- Phosphenes, 217, 386
- Photisms, 386
- Photophobia, 128, 311, 324, 354, 361
- Photopsias, 216
- Photoreceptors, 215
- Photostress recovery testing, 104, 199
- Phycomycosis, 426
- Physiologic anisocoria, 314–317
- Physiologic scotoma, 24
- PICA. *See* Posterior inferior cerebellar artery
- Pie in the sky defects, 190
- Pilocarpine, 241, 324
- Pilocystic astrocytoma. *See* Optic pathway glioma
- Pineal tumors, 238
- PION. *See* Posterior ischemic optic neuropathy
- Pituitary adenoma, 68*t*, 115*f*, 181, 183*f*, 184
- Pituitary apoplexy, 181, 183*f*, 348
- Pituitary fossa, 6*f*
- Pituitary tumor, 119*f*

- Planum sphenoidale, 6*f*  
Platelet-fibrin embolus, 202, 203*f*, 204*t*  
Plexiform neurofibroma, 329*f*  
PML. *See* Progressive multifocal leukoencephalopathy  
Polarized lens test, 372  
Poly(A) binding protein nuclear 1 gene, 399  
Polymyalgia rheumatica, 382  
Polypharmacy, 88  
Pons, 43*f*  
Pontine disorders, 338  
Pontine glioma, 346  
Pontomedullary junction, 10  
Port-wine stain, 402*f*  
Positive dysphotopsia, 215  
Positron emission tomography (PET), 75  
Posterior alveolar nerve, 48  
Posterior cavernous sinus, 13  
Posterior cerebral artery (PCA)  
  anatomy of, 10, 11*f*, 16, 17*f*, 18*f*, 20*f*, 39*f*  
  aneurysms of, 409*f*  
  occlusion of, 192  
  parieto-occipital branch of, 20  
  perforators from, 19  
Posterior choroidal artery, 19*f*, 20*f*  
Posterior ciliary artery  
  branches of, 15  
  lateral long, 15  
Posterior circulation, 18–20, 20*f*, 21*f*  
Posterior circulation ischemia, 198, 407*f*, 408  
Posterior commissure, 35  
Posterior communicating artery (PCoA)  
  anatomy of, 14*f*, 15, 17*f*, 19*f*, 20*f*, 39*f*  
  aneurysm of, 73*f*, 74*f*, 239, 240*f*, 241*f*, 410  
Posterior cortical atrophy, 195, 220  
Posterior cranial fossa, 4*f*  
Posterior cranial fossa disease, 68*t*, 363  
Posterior ethmoidal artery, 14*f*, 15  
Posterior ethmoidal foramen, 10  
Posterior inferior cerebellar artery (PICA)  
  anatomy of, 18, 20*f*  
  lateral medulla blood supply from, 266  
Posterior ischemic optic neuropathy (PION), 155  
Posterior lateral choroidal artery  
  anatomy of, 17*f*  
  occlusion of, 189, 189*f*  
Posterior reversible encephalopathy syndrome (PRES)  
  characteristics of, 405  
  magnetic resonance imaging of, 405, 405*f*  
  neuromyelitis optica spectrum disorder versus, 393  
Posterior segment examination, 360  
Posterior temporal artery, 14*f*, 20*f*  
Postherpetic neuralgia, 361–362  
Potential acuity meter testing, 104  
PPRF. *See* Paramedian pontine reticular formation  
Prednisone  
  acute inflammatory demyelinating optic neuritis treated with, 145  
  giant cell arteritis treated with, 383  
Preeclampsia, 403, 405  
Pregnancy, neuro-ophthalmic disorders associated with  
  cerebral venous thrombosis, 403  
  cranial neuropathies, 403  
  lymphocytic hypophysitis, 405–406  
  overview of, 403, 405  
  posterior reversible encephalopathy syndrome, 393, 405, 405*f*  
Prenuclear pathways, 227  
PRES. *See* Posterior reversible encephalopathy syndrome  
Preseptal muscle, 51  
Pretarsal muscle, 51  
Pretecal nuclei, 55  
Pretecal syndrome, 283  
Pretecalum, 284  
Primary aberrant regeneration, of cranial nerve III, 244  
Primary headaches, 347  
Primary visual cortex  
  anatomy of, 29, 30*f*  
  central retinal activity and, 31  
  illusions caused by, 216  
  superior portion of, 31  
Prion diseases, 428  
Prism and cover test (PACT), 229–230, 324  
pRNFL. *See* Peripapillary retinal nerve fiber layer  
Progressive multifocal leukoencephalopathy (PML), 387, 422, 423*f*  
Progressive supranuclear palsy (PSP), 260, 338  
Prosopagnosia, 222  
Pr<sup>PC</sup>, 428  
Pr<sup>PCJD</sup>, 428  
Pr<sup>PS</sup>, 428  
Pseudo-Horner syndrome, 316  
Pseudo-internuclear ophthalmoplegia, 236  
Pseudo-Foster Kennedy syndrome, 154  
Pseudohyphae, 424  
Pseudoisochromatic plates, 90, 90*f*, 223  
Pseudopapilledema, 135–136, 136*f*  
Pseudophakia, 95  
Pseudoptosis, 329*f*, 333–334  
Pseudotumor cerebri. *See* Idiopathic intracranial hypertension  
PSP. *See* Progressive supranuclear palsy  
Psychotherapy, 380  
Pterygoid canal, 6*f*  
Pterygoid plexus, 21, 22*f*  
Pterygoid process, 4  
Pterygomaxillary area, 8  
Pterygomaxillary space, 56  
Pterygopalatine fossa, 10, 12  
Pterygopalatine nerves, 48  
Ptosis  
  acquired, 332*t*, 332–333  
  aponeurotic, 332  
  asymmetric, 328  
  botulism as cause of, 333  
  cerebral, 333  
  congenital, 331*f*, 331–332

- enophthalmos as cause of, 330
- fatigable, 330
- functional, 379
- in Marcus Gunn jaw-winking syndrome, 331, 331*f*
- measurements for, 328
- mechanical, 329*f*, 332*t*, 333
- myasthenia gravis, 328, 329*f*, 330, 333, 394–397, 396*f*
- myogenic, 332*t*, 333
- neurogenic, 332*t*, 332–333
- neuromuscular, 332*t*
- “senile,” 332
- traumatic, 332*t*, 333
- tumors that cause, 332
- Pulfrich phenomenon, 216
- Pulse-step matching, 271
- Pulvinar, 17*f*
- Pupil(s)
  - Adie. *See* Adie pupil
  - Argyll Robertson, 325–326
  - dilator muscles of, 53
  - fixed, dilated, 378
  - irregularity of, 313–314
  - light response of, 314
  - neovascularization of, 314
  - size of, 313, 378
  - springing, 326
  - tadpole, 314
  - tonic, 325
- Pupil-involving cranial nerve III palsy, 239–242, 241*f*, 324–325
- Pupil-sparing cranial nerve III palsy, 242–243
- Pupillary dilation, in Horner syndrome, 317
- Pupillary disorders
  - Adie pupil. *See* Adie pupil
  - anisocoria. *See* Anisocoria
  - benign episodic unilateral mydriasis, 326
  - dorsal midbrain damage as cause of, 325
  - history-taking in, 311–312
  - reactivity, 325–326
- Pupillary examination, 312–313
- Pupillary light reaction
  - pathway of, 55*f*
  - testing of, in functional neurological symptom disorder, 370
- Pupillary light reflex
  - description of, 312
  - evaluation of, 94
- Pupillary near response, 312
- Pupillary testing
  - in transient visual loss evaluations, 199
  - in vision loss evaluations, 91*f*, 91–94, 93*f*
- Pursuit movements, 276
- Quadrantanopia, 133*t*
  - Quadruple sectoranopia, 190
- Radiation damage, 68*t*
- Radiation necrosis, 429
- Radiation optic neuropathy (RON), 429, 429*f*
- Radiation therapy, 428–430
- Radiosurgery, 428–429
- Raeder paratrigeminal syndrome, 321
- Rakelike defects, 95, 96*f*
- Ramsay Hunt syndrome, 340*t*, 341, 361, 421
- RAPD. *See* Relative afferent pupillary defect
- Raymond syndrome, 238
- Raynaud phenomenon, 199
- RCVS. *See* Reversible cerebral vasoconstriction syndrome
- Real-time quaking-induced conversion (RT-QuIC), 428
- Rebif. *See* Interferon beta-1a
- Rebound nystagmus, 296
- Recognition disorders, 221*t*, 221–223
  - akinetopsia, 222
  - alexia without agraphia, 222*f*, 222–223
  - cerebral achromatopsia, 223
  - object agnosia, 221–222
  - prosopagnosia, 222
- Recoverin, 129, 131
- Rectus muscles, 45, 46*f*. *See also specific muscle*
- Recurrent meningeal artery, 12*f*
- Recurrent painful ophthalmoplegic neuropathy (RPON), 248, 354
- Red comparison test, 97–98
- Red-green color defects, 91
- Red nucleus, 17*f*, 55*f*
- Red perception testing, 94
- Reflex blepharospasm, 343
- Reflexive saccades, 268, 271–273, 275
- Refractive errors
  - optical coherence tomography of, 77
  - vision loss versus, 88
  - visual field testing for, 89
- Relapsing-remitting multiple sclerosis, 145
- Relative afferent pupillary defect (RAPD)
  - anisocoria and, 311
  - chiasmal lesions as cause of, 92
  - contralateral, cataract as cause of, 93
  - description of, 16, 55, 72*f*
  - ipsilateral, amblyopia as cause of, 93
  - lesions that cause, 93, 93*f*
  - in maculopathy, 127
  - mild, in contralateral eye, 189
  - no light perception in one eye testing, 371
  - optic nerve dysfunction and, 92
  - in optic nerve sheath meningioma, 159
  - in optic neuritis, 143
  - optic neuropathy associated with, 91*f*, 94, 151
  - in optic pathway glioma, 160
  - optic tract lesions and, 92–93, 188
  - pain associated with, 360
  - pupillary testing for, 91–94
  - retinal disease as cause of, 92
  - swinging flashlight test for, 91*f*, 91–92
  - testing for, 91–94, 371
  - in traumatic optic neuropathy, 91*f*
- Relative enophthalmos, 254
- Release hallucinations, 219

- Restrictive strabismus  
 description of, 231  
 thyroid eye disease as cause of, 252
- Retina  
 afferent visual pathways in, 24*f*, 24–25  
 emboli of, 198, 202–208, 203*f*, 204*t*  
 hemangioblastoma of, 401*f*  
 layers of, 76, 76*f*  
 transient ischemic attacks, 206–207
- Retinal angiomatosis, 401, 401*f*, 404*t*
- Retinal arterial ischemia, 202
- Retinal diseases  
 illusions caused by, 215–216  
 photopsias caused by, 216  
 relative afferent pupillary defect caused by, 92
- Retinal dystrophy, 290–291
- Retinal ganglion cell(s)  
 axons of, 26*f*  
 damage to, optic atrophy as sign of, 94  
 description of, 24  
 intrinsically photosensitive, 24, 28  
 melanopsin-containing, 24
- Retinal ganglion cell nerve fibers, 131, 132*f*
- Retinal hemorrhages, 157, 410, 411*f*
- Retinal ischemia, 205, 216
- Retinal migraine, 211–212
- Retinal nerve fiber layer (RNFL)  
 imaging of, 76*f*  
 in multiple sclerosis, 112, 386  
 myelination of, 137
- Retinal pigment epithelium  
 blood supply to, 15  
 cells of, lipofuscin in, 106  
 optical coherence tomography of, 76*f*  
 retinal photoreceptor cells and, 24
- Retinal vascular sheathing, 138*f*
- Retinitis, cytomegalovirus, 420
- Retinochoroidal collaterals, 137
- Retinopathy  
 autoimmune, 216  
 cancer-associated, 120, 121*f*, 129, 216  
 melanoma-associated, 120, 129, 130*f*, 131  
 nonparaneoplastic autoimmune, 131  
 venous stasis, 209  
 vision loss caused by, 126–131, 127*f*, 130*f*
- Retinotopic mapping, 31
- Retrobulbar block, 7
- Retrobulbar infiltration of optic nerve, 162–163
- Retrobulbar optic neuritis, 142, 143*f*
- Retrochiasmal lesions  
 anatomy of, 187–188  
 lateral geniculate nucleus, 189*f*, 189–190  
 in multiple sclerosis, 387  
 optic radiations  
 of occipital lobe, 191–194  
 of parietal lobe, 191  
 of temporal lobe, 190*f*, 190–191  
 optic tract, 188–189
- Retrochiasmal pathway, 187–188
- Retrograde axonal transport, 25
- Reversible cerebral vasoconstriction syndrome (RCVS), 417–418, 418*f*
- Rhinocerebral zygomycosis, 426*f*
- Riddoch phenomenon, 194, 224
- “Ring sign”, 159*f*
- RNFL. *See* Retinal nerve fiber layer
- RON. *See* Radiation optic neuropathy
- Rostral interstitial nucleus of medial longitudinal fasciculus, 33, 35, 270, 283
- RPON. *See* Recurrent painful ophthalmoplegic neuropathy
- RT-QuIC. *See* Real-time quaking-induced conversion
- Rubrospinal cerebellar peduncle, 238
- Saccades  
 assessment of, 271–272  
 dysmetric, 272  
 horizontal, 269*f*  
 hypermetric, 272  
 hypometric, 272  
 paramedian pontine reticular formation generation of, 269–270  
 reflexive, 268, 271–273, 275  
 slow, 272  
 volitional, 268, 271, 273
- Saccadic intrusions  
 classes of, 305  
 definition of, 287  
 with normal intersaccadic intervals, 305–306  
 schematic representation of, 305*f*
- Saccadic oscillations, 287
- Saccadic palsy, acquired, 275
- Saccadic pursuit, 276
- Saccadic system  
 description of, 33, 34*f*  
 dysfunction of, 272–273  
 function of, 258, 258*t*, 268  
 main sequence, 268
- Saccadic training, 196
- Saccomania, 306
- Saccular aneurysm, 409
- Sacculi, 261
- Sagging eye syndrome, 254
- Sagittal suture, 4
- Sarcoid granuloma, 397
- Sarcoid optic neuropathy, 158*f*
- Sarcoidosis, 341, 397–398
- Scalp, 12
- Scarring, 215
- Schlemm canal, 20
- Schwannoma, 71*f*
- Scintillating scotoma with fortification spectrum, 350
- sCJD. *See* Sporadic Creutzfeldt-Jakob disease
- Scleritis, 360
- Scotoma  
 altitudinal, 131, 133*t*  
 arcuate, 131, 133*t*, 134*f*  
 cecocentral, 131, 133*t*, 134*f*  
 central, 131, 133*t*, 134*f*, 375  
 definition of, 133*t*

- homonymous hemianopic, 193, 194*f*
- junctional, 181, 182*f*
- paracentral, 131, 133*t*, 134*f*
- scintillating scotoma with fortification spectrum, 350
- SD-OCT. *See* Spectral-domain optical coherence tomography
- Second-order intermediate neuron, 54*f*
- Second-order neuron, Horner syndrome with, 319*f*, 320*t*
- Secondary headaches, 347
- Secondary trigeminal neuralgia, 349*t*, 362–363, 363*t*
- See-saw nystagmus, 304
- Seizures
  - focal, 284, 346
  - occipital, 212
- Sella, 29*f*
- Sella turcica, 4, 4*f*, 9*f*
- Semicircular canals
  - description of, 260–262, 261*f*, 267
  - horizontal, 298*f*
  - in peripheral vestibular nystagmus, 297, 298*f*
- “Senile” ptosis, 332
- Sensitivity threshold, 100
- “Sentinel bleed,” 410
- Septic thrombosis
  - cavernous sinus, 416
  - transverse sinus, 416
- Septo-optic dysplasia, 187
- Setting sun sign, 284
- Short-lasting unilateral neuralgiform headache with conjunctival injection and tearing (SUNCT) syndrome, 349*t*, 358
- Short tau inversion recovery (STIR)
  - description of, 62*t*, 63
  - example of, 62*f*
  - orbit imaging with, 63, 65*f*, 66*f*
- Sigmoid sinus, 21, 23*f*
- Simple anisocoria, 314
- Simultanagnosia, 195, 223*f*, 223–224, 275
- Single-photon emission computed tomography (SPECT), 75
- Sino-orbital aspergillosis, 425*f*
- Siponimod, 390*t*
- SITA (Swedish Interactive Threshold Algorithm), 102
- Skew deviation, 244, 264–265
- Skull
  - arterial system of, 10, 11*f*
  - blood supply to, 10
- Skull base
  - anatomy of, 4–5
  - anterior aspect of, 5
  - bony anatomy of, 4*f*, 4–5, 5*f*
- Sleep-associated hallucinations, 218
- Slit-lamp examination, of anterior segment, 313
- Slow drift eye movements, 259
- Slow saccades, 272
- Small-cell lung carcinoma, 129
- SMART. *See* Stroke-like migraine attacks after radiation therapy
- Smooth-pursuit system
  - assessment of, 276, 278
  - description of, 34, 35*f*
  - dysfunction of, 279
  - functions of, 258*t*, 276
  - schematic diagram of, 277*f*
- SOM. *See* Superior oblique myokymia
- Somatic symptom disorder
  - characteristics of, 365
  - diagnosis of, 367
  - prevalence of, 368
  - treatment of, 220, 380
- Sound-induced photisms, 217
- SOV. *See* Superior ophthalmic vein
- Spasm
  - of accommodation, 379
  - of near reflex, 281, 378
- Spasmus nutans syndrome, 294–295
- Spastic parietic hemifacial contracture, 345
- SPECT. *See* Single-photon emission computed tomography
- Spectral-domain optical coherence tomography (SD-OCT), 108–109
- Sphenocavernous syndrome, 249
- Sphenoid bone
  - anatomy of, 7
  - greater wing of, 5, 5*f*, 6*f*, 10
  - lesser wing of, 4–5, 5*f*, 6*f*
- Sphenoid sinus
  - anatomy of, 4, 7, 9*f*
  - magnetic resonance imaging of, 60*f*
  - surgery in, 7
- Sphenoid wing, 60*f*
- Sphenopalatine ganglion, 56
- Sphingosine-1-phosphate receptor modulator, 389
- Spinal cord, 393
- Spinal nucleus, 46
- Spiral of Tillaux, 45
- Splenium of corpus callosum, 222, 222*f*
- Sporadic Creutzfeldt-Jakob disease (sCJD), 428
- Spread of comitance, 245
- Springing pupil, 326
- Square-wave jerks (SWJs), 259–260, 305*f*
- Square waves, 259
- SS-OCT. *See* Swept-source optical coherence tomography
- SSS. *See* Superior sagittal sinus
- Stapedial nerve, 51
- Staticokinetic dissociation, 193–194, 224
- Stereocilia, 261*f*
- Stereopsis
  - testing of, 371–373
  - visual acuity to, comparison of, 374*t*
- Stereotactic fractionated radiation therapy, 159
- STIR. *See* Short tau inversion recovery
- Strabismus
  - childhood, 255
  - supranuclear causes of, 233, 233*t*
- Strabismus fixus, 254
- Straight sinus, 23*f*
- Striate cortex, 29
- String sign, 321*f*



- Stroke
  - imaging modality for, 68*t*
  - internuclear ophthalmoplegia caused by, 236
  - macula-sparing homonymous hemianopia as cause of, 192*f*, 192–193
  - occipital lobe lesions from, 192
  - one-and-a-half syndrome caused by, 236
  - parieto-occipital, 192*f*
  - prosopagnosia caused by, 222
- Stroke-like migraine attacks after radiation therapy (SMART), 430
- Sturge-Weber syndrome, 401, 402*f*, 404*t*
- Subacute necrotizing encephalopathy, 294
- Subarachnoid hemorrhage, 410–411
- Subarachnoid space, 56
- Subclavian artery
  - left, 18
  - right, 18
- Subclavian steal, 408
- Suboccipital craniectomy, 345
- Subungual lesions, 401*f*
- SUNCT syndrome, 349*t*, 358
- Superficial temporal artery
  - anatomy of, 12, 12*f*
  - frontal branch of, 12*f*
- Superior cerebellar artery
  - anatomy of, 17*f*, 19
  - aneurysms of, 409*f*
  - trigeminal nerve and, 47
- Superior cervical ganglion lesions, 317
- Superior colliculus
  - anatomy of, 17*f*, 27
  - brachial lesions of, 55
- Superior muscular artery, 15
- Superior oblique muscle
  - anatomy of, 8*f*, 45
  - functions of, 46*f*
  - innervation of, 7
  - magnetic resonance imaging of, 60*f*
  - trochlear nerve and, 42*f*
- Superior oblique myokymia (SOM), 308–309
- Superior oblique tenectomy, 308
- Superior ophthalmic vein (SOV)
  - anatomy of, 8*f*, 20–21, 23*f*
  - imaging of, 251*f*
- Superior orbital fissure
  - anatomy of, 4*f*, 4–5, 6*f*, 10, 39*f*
  - lesions of, 249
- Superior orbital rim, 7
- Superior palpebral vein, 22*f*
- Superior petrosal sinus, 22, 23*f*
- Superior rectus muscle
  - anatomy of, 8*f*, 45
  - functions of, 46*f*
  - magnetic resonance imaging of, 60*f*
- Superior sagittal sinus (SSS)
  - anatomy of, 21, 23*f*
  - cerebrospinal fluid absorption by, 21
  - thrombosis of, 416
- Superior salivatory nucleus, 56
- Superior segment hypoplasia, 187
- Supranuclear disorders
  - diplopia caused by, 233, 233*t*
  - strabismus caused by, 233, 233*t*
- Supranuclear facial palsy, 336*f*
- Supranuclear pathways, 227–228
- Supraorbital artery, 12*f*
- Supraorbital foramen, 10
- Supraorbital vein, 22*f*
- Supratrochlear artery, 12*f*
- Supratrochlear vein, 22*f*
- Surgery
  - aspergillomas treated with, 425
  - eyelid retraction treated with, 334
  - infantile nystagmus syndrome treated with, 291, 292*f*
  - invasive aspergillosis treated with, 425
  - lymphocytic hypophysitis treated with, 406
  - optic nerve glioma treated with, 161–162
- Surgical myectomy, 344
- Susac syndrome, 104
- Susceptibility weighted imaging (SWI), 64
- Swept-source optical coherence tomography (SS-OCT), 108–109
- SWI. *See* Susceptibility weighted imaging
- Swinging flashlight test, 91*f*, 91–92
- SWJs. *See* Square-wave jerks
- Sympathetic pathways, 52–54
- Syndrome of crocodile tears, 337
- Synechia, 314, 318
- Synkinetic phenomena, 243–244, 339
- Syphilis, 422
- Tadpole pupil, 314
- Tangent screen testing, 377, 377*f*
- Tardive dyskinesia, 344, 346
- TD-OCT. *See* Time-domain optical coherence tomography
- Tear film abnormalities, 200
- Tecfidera. *See* Dimethyl fumarate
- TED. *See* Thyroid eye disease
- Tegmental mesencephalic paralysis, 238
- Teleopsia, 216
- Temporal arteritis. *See* Giant cell arteritis
- Temporal artery biopsy, for giant cell arteritis, 382–383
- Temporal bone
  - anatomy of, 5
  - petrous portion of, 6*f*
- Temporal crescent, 192, 193*f*
- Temporal fossa, 7
- Temporal lobe
  - magnetic resonance imaging of, 60*f*
  - Meyer loop of, 190
  - optic radiations of, 190–191
  - tumors in, 190–191
- Temporal lobe lesions, 219
- Temporal-superior-nasal-inferior-temporal peripapillary retinal nerve fiber layer, 77, 81*f*
- Temporomandibular joint (TMJ) syndrome, 361
- Tension-type headache, 354–357

- Tensor tympani, 47
- Tensor veli palatini, 47
- Teprotumumab, 164
- Teriflunomide, 391*t*
- Terson syndrome, 410, 411*f*
- Thalamostriate arteries, 20
- Third-order neuron, Horner syndrome with, 319*f*, 320*t*
- Third-order neuron segment, 54*f*
- Thoracic aneurysms, 383
- Threshold value, 100
- Thromboembolic disease, 382
- Thrombosis
  - cavernous sinus, 20, 416
  - cerebral venous, 403, 415–417
  - lateral sinus, 416–417
  - superior sagittal sinus, 416
  - transverse sinus, 416–417
- Thunderclap headaches, 417
- Thymectomy, 397
- Thymomas, 397
- Thyroid-associated orbitopathy. *See* Thyroid eye disease
- Thyroid eye disease (TED)
  - definition of, 397
  - description of, 163–164, 164*f*
  - eyelid retraction caused by, 334, 335*f*
  - imaging modality for, 68*t*
  - in myasthenia gravis, 395
  - restrictive strabismus caused by, 231, 252
  - signs and symptoms of, 397
- TIAs. *See* Transient ischemic attacks
- Tic douloureux. *See* Trigeminal neuralgia
- Tilted disc syndrome, 178*f*, 178–179
- Time-domain optical coherence tomography (TD-OCT), 107–108
- Tinted lenses, for benign essential blepharospasm, 344
- TMJ syndrome. *See* Temporomandibular joint (TMJ) syndrome
- Todd paralysis, 346
- Tolosa-Hunt syndrome, 249–250
- Tonic deviations, 282–285
- Tonic orbicularis, 52
- Tonic vergence, 279–280
- Topiramate, 355
- Torcular Herophili, 21, 23*f*
- Torsional nystagmus, 299, 302
- Torticollis, 294
- Tourette syndrome, 346
- Toxic optic neuropathy, 113, 169–171
- Toxic vestibular dysfunction, 299
- Toxoplasmosis, 422–423
- Tractus solitarius, nucleus of, 56
- “Tram track sign”, 159*f*
- Transesophageal echocardiography, 206
- Transient ischemic attacks (TIAs)
  - occipital, 211
  - retinal, 206–207
  - treatment of, 207
  - vertebrobasilar system, 352, 406, 407*f*, 408
- Transient visual loss (TVL)
  - binocular
    - cerebral ischemia as cause of, 199
    - characteristics of, 197–198
    - duration of, 198
    - migraine as cause of, 198, 211
    - occipital ischemia as cause of, 211
    - occipital mass lesions as cause of, 211
    - occipital seizures as cause of, 212
    - pattern/description of, 198
  - cerebral ischemia as cause of, 199
  - cerebrovascular causes of, 406
  - characteristics of, 197–199
  - clinical features of, 198
  - duration of, 198
  - examination of, 199
  - gaze-evoked, 200
  - giant cell arteritis as cause of, 198, 204, 208
  - monocular
    - amaurosis fugax as cause of, 202
    - central retinal vein occlusion as cause of, 208–209
    - cerebral stroke caused by, 205–206
    - characteristics of, 197–198
    - clinical evaluation of, 204–205
    - duration of, 198
    - flowchart for, 201*f*
    - halos associated with, 200
    - hypercoagulability as cause of, 210, 210*t*
    - hyperviscosity syndrome as cause of, 210
    - imaging of, 205–206
    - laboratory evaluation of, 204–205
    - macular causes of, 200
    - ocular causes of, 200, 201*f*
    - ocular hypoperfusion as cause of, 208–210
    - ocular ischemic syndrome as cause of, 209*f*, 209–210
    - orbital causes of, 200, 201*f*
    - pattern/description of, 198
    - postural changes as cause of, 209
    - prognosis for, 206
    - retinal emboli as cause of, 198, 202–208, 203*f*, 204*t*
    - risk stratification for, 207
    - systemic causes of, 208–210
    - vascular causes of, 201*f*, 202–210
    - vasculitis as cause of, 208
    - vasospasm as cause of, 210
  - neurologic signs and symptoms of, 199
  - overview of, 197
  - pattern/description of, 198
  - predisposing conditions, 199
  - prognosis for, 206
  - recovery from, 198
  - risk stratification for, 207
  - signs and symptoms of, 198–199
  - thromboembolic disease as cause of, 382
- Transmissible spongiform encephalopathies, 428
- Transthoracic echocardiography, 206
- Transverse facial artery, 12*f*
- Transverse myelitis, longitudinally extensive, 393, 393*f*

- Transverse sinus
  - anatomy of, 21, 23*f*
  - thrombosis of, 416–417
- Trauma
  - imaging modality for, 68*t*
  - ptosis caused by, 332*t*, 333
- Traumatic optic neuropathy
  - computed tomography of, 173*f*
  - description of, 172–174
  - direct, 172
  - indirect, 173
  - relative afferent pupillary defect in, 91*f*
- Treponema pallidum*, 422
- Trial frame with plus and minus cylinder lenses, 372, 373*f*
- Trigeminal autonomic cephalgias, 321, 357–358
- Trigeminal ganglion, 47, 48*f*
- Trigeminal nerve. *See* Cranial nerve V
- Trigeminal neuralgia, 47, 347, 349*t*, 362–363, 363*t*
- Trigeminal nucleus, 45
- Triptans, 355
- Tritanopia, 167
- Trochlea, 45
- Trochlear headache, 360
- Trochlear nerve. *See* Cranial nerve IV
- Trochleitis, 360
- Tropheryma whipplei*, 309
- Tuberculous meningitis, 421
- Tuberculum sella, 6*f*
- Tuberous sclerosis, 400, 401*f*, 404*t*
- Tumors, 64*f*
- TVL. *See* Transient visual loss
- Tysabri. *See* Natalizumab
- UGH syndrome, 200
- Uhthoff phenomenon, 198, 386
- Ultrasonography
  - carotid Doppler imaging, 75
  - carotid stenosis on, 75
  - description of, 75
  - giant cell arteritis evaluations, 75
  - indications for, 58
  - internal carotid artery dissection on, 413
  - optic disc drusen on, 176
  - orbital Doppler, 75
  - vision loss evaluations, 115
- Uncus, 41
- Unformed visual hallucinations, 193
- Upbeat nystagmus, 301
- Upgaze paresis, 284
- Upper eyelid crease, 51
- Urrets-Zavalía syndrome, 314
- Uveitis
  - description of, 361
  - fluorescein angiography evaluation of, 105
  - in multiple sclerosis, 387
- Uveitis-glaucoma-hyphema (UGH) syndrome, 200
- Valsalva maneuver
  - orbital varices with, 70, 70*f*
  - vestibular nystagmus evaluations, 297
- Variant Creutzfeldt-Jakob disease (vCJD), 428
- Varicella-zoster virus, 421
- Vasculitis, 208
- Vasogenic edema, 67*t*
- Vasospasm, 210, 410
- vCJD. *See* Variant Creutzfeldt-Jakob disease
- Vein of Galen, 21
- Vein of Labbé, 21
- Venous sinus thrombosis
  - magnetic resonance venography of, 73, 74*f*
  - risk factors for, 139
- Venous stasis retinopathy, 209
- Ventral uvula, 37
- Ventriculoperitoneal shunt, 142
- VEP testing. *See* Visual evoked potential (VEP) testing
- Vergence
  - accommodative, 279
  - fusional, 279–280
  - tonic, 279–280
- Vergence system
  - dysfunction of, 280–281
  - function of, 258, 258*t*, 279
- Versions, 229
- Vertebral artery
  - anatomy of, 10
  - aneurysms of, 409*f*
  - dissection of, 413
  - reversal of blood flow in, 408
- Vertebrobasilar atherosclerotic disease, 19
- Vertebrobasilar insufficiency, 406–408
- Vertebrobasilar system disease, 406–408, 407*f*
- Vertical gaze-evoked nystagmus, 236, 295
- Vertical gaze palsies, 282
- Vertical nystagmus, 299
- Vertical-oblique diplopia, 235
- Vertical prism dissociation test, 371, 372*f*, 373
- Vertical pursuit movements, 276
- Vertical saccades, 266
- Vertical saccadic palsy, 309
- Vestibular nerve, 36
- Vestibular neuronitis, 298
- Vestibular nuclei, 36
- Vestibular nystagmus
  - central, 299–303
  - description of, 271, 288*f*
  - peripheral, 296–297, 297*t*
- Vestibular-ocular reflex (VOR)
  - assessment of, 262–264, 278*f*
  - cancellation of, 278, 278*f*
  - description of, 36–37
  - dysfunction of, 264–267
  - eye movements from, 267
  - function of, 258*t*, 260
  - gain, 263–264
  - head impulse test for, 263
  - labyrinth in, 260, 261*f*
  - nystagmus, 261
  - oxotoxins' effect on, 299
- Vestibular-ocular system
  - dysfunction of, 264–267

- function of, 258, 258*t*, 260
- ocular tilt reaction, 261–262, 263*f*, 265
- semicircular canals, 260–262, 261*f*
- Vestibular system dysfunction, 298–299
- Vestibulocerebellum lesions, 300
- Vidian nerve, 56
- Vision loss
  - acute, 89*t*
  - acute idiopathic blind-spot enlargement syndrome
    - as cause of, 107, 122, 123*f*, 127–128
  - acute zonal occult outer retinopathy as cause of, 107, 109*f*, 127–128
  - assessment goals for, 187
  - autoimmune retinopathies as cause of, 129–131, 130*f*
  - bilateral, 87–88
  - cancer-associated retinopathy as cause of, 120, 121*f*, 129
  - chiasmal lesions as cause of, 180–186
  - chronic, 89*t*
  - cognitive status assessments in, 88
  - cone dystrophy as cause of, 126–129
  - cortical visual impairment as cause of, 194–195
  - craniopharyngiomas as cause of, 184
  - etiology of, 89*t*
  - examination for
    - color vision testing, 90–91
    - contrast sensitivity testing, 102–104
    - electrophysiologic testing, 117–122
    - electroretinography, 120–122, 122*f*
    - fluorescein angiography, 104–105, 106*t*
    - fundus, 94–95, 95*f*, 96*f*
    - fundus autofluorescence, 105–107, 106*t*
    - indocyanine green angiography, 105, 106*t*
    - optic nerve head, 94–95, 95*f*, 96*f*
    - optical coherence tomography, 106*t*, 107–115
    - photostress recovery testing, 104
    - potential acuity meter testing, 104
    - pupillary testing, 91*f*, 91–94, 93*f*
    - ultrasonography, 106*t*, 115
    - visual acuity testing, 89–90
    - visual evoked potential testing, 117–120
    - visual field evaluation. *See* Visual field evaluation
  - in functional neurological symptom disorder, 367
  - gradual onset of, 88
  - hallucinations associated with, 219
  - history-taking for, 87–88
  - in homonymous hemianopia, 88
  - internal carotid artery aneurysms as cause of, 184
  - lateral geniculate nucleus lesions as cause of, 189*f*, 189–190
  - melanoma-associated retinopathy as cause of, 120, 129, 130*f*, 131
  - multiple evanescent white dot syndrome as cause of, 107, 122, 127–128
  - neuroretinitis as cause of, 148–150, 150*f*
  - no light perception in both eyes, 369–371, 370*f*
  - no light perception in one eye, 371–372
  - nonarteritic anterior ischemic optic neuropathy as cause of, 153
  - nonparaneoplastic autoimmune retinopathy as cause of, 131
  - ocular media abnormalities as cause of, 126
  - optic nerve hypoplasia as cause of, 177*f*, 177–178
  - optic neuritis as cause of, 142–148
  - optic neuropathy as cause of, 131–179. *See also* Optic neuropathy
  - optic radiations
    - of occipital lobe, 191–194
    - of parietal lobe, 191
    - of temporal lobe, 190*f*, 190–191
  - optic tract, 188–189
  - optic tract lesions as cause of, 188–189
  - papillophlebitis as cause of, 157, 157*f*
  - parasellar meningiomas as cause of, 184
  - perineuritis as cause of, 150
  - perioperative ischemic optic neuropathy as cause of, 155–156
  - pituitary adenoma as cause of, 181, 183*f*, 184
  - reduced vision in both eyes, 374–375
  - refractive error versus, 88
  - retinopathies as cause of, 126–131, 127*f*, 130*f*
  - retrobulbar infiltration of the optic nerve as cause of, 162–163
  - signs and symptoms of, 88
  - subacute, 89*t*
  - sudden, 88
  - thyroid eye disease as cause of, 163–164, 164*f*
  - tilted disc syndrome as cause of, 178*f*, 178–179
  - time course of, 88
  - transient. *See* Transient visual loss
  - unilateral, 87–88
  - vertical prism dissociation test for, 371, 372*f*
  - vision rehabilitation for, 195–196
- Vision rehabilitation, 195–196
- Visual acuity
  - dynamic, 264
  - during head reactions, 264
  - stereopsis to, comparison of, 374*t*
- Visual acuity testing
  - contrast sensitivity testing versus, 102
  - vision loss evaluations with, 89–90
- “Visual aids,” 374
- Visual allesthesia, 224
- Visual awareness
  - disorders of, 224–225
  - physiology of, 220
- Visual cortex
  - blood supply to, 192
  - hallucinations caused by, 217–220
  - primary, disturbances of, 193–194
- Visual deficit disorders, 224–225
- Visual evoked potential (VEP) testing
  - flash and pattern-reversal, 370–371
  - functional neurological symptom disorder evaluations, 370–371
  - indications for, 118
  - vision loss evaluations with, 117–120
- Visual field defects
  - absolute, 133*t*

- automated perimetry for, 375*f*, 375–376
  - bilateral constricted, 376*f*
  - bitemporal, 398
  - in chronic papilledema, 139
  - confrontation testing for, 376
  - congruous, 29, 188
  - homonymous, 97, 188, 398, 407–408
  - incongruous, 188
  - occipital lobe lesions as cause of, 191, 192*f*
  - in optic disc drusen, 174
  - relative, 133*t*
  - retrochiasmal damage as cause of, 188
  - terminology for describing, 133*t*
  - tests for, 375*f*, 375–377, 376*f*, 377*f*
  - types of, 131, 133*t*
- Visual field evaluation
  - Amsler grid testing, 98
  - confrontation testing, 97–98
  - perimetry
    - automated static, 99*f*, 99–102, 101*f*
    - description of, 98–99
    - kinetic, 98–100
    - static, 98–100
  - vision loss assessments with, 96–102
- Visual field patterns, 131, 134*f*
- Visual field testing, 88
- Visual hallucinations
  - assessment of, 214
  - aura and, 218, 220
  - brain lesions as cause of, 219
  - cortical origin of, 217–220
  - definition of, 213, 216
  - formed, 193, 216
  - hypnagogic, 218
  - hypnopompic, 218
  - illusion versus, 213
  - intermittent, 218
  - migraine as cause of, 218
  - neurodegenerative disease as cause of, 219–220
  - nonophthalmic conditions that cause, 214*t*
  - ocular origin of, 216–217
  - optic neuritis as cause of, 217
  - palinopsia as cause of, 217–218
  - perception of entoptic phenomenon versus, 214
  - persistent positive visual phenomena as cause of, 218
  - release, 219
  - sleep-associated, 218
  - treatment of, 220
  - unformed, 193, 216
  - vision loss as cause of, 219
- Visual impairment, cortical, 194–195
- Visual pathways
  - lesions of, 180*f*
  - schematic diagram of, 180*f*
  - vascular supply of, 19*f*
- Visual snow syndrome, 353
- Visual–spatial relationship disorders, 223–224
- Visual–visual disconnection, 222
- Vitamin A deficiency, 216
- Vitamin D deficiency, 113, 384
- Vitreopapillary traction, 137
- Vitreoretinal adhesions, 216
- Vitreous, 60*f*
- Vitreous detachment with persistent vitreoretinal adhesions, 216
- Vitritis, 387
- Volitional saccades, 268, 271, 273
- Voluntary flutter, 307, 377
- Voluntary nystagmus, 307, 377
- von Hippel–Lindau disease, 401, 401*f*, 404*t*
- VOR. *See* Vestibular-ocular reflex
- Voriconazole, 425
- Vortex veins, 20
- Vorticose vein, 22*f*
- Vumerity. *See* Dimethyl fumarate
- Wall-eyed bilateral internuclear ophthalmoplegia (WEBINO), 236, 387
- Wallenberg syndrome, 18, 224, 407
- Warfarin, 207
- Wayfinding training, 195
- Weber syndrome, 238
- WEBINO. *See* Wall-eyed bilateral internuclear ophthalmoplegia
- Weight loss, for idiopathic intracranial hypertension, 141
- Wernicke encephalopathy, 233
- Whipple disease, 309
- White flashes, vertical, 216
- White matter disease, 68*t*
- Whole-brain radiation therapy, 428
- Wilson disease, 285, 334
- Wolfram syndrome, 169, 169*t*
- Wyburn-Mason syndrome, 401, 403*f*, 404*t*
- Yeasts, 424
- Zeposia. *See* Ozanimod
- Zygomatic bone, 4, 6*f*, 7
- Zygomatic nerve, 8*f*, 49
- Zygomaticofacial artery, 12*f*
- Zygomaticofacial nerve, 49
- Zygomaticomaxillary suture, 7
- Zygomaticotemporal artery, 12*f*
- Zygomaticotemporal foramen, 10
- Zygomaticotemporal nerve, 49
- Zygomycosis, 426*f*, 426–427













